
Profound Opioid and Medetomidine Withdrawal: A Case Series and Narrative Review of Available Literature

Phil Durney , Elise Paquin , [Gamal Fitzpatrick](#) , [Drew Lockstein](#) , [TaReva Warrick-Stone](#) , [Maeve Montesi](#) , [Sejal Patel](#) , Jamal Rashid , [Oluwarotimi Vaughan-Ogunlusi](#) , Kelly Goodsell , [Jennifer L. Kahoud](#) , Christopher Martin , Keira Chism , Paul Goebel , Karen Alexander , [Dennis Goodstein](#) , [Kory S. London](#) *

Posted Date: 8 October 2025

doi: 10.20944/preprints202508.0751.v3

Keywords: medetomidine; xylazine; fentanyl; alpha-2 agonist withdrawal; dexmedetomidine withdrawal; opioid withdrawal; adulterant; sedative withdrawal; low dose dexmedetomidine; high dose dexmedetomidine; toxicokinetics



Preprints.org is a free multidisciplinary platform providing preprint service that is dedicated to making early versions of research outputs permanently available and citable. Preprints posted at Preprints.org appear in Web of Science, Crossref, Google Scholar, Scilit, Europe PMC.

Copyright: This open access article is published under a Creative Commons CC BY 4.0 license, which permit the free download, distribution, and reuse, provided that the author and preprint are cited in any reuse.

Case Report

Profound Opioid and Medetomidine Withdrawal: A Case Series and Narrative Review of Available Literature

Phil Durney ^{1,2,3}, Elise Paquin ^{1,2,3}, Gamal Fitzpatrick ^{1,2,3}, Drew Lockstein ⁴, TaReva Warrick-Stone ^{2,3}, Maeve Montesi ^{1,2}, Sejal Patel ⁴, Jamal Rashid ⁴, Oluwarotimi Vaughan-Ogunlusi ⁴, Kelly Goodsell ^{3,4}, Jennifer L. Kahoud ^{3,4}, Christopher Martin ^{2,3,5}, Keira Chism ^{2,3,5}, Paul Goebel ⁶, Karen Alexander ⁷, Dennis Goodstein ^{2,6} and Kory S. London ^{2,3,4,*}

¹ Department of Internal Medicine, Thomas Jefferson University, 1020 Walnut Street, Philadelphia, PA 19107, USA

² Jefferson Addiction Multidisciplinary Service, Thomas Jefferson University, 1020 Walnut Street, Philadelphia, PA 19107, USA

³ Sidney Kimmel Medical College, Thomas Jefferson University, 1020 Walnut Street, Philadelphia, PA 19107, USA

⁴ Department of Emergency Medicine, Thomas Jefferson University, 1020 Walnut Street, Philadelphia, PA 19107, USA

⁵ Department of Psychiatry, Thomas Jefferson University, 1020 Walnut Street, Philadelphia, PA 19107, USA

⁶ Department of Pharmacy, Thomas Jefferson University, 1020 Walnut Street, Philadelphia, PA 19107, USA

⁷ Friends Research Institute, 1516 N. 5th St., Suite 321, Philadelphia, PA 19122, USA

* Correspondence: kory.london@jefferson.edu

Abstract

Medetomidine, a potent veterinary α_2 agonist, has emerged as a fentanyl adulterant in the non-medical opioid supply. Its use has been linked to a novel withdrawal syndrome that is often resistant to conventional treatment protocols. Four cases are presented demonstrating extreme forms of this withdrawal syndrome. A literature review is provided showing both the paucity of available literature as well as potential avenues for treatment and future research. As adulterants continue to proliferate in the illicit drug supply, clinicians should anticipate atypical withdrawal phenotypes and consider early intervention.

Keywords: medetomidine; xylazine; fentanyl; alpha-2 agonist withdrawal; dexmedetomidine withdrawal; opioid withdrawal; adulterant; sedative withdrawal; low dose dexmedetomidine; high dose dexmedetomidine; toxicokinetics

1. Introduction

Philadelphia has been at the forefront of the evolving opioid crisis, with illicit fentanyl often contaminated by potent sedatives that complicate withdrawal management [1]. Beginning around 2019, the veterinary tranquilizer xylazine became a ubiquitous fentanyl adulterant – detected in up to 98–99% of tested “dope” samples by 2023 [2]. The combination of high-potency synthetic opioids and xylazine led to unusually challenging withdrawal syndromes and even precipitated withdrawal in patients started on buprenorphine [3]. In response, hospitals in Philadelphia developed novel withdrawal protocols tailored to “tranq dope” (fentanyl/xylazine) users, employing short-acting opioids, ketamine, antipsychotics for nausea/anxiety, and α_2 agonists to replace xylazine’s effect [4]. Early data showed these protocols were effective during the xylazine era, achieving significant symptom relief and reducing patients leaving the hospital against medical advice.

Since mid-2024, however, clinicians and public health advocates in Philadelphia noted a sharp shift in adulterants [5,6]. Medetomidine, a potent α -2-agonist used in veterinary anesthesia, largely supplanted xylazine as the dominant fentanyl adulterant. This change coincided with Pennsylvania's scheduling of xylazine as a controlled substance, possibly prompting suppliers to substitute medetomidine. Notably, medetomidine is a racemic mixture of dexmedetomidine, a drug used in critical care and operative sedation, and its enantiomer. It is up to 200 times more potent than xylazine as an α 2 receptor agonist [7,8]. By late 2024, laboratory surveillance confirmed medetomidine's widespread presence: 72% of tested opioid samples contained medetomidine (while xylazine prevalence fell to ~30%) [6]. Frontline clinicians began encountering fentanyl users with an atypical, severe withdrawal syndrome distinct from opioid- or xylazine-withdrawal [5]. Reported features include intractable vomiting, diaphoresis, tremors, and sympathetic crises characterized by extreme tachycardia and hypertensive emergencies often refractory to treatment for fentanyl and xylazine withdrawal.

Unlike ordinary opioid withdrawal, some patients exhibited altered mental status with periods of stupor, waxing/waning hypoactive encephalopathy, that were surmised to represent posterior reversible encephalopathy syndrome due to severe blood pressure elevation, and other cases of demand myocardial ischemia and stress cardiomyopathy. These severe withdrawal presentations are hypothesized to represent medetomidine withdrawal, analogous to dexmedetomidine rebound, given medetomidine's pharmacology [9]. Alarming, previously efficacious treatment protocols seemed ill equipped to manage symptoms, with marked attenuation in reduction of clinical opiate withdrawal scale (COWS) scores [10]. Health officials and clinicians reported that many such patients rapidly deteriorated and required critical care for management. This emerging medetomidine-linked withdrawal has been deemed life-threatening, often necessitating unprecedented escalations in therapy.

We describe the care of four individuals with opioid use disorder who developed extreme withdrawal syndromes due to suspected or confirmed medetomidine-adulterated fentanyl. These cases exemplify the sometimes intractable clinical course of medetomidine withdrawal and highlight the challenges in management of this newly recognized syndrome. We then describe available literature on the human experience with adulterated medetomidine and future concepts in the treatment of severe withdrawal.

2. Materials and Methods

2.1. Population

Four cases of severe "opioid" withdrawal were referred by the addiction medicine service to the emergency department (ED) quality assurance and peer review committee for review. These referrals were sent due to the atypical and unprecedented nature of their clinical courses. Given the small number of cases, there were no further inclusion nor exclusion criteria were utilized. One of the cases had urine toxicology testing via liquid chromatography-tandem mass spectrometry for medetomidine exposure. The remaining cases were sent based on clinical course and are described given the stereotypical symptoms the patients experienced in temporal relationship to medetomidine adulteration in Philadelphia, PA, USA.

2.2. Case Series Review

Cases were reviewed and written in narrative fashion by separate authors and are presented from the timeline of arrival in the ED through their ultimate departure from the hospital. All records were taken from the electronic health record (EPIC Systems, Madison, WI, USA). All identifying details were removed. Due to the retrospective and deidentified nature of this evaluation, no explicit consent was sought from patients.

2.3. Medication Usage

Use of medications are directed by a hospital formulary, which is based on a host of sources, including manufacturer labels and expert guidance. The formulary dosage thresholds are built into the electronic health record. For the below cases, infusions of medications are often referenced as being 'maximally dosed.' The dosing ranges denoted by the hospital formulary of described medications include: dexmedetomidine – maximally dosed at 1.5 mcg/kg/hour; fentanyl – maximally dosed at 500 mcg/hour; midazolam - maximally dosed at 16 mg/hour; propofol – maximally dosed at 100 mcg/kg/hour and hydromorphone – maximally dosed at 10 mg/hour. Conversion of medications to standard oral morphine and diazepam units were done systematically for figure development. [11,12]

The micro-induction of buprenorphine utilized includes: 150 mcg every 6 hours x 4 doses, 450 mcg every 6 hours x 4 doses, 2 mg every 6 hours x 4 doses, 4 mg every 8 hours x 3 doses, 8 mg every 12 hours x 2 doses. The 2, 4 and 8 mg doses of buprenorphine utilize combination films with naloxone, 0.5, 1 and 2 mg, respectively. Of note, if patients develop precipitated withdrawal during the micro-induction, future doses are held, and titration is held for an additional 24 hours or until dose escalation is tolerated.

2.4. Narrative Literature Review

We separately conducted a narrative literature review to synthesize current evidence on the co-management of opioid and medetomidine withdrawal, with an emphasis on the role of α_2 agonists. The search was conducted by reviewers (KL, DG, PD, SP, JR) using PubMed and Google Scholar between June 1 and July 1, 2025. Example search terms included: "medetomidine human," "medetomidine fentanyl," "medetomidine adulterant," "medetomidine withdrawal," "dexmedetomidine withdrawal," "opioid withdrawal alpha-2 agonist," "transdermal clonidine," "high dose dexmedetomidine," "low dose dexmedetomidine," "combination dexmedetomidine clonidine," and "combination clonidine tizanidine."

Inclusion criteria were human studies, case reports, case series, observational studies, narrative reviews, editorials, and clinical guidelines addressing the human experience with medetomidine exposure, dexmedetomidine use, and use of α_2 agonists in withdrawal management. Due to the paucity of research directly examining medetomidine withdrawal, we also included literature on dexmedetomidine and opioid withdrawal as proxy models where relevant. Animal studies were included only where no human data was discovered and solely surround pharmacokinetics and dynamics.

In addition to indexed databases, we conducted a plain-language Google search to identify relevant grey literature, including continuing education resources and public health advisories. This yielded additional context on emerging clinical practices, such as the use of low dose dexmedetomidine in non-intensive care settings, and public alerts from regional health departments, including the Philadelphia Department of Public Health.

This manuscript was developed in accordance with the CARE guidelines for case reports and the SANRA criteria for narrative reviews to ensure clarity, transparency, and scientific rigor [13,14]. No quantitative synthesis or formal risk-of-bias assessment was performed due to the narrative nature of the review and heterogeneity of the included sources. This study was evaluated by the Thomas Jefferson University Institutional Review Board and was approved given the retrospective and de-identified nature (IRB #1685) of the patient data.

3. Results

3.1. Case One

A 32-year-old female with a past medical history of opioid use disorder (reported use of 8-10 bags/day, taken via insufflation), and denied other relevant past medical history, including a history of other drug use such as cocaine, amphetamines, benzodiazepines, or alcohol, presented to the ED in police custody with symptoms of vomiting, body aches, tremor, and anxiety. She reported she had

last used drugs at approximately 14.5 hours prior to arrival, at her usual dose and method. She noted that she was arrested on an outstanding warrant and brought to the police station, whereas she was brought to the hospital several hours later due to onset of severe vomiting and patient report of withdrawal.

Her triage vital signs noted an oral temperature of 98.2 degrees Fahrenheit, heart rate (HR) 134, respiratory rate (RR) 29, initial blood pressure (BP) 143/106 with a pulse oximetry (SPO2) of 99% on room air. Her initial COWS score was documented at 42, denoting severe withdrawal. As per protocol at the hospital, she was ordered standardized severe opioid/adulterant medications: hydromorphone 2 mg intravenous push (IVP), ketamine 10 mg IVP, diphenhydramine 25mg IVP, olanzapine 10 mg oral dissolving tablet (ODT), lactated ringer's intravenous fluid 1000 mL (IVF), acetaminophen 1000 mg PO, gabapentin 300 mg PO, tizanidine 4 mg PO. Due to profuse vomiting, she was unable to take the oral medications but received all intravenous (IV) medications and fluid. Given inability to tolerate the olanzapine, she was also given droperidol 5 mg IVP x 1 to help try to get vomiting under control. Her vital signs were then noted to dramatically worsen, developing a HR first of 166 and as high as 205, with RR of 45, with relatively mild hypertensive BP, 118/98. ECG demonstrated sinus tachycardia, a rate of 164, PR interval 128 ms, QRS interval 70 ms, QTc interval 488 ms with non-specific, favored rate-related, repolarization changes.

Due to this severe worsening, she was given serial doses of medication to better control her withdrawal. These included, over a 90 minute period: diazepam 10 mg IVP, hydromorphone 10 mg IVP, diazepam 10 mg IVP, acetaminophen 1000 mg IVPB and hydromorphone 20 mg IVP. The sum total impact on her vital signs was that her RR went from 29-46 prior to these medications, to a documented RR of 16. She was still noted to be wide awake, tremulous, anxious, and complaining of severe pain. At that point, her other vital signs were: BP: 134/60, HR: 170, SPO2 = 97% on RA and a temperature of 100.8 degrees Fahrenheit.

Her withdrawal only seemed to worsen, with additional medications given over the next two hours: hydromorphone 10 mg, diazepam 10 mg IVP, hydromorphone 10 mg IVP again, diazepam 10 mg IVP again, hydromorphone 6 mg IVP, diazepam 10 mg IVP, all before being placed on dexmedetomidine, then fentanyl and finally midazolam infusions. Dexmedetomidine infusion began with escalating titration leading to ceiling dose (1.5 mcg/kg/hour) within 90 minutes after onset. Due to lack of response (patient was wide awake), she was also started on a fentanyl and finally midazolam infusions at within two hours after reaching maximal dexmedetomidine dose. Her COWS at that point had improved but was still markedly elevated at 27. She was also administered 2x 0.3mg/24 hour clonidine transdermal patches, an additional 2000 mL of IVF (1000 mL of 0.9% normal saline, 1000 mL of lactated ringer's solution) and admitted to the medical intensive care unit (MICU).

Of note, her diagnostic evaluation revealed normal electrolytes with a serum bicarbonate of 18 and an anion gap of 23, normal hepatic function tests, and a white blood cell count of 32,600 with a 94% neutrophilic predominance as well as a thrombocytosis to 654,000 with a normal hemoglobin/hematocrit (12.3/36.9). Toxicology testing was done in two fashions: urine antigen testing was positive for fentanyl, benzodiazepines, and opiates. Additionally, LCMS/MS testing detected medetomidine metabolites in her urine (obtained from a sample following provision of hydromorphone and diazepam, but before dexmedetomidine and fentanyl). A chest radiograph showed no evidence of pneumonia, pneumothorax or mediastinal abnormalities and urine/blood cultures were negative on gram stain and final analysis. Leukocytosis improved to 23,700 the following day and 10,000 by hospital day four, with thrombocytosis improving, but not resolved (459,000) by hospital day eight.

During her ED care she received, over six hours, a total of 58 mg of IVP hydromorphone, 50 mg of IVP diazepam, 10 mg of ketamine IVP and rapidly titrated infusions of dexmedetomidine, fentanyl (switched to hydromorphone after one hour) and midazolam. Her vital signs remained markedly hypertensive and tachycardic, but she never required intubation despite being on maximally dosed infusions of dexmedetomidine, fentanyl and midazolam. All infusions were weaned down over the subsequent 72 hours while oral medications (buprenorphine, clonidine, gabapentin, hydroxyzine)

were titrated up. See Figure 1 for an account of her withdrawal medication requirements and COWS trend.

After the infusions were discontinued, she worked with the addiction team to find a safe disposition, to a sober living house. She was discharged on hospital day 11, with prescriptions for buprenorphine, tizanidine as well as a clonidine taper. She suffered no adverse events and never required respiratory support despite being on maximal doses of three parenteral infusions.

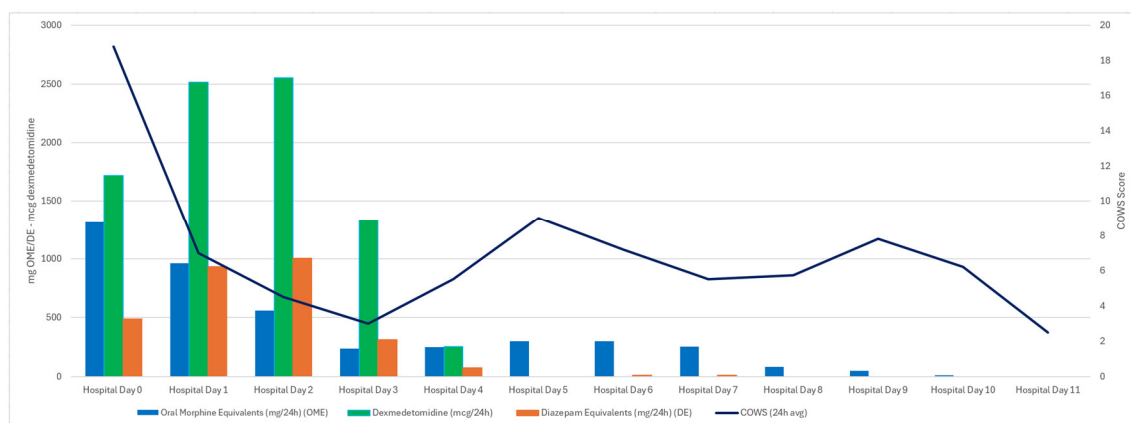


Figure 1. Withdrawal Medication Provision (opioids, dexmedetomidine and benzodiazepines) and COWS trend for Case One.

3.2. Case Two

A 44 year old female who was brought to the ED by ambulance for altered mental status with concern for substance use/intoxication. Paramedics noted she was alert but disoriented on initial evaluation. Her triage vital signs showed moderate hypertension but were otherwise stable (oral temperature 97.3 degrees Fahrenheit, HR 70, BP 142/102, RR 14, SPO2 98% on room air).

She quickly became markedly hypertensive (231/138) and tachycardic (166). Her mental status also worsened; she developed increasing agitation despite multiple doses of IV hydromorphone (total ED dose = 10 mg), droperidol (5 mg), diphenhydramine (50 mg), midazolam (10 mg), and ketamine (360 mg). A COWS score of 33 was recorded approximately four hours after initial presentation. Urine drug antigen screening was positive for fentanyl, cocaine, benzodiazepines, and amphetamines (the sample was obtained before provision of medications).

A dexmedetomidine infusion was started to treat suspected α_2 agonist withdrawal. Despite maximal dosing of dexmedetomidine as well as additional 6 mg doses of IV hydromorphone (12 mg total over 3 hours), the patient remained agitated with severe vital sign abnormalities. The decision was then made to intubate the patient for airway protection, and to allow for more even more aggressive medical intervention. Intravenous propofol and fentanyl infusions were added at that time, which were also soon brought to maximal parameters. The patient was subsequently admitted to the medical intensive care unit (MICU).

Approximately one hour following intubation, with three active infusions, she remained awake, pulling at tubes and lines. Per the admission history, "... pt was intubated [and placed] on max dose of fentanyl, [dexmedetomidine], and propofol. [Alert and] still moving all extremities unpurposefully." A midazolam infusion was added to the patient's regimen at this time, which reached as high as 10 mg/hour.

The addiction service was consulted the following morning. They were able to locate and contact the shelter at which the patient had been staying; staff there were able to identify the patient and provide additional history. It was determined the patient had an opioid use disorder history, with the patient reportedly injecting use of up to 3-4 bundles (45-60 bags) per day of fentanyl/ α_2 agonists. She was also frequent user of stimulants (cocaine and methamphetamine), with a past, but inactive history of alcohol use.

At the time of initial addiction evaluation, her medication regimen had stabilized on the four infusion regimen. Enteral medications were added via orogastric tube, including standing clonidine (0.3 mg orally (per oris, PO) every 8 hours, tizanidine (6 mg PO every 8 hours), oxycodone 20 mg PO every 4 hours and diazepam 10 mg PO every 8 hours were added to some effect. A buprenorphine micro-induction was also ordered to assist with weaning the full opioid agonists being used (fentanyl and oxycodone), starting at 150 mcg every 12 hours, though she received only four doses total.

Early on hospital day two, the patient was again noted to have episodes of severe agitation. A third 0.3 mg clonidine patch was added, and infusions were titrated back up to maximal parameters. She made repeated requests for extubation despite her condition being documented as critical and developing fever (102.7 degrees F) and a productive cough.

Later in the afternoon of hospital day two, the patient self-extubated while on maximal doses of dexmedetomidine and fentanyl infusions. Despite her treatment regimen, she was described by the MICU team as awake and alert, and shortly after requested to be discharged from the hospital. After extensive discussion with the patient about risks and benefits of discharge vs continued hospitalization, the patient was found to have medical decision making capacity and left the hospital that evening.

3.3. Case Three

A 40 year old male was brought by ambulance to the ED from a municipal bus with reports of vomiting, tremor, and concern for opioid and α_2 agonist withdrawal. Initially he was not able to provide further history other than to say he did not remember when he last used. Initial vital signs showed BP 213/99, RR 24, HR 97, temperature 97.2 degrees Fahrenheit and SPO2 of 98% on room air. His initial COWS was documented at 24. Initial withdrawal treatment included 4 mg of IVP hydromorphone, 10 mg of IVP ketamine, olanzapine 10 mg ODT, ondansetron 4 mg IVP and the application of a 0.3 mg clonidine transdermal patch. An hour later, the patient was noted to have a COWS score of 29. His BP (215/144) and HR worsened, the latter, first to 170, then consistently between 180-200, with a maximum of 217. It was documented as a regular, narrow complex tachycardia. Electrical cardioversion was attempted after the patient had no response to additional doses of hydromorphone (12 mg total), midazolam (10 mg total) and IV fluid (2L of ringer's lactate) in the next two hours, but patient remained severely tachycardic. During the ED stay, the patient received 20 mg of hydromorphone, 15 mg midazolam, and eventually, a dexmedetomidine infusion, reaching maximal dose within 3 hours.

Propofol, midazolam and fentanyl infusions were ordered, and quickly titrated to maximum. The sum total of these interventions brought patient's HR to 120-130s and their BP to 140/104 mmHg. He was then intubated for refractory encephalopathy and airway protection and was admitted to the MICU. The patient self-extubated on hospital day two, despite being on maximally dosed infusions of dexmedetomidine, propofol, midazolam, and fentanyl. After re-intubation, patient was slowly weaned from all sedation. See Figure 2 for medication and COWS trending.

His hospital course was complicated by upper gastrointestinal bleeding (thought related to critical illness) and bilateral pneumonia. After final extubation on hospital day number six, the patient completed his micro-induction of buprenorphine and began conventional dosing. He was maintained on both clonidine orally and transdermally, and oral diltiazem was added to treat a persistent atrial tachycardia. He was connected with social services for shelter placement and follow up with our ambulatory addiction medicine team to help continue his medical and substance recovery.

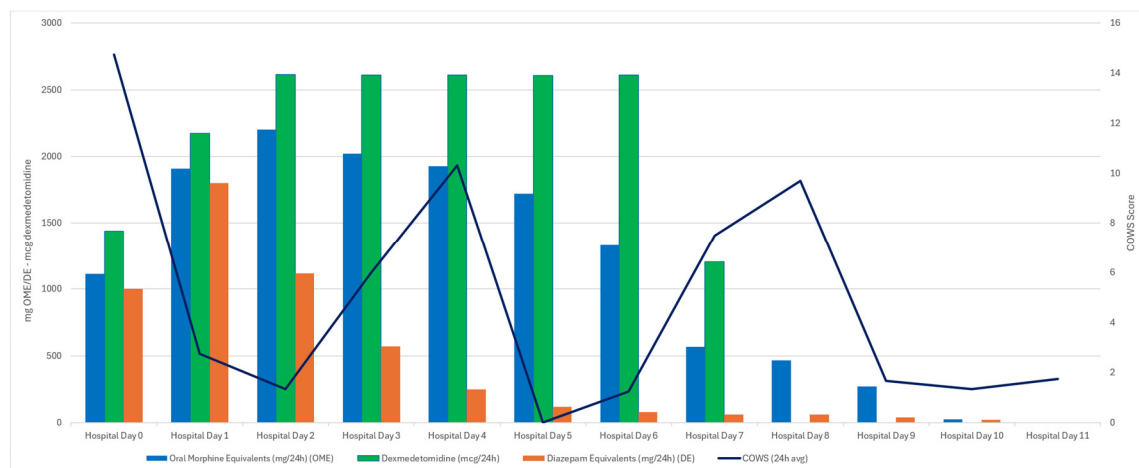


Figure 2. Withdrawal Medication Provision (opioids, dexmedetomidine and benzodiazepines) and COWS trend for Case Three.

3.4. Case Four

A 32 year old male with a past medical history of opioid use disorder (16 bags/day via insufflation), prior alcohol use disorder, nicotine dependence and reported schizoaffective disorder presented to the ED complaining of severe withdrawal symptoms: nausea, vomiting, tremors and uncontrolled anxiety. He reportedly last used 4 hours prior to arrival and he denied using other substances intentionally. Two months prior to this presentation, the patient was treated in a separate hospital for hypertensive urgency, hypokalemia, and complicated withdrawal and requiring MICU level of care and was treated with a dexmedetomidine infusion.

His triage vital signs were temperature of 97.5 degrees Fahrenheit, HR 86, RR 18, SPO2 98% on room air, and BP 121/79. His urine drug screen was positive for fentanyl and methadone (though methadone was given prior to sample collection). Initial COWS was seven then progressed to 15 within 90 minutes. The patient was given Ketamine 50 mg IVP, hydromorphone 4 mg IVP and methadone PO 30 mg to address withdrawal. Despite these medications, the patient's COWS increased to 22 within an hour. The patient continued to exhibit restlessness, agitation, vomiting, piloerection, diaphoresis, and vital abnormalities. Repeat vitals indicated a HR of 113 and BP of 165/71. The patient again received 4 mg IVP of hydromorphone along with 1 mg IVP of lorazepam in response.

Dexmedetomidine IV infusion was started and additional hydromorphone 4 mg IVP doses were provided (receiving a total of 12 mg in 3 hours) without improvement in symptoms. He was admitted to the MICU for further intervention and management. Unfortunately, his withdrawal worsened with his COWS peaking at 27, with a HR 123 and BP 173/94 on maximally dosed dexmedetomidine. During hospital day zero, the patient would receive a total of 62 mg of IV hydromorphone, 0.9 mg of clonidine transdermal (3 patches), 5 mg of IVP lorazepam and 10 mg of IVPB methadone on top of the 30 mg he received orally. His dexmedetomidine infusion remained at maximal dosage.

On hospital day one, due to vomiting, the patient was unable to tolerate oral medications and was treated exclusively with IV infusions of fentanyl, dexmedetomidine and midazolam. Despite these medications reaching maximal dosages, the patient's lowest COWS was ten. The remained alert and throughout the day and the patient's level of alertness range from being alert and calm to mildly drowsy except for sleeping hours.

The patient requested to be weaned off all substances on hospital day two (including methadone and buprenorphine). He was able to be weaned off dexmedetomidine entirely by the morning of hospital day three, while tolerating 0.3 mg every 4 hour PO doses of clonidine, tizanidine 4 mg PO every 8 hour doses, 0.9 mg of transdermal clonidine patches and methadone PO 60 mg.

Later on hospital day 3, the patient requested to be discharged. He was offered referral to an inpatient drug and alcohol rehabilitation facility or to have an intake scheduled with an outpatient methadone clinic, but declined. At the time of the discussion, patient's COWS was reported at ten.

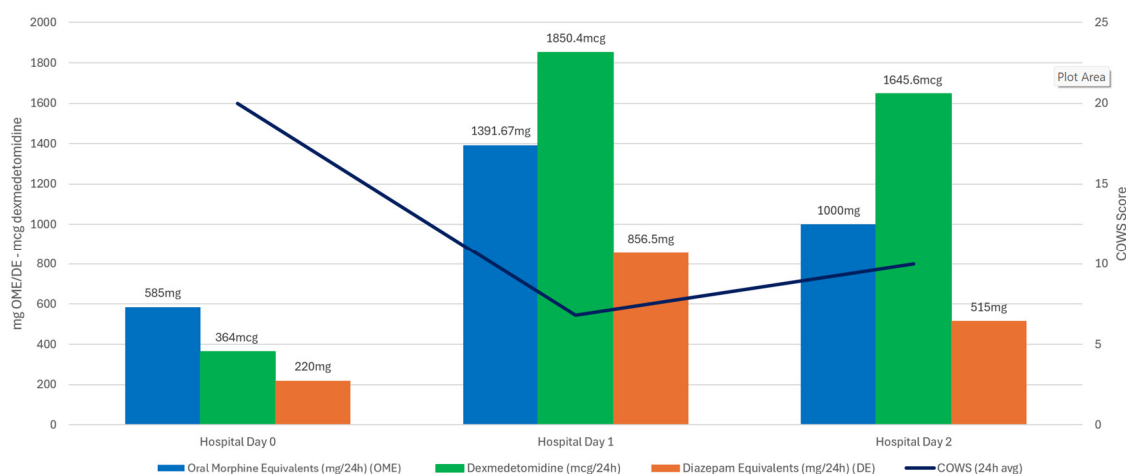


Figure 3. Withdrawal Medication Provision (opioids, dexmedetomidine and benzodiazepines) and COWS trend for Case Four.

4. Discussion

4.1. Summary

The patients described above exemplify the most severe features of suspected medetomidine withdrawal syndrome. Despite receiving timely, high-dose treatment for opioid and α_2 agonist treatment when identified, the patients suffered persistent or worsening withdrawal symptoms with uncontrolled autonomic dysfunction. Such extreme tachycardia and hypertension, accompanied by tremors, anxiety, and protracted vomiting, often refractory to even multiple sedative agents, are not seen in uncomplicated opioid withdrawal [5,6,9].

4.2. Introduction to Narrative Review

Managing this syndrome requires a fundamentally different approach and intensity of care than ordinary opioid withdrawal. Our patients' deterioration prompted early transfer to intensive care and initiation of a dexmedetomidine infusion, alongside opioid and other sedative infusions, to achieve symptom control. In a larger cohort of patients with suspected medetomidine withdrawal, over 90% of patients needed ICU care and almost a quarter required mechanical ventilation [5]. Notably, dexmedetomidine proved to be a cornerstone of therapy – as it directly replaces the missing α_2 agonists, allowing gradual down-titration and mitigation of withdrawal, until patients are able to tolerate oral intake and can be switched to clonidine, tizanidine or another oral α_2 agonists. Of note, there is a paucity of literature to support many of these treatments given the novelty of this exposure and condition in human history. As such, the literature cited are association and correlation, hypothesis generating, and by no means are any of these concepts rigorously studied.

4.3. Pharmacology and Comparison to Xylazine

Medetomidine is a racemic mixture of dexmedetomidine and levomedetomidine, used in veterinary medicine for its safe therapeutic window and potent sedative and analgesic properties. Dexmedetomidine, the more pharmacologically active enantiomer, is FDA-approved for human use and widely administered for procedural and ICU sedation [15,16]. Its sedative effects are primarily mediated in the pons (locus coeruleus), where activation of presynaptic α_2 -adrenergic receptors

inhibits adenylate cyclase via G-protein coupling [17]. This leads to decreased release of norepinephrine, disinhibiting GABAergic neurons in the thalamus, creating sedation.

Analgesia is mediated at both spinal and supratentorial levels. In the dorsal horn of the spinal cord, dexmedetomidine inhibits the pre-synaptic release of substance P and glutamate. Concurrently, it activates postsynaptic α_2 receptors, thereby decreasing excitability and pain transmission [18]. Dexmedetomidine's high $\alpha_2:\alpha_1$ selectivity ratio (~1600:1) underlies its targeted pharmacologic profile, providing effective sedation and analgesia with reduced risk of α_1 -mediated side effects or significant respiratory compromise [19].

At higher doses, medetomidine can suppress atrioventricular (AV) nodal conduction, increasing the risk of significant bradycardia and conduction delays, particular those with underlying heart conditions or on other AV nodal blocking therapies [20]. Intramuscular administration results in rapid absorption, with peak plasma concentrations occurring within 10 to 30 minutes [21]. IV administration of dexmedetomidine and medetomidine have similar onset, duration, and half-lives between two and three hours [22,23].

Medetomidine is at least two hundred times more potent than xylazine, its veterinary predecessor in the street drug supply [7,8,24,25]. Medetomidine is also more lipophilic and exhibits a longer duration of action. Medetomidine metabolism is primarily in the liver, and has an elimination half-life of approximately 1.6 hours, and produces sedation lasting 2 to 3 hours, which may be potentiated with co-administered opioids [26]. This synergism is thought to contribute to its growing presence as an adulterant in illicit fentanyl, potentially enhancing or extending the experience for users.

Xylazine withdrawal and treatment are more widely described than medetomidine and include use of short acting opioids, replacement α_2 agonists with clonidine, tizanidine and guanfacine and other adjunctive medications [4,27–29]. While some have recommended benzodiazepines and other sedatives for the treatment of this condition [30] we generally discourage this practice due to the risk of dependence and respiratory depression.

4.4. Dexmedetomidine Withdrawal Syndrome

Dexmedetomidine withdrawal syndrome is increasingly recognized in critically ill adults following prolonged or high-dose infusions. Characteristic symptoms include agitation, anxiety, rebound hypertension, and tachycardia, typically emerging within hours of abrupt discontinuation, particularly after infusions exceeding 48 hours [31,32]. This phenomenon was first described in two ICU patients, with symptoms developing 4–6 hours post-infusion and resolving after α_2 agonist re-initiation [29]. Others have similarly reported withdrawal-related sympathetic hyperactivity, including that rebound hypertension is common and a potentially severe manifestation [32–35]. This includes the possibility of development of acute delirium, or posterior reversible encephalopathy syndrome (PRES), due to the uncontrolled hypertension. [36]

Abrupt cessation can also lead to increased pain sensitivity, possibly due to the loss of dexmedetomidine's modulatory effects on central arousal pathways [35]. In a pilot study, scheduled clonidine tapers significantly reduced withdrawal incidence and severity in ICU patients [37]. A larger review confirmed these findings and advocates for proactive planning in cases involving long-term dexmedetomidine use [38].

Although these data reflect medically and surgically ill patients in the ICU setting, these findings remain relevant for managing medetomidine withdrawal, where abrupt cessation may mirror infusion discontinuation without tapering. Understanding the physiologic consequences of withdrawal from potent α_2 -agonists underscores the need for carefully titrated substitution strategies.

4.5. Timeline and Epidemiology

While medetomidine has circulated in veterinary practice since the 1990s, its appearance in the illicit opioid supply appears to be a recent phenomenon. Laboratory surveillance first detected it in

North American drug samples in 2022–2023, with a sharp rise beginning in 2024. In Philadelphia, medetomidine prevalence increased from 29% to 87% of opioid-positive samples between May and November 2024, eventually reaching 72% of all tested opioid samples by late 2024 [6,39]. A separate series of atypically intoxicated individuals from Pennsylvania was also published in early 2025 [40]. This coincided with the Pennsylvania state scheduling of xylazine, suggesting a substitution effect by drug suppliers.

Additional outbreaks have been documented elsewhere in the U.S. A May 2024 cluster in Chicago identified 12 patients with medetomidine-associated overdose, including multiple cases of bradycardia, altered mental status, and minimal naloxone response [41]. In Pittsburgh, a cohort of 23 patients presented with severe, refractory withdrawal symptoms in late 2024, prompting toxicological confirmation of medetomidine exposure via LC-MS/MS testing [42]. Lastly, a larger cohort was recently published that demonstrated symptoms correlated to concentration of urine medetomidine metabolites, but not xylazine metabolites [43].

4.6. Concepts in Clinical Management

No published treatment protocol exists for medetomidine withdrawal. A few papers have included treatment guidance, which involves co-treatment of opioid withdrawal and α_2 agonist withdrawal [5,9,44,45] using large amounts of oral and IV α_2 agonists. A separate website, maintained by members of the University of Pennsylvania, is dedicated to up to date expert guidance on management of medetomidine withdrawal [46]. Below are a series of novel concepts that either relate to treatments provided in the above cases or are avenues for future research.

While not well described in the literature, the hallmark symptoms: vomiting and sympathetic dysregulation are frightening both in their severity and in the rapidity of their onset [45]. Individuals who have been monitored for intoxication or for other complaints seem to go from benign appearance to life threatening presentations within hours and sometimes as few as 1-2 hours. Focusing on early perturbations in vital signs (such as new tachycardia or hypertension) before other physical signs develop has been postulated as warning signs. Given the difficulty of controlling symptoms following the onset of vomiting, we and other experts recommend early use of oral and IV treatments before severe symptoms develop, as they often are easier to prevent than control.

While xylazine withdrawal has been shown to be controllable with less potent α_2 agonists like tizanidine and guanfacine [4], medetomidine has seemingly mandated the use of the most potent commonly available oral α_2 agonist, clonidine. Given the huge volumes individuals are using, supratherapeutic doses of clonidine are also being used, with individuals in severe withdrawal sometimes requiring 0.6 – 0.9 mg doses of clonidine every 1-2 hours until symptoms are controlled. Future studies should assess use of these dosages to assess safety and therapeutic ceiling.

In the present series, clonidine was administered at doses exceeding the package-insert-listed maximum effective daily dose for any FDA-approved indication. This approach was necessitated by the severity of the clinical presentation, which reflects a novel toxicologic emergency rather than the chronic disease states for which clonidine is typically prescribed. Standard labeling is based on conventional pharmacokinetic parameters derived from populations with stable physiology and modest sympathetic overactivity. In contrast, our patients presented with extreme withdrawal-related sympathetic hyperactivation in the setting of prolonged, high-dose exposure to potent α_2 agonists. The resulting toxidrome required rapid, high-intensity pharmacologic intervention to restore physiologic stability.

Under such conditions, reliance on conventional pharmacokinetic data, optimized for steady-state therapeutic use, is inappropriate. The magnitude of receptor dysregulation and neuroendocrine activation in these cases suggests that the clinical requirement for α_2 agonist activity far exceeds that predicted by standard dosing algorithms. Limiting treatment to FDA-approved doses and indications risks underdosing, prolonged morbidity, and potentially, life-threatening complications. In these scenarios, the toxicologic framework of toxicokinetics and toxicodynamics, rather than traditional pharmacokinetics, provides a more relevant basis for dose selection and therapeutic monitoring. This

approach acknowledges that the pathophysiologic driver is a self-sustaining toxic state, where the “toxin” is the abrupt absence of high potency α_2 agonist stimulation.

Given the novelty of this presentation, further studies are warranted to characterize the direct toxicodynamic and kinetic effects of high potency α_2 agonists such as medetomidine when used at doses markedly exceeding their maximum therapeutic amounts. Such research would inform rational withdrawal strategies, guide safe upper dosing limits of medications like clonidine and dexmedetomidine, and refine treatment protocols for future patients encountering this emerging toxidrome.

4.7. Combination α_2 Agonist Therapy

Emerging evidence supports the synergistic use of combined α_2 -adrenergic agonists to achieve enhanced therapeutic efficacy, potentially minimizing adverse effects and dosages [9,47–49]. Fairbanks et al. demonstrated clear synergy between clonidine and dexmedetomidine, reporting significantly greater antinociceptive effects in combination compared to either drug alone, attributable to separate activation of α_2A - and α_2C -adrenoceptor subtypes [47]. Similarly, combined clonidine and tizanidine [9], despite limited direct clinical evidence, share overlapping analgesic mechanisms by inhibiting spinal substance P release, a critical mediator of nociceptive transmission [50]. Co-administration of these α_2 -agonists allows clinicians to optimize treatment efficacy while reducing dose-dependent side effects and allowing safer titration to solely oral medications [48–50]. This synergistic approach is particularly valuable in clinical contexts where maximal drug dosing is reached, or limited due to tolerability concerns, offering practical advantages in managing complex withdrawal syndromes involving potent α_2 -agonists like medetomidine.

4.8. Low Dose Dexmedetomidine Infusion Outside the ICU

Dexmedetomidine infusions, typically administered in intensive care units (ICUs), are emerging as a feasible option for use at lower doses (typically up to 0.7 mcg/kg/hour) in non-ICU settings, such as progressive care units or step-down floors. Literature exploring adjunctive use of dexmedetomidine in other sedative withdrawal supports its safe and effective administration outside the ICU, demonstrating minimal adverse safety events and improved patient management compared to standard therapies alone [51]. Similarly, critical care nursing associations are starting to highlight successful experiences with dexmedetomidine in non-ICU settings, citing controlled sedation and reduced agitation without respiratory depression or significant cardiovascular instability [52]. Another study discussed use of low dose dexmedetomidine for as an adjunct to a multi-modal regimen for those with significant opioid tolerance [53]. As such, low dose dexmedetomidine infusion represents an emerging therapeutic modality for safely transitioning stable patients from intensive care or supporting individuals who cannot tolerate oral α_2 agonists (e.g., clonidine or tizanidine) but do not require intensive care level management. While the existing literature supporting low dose dexmedetomidine for individuals suffering from suspected medetomidine withdrawal is meager, a small case series was recently presented, demonstrating safety of this intervention [54]. Additional studies should assess the safety and efficacy profile of low dose dexmedetomidine outside the ICU setting for suspected α_2 agonist withdrawal.

4.9. High Dose Dexmedetomidine

Mounting clinical experience supports IV dexmedetomidine as a core intervention for managing refractory withdrawal syndromes due to α_2 -agonist adulterants like medetomidine. Although standard package dexmedetomidine dosing ranges from 0.2–1.5 mcg/kg/hour [55], clinical reports suggest higher doses, up to 2.5 mcg/kg/hour, may be required to adequately control severe agitation and autonomic instability [56–59]. Importantly, the pharmacokinetic work shared by Iirola et al. demonstrate evidence of linear human metabolism at doses up to 2.5 mcg/kg/hour [58]. Clinically, these higher doses are frequently administered concurrently with opioids (e.g., fentanyl,

hydromorphone), allowing eventual step-down to oral medications as withdrawal symptoms subside. Future research should assess whether a higher ceiling doses of dexmedetomidine could prevent the need for, or lower the doses of, concurrent infusion sedative/analgesic agents and safety outcomes in larger cohorts.

4.10. Transdermal Clonidine

Transdermal clonidine patches offer continuous α_2 -adrenergic agonist delivery, effectively mitigating withdrawal symptoms in settings where oral medications are not tolerated due to severe vomiting or altered mental status. The caveat to this is that delayed duration of action, often requiring 18-24 hours after placement to see evidence of therapeutic effect [60]. This approach has been successfully employed as a bridging strategy for patients transitioning from ICU-level sedation with dexmedetomidine, as well as in outpatient opioid withdrawal management [61–63]. Literature demonstrates that clonidine patches reduce withdrawal severity by providing sustained sympatholytic activity without significant adverse effects, such as severe hypotension or bradycardia [61,62]. In clinical scenarios of other α_2 agonist withdrawal, the clonidine patch has been effectively used to prevent rebound sympathetic hyperactivity, facilitating smoother transitions to oral medications or discontinuation altogether [63–65].

4.11. Public Health Implications and Future Directions

The rapid rise of medetomidine as a fentanyl adulterant, and the severity of the withdrawal it induces, represents a significant public health challenge. Traditional opioid withdrawal algorithms, even those adapted for xylazine, are insufficient in this context. Regional protocols in Philadelphia have already been updated to include earlier addiction and ICU consultation, higher opioid dosing, combination oral and transdermal α_2 agonist therapy, and routine use of dexmedetomidine infusions for refractory withdrawal.

Testing for medetomidine is limited to specialized LC-MS/MS platforms [5,40,43,45], which may delay confirmation. Still, clinicians encountering withdrawal syndromes with extreme sympathetic features (e.g., unexplained hypertension, HR >180, persistent vomiting, altered mental status) should consider medetomidine exposure and escalate care accordingly. Physicians and public health advocates strongly recommend increasing funding and innovation in the fields of testing and treatment for this condition [66].

4.12. Limitations

There are several important limitations to this study. First, toxicologic confirmation of medetomidine exposure was only performed in one of the four patients due to collection and operational constraints. While the patients all admitted use of illicit opioids in temporal relationship to widespread adulteration of the drug supply [6] and they also all were coincident to another larger case series, with a 100% positivity rate of those tested for suspected medetomidine exposure [43], their conditions cannot be conclusively linked to medetomidine. Secondly, it is virtually impossible to separate the treatment of opioid and suspected α_2 agonist withdrawal, and efforts to focus withdrawal strategies on specific conditions will be limited. While a receptor based withdrawal approach is indicated, future research should attempt to develop assessment systems to adapt to these novel and constantly changing withdrawal syndromes.

6. Conclusion

Severe medetomidine withdrawal presents with often refractory sympathetic activity and can require the use of seemingly heroic doses and combinations of medical treatments to control, with variable success. Potential treatment options include replacement of α_2 agonists, combination α_2 agonists, high and low dose dexmedetomidine and transdermal therapies. These are often required across a continuum of care spaces, including the ICU, and require careful titration to assure symptom

control and safe use. Future studies are required to assess viability of novel treatment options and public health leaders should maintain vigilance surrounding adulteration of illicit drug supplies.

Author Contributions: K.S.L., P.D., J.K, and D.G. methodology; E.P., M.M., O.V., K.G., G.F., D.L., C.M., K.C., S.P., P.D., J.K., D.G., J.R., K.S.L. investigation; K.S.L.,D.L., D.G, J.R. writing—original draft preparation; K.S.L., J.K., P.D. writing—review and editing, D.G.; T.W.S. supervision; All authors have read and agreed to the published version of the manuscript.

Funding: This research received no external funding.

Institutional Review Board Statement: The study was also approved by the hospital institutional review board (IRB# 1685), with a waiver of informed consent, as it involved analysis of de-identified clinical data and leftover biological specimens.

Informed Consent Statement: Patient informed consent was waived due to the retrospective nature of the study and pooled, deidentified results.

Data Availability Statement: The data presented in this study are available on request from the corresponding author due to it relating to specific patients.

Acknowledgments: The authors would like to acknowledge the tireless work of the whole Jefferson Addiction Multidisciplinary Service (JAMS), including the certified recovery specialists, social workers and administrative/clerical staff that make our engines run. We would also like to acknowledge our colleagues from the Philadelphia Department of Public Health (Daniel (Danny) Teixeira da Silva, Shelby Kehoe), as well as the Health Federation of Philadelphia (Catherine Abrams, Caroline Drob) who have done so much to centralize and bring our hospitals together. Lastly we would like to acknowledge our colleagues from the University of Pennsylvania and Temple University, too many to list, but Drs. Jeanmarie Perrone, Margaret Lowenstein, Ashish Thakrar; Brendan Hart, Lauren Murphy, Sam Stern and so many others.

Conflicts of Interest: The authors declare no conflicts of interest.

Abbreviations

The following abbreviations are used in this manuscript:

Abbreviation	Full Term
AV	Atrioventricular
BP	Blood Pressure
CARE	CAse REport guidelines
CNS	Central Nervous System
COWS	Clinical Opiate Withdrawal Scale
ECG	Electrocardiogram
ED	Emergency Department
GABA	Gamma-Aminobutyric Acid
HR	Heart Rate
IV	Intravenous
IVF	Intravenous Fluid
IVP	Intravenous Push
LC-MS/MS	Liquid Chromatography–Tandem Mass Spectrometry
MICU	Medical Intensive Care Unit
ODT	Oral Dissolving Tablet
PO	Per Os (by mouth/orally)
QTc	Corrected QT Interval
SANRA	Scale for the Assessment of Narrative Review Articles
$\alpha 2$	Alpha-2 (adrenergic receptor)

References

1. Quijano T, Crowell J, Eggert K, Clark K, Alexander M, Grau L, Heimer R. Xylazine in the drug supply: emerging threats and lessons learned in areas with high levels of adulteration. *Int. J. Drug Policy* 2023, 120, 104154. <https://doi.org/10.1016/j.drugpo.2023.104154>

2. Reed MK, Esteves Camacho T, Olson R, Grover Z, Rapoza T, Larson MJ. Xylazine's impacts on the community in Philadelphia: perspectives of people who use opioids and harm reduction workers. *Subst. Use Misuse* 2024, 60(1), 100–107. <https://doi.org/10.1080/10826084.2024.2409720>
3. Alexander R, Agwuncha C, Wilson C, Schrecker J, Holt A, Heltsley R. Withdrawal signs and symptoms among patients positive for fentanyl with and without xylazine. *J. Addict. Med.* 2025, 19, 202–207. <https://doi.org/10.1097/ADM.0000000000001423>
4. London K, Li Y, Kahoud JL, Cho D, Mulholland J, Roque S, Slovis B. Tranq dope: characterization of an ED cohort treated with a novel opioid withdrawal protocol in the era of fentanyl/xylazine. *Am. J. Emerg. Med.* 2024, 85, 130–139. <https://doi.org/10.1016/j.ajem.2024.08.036>
5. Huo S, London K, Murphy L, et al. Notes from the Field: Suspected Medetomidine Withdrawal Syndrome among Fentanyl-Exposed Patients—Philadelphia, Pennsylvania, September 2024–January 2025. *MMWR Morb. Mortal. Wkly. Rep.* 2025, 74(15), 266–268. <https://doi.org/10.15585/mmwr.mm7415a2>
6. Philadelphia Department of Public Health. Health Alert: Medetomidine as an emerging adulterant in the illicit drug supply—December 10, 2024. Available online: <https://hip.phila.gov/document/4874/PDPH-HAN-00444A-12-10-2024.pdf> (accessed on 30 July 2025)
7. Bryant CE, England GCW, Clarke KW. A comparison of the sedative effects of medetomidine and xylazine in the horse. *J. Vet. Anaesth.* 1991, 18, 55–57. [https://doi.org/10.1016/S0375-8427\(07\)80114-8](https://doi.org/10.1016/S0375-8427(07)80114-8)
8. Tyner CL, Woody BJ, Reid JS, Chafetz EP, Lederer HA, Norton JF, Jöchle W. Multicenter clinical comparison of sedative and analgesic effects of medetomidine and xylazine in dogs. *J. Am. Vet. Med. Assoc.* 1997, 211, 1413–1417. <https://doi.org/10.2460/javma.1997.211.1413>
9. London KS, Durney P, Warrick-Stone T, Alexander K, Kahoud JL. Decreased effectiveness of a novel opioid withdrawal protocol following the emergence of medetomidine as a fentanyl adulterant. *Biomedicine* 2025, 5(2), 13. <https://doi.org/10.3390/biomed5020013>
10. Wesson DR, Ling W. The clinical opiate withdrawal scale (COWS). *J. Psychoact. Drugs* 2003, 35, 253–259. <https://doi.org/10.1080/02791072.2003.10400007>
11. Ashton, C.H. Benzodiazepines: How They Work and How to Withdraw (The Ashton Manual); Institute of Neuroscience, Newcastle University: Newcastle upon Tyne, UK, 2002.
12. McPherson, M.L.; American Society of Health-System Pharmacists, Eds. Demystifying Opioid Conversion Calculations: A Guide for Effective Dosing, 2nd ed.; American Society of Health-System Pharmacists: Bethesda, MD, USA, 2018.
13. Gagnier JJ, Kienle G, Altman DG, et al. The CARE guidelines: consensus-based clinical case reporting guideline development. *J. Clin. Epidemiol.* 2014, 67(1), 46–51. <https://doi.org/10.1016/j.jclinepi.2013.08.003>
14. Baethge C, Goldbeck-Wood S, Mertens S. SANRA—a scale for the quality assessment of narrative review articles. *Res. Integr. Peer Rev.* 2019, 4, 5. <https://doi.org/10.1186/s41073-019-0064-8>
15. Keating GM. Dexmedetomidine: a review of its use for sedation in the intensive care setting. *Drugs* 2015, 75(10), 1119–1130. <https://doi.org/10.1007/s40265-015-0419-5>
16. Shukry M, Miller JA. Update on dexmedetomidine: use in nonintubated patients requiring sedation for surgical procedures. *Ther. Clin. Risk Manag.* 2010, 6, 111–121. <https://doi.org/10.2147/TCRM.S5374>
17. Maze M, Tranquilli W. Alpha-2 adrenoceptor agonists: defining the role in clinical anesthesia. *Anesthesiology* 1991, 74(3), 581–605. <https://doi.org/10.1097/00000542-199103000-00029>
18. Gertler R, Brown HC, Mitchell DH, Silvius EN. Dexmedetomidine: a novel sedative-analgesic agent. *Proc. (Baylor Univ. Med. Cent.)* 2001, 14(1), 13–21. <https://doi.org/10.1080/08998280.2001.11927725>
19. Karol MD, Maze M. Pharmacokinetics and interaction pharmacodynamics of dexmedetomidine in humans. *Best Pract. Res. Clin. Anaesthesiol.* 2000, 14(2), 261–269. <https://doi.org/10.1053/bean.2000.0081>
20. Ingersoll-Weng E, Manecke Jr GR, Thistlethwaite PA. Dexmedetomidine and cardiac arrest. *Anesthesiology* 2004, 100(3), 738–739. <https://doi.org/10.1097/00000542-200403000-00040>
21. Scheinin H, Karhuvaara S, Olkkola KT, Kallio A, Anttila M, Vuorilehto L, Scheinin M. Pharmacodynamics and pharmacokinetics of intramuscular dexmedetomidine. *Clin. Pharmacol. Ther.* 1992, 52(5), 537–546. <https://doi.org/10.1038/clpt.1992.182>

22. Kallio A, Salonen M, Forssell H, Scheinin H, Scheinin M, Tuominen J. Medetomidine premedication in dental surgery: a double-blind cross-over study with a new alpha 2-adrenoceptor agonist. *Acta Anaesthesiol. Scand.* 1990, 34(3), 171–175. <https://doi.org/10.1111/j.1399-6576.1990.tb03015.x>
23. Li A, Yuen VM, Goulay-Dufay S, Kwok PC. Pharmacokinetics and pharmacodynamics of dexmedetomidine. *Drug Dev. Ind. Pharm.* 2016, 42(12), 1917–1927. <https://doi.org/10.1080/03639045.2016.1183210>
24. Virtanen R, Savola JM, Saano V, Nyman L. Characterization of the selectivity, specificity and potency of medetomidine as an α_2 -adrenoceptor agonist. *Eur. J. Pharmacol.* 1988, 150, 9–14. [https://doi.org/10.1016/0014-2999\(88\)90744-3](https://doi.org/10.1016/0014-2999(88)90744-3)
25. Yaygingül R, Belge A. The comparison of clinical and cardiopulmonary effects of xylazine, medetomidine and detomidine in dogs. *Ankara Univ. Vet. Fak. Derg.* 2018, 65, 313–322. <https://doi.org/10.33988/auvfd.377331>
26. Maurer PM, Bartkowski RR. Drug interactions of clinical significance with opioid analgesics. *Drug Saf.* 1993, 8(1), 30–48. <https://doi.org/10.2165/00002018-199308010-00004>
27. Srivastava AB, Mariani JJ, Levin FR. New directions in the treatment of opioid withdrawal. *Lancet* 2020, 395(10241), 1938–1948. [https://doi.org/10.1016/S0140-6736\(20\)30357-1](https://doi.org/10.1016/S0140-6736(20)30357-1)
28. Rudolf G, Walsh J, Plawman A, Gianutsos P, Alto W, Mancl L, Rudolf V. A novel non-opioid protocol for medically supervised opioid withdrawal and transition to antagonist treatment. *Am. J. Drug Alcohol Abuse* 2018, 44(3), 302–309. <https://doi.org/10.1080/00952990.2017.1395495>
29. Ehrman-Dupre R, Kaigh C, Salzman M, Haroz R, Peterson LK, Schmidt R. Management of xylazine withdrawal in a hospitalized patient: a case report. *J. Addict. Med.* 2022, 16(6), 595–598. <https://doi.org/10.1097/ADM.0000000000000896>
30. Ayub S, Parnia S, Poddar K, Bachu AK, Sullivan A, Khan AM, Ahmed S, Jain L. Xylazine in the opioid epidemic: a systematic review of case reports and clinical implications. *Cureus* 2023, 15(3), e36864. <https://doi.org/10.7759/cureus.36864>
31. Kukoyi AT, Coker SA, Lewis LD, Nierenberg DW. Two cases of acute dexmedetomidine withdrawal syndrome following prolonged infusion in the intensive care unit: report of cases and review of the literature. *Hum. Exp. Toxicol.* 2013, 32(1), 107–110. <https://doi.org/10.1177/0960327112459375>
32. Pathan S, Kaplan JB, Adamczyk K, et al. Evaluation of dexmedetomidine withdrawal in critically ill adults. *J. Crit. Care* 2021, 62, 19–24. <https://doi.org/10.1016/j.jcrc.2020.11.008>
33. Bouajram RH, Bhatt K, Croci R, Baumgartner L, Puntillo K, Ramsay J, Thompson A. Incidence of dexmedetomidine withdrawal in adult critically ill patients: a pilot study. *Crit. Care Explor.* 2019, 1(1), e0035. <https://doi.org/10.1097/CCE.0000000000000355>
34. Flieller LA, Alaniz C, Pleva MR, Miller JT. Incidence of rebound hypertension after discontinuation of dexmedetomidine. *Pharmacotherapy* 2019, 39(10), 970–974. <https://doi.org/10.1002/phar.2318>
35. Ferguson L, Hooper S. Dexmedetomidine withdrawal syndrome and opioid sensitivity. *BMJ Support. Palliat. Care* 2023, 13(Suppl 1), e105–e107. <https://doi.org/10.1136/spcare-2020-002375>
36. Pillai S, Hoehn K, Brouillette G. Posterior Reversible Encephalopathy Syndrome as a Result of Withdrawal from Prolonged Dexmedetomidine. *Journal of Pediatric Intensive Care.* 2015;04(03):162-165. doi:<https://doi.org/10.1055/s-0035-1559822>
37. Bhatt K, Quan AT, Baumgartner L, et al. Effects of a clonidine taper on dexmedetomidine use and withdrawal in adult critically ill patients—a pilot study. *Crit. Care Explor.* 2020, 2(11), e0245. <https://doi.org/10.1097/CCE.0000000000000245>
38. Kim CS, McLaughlin KC, Romero N, Crowley KE. Evaluation of dexmedetomidine withdrawal and management after prolonged infusion. *Clin. Ther.* 2024, 46(12), 1034–1040. <https://doi.org/10.1016/j.clinthera.2024.04.015>
39. Philadelphia Department of Public Health, Division of Substance Use Prevention and Harm Reduction. Health Alert: In Philadelphia, medetomidine, a potent non-opioid veterinary sedative, has been detected in the illicit drug supply [Health Alert PDPH-HAN-0441A]. Philadelphia Department of Public Health; 13 May 2024. Available online: <https://hip.phila.gov/document/4421/PDPH-HAN-0441A-05-13-24.pdf> (accessed on 30 July 2025)

40. Murphy L, Krotulski A, Hart B, Wong M, Overton R, McKeever R. Clinical characteristics of patients exposed to medetomidine in the illicit opioid drug supply in Philadelphia: a case series. *Clin. Toxicol.* 2025, 63, 438–441. <https://doi.org/10.1080/15563650.2025.2500601>
41. Nham A, Le JN, Thomas SA, Gressick K, Ussery EN, Ko JY, Gladden RM, Mikosz CA, Schier JG, Vivolo-Kantor A, et al. Overdoses involving medetomidine mixed with opioids—Chicago, Illinois, May 2024. *MMWR Morb. Mortal. Wkly. Rep.* 2025, 74(15), 258–265. <https://doi.org/10.15585/mmwr.mm7415a1>
42. Ostrowski SJ, Tamama K, Trautman WJ, Stratton DL, Lynch MJ. Notes from the Field: Severe Medetomidine Withdrawal Syndrome in Patients Using Illegally Manufactured Opioids — Pittsburgh, Pennsylvania, October 2024–March 2025. *MMWR Morb. Mortal. Wkly. Rep.* 2025, 74(15), 269–271. <https://doi.org/10.15585/mmwr.mm7415a3>
43. Durney P, Kahoud JL, Warrick-Stone T, Montesi M, Carter M, Butt S, Mencia AM, Omoregie L, Shah M, Bloomfield M, et al. Biochemical identification and clinical description of medetomidine exposure in people who use fentanyl in Philadelphia, PA. *Int. J. Mol. Sci.* 2025, 26(14), 6715. <https://doi.org/10.3390/ijms26146715>
44. Johnson RJ, Casey ER, Zwiebel SJ. Diagnosis and management of medetomidine withdrawal: clinical implications of the shifting illicit opioid landscape. *J. Acad. Consult. Liaison Psychiatry* 2025, published online. <https://doi.org/10.1016/j.jaclp.2025.06.005>
45. London KS, Huo S, Murphy L, Warrick-Stone T, Goodstein D, Montesi M, Carter M, Butt S, Alexander K, Satz W, Tasillo A, Xu L, Arora M, Casey E, McKeever R, Lowenstein M, Durney P, Hart B, Perrone J. Severe fentanyl withdrawal associated with medetomidine adulteration: a multicenter study from Philadelphia, PA. *J. Addict. Med.* 2025, 00(00), 1–7. <https://doi.org/10.1097/ADM.0000000000001560>
46. Pennsylvania Coordinated Medication-Assisted Treatment Program (PENNCAMP). Medetomidine. Published 2024. Available online: <https://penncamp.org/medetomidine/> (accessed on 29 July 2025)
47. Fairbanks CA, Kitto KF, Nguyen HO, Stone LS, Wilcox GL. Clonidine and dexmedetomidine produce antinociceptive synergy in mouse spinal cord. *Anesthesiology* 2009, 110(3), 638–647. <https://doi.org/10.1097/ALN.0b013e318195b51d>
48. Stone LS, Fairbanks CA, Wilcox GL. α_2 receptors and agonists in pain management. *Curr. Opin. Anaesthesiol.* 2001, 14(5), 527–533. <https://doi.org/10.1097/00001503-200110000-00009>
49. Chan AKM, Cheung CW, Chong YK. Alpha-2 agonists in acute pain management. *Expert Opin. Pharmacother.* 2010, 11(17), 2849–2868. <https://doi.org/10.1517/14656566.2010.511613>
50. Ono H, Mishima A, Ono S, Fukuda H, Vasko MR. Inhibitory effects of clonidine and tizanidine on release of substance P from slices of rat spinal cord and antagonism by α adrenergic receptor antagonists. *Neuropharmacology* 1991, 30(6), 585–589. [https://doi.org/10.1016/0028-3908\(91\)90077-O](https://doi.org/10.1016/0028-3908(91)90077-O)
51. Wong A, Smithburger PL, Kane-Gill SL. Review of adjunctive dexmedetomidine in the management of severe acute alcohol withdrawal syndrome. *Am. J. Drug Alcohol Abuse* 2015, 41(5), 382–391. <https://doi.org/10.3109/00952990.2015.1046392>
52. American Association of Critical Care Nurses (AACN). Dexmedetomidine (Precedex) in the Progressive Care Unit. Available online: <https://www.aacn.org/education/ce-activities/nti23330/dexmedetomidine-precedex-in-the-progressive-care-unit> (accessed on 29 July 2025)
53. Patch RK, Eldrige JS, Moeschler SM, Pingree MJ. Dexmedetomidine as part of a multimodal analgesic treatment regimen for opioid induced hyperalgesia in a patient with significant opioid tolerance. *Case Rep. Anesthesiol.* 2017, 2017, 9876306. <https://doi.org/10.1155/2017/9876306>
54. Durney P, Carter M, London K, Goodstein DC, Montesi M, Butt S, Warrick-Stone T, Fiore J. Low-Dose Dexmedetomidine: Repurposing an Intravenous Agent for Opioid & Alpha-2 Withdrawal. Abstract presented at: American Society of Addiction Medicine (ASAM) Annual Conference; April 24–27, 2025; Denver, CO.
55. Dexmedetomidine Hydrochloride Injection [package insert]. Hospira, Inc; revised 2021 (21 038/S 017). Available online: https://www.accessdata.fda.gov/drugsatfda_docs/label/2021/206628s017lbl.pdf (accessed on 29 July 2025)

56. Rodriguez K, Anderson RL, Keriazes G, Meyers B. A Retrospective Review of High versus Standard Dose Dexmedetomidine for Sedation in Critically Ill Patients. *Journal of Intensive and Critical Care*. 2016;02(02). <https://doi.org/10.21767/2471-8505.100025>
57. Bajwa BS, Satpal. Role of dexmedetomidine in anesthesia and critical care. *Journal of Evolution of Medical and Dental Sciences*. 2014;3(43):10711-10722. Accessed September 27, 2025. DOI: <https://doi.org/10.14260/jemds/2014/3396>
58. Iirola T, Aantaa R, Laitio R, Kentala E, Lahtinen M, Wighton A, Garratt C, Ahtola-Sätälä T, Olkkola KT. Pharmacokinetics of prolonged infusion of high-dose dexmedetomidine in critically ill patients. *Crit. Care* 2011, 15(5), R257. <https://doi.org/10.1186/cc10441>
59. Voscopoulos C, Kirk FL, Lovrinkevich M, Lema M. The use of “high dose” dexmedetomidine in a patient with critical tracheal stenosis and anterior mediastinal mass. *Open Anesth. J.* 2011, 5(1), 42. <https://doi.org/10.2174/1874321801105010042>
60. Selvam RP, Singh AK, Sivakumar T. Transdermal drug delivery systems for antihypertensive drugs—a review. *Int. J. Pharm. Biomed. Res.* 2010, 1(1), 1–8. <https://doi.org/10.22270/ijpbr.v1i1.179>
61. Glaess SS, Attridge RL, Gutierrez GC. Clonidine as a strategy for discontinuing dexmedetomidine sedation in critically ill patients: a narrative review. *Am. J. Health Syst. Pharm.* 2020, 77(7), 515–522. <https://doi.org/10.1093/ajhp/zxaa040>
62. Lardieri AB, Fusco NM, Simone S, et al. Effects of clonidine on withdrawal from long-term dexmedetomidine in the pediatric patient. *J. Pediatr. Pharmacol. Ther.* 2015, 20(1), 45–53. <https://doi.org/10.5863/1551-6776-20.1.45>
63. Spencer L, Gregory M. Clonidine transdermal patches for use in outpatient opiate withdrawal. *J. Subst. Abuse Treat.* 1989, 6(2), 113–117. [https://doi.org/10.1016/0740-5472\(89\)90030-0](https://doi.org/10.1016/0740-5472(89)90030-0)
64. Sica DA, Grubbs R. Transdermal clonidine: therapeutic considerations. *J. Clin. Hypertens.* 2005, 7(9), 558–562. <https://doi.org/10.1111/j.1524-6175.2005.05226.x>
65. Deutsch AB, Hartman CF, Flaherty CP, et al. Novel use of clonidine patch to treat tizanidine withdrawal. *Cureus* 2024, 16(2), e54831. <https://doi.org/10.7759/cureus.54831>
66. Sood N. Rise of illicit medetomidine use: a worrisome trend. *Am. J. Addict.* 2025, [online ahead of print]. <https://doi.org/10.1111/ajad.70030>

Disclaimer/Publisher’s Note: The statements, opinions and data contained in all publications are solely those of the individual author(s) and contributor(s) and not of MDPI and/or the editor(s). MDPI and/or the editor(s) disclaim responsibility for any injury to people or property resulting from any ideas, methods, instructions or products referred to in the content.