Preprints.org

Article

Not peer-reviewed version

Arthur Keith Was the First to Describe What Is Now Known as Koch's Triangle: The Building of the Triangular Locus of the Atrioventricular Node from Todaro to Tandler

Marcos C De Almeida *

Posted Date: 10 September 2025

doi: 10.20944/preprints202506.2135.v2

Keywords: Atrioventricular node; Koch's triangle; Atrioventricular conduction system; Triangular locus of atrioventricular node; Triangle of atrioventricular node; Heart anatomy; arthur Keith

Preprints.org is a free multidisciplinary platform providing preprint service that is dedicated to making early versions of research outputs permanently available and citable. Preprints posted at Preprints.org appear in Web of Science, Crossref, Google Scholar, Scilit, Europe PMC.

Copyright: This open access article is published under a Creative Commons CC BY 4.0 license, which permit the free download, distribution, and reuse, provided that the author and preprint are cited in any reuse.

Preprints.org (www.preprints.org) | NOT PEER-REVIEWED | Posted: 10 September 2025 doi:10.20944/preprints202506.2135.v2

Disclaimer/Publisher's Note: The statements, opinions, and data contained in all publications are solely those of the individual author(s) and contributor(s) and not of MDPI and/or the editor(s). MDPI and/or the editor(s) disclaim responsibility for any injury to people or property resulting from any ideas, methods, instructions, or products referred to in the content.

Article

Arthur Keith Was the First to Describe What is Now Known as Koch's Triangle: The Building of the Triangular Locus of the Atrioventricular Node from Todaro to Tandler

Running title: Triangular locus

Marcos C De Almeida

Department of Genetics and Morphology, Brasilia's University, Campus Asa Norte, Cep:70910-900. Brasilia, Brazil; mca.brsl@gmail.com; Tel: +55(61)981340964

Abstract

Purpose: To show the developments that culminated with the eponym Koch's triangle -- the fibrous attachment of septal tricuspid leaflet, aperture of the coronary sinus and the tendon linking the inferior vena cava valve to the central fibrous body- and how it was a construct of several anatomists. Methods: The literature is reviewed centering in the discovery of the atrioventricular node by Sunao Tawara (January 1906), its previous announcement by Tawara's mentor Ludwig Aschoff (1905) as well as in the contributions of the authors that described the other components of the triangular locus. Results :Tawara described the atrioventricular node and its relations with fibrous attachment of septal tricuspid leaflet and ostium of the coronary sinus. The first description assembling all components was due to Arthur Keith (March1906). Keith was also the first to consider the triangular locus as useful landmark for identifying the atrial structures of the conduction system discovered by Tawara and Wilhelm His Jr (1893). Conclusion: The triangular locus of the atrioventricular node was a construct of several exceptional anatomists: The contributions of keith in this topic has been particularly overlooked. The triangular locus of atrioventricular node or triangle of atrioventricular node are more instructive and impartial names.

Keywords: atrioventricular node; Koch's triangle; atrioventricular conduction system; triangular locus of atrioventricular node; triangle of atrioventricular node; heart anatomy .Arthur Keith

Introduction

What is known today as Koch's triangle (the triangle of the atrioventricular node) is delimited by the fibrous attachment of septal tricuspid leaflet, aperture of the coronary sinus and the tendon linking the inferior vena cava valve (Eustachian) and central fibrous body [1]. It was a construct

[1] **J Tandler, Anatomie Des Herzens, 1st ed. (Jena: Gustav Fischer, 1913); Walter Koch, "Weiter Mitteilungen Über Den Sinusknoten Des Herzens," . . Verh Deutscth Ges Pathol 13 (1909): 85–92; Thomas N. James, "The Tendons of Todaro and the 'Triangle of Koch': Lessons from Eponymous Hagiolatry," Journal of Cardiovascular Electrophysiology 10, no. 11 (1999): 1478–96, https://doi.org/10.1111/j.1540-8167.1999.tb00207.x; D Drenckham, Benninghoff Anatomie, ed. D Drenckham, 16th ed. (München: Urban and Fischer. Elsevier, 2004); S Stranding, Gray`s Anatomy, ed. S Stranding, 41st ed. (Elsevier, 2016); Arthur Keith, "The Auriculo Ventricular Bundle of His," The Lancet 167, no. 4305 (1906): 623–25.**

© 2025 by the author(s). Distributed under a Creative Commons CC BY license.

Preprints.org (www.preprints.org) | NOT PEER-REVIEWED | Posted: 10 September 2025 doi:10.20944/preprints202506.2135.v2

developed by exceptional anatomists. They were Francesco Todaro (February 14 th, 1839 in Tripi ,Messina ; October 22 nd, 1918 Rome) , Sunao Tawara (July 5th, 1873 Nakajima, in Aki - Ōita; January 19th,, 1952 Nakatsu) , Ludwig Aschoff (January 10 th , 1866 in Berlin; 24. June 1942 in Freiburg ,Breisgau), Arthur Keith (February 5th, 1866 in Old Machar, Aberdeenshire ;January 7th, 1955 Downe, Kent) and Carl Eduard Walter Koch (3rd. Mai 1880 in Dortmund; 21th November 1962 in Gretesch bei Osnabrück) . Julius Tandler (February 16 1869 in Iglau/Mähren; August 25 1936 in Moscow) gave the name" Dreieck", (triangle), focusing on Koch's contributions [2]. Selected refences on the biographies of these scientists are: Francesco Todaro [3], Ludwig Aschoff [4], Sunao Tawara [5], Arthur Keith [6], Walter Koch [7], J Tandler [8].

It is shown how the contributions of all these authors progressed to this important macro and microscopic concept, the locus of atrioventricular node, and why Koch's triangle is not a fair eponym and should be replaced by a more informative and unbiased term: atrioventricular node triangle or triangular locus of the atrioventricular node. Previously, the late Thomas James [9] have criticized the soundness of this eponym and ,controversially, the utility of the concept [10]. The utility of the concept, the locus of atrioventricular node, since then has been

---

[2] Tandler, Anatomie Des Herzens.

[3] Alessandro Ottaviani, "Francesco Todaro," in Dizionario Biografico Degli Italiani (Istituto della Enciclopedia Italiana fondata da Giovanni Treccani S.p.A, 2019), https://www.treccani.it/enciclopedia/francesco-todaro_(Dizionario-Biografico)/.

[4] **W B Fye, "Ludwig Aschoff.," Clinical Cardiology 22, no. 8 (August 1999): 545–46, https://doi.org/10.1002/clc.4960220812.**

[5] **K Suma, "Sunao Tawara: A Father of Modern Cardiology.," Pacing and Clinical Electrophysiology : PACE 24, no. 1 (January 2001): 88–96, http://www.ncbi.nlm.nih.gov/pubmed/11227976; M.C. De Almeida et al., "The Ox Atrioventricular Conduction Axis Compared to Human in Relation to the Original Investigation of Sunao Tawara," Clinical Anatomy 33, no. 3 (2020), https://doi.org/10.1002/ca.23524; Marcos C. De Almeida, "Heinrich Ewald Hering's Discovery of the Heart Pacemaker: Hering, Tawara and Aschoff's Search for Its Morphological Basis, the Sinoatrial Node, and Why They Failed," Anatomical Science International 98 (2023): 482–492.**

[6] **WCLG Clark, "Arthur Keith 1866-1955," Biographical Memoirs of the Fellows of the Royal Society 1 (1955): 144–51; A Keith, "The Sino-Auricular Node: A Historical Note," Heart 4, no. 3 (1942): 77–79, https://doi.org/10.1136/HRT.4.3.77.**

[7] **James, "The Tendons of Todaro and the 'Triangle of Koch': Lessons from Eponymous Hagiolatry"; Andrea A Conti, "Calling the Heart by Name: Distinguished Eponyms in the History of Cardiac Anatomy.," The Heart Surgery Forum 14, no. 3 (June 2011): E183-7, https://doi.org/10.1532/HSF98.20101047.**

[8] **Robert A Kyle and Marc A Shampo, "Professor Julius Tandler, Anatomist and Public Health Advocate," Mayo Clinic Proceedings 65, no. 4 (1990): 530, https://doi.org/https://doi.org/10.1016/S0025-6196(12)60953-7.**

[9] Giulia Ottaviani, "Dr. Thomas N. James, MD, MACP (1925-2010): In Memoriam.," The American Journal of Cardiology (United States, July 2011), https://doi.org/10.1016/j.amjcard.2011.04.001.

[10] James, "The Tendons of Todaro and the 'Triangle of Koch': Lessons from Eponymous Hagiolatry."

© 2025 by the author(s). Distributed under a Creative Commons CC BY license.

Preprints.org (www.preprints.org) | NOT PEER-REVIEWED | Posted: 10 September 2025 doi:10.20944/preprints202506.2135.v2

largely confirmed [11]. However, the criticisms of Thomas James about the soundness of the eponym, although right, lacks a clear temporal description of the events culminating in the concept and has two important gaps: the contributions of Tawara, not only based in his thesis [12], and of Arthur Keith. In particular, the contributions of Arthur Keith on this topic , so far as I know have not been considered except by a brief mention given in a recent paper [13].

Methods

The literature is reviewed centering in the discovery of the atrioventricular node by Sunao Tawara [14], its previous announcement by Tawara's mentor Ludwig Aschoff [15] and the contributions of the authors that described for the first time the other components of the triangular locus

Results and Discussion

The Announcement of the Knoten (Node) and Its Place.

In a congress of the German physiological society held in Marburg, 14-16 June of 1905 the Knoten (node) was announced for the first time as a structure confined in the atrial portion of the atrio ventricular bundle [16] . Ludwig Aschoff , Tawara's mentor and then head of the anatomic pathological institute at Marburg, Germany, gave a succinct but clear summary of Tarawa's, in course, investigation and presented microscopic preparations produced by Tawara [17]. A significant excerpt from Aschoff's seminar is selected:

Atrial fibers first appear as a closed bundle at the coronary sinus. They then run anteriorly along the atrial septum to the area of the insertion of the medial tricuspid leaflet, where they form a tangled network and then, together with the plexus from which the fibers of the ventricular segment arise, form the so-called node. This lies as a flat, ridged structure in the fibrous septum between the

---

[11] **Shumpei Mori et al., "Clinical Structural Anatomy of the Inferior Pyramidal Space Reconstructed from the Living Heart: Three-Dimensional Visualization Using Multidetector-Row Computed Tomography," Clinical Anatomy (John Wiley and Sons Inc., October 1, 2015), https://doi.org/10.1002/ca.22483.**

[12] **S Tawara, The Conduction System of the Mammalian Heart: An Anatomico-Histological Study of the Atrioventricular Bundle and the Purkinje Fibers., ed. K Suma and M Shimada, Imperial Collage Press, 1st Englis (London: Imperial College Press, 2000); S Tawara, Das Reizleitungssystem Des Säugetierherzens. Eine Anatomisch-Histologische Studie Über Das Atrioventrikularbündel Und Die Purkinjeschen Fäden (Jena: Gustav Fischer, 1906).**

[13] De Almeida, "Heinrich Ewald Hering's Discovery of the Heart Pacemaker: Hering, Tawara and Aschoff's Search for Its Morphological Basis, the Sinoatrial Node, and Why They Failed."

[14] **S Tawara, "Die Topographie Und Histologie Der Brückenfasern.," Zentrallblatt Fur Physiologie 19, no. 3 (1906): 70–76; Tawara, Das Reizleitungssystem Des Säugetierherzens. Eine Anatomisch-Histologische Studie Über Das Atrioventrikularbündel Und Die Purkinjeschen Fäden.**

[15] **L Aschoff, "Ueber Die Untersuchungen Des Herrn Dr. Tawara, Die Bruckenfasern Betreffend Und Demonstration Der Zugehorigen Mikroskopischen Praparate.," Muenchener Medizinische Wochenscrift 52, no. 2 (1905): 674.**

[16] Aschoff.

[17] Aschoff.

© 2025 by the author(s). Distributed under a Creative Commons CC BY license.

Preprints.org (www.preprints.org) | NOT PEER-REVIEWED | Posted: 10 September 2025 doi:10.20944/preprints202506.2135.v2

tricuspid and mitral insertions, and from it the ventricular fibers pass anteriorly through the fibrous septum in an easily traceable bundle to the ventricular septum[18].

This communication was published in September 26th in the Muenchener Medizinische wochenscrift (Munich Medical Weekly) (Aschoff 1905). Tawara himself had produced an account of his almost finished doctoral thesis : "Die topographie und histologie der brückenfasern " (The topography and histology of the bridge fibers) received by the Zentrallblatt fur Physiologie (key papers in Physiology) in April 17th 1905 and published at the end of January 1906 [19] . That was not a brief communication but a full seven pages paper without illustrations. Tawara anticipated much of the material that would be further developed in his 1906 monography [20], which has now an English translation [21]. Tawara stressed in that paper:

So far, I have only been able to identify one center that has been precisely characterized histologically, and which, in my opinion, has its center in a mesh-like node in the atrial septum, directly above the atrioventricular fibrous septum. From this node, a fiber bundle runs backward, often to the anterior border of the coronary sinus, and a second fiber bundle runs anteriorly downward through the atrioventricular fibrous septum, where it continues with the system of Purkinje fibers ...

Tawara mentioned as well that the system is present in birds besides mammals. He particularly stressed that the atrial node is fully irrigated and defined its microscopic aspects:

These fibers are characterized by various features: ...they are narrower than the remaining fibers of the atrial muscle and are very rich in nuclei and exhibit slight fibrillar differentiation, limited only to the peripheral layer. The protoplasm of these fibers always stains a different color than the other muscle fibers. In their imperfect development, they resemble embryonic muscle fibers, but can already be clearly distinguished from the rest of the muscles in the newborn .

Tawara [22] , on second half of February , also published the histologic analysis of the Hering's (Henrich Ewald Hering (May 3rd, 1866 Vienna; December 16th, 1948 Papenhusen)) material on the bundle transection [23] (Figure 1). In this publication he depicted the position of the node and the bundle. These would be further improved in his monography. Previously, Hering [24] had provided macroscopic photographs illustrating in the real hearts where the bundle should be sectioned to produce atrio- ventricular dissociation (Figure 2)

---

[18] Aschoff.

[19] **S. Tawara, "Die Topographie Und Histologie Der Brückenfasern. Ein Beitrag Zur Lehre von Der Bedeutung Der Purkinjeschen Fäden.," Zentrallblatt Fur Physiologie 19, no. 3 (1906): 70–76.**

[20] Tawara, Das Reizleitungssystem Des Säugetierherzens. Eine Anatomisch-Histologische Studie Über Das Atrioventrikularbündel Und Die Purkinjeschen Fäden.

[21] Tawara, The Conduction System of the Mammalian Heart: An Anatomico-Histological Study of the Atrioventricular Bundle and the Purkinje Fibers.

[22] S Tawara, "Anatomisch-Histologische Nachpriifung Der Schnittfuhrung an Den von Prof. H.E. Hering Ubersandten Hundeherzen.," Zentrallblatt Fur Physiologie 111 (1906): :300-302.

[23] **H E Hering, "Nachweis, Dass Das His'sche Uebergangsbündel Vorhof Und Kammer Des Säugethierherzens Functionell Verbindet - Zweite Mittheilung," Pflüger, Archiv Für Die Gesammte Physiologie Des Menschen Und Der Thiere 108, no. 6–7 (1905): 267–80, https://doi.org/10.1007/BF01678340; Tawara, "Anatomisch-Histologische Nachpriifung Der Schnittfuhrung an Den von Prof. H.E. Hering Ubersandten Hundeherzen."**

[24] Hering, "Nachweis, Dass Das His'sche Uebergangsbündel Vorhof Und Kammer Des Säugethierherzens Functionell Verbindet - Zweite Mittheilung."

© 2025 by the author(s). Distributed under a Creative Commons CC BY license.

Preprints.org (www.preprints.org) | NOT PEER-REVIEWED | Posted: 10 September 2025 doi:10.20944/preprints202506.2135.v2

Fig 1

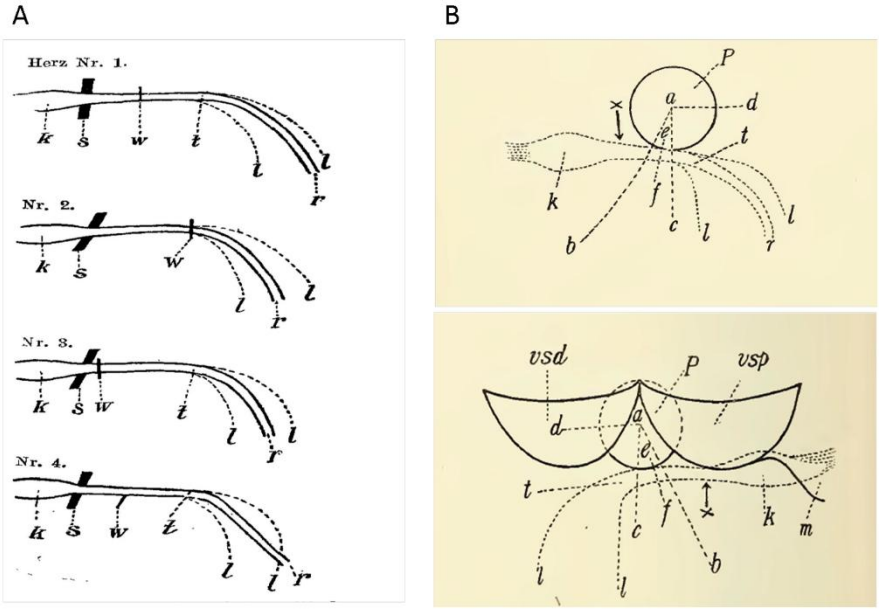

Figure 1. A Representation of the level of experimental transection done by H E Hering in the His bundle of four dog hearts. Published in Tawara, S. 1906a." Anatomisch-Histologische Nachprüfung der Schnittfuhrung an den von Prof. H.E. Hering Ubersandten Hundeherzen. Zentrallblatt für Physiologie 111::300–302 " (Anatomical–histological verification of the incision made by Prof. H.E. Herring on dog hearts". K = atrioventricular node; S = atrioventricular fibrous septum; W = experimental transection; t = bifurcating bundle; right branch (r) and left branch (ll); **B** Didactic representation of human His bundle and important reference points for planning the experimental transection. S Tawara 1906. " Das Reizleitungssystem Des Säugetierherzens. Eine Anatomisch-Histologische Studie Über Das Atrioventrikularbündel Und Die Purkinjeschen Fäden" (The conduction system of the mammalian heart. An anatomical–histological study of the atrioventricular bundle and Purkinje's network) Jena: Gustav Fischer. Right side view = superior drawing. Left side view = inferior drawing; P = membranous septum; t = bifurcating bundle;right branch (r) and left branch l (ll); X = frontier between atrium and ventricle: m = aortic mitral leaflet; ba –ad = septal and superior tricuspid leaflet position; ef = suggested transection line.

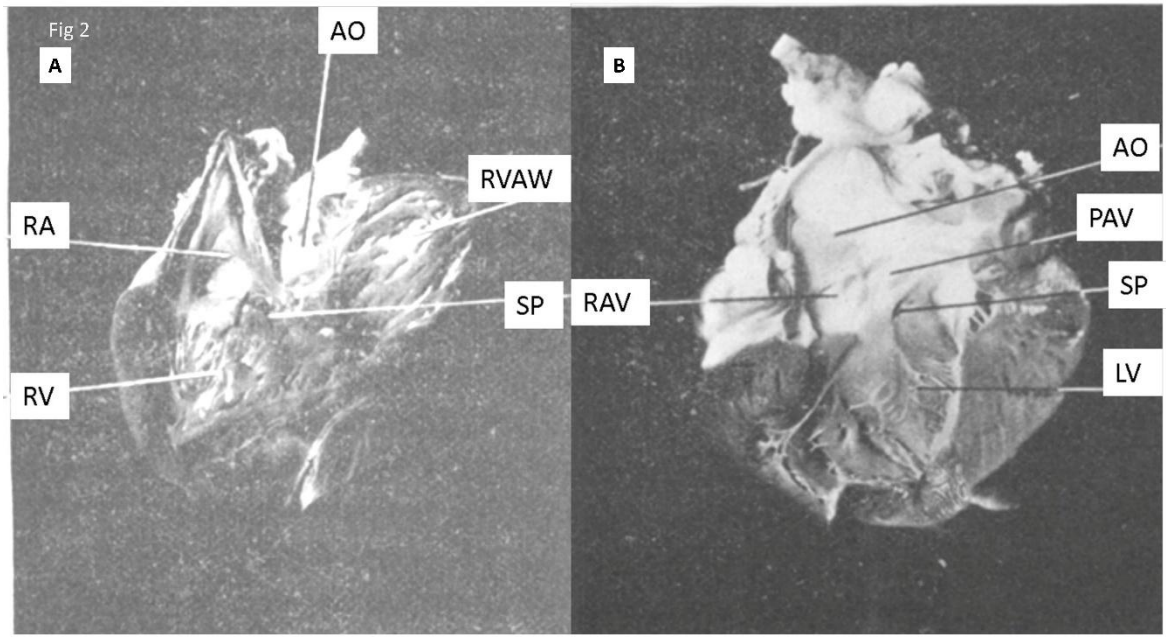

© 2025 by the author(s). Distributed under a Creative Commons CC BY license.

Preprints.org (www.preprints.org) | NOT PEER-REVIEWED | Posted: 10 September 2025 doi:10.20944/preprints202506.2135.v2

Figure 2. Cutting through the transition/crossing bundle in the dog's heart. (First experiment on February 21, 1905.) from H. E. Hering, Hering HE (1905) " Nachweis, dass das His'sche Uebergangsbündel Vorhof und Kammer des Säugethierherzens functionell verbinde"t (Evidence that the His junctional bundle functionally connects the atrium and ventricle of the mammalian heart) - Zweite Mittheilung. Pflüger, Arch für die Gesammte Physiol des Menschen und der Thiere 108:267–280. **A** Right atrium and ventricle opened. AO= aorta; RA= right Atrium; R V= right ventricle; RVAW= right ventricle anterior wall; SP= section point. **B** Left atrium and ventricle opened. AO= aorta; LV= left ventricle; RAV= right aortic valve; PAV= posterior aortic valve; SP= Section point.

The Development of the Concept of a Triangular Locus

James Mackenzie (April 12th, 1853 Pictonhill Scone; January 25th, 1925 London) at Burnley read the Aschoff's report [25] and communicated it to Arthur Keith who was struggling without success to reproduce His junior's [26] (Wilhelm His Jr (December 29th,1863 Basel; November 10th, 1934 Brombach- Lörrach)) and Hering's [27] results on the atrioventricular bundle. Arthur Keith afterwards sent in February 3rd 1906 a letter to The Lancet that was published in March 3rd 1906 [28] . Keith exposed that he was indeed preparing a previous letter to The Lancet denying the existence of the bundle:

There may be an error in my observation or in my technique. I simply draw attention to the fact that I have failed to find a muscular bundle in the position described by His and Hering and that before it is accepted as the anatomical basis of Stokes-Adams disease its constancy must be proved. At least it is well to have the existence of the bundle of His verified at the very commencement, so that it may not have a circulation of two centuries before it is called in as false coin. Some days after writing the part of this letter given above Dr. James Mackenzie sent me a cutting from the Muenchner Medizinische Wochenschrift of Sept. 26th, 1905 p. 1904, in which Dr. L. Aschoff gave an account " Ueber die Untersuchungen des Herrn Dr. Tawara, die Bruckenfasern betreffend und Demonstration der zugehorigen mikroskopischen Praparate" (On the investigations of Dr. Tawara, concerning the bridge fibers and demonstration of the associated microscopic preparations) ….With this account to guide me I renewed my search with success [29] .

It is worthy to recognize that Keith, although reading the description of the node by Aschoff [30] overlooked the description of the "Knoten" in his letter , apparently he was more focused in identify the atrioventricular bridging fibers of the atrioventricular bundle (His bundle). Confirming that he wrote " since it is probable that others may find the initial difficulty I experienced in dealing with this intricate region of the heart I propose to give briefly by the aid of a diagram some of the points which have proved most useful to me"(Figure 3A). This diagram, as mentioned [31], is a

---

[25] Aschoff, "Ueber Die Untersuchungen Des Herrn Dr. Tawara, Die Bruckenfasern Betreffend Und Demonstration Der Zugehorigen Mikroskopischen Praparate."

[26] **Wilhelm His, "The Activity of the Embryonic Human Heart and Its Significance for the Understanding of the Heart Movement in the Adult (English Translation)," Journal of the History of Medicine and Allied Sciences 4, no. 3 (1949): 289–318, https://doi.org/10.1093/jhmas/IV.3.289.**

[27] Hering, "Nachweis, Dass Das His'sche Uebergangsbündel Vorhof Und Kammer Des Säugethierherzens Functionell Verbindet - Zweite Mittheilung."

[28] Keith, "The Auriculo Ventricular Bundle of His."

[29] Keith.

[30] Aschoff, "Ueber Die Untersuchungen Des Herrn Dr. Tawara, Die Bruckenfasern Betreffend Und Demonstration Der Zugehorigen Mikroskopischen Praparate."

[31] De Almeida, "Heinrich Ewald Hering's Discovery of the Heart Pacemaker: Hering, Tawara and Aschoff's Search for Its Morphological Basis, the Sinoatrial Node, and Why They Failed."

© 2025 by the author(s). Distributed under a Creative Commons CC BY license.

Preprints.org (www.preprints.org) | NOT PEER-REVIEWED | Posted: 10 September 2025 doi:10.20944/preprints202506.2135.v2

first description of the landmarks delimiting in the right atrial side a triangular area (red dotted lines in Figure 3) whose components are known today as Koch's triangle. Unfortunately, Keith not portrayed the Knoten (node) described by Aschoff's communication, but only the atrioventricular bundle as described by Aschoff. However, he described the fibrous tendon linking inferior vena cava valve (Eustachian) to central fibrous body as a novelty:" In the musculature beneath the endocardium will be found two fibrous bands (see g, h, in figure) which are of great interest but, so far as I know, have never been described. These bands begins in the membranous space and run through the musculature of the septum to the Eustachian (g) and Thebesian (h)…"[32] . Keith was unaware that Francesco Todaro [33] had described the fibrous structure arising from vena cava inferior valve (Eustachian valve) in 1895 (Figure 4). Todaro's description is more complete than that of Keith:

I immediately noticed that from the right posterior portal/part of the tendinous center, a fibrous ribbon started; and, having followed it, with great care, among the muscular fibers below, I accompanied it up to the posterior pillar of the oval fossa, from where I made sure that it entered through the posterior horn, which originates here, in the Eustachian valve, following it along its entire free margin. I have confirmed this observation later, in many other cases; and I have always found the tendon constant, even when the Eustachian valve is almost deficient [34].

Fig 3

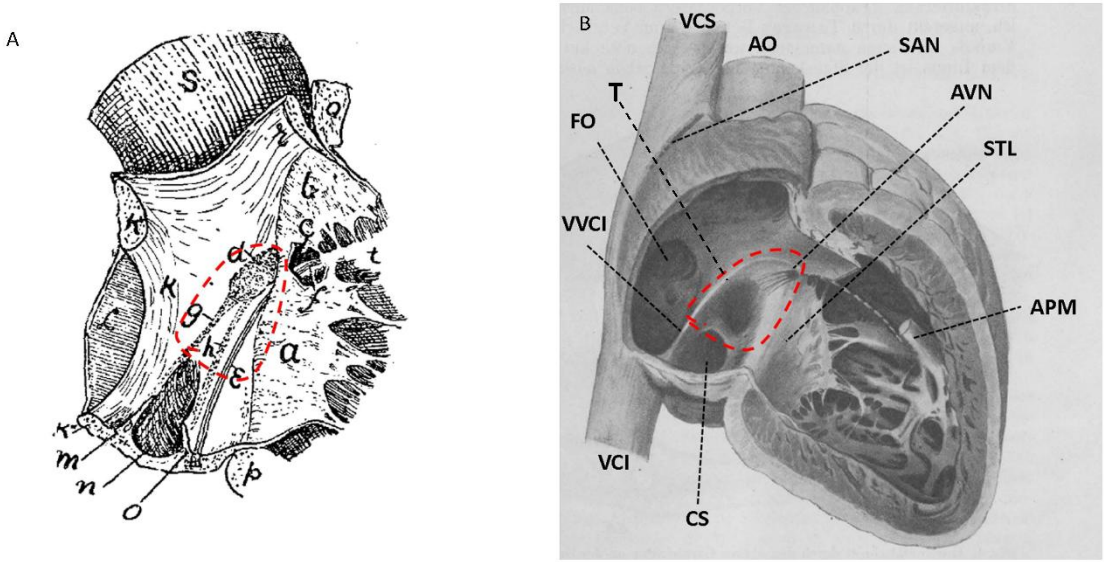

Figure 3. A. Original drawing of Arthur Keith published in Keith A. 1906 modified by the author. The auriculo-ventricular bundle of His. Lancet 167:623–625." He drew it to show the important landmarks to find the His bundle and the atrioventricular node . As far as we know it is the first representation of what is today know as Koch's triangle. The doted red line triangle was provided by the author to emphasize the triangular geometry of the area. The triangle sides are a= attachment of septal cusp of tricuspid leaflet; g= fibrous tendon of Eustachian valve; n= order of coronary sinus ; " a, Septal cusp of tricuspid. b, Infundibular cusp. c, Ventricular part of membranous space. d, Auricular part of membranous space. e, Position of bundle of His in auricle. f, Position of bundle of His in ventricle. g, Fibrous band of Eustachian valve. h, Fibrous band of Thebesian valve. k, Annulus ovalis. l, Septum ovale. m, Eustachian valve. n, Coronary sinus. o, Thebesian valve. p, Base of right ventricle. q, Base of right ventricle (infundibular part). r, Wall of right auricle. s, Aorta. t, Interventricular septum.

[32] Keith, "The Auriculo Ventricular Bundle of His."

[33] Francesco Todaro, Novelle Ricerche Sopra La Struttura Delle Orecchiette Del Cuore Umano e Sopra Ta Valvola Di Eustachio. ., Stabilimento Civelli (Firenze, 1895).

[34] Todaro.

© 2025 by the author(s). Distributed under a Creative Commons CC BY license.

Preprints.org (www.preprints.org) | NOT PEER-REVIEWED | Posted: 10 September 2025 doi:10.20944/preprints202506.2135.v2

B Figure published by W. Koch, Koch W (1909) and modified by the author "Weiter Mitteilungen über den Sinusknoten des Herzens (Further aspects about the sinus node of the heart) . Verh Deutscth Ges Pathol 13:85–92". The identification labels were provided by the author, as well as the dotted red line triangle to emphasize the triangular geometry of the area. The original legend read as : "Schematic drawing of the location of the sinus node (Keith),(black) line at the border between the cava and the auricle , and the atrioventricular node (Tawara),(black) spot above the insertion of the tricuspid septal leaflet. The white line in the atrium demarcates the coronary sinus from the rest of the atrium. (S. Ziegler's Beitr., Vol. XLII, p. 219.)". AO= aorta; APM= anterior papillary muscle: CS= aperture of the coronary sinus; LV= left ventricle; FO= fossa ovalis; SAN=sinoatrial node; ST= septal tricuspid leaflet; VCI= inferior caval vein; VCS= superior caval vein. The whitish tread was posteriorly identified as the Todaro's tendon. The identification labels were provided by the author as well as the dotted red line triangle to emphasize the triangular geometry of the area .

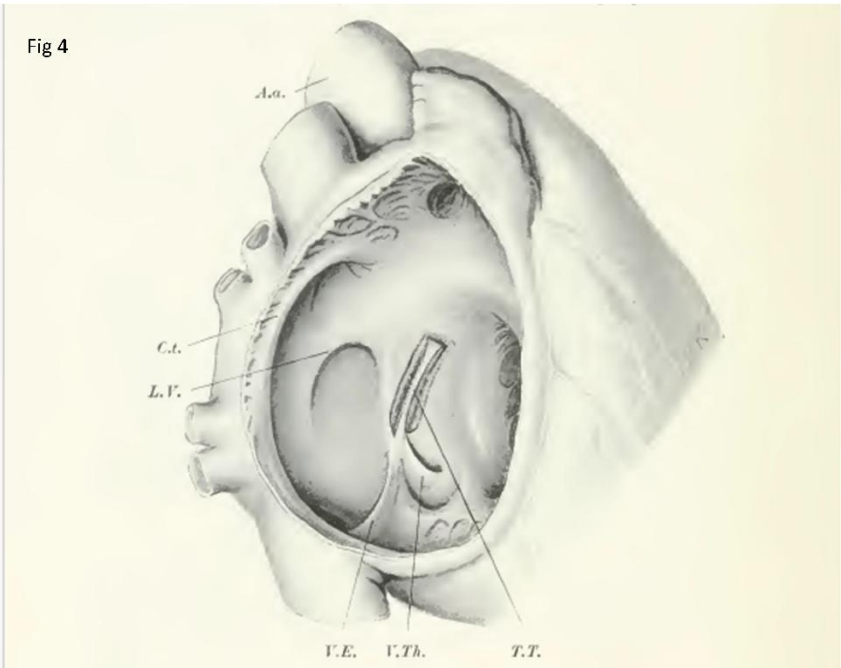

Figure 4. Anterior/lateral wall of right atrium removed showing the fibrous connexon between inferior vena cava valve and central fibrous body (Todaro's tendon). From Tandler Tandler J (1913) "Anatomie Des Herzens" (Anatomia do coração), 1st edn. Gustav Fischer, Jena. Aa= aorta; Ct= terminal crest; LV= limbo of fossa oval (ring of Viussens) Raymond Vieussens (born 1641; Vigan; (16Th ; 1715Montpellier) valve of inferior vena cava; (Eustachian) Bartolomeo Eustachi (San Severino March , 1500-1510; Fossombrone, August 27th 1574) ; VTh= valva do seio coronário (Thebesian) Adam Christian Thebesius (January 1686, in Tschistey, Guhrau, Duchy of Glogau; November 10th, 1732 in Hirschberg, Duchy of Schweidnitz); TT= Tendon of Todaro.

Keith described too the nodal artery: "…large artery (with a caliber of 1 to 1. 5 millimeters) invariably perforates the central fibrous body just behind the bundle ; the artery is always bigger than the muscular bundle at the point of perforation" [35]. Nevertheless, Keith described, inside the triangular area, a component which is not today mentioned in the triangular locus of the atrioventricular node: a separate tendon arising from coronary sinus valve. However, Keith could be describing a case with a double Tendon as reported previously [36].

[35] Keith, "The Auriculo Ventricular Bundle of His."

[36] James, "The Tendons of Todaro and the 'Triangle of Koch': Lessons from Eponymous Hagiolatry."

© 2025 by the author(s). Distributed under a Creative Commons CC BY license.

Preprints.org (www.preprints.org) | NOT PEER-REVIEWED | Posted: 10 September 2025 doi:10.20944/preprints202506.2135.v2

It is almost certain that Keith read also the Tawara's paper [37] because one description is not present in Aschoff's paper [38]. He mentioned in the letter to The Lancet "… as Tawara described, fine, multinucleated cells with indistinct striation; I observed also, as he did, that the fibers were accompanied by numerous nerve fibers, and there are cells, too, which have the appearance of ganglionic nerve cells". The Keith intention was to give a more didactic presentation of Tawara discoveries. Keith indeed was also the first to consider the triangular locus as useful landmark for identifying the atrial structures of the conduction system discovered by Tawara[39] and Wilhelm His Jr[40] . He was also the first to add the tendon of inferior vena cava in this area as a useful delimitation [41].

Tawara's monography "Das Reizleitungssystem des Säugetierherzens. Eine anatomisch-histologische Studie über das Atrioventrikular bündel und die Purkinjeschen Fäden" [42] (The conduction system of the mammalian heart. An anatomical-histological study of the atrioventricular bundle and Purkinje's fibers.[43]) was finished December 24th 1905 at Marburg and published at the beginning of 1906. The Aschoff's preface was written in March 19th. In that monography, he further developed what was announced before by his Mentor and by himself. Tawara first described the node (knoten) in a human heart (No. 136. The two-year-old child heart). The description is given in the section "Topography of the Atrioventricular Connecting System". Tawara had previously examined ten dog hearts in which an atrial segment of the connecting system is described, a description compatible with the node. The word knoten (node), however, was not mentioned in these dogs' hearts descriptions but he had drawn it (dog heart no 166, Figure 3) Figure 7A. In consequence, Tawara crystalized the concept of the node (Knoten) just when he studied the human heart No 136 (Figure 5);

---

[37] Tawara, "Die Topographie Und Histologie Der Brückenfasern. Ein Beitrag Zur Lehre von Der Bedeutung Der Purkinjeschen Fäden."

[38] Aschoff, "Ueber Die Untersuchungen Des Herrn Dr. Tawara, Die Bruckenfasern Betreffend Und Demonstration Der Zugehorigen Mikroskopischen Praparate."

[39] Tawara, Das Reizleitungssystem Des Säugetierherzens. Eine Anatomisch-Histologische Studie Über Das Atrioventrikularbündel Und Die Purkinjeschen Fäden; Tawara, "Die Topographie Und Histologie Der Brückenfasern."

[40] **His, "The Activity of the Embryonic Human Heart and Its Significance for the Understanding of the Heart Movement in the Adult (English Translation)"; Wilhelm His, "The Story of the Atrioventricular Bundle with Remarks Concerning Embryonic Heart Activity," Journal of the History of Medicine and Allied Sciences 4, no. 3 (1949): 319–33, https://doi.org/10.1093/jhmas/IV.3.319.**

[41] Keith, "The Auriculo Ventricular Bundle of His."

[42] Tawara, Das Reizleitungssystem Des Säugetierherzens. Eine Anatomisch-Histologische Studie Über Das Atrioventrikularbündel Und Die Purkinjeschen Fäden.

[43] Tawara, The Conduction System of the Mammalian Heart: An Anatomico-Histological Study of the Atrioventricular Bundle and the Purkinje Fibers.

© 2025 by the author(s). Distributed under a Creative Commons CC BY license.

Preprints.org (www.preprints.org) | NOT PEER-REVIEWED | Posted: 10 September 2025 doi:10.20944/preprints202506.2135.v2

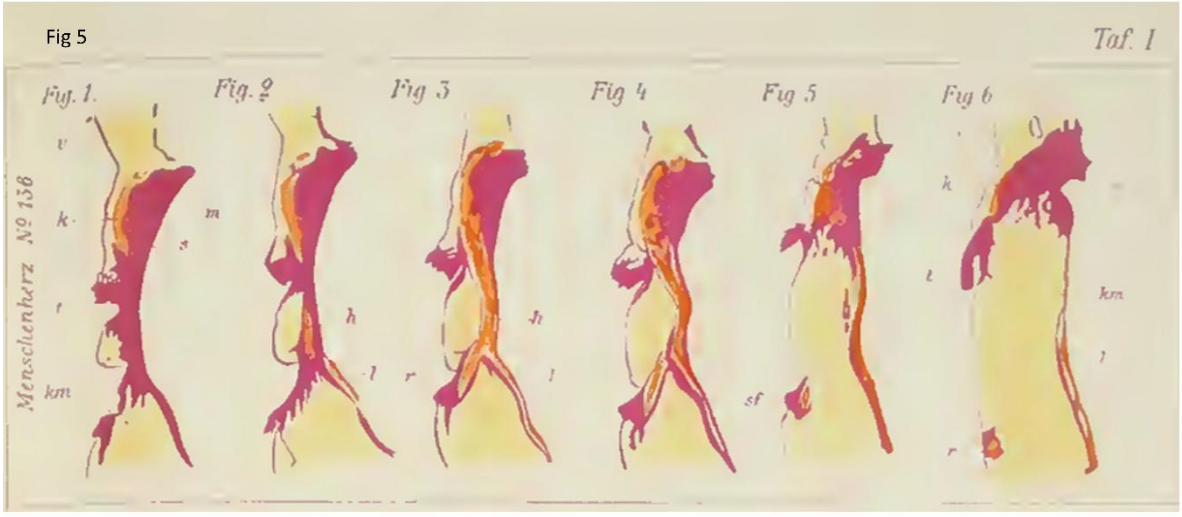

Figure 5. Sections of Human heart (No. 136. The two-year-old child heart) from S Tawara 1906 , "Das Reizleitungssystem Des Säugetierherzens. Eine Anatomisch-Histologische Studie Über Das Atrioventrikularbündel Und Die Purkinjeschen Fäden 'The conduction system of the mammalian heart"(. An anatomical–histological study of the atrioventricular bundle and Purkinje's network.) Jena: Gustav Fischer, " The upper portion of the septum(from the free edge of the noncoronary aortic leaflet) and the lower portion (from a line about 8 mm below the lowest attachment of the noncoronary aortic leaflet) were cut away parallel to the upper horizontal section line" translation by Kozo Suma& Munehiro Shimada (Tawara 2000 English translation). The cuts are so represented in vertical position and not in horizontal anatomic position. v = musculature of the atrial septum; s = the atrioventricular fibrous septum; m = anterior mitral leaflet; t = septal leaflet of the tricuspid valve; km = the ventricular septum; h = initial portion of the ventricular bundle of the connecting system;sf = a tendinous fiber for the septal leaflet of the tricuspid valve; 1 & r = the left and the right bundle branch of the connecting system; It = a part of muscle fibers of the left bundle branch entering a tendinous fibe;h = deepest attachment of the noncoronary aortic leaflet;; k = node, i.e. atrial segment of the connecting system. translation by Kozo Suma& Munehiro Shimada (Tawara 2000 English translation).

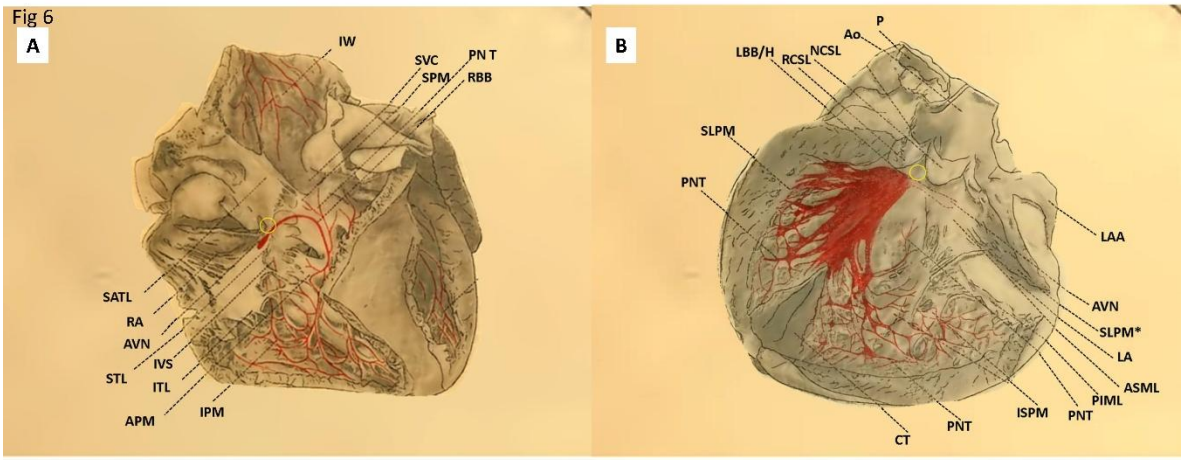

© 2025 by the author(s). Distributed under a Creative Commons CC BY license.

Preprints.org (www.preprints.org) | NOT PEER-REVIEWED | Posted: 10 September 2025 doi:10.20944/preprints202506.2135.v2

Figure 6. Human heart opened on right **A** and left sides **B** showing the atrioventricular conduction system.). Modified from S Tawara 1906 ",Das Reizleitungssystem Des Säugetierherzens. Eine Anatomisch-Histologische Studie Über Das Atrioventrikularbündel Und Die Purkinjeschen Fäden"(The conduction system of the mammalian heart. An anatomical–histological study of the atrioventricular bundle and Purkinje's network"' Jena: Gustav Fischer. ". The heart is positioned in anatomical position and the nomenclature was changed accordingly. O= The white circle was inserted by the author to show the localization of membranous septum. **A** APM= anterior papillary muscle; AVN= atrioventricular node; IVS= interventricular septum; IPM= inferior papillary muscle; ITL= inferior tricuspid leaflet; IW= inferior free wall; PNT= Purkinje network threads; RA= right atrium; RBB= right bundle branch; SATL= supero anterior tricuspid leaflet; SPM= septal papillary muscle; SVC= superior vena cava. O= Localization of membranous septum. **B** Ao= aorta; AVN= atrioventricular node; ISPM= infero septal papillary muscle; LA= left Atrium; LAA= left Atrium appendage; LBB/H= left bundle branch/bifurcation of his bundle; NCL= noncoronary aortic sinus leaflet; PNT= = Purkinje network threads; RCSL= right coronary aortic sinus leaflet ; SPLM= supero lateral papillary muscle; SPLM*=sectioned part of supero lateral papillary muscle; O= Localization of membranous septum.

Fig 7

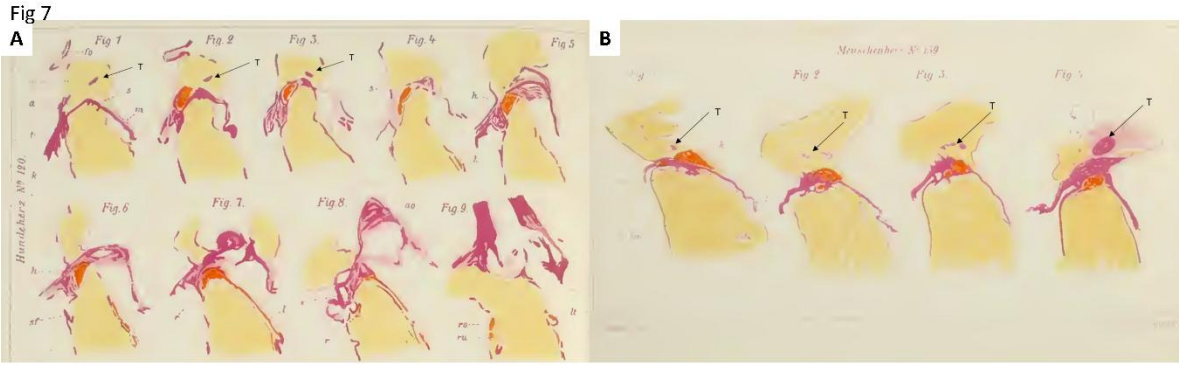

Figure 7. Sections of dog heart No 120. The three-day-old dog heart, f rom S Tawara 1906 modified by us. We added T= Todaro tendon in pictures or tendon of inferior vena cava valve. ",Das Reizleitungssystem Des Säugetierherzens. Eine Anatomisch-Histologische Studie Über Das Atrioventrikularbündel Und Die Purkinjeschen Fäden (The conduction system of the mammalian heart. An anatomical–histological study of the atrioventricular bundle and Purkinje's network). Jena: Gustav Fischer". "The axis of the heart was positioned as perpendicularly as possible, the ventricular septum being in the sagittal plane. Every sixth section was stained with Haematoxylin and van Gieson". The heart "was cut in the frontal plane serially with a thickness of nine microns in the posteroanterior direction. The axis of the heart was positioned as perpendicularly as possible, the ventricular septum being in the sagittal plane." Translation by Kozo Suma& Munehiro Shimada (Tawara 2000 English translation). fo = the oval fossa; v = musculature of the atrial septum; a = tongue like process of the atrial musculature ;s = the atrioventricular fibrous septum; m = anterior mitral leaflet; t = septal leaflet of the tricuspid valve; k = the ventricular septum; h = initial portion of the ventricular bundle of the connecting system; sf = a tendinous fiber for the septal leaflet of the tricuspid valve;1 & r = the left and the right bundle branch of the connecting system; ao = the aorta like cord; It = a part of muscle fibers of the left bundle branch entering a tendinous fiber; ro& ru = the right bundle branch separates into two groups.. Translation by Kozo Suma& Munehiro Shimada (Tawara 2000 engl translation). This is one of ten initial dogs in which Tawara did not mention theKnoten (node) but just atrial segment of the connecting system. See text.). T= Todaro tendon in pictures or tendon of inferior vena cava valve. **B** Human heart No. 139 . The heart of a female fetus, 31.5 cm

© 2025 by the author(s). Distributed under a Creative Commons CC BY license.

Preprints.org (www.preprints.org) | NOT PEER-REVIEWED | Posted: 10 September 2025 doi:10.20944/preprints202506.2135.v2

long, f rom S Tawara 1906 "Das Reizleitungssystem Des Säugetierherzens. Eine Anatomisch-Histologische Studie Über Das Atrioventrikularbündel Und Die Purkinjeschen Fäden" (The conduction system of the mammalian heart. An anatomical–histological study of the atrioventricular bundle and Purkinje's network)' Jena: Gustav Fischer. The sections were done postero anteriorly, parallel to the long axis of the heart and perpendicular to the septum. We added T= Todaro tendon in pictures or tendon of inferior vena cava valve. "v = the atrial septum; k = node, i.e. atrial segment of the connecting system; rn = the anterior mitral leaflet; t = septal leaflet of the tricuspid valve; s =the atrioventricular fibrous septum;km = ventricular septum; 1 & r = the left and the right bundle branch of the connecting system; sf = a tendinous fiber for septal leaflet of the tricuspid valve; va = leaflets of the aortic valve" . Translation by Kozo Suma& Munehiro Shimada (Tawara 2000 English translation). T= Todaro tendon or tendon of inferior vena cava valve.

By examining the staged microscopic sections, a peculiar muscle group is observed in section No. 105, which is entirely different from the atrial musculature in terms of abundancy and form of nuclei as well as in the arrangement of the muscle fibers. The muscle group is located about 1.5 mm below the lowest attachment of the noncoronary aortic leaflet, in other words, at the infero posterior margin of the membranous septum. It adheres to the atrioventricular fibrous septum (s), i.e. to the origin of the aorta. When compared with the adjacent atrial muscle fibers, the fibers are much smaller and less differentiated. The arrangement is extremely irregular, giving the appearance of a complicated glomerulation - I call this site "the node*" (k). In the following sections, this bundle becomes gradually thicker and extends anteriorly. Consequently, the tip of the bundle protrudes into the fibrous septum (section No. 110). When projected to the left endocardial surface, the extension of the bundle occupies the posterior three quarters of the noncoronary aortic leaflet. The muscle fibers connect with the adjacent ordinary atrial muscle fibers (v) posteriorly and at the right hand margin of the node (Figure 1 = section No. 110.) [44].

Tawara monography provided drawings helping the macroscopic and microscopic localization of the Knoten (Atrioventricular node). (Figure 1A, B; Figure 6A, B) Tawara macroscopic figures show the evident relation of the node with the septal tricuspid leaflet and mitral aortic leaflet, coronary sinus ostium, commissure of septal and antero superior tricuspid leaflet, right and non-coronary leaflets, central fibrous body and membranous septum (Figure 1; Figure 6A, B). The inferior vena cava tendon (Todaro's tendon), however, is not described or mentioned. In some of his histological figures he sketched the tendon but he did not make reference to it . Tawara clearly represented the tendon in Fig 120 plate 1. in a dog heart (Figure 7A). and possibly in fig 139 in a human heart. (Figure 7B). In general, the upper border of the other figures are too close to the fibrous skeleton to see the tendon in different cut levels. However, his descriptions, and figures of the node and its relation with surroundings structures are completely original and precise. Shortly, Tawara was the first to describe all components of the triangular locus in its relation with the node excluding the inferior vena cava valve tendon. Koch [45] three years after Keith, 1909, described the tendon of vena cava and assembled it with the other structures previously described by Tawara, constructing the triangle . Importantly, Koch started working with the histology of conduction system in 1907[46]. Koch emphasized the presence of the node and atrioventricular bundle in a figure whose main objective was to show the advances he obtained in morphology of sinoatrial node [47](Fig .8) . He did not use the tendon of inferior vena cava , the ostium of Conary sinus and the septal

[44] Tawara.

[45] Koch, "Weiter Mitteilungen Über Den Sinusknoten Des Herzens."

[46] James, "The Tendons of Todaro and the 'Triangle of Koch': Lessons from Eponymous Hagiolatry."

[47] Koch, "Weiter Mitteilungen Über Den Sinusknoten Des Herzens"; Arthur Keith and Ivy Mackenzie, "Recent Researches on the Anatomy of the Heart," *The Lancet* 175, no. 4506 (January 8, 1910): 101–3, https://doi.org/10.1016/S0140-6736(01)74711-3.

© 2025 by the author(s). Distributed under a Creative Commons CC BY license.

Preprints.org (www.preprints.org) | NOT PEER-REVIEWED | Posted: 10 September 2025 doi:10.20944/preprints202506.2135.v2

attachment of tricuspid leaflet as useful landmarks for finding the atrial components of heart conduction system. Indeed, the main objective of the whole paper was to detail his findings in sinoatrial node and discuss its probable function [48] . He wrote

On the other hand, at another location in the entry of the atrial cavity, more anteriorly near the upper border of the right atrial appendage, there is a peculiar muscular system discovered by Keith and described in more detail by me in a previously published work, which in many respects can be considered parallel to the atrial part of the conduction system between the atrium and the ventricle. I was able to demonstrate it at the time, at the border between the atrium and the cava in the sulcus already discussed, beginning approximately at the upper edge of the atrial appendage. As recent observations have shown me, it appears to extend along the sulcus, its fibers extending outward and downward almost 1 cm further than I previously stated (2 cm) (Figure 3), where it splits and disappears upward into the musculature of the cava and downward into the atrial musculature…. I consider the demonstration of this muscular system discovered by Keith to be not unimportant, since with a better understanding of its function, disturbances in it may perhaps be able to be used to explain physiological and pathological cardiac processes.

Dreieck (triangle) is not mentioned nor in this paper neither in his magnum opus [49]. Koch did not gave credit to Keith, on this particular aspect, who just emphasized the fibers of the atrial portion of the bundle inside of the triangular locus. Both did not gave credit to Todaro [50] .Both did not stress or write that they were delimiting a triangular area . Tandler [51] named for the first time the locus as a Koch's Dreieck (triangle) [52]

Topographically, the nodule was described almost entirely consistently by all authors, although the relationship to the aortic valves was particularly emphasized. This relationship, at least for locating the nodule, does not seem particularly well chosen, since the nodule is most easily located from the right side of the atrial septum. Koch relocated the nodule into the triangle he described. Koch outlined this triangle as follows: The caudal border is formed by the insertion of the tricuspid artery, the calcaneal border by a fold that forms when the junction of the Eustachian and Thebesian valves is tensed to the right with forceps. The fold then runs obliquely forward and downward toward the membranous septum. In my opinion, it is the expression of the tension of Todaro's tendon, which has already been described elsewhere. The posterior border of this triangular field is represented by the orifice of the coronary sinus. Near the apex of this triangle, as Koch quite rightly points out, lies the node. We already emphasized elsewhere that Koch's deductions, as if this field were originally a sensory area, are not valid for evolutionary reasons. However, Koch's topographical definition is certainly acceptable.

Tandler forgot also that Tawara had described the main relations of the node in right atrial side.

Limitations of the Study

The author did not intend to be exhaustive or dogmatic in matters of the priority of the discoveries. As exposed here Keith and Koch have rediscovered the findings of Todaro and we cannot affirm with absolute certainty that Todaro was the first to describe the tendon of the inferior vena cava valve. These does not invalidate the thesis: to know, that the triangular locus of the

---

[48] Koch, "Weiter Mitteilungen Über Den Sinusknoten Des Herzens."

[49] **Walter Koch, Der Funktionelle Bau Des Menschlichen Herzens, 1st ed. (Berlin: Urban & Schwazenberger, 1922).**

[50] Todaro, Novelle Ricerche Sopra La Struttura Delle Orecchiette Del Cuore Umano e Sopra Ta Valvola Di Eustachio. .

[51] Tandler, Anatomie Des Herzens.

[52] James, "The Tendons of Todaro and the 'Triangle of Koch': Lessons from Eponymous Hagiolatry."

© 2025 by the author(s). Distributed under a Creative Commons CC BY license.

Preprints.org (www.preprints.org) | NOT PEER-REVIEWED | Posted: 10 September 2025 doi:10.20944/preprints202506.2135.v2

atrioventricular node was a collective construct. To prove it we just need one clear and logical sequence of temporally sound events as shown here.

Conclusion

The first to assemble all the components of the triangular locus relating them as useful marks to find the atrial components of the conduction system described by Sunao Tawara was Arthur Keith. In summary the triangular locus of the atrioventricular node was a collective construct as the majority of human scientific endeavors[53].

Ethical issues: The ethical issues are not involved in this article whose main novelty is a revision of an historical error, an eponym widely used in cardiac anatomy.

Acknowledgments: Many thanks to the librarians of Free University of Berlin who gently sent me the paper of Koch W (1909) Weiter Mitteilungen über den Sinusknoten des Herzens. . Verh Deutscth Ges Pathol 13:85–92 The author is the responsible for planning, writing and analyzing the data presented in the article.

Conflict of interest: There is no conflict of interest.

Copyrights: The figures shown in this article are free of copyrights.

References

1. Almeida, M.C. De, D. Sánchez-Quintana, N. Davis, F.R. Charles, A. Chikweto, W. Sylvester, M. Loukas, and R.H. Anderson. "The Ox Atrioventricular Conduction Axis Compared to Human in Relation to the Original Investigation of Sunao Tawara." *Clinical Anatomy* 33, no. 3 (2020). https://doi.org/10.1002/ca.23524.
2. Almeida, Marcos C. De. "Heinrich Ewald Hering's Discovery of the Heart Pacemaker: Hering, Tawara and Aschoff's Search for Its Morphological Basis, the Sinoatrial Node, and Why They Failed." *Anatomical Science International* 98 (2023): 482–492.
3. Aschoff, L. "Ueber Die Untersuchungen Des Herrn Dr. Tawara, Die Bruckenfasern Betreffend Und Demonstration Der Zugehorigen Mikroskopischen Praparate." *Muenchener Medizinische Wochenscrift* 52, no. 2 (1905): 674.
4. Clark, WCLG. "Arthur Keith 1866-1955." *Biographical Memoirs of the Fellows of the Royal Society* 1 (1955): 144–51.
5. Conti, Andrea A. "Calling the Heart by Name: Distinguished Eponyms in the History of Cardiac Anatomy." *The Heart Surgery Forum* 14, no. 3 (June 2011): E183-7. https://doi.org/10.1532/HSF98.20101047.
6. Drenckham, D. *Benninghoff Anatomie*. Edited by D Drenckham. 16th ed. München: Urban and Fischer. Elsevier, 2004.
7. Fye, W B. "Ludwig Aschoff." *Clinical Cardiology* 22, no. 8 (August 1999): 545–46. https://doi.org/10.1002/clc.4960220812.
8. Hering, H E. "Nachweis, Dass Das His'sche Uebergangsbündel Vorhof Und Kammer Des Säugethierherzens Functionell Verbindet - Zweite Mittheilung." *Pflüger, Archiv Für Die Gesammte Physiologie Des Menschen Und Der Thiere* 108, no. 6–7 (1905): 267–80. https://doi.org/10.1007/BF01678340.
9. His, Wilhelm. "The Activity of the Embryonic Human Heart and Its Significance for the Understanding of the Heart Movement in the Adult (English Translation)." *Journal of the History of Medicine and Allied Sciences* 4, no. 3 (1949): 289–318. https://doi.org/10.1093/jhmas/IV.3.289.
10. ———. "The Story of the Atrioventricular Bundle with Remarks Concerning Embryonic Heart Activity." *Journal of the History of Medicine and Allied Sciences* 4, no. 3 (1949): 319–33. https://doi.org/10.1093/jhmas/IV.3.319.

[53] Alexander Woywodt and Eric Matteson, "Should Eponyms Be Abandoned? Yes.," BMJ (Clinical Research Ed.) 335, no. 7617 (September 2007): 424, https://doi.org/10.1136/bmj.39308.342639.AD; David J Ogden, "Time to Drop Eponyms: Curbing Medicalese Is the Issue.," BMJ (Clinical Research Ed.) (England, September 2007), https://doi.org/10.1136/bmj.39332.450995.3A.

© 2025 by the author(s). Distributed under a Creative Commons CC BY license.

Preprints.org (www.preprints.org) | NOT PEER-REVIEWED | Posted: 10 September 2025 doi:10.20944/preprints202506.2135.v2

11. James, Thomas N. "The Tendons of Todaro and the 'Triangle of Koch': Lessons from Eponymous Hagiolatry." *Journal of Cardiovascular Electrophysiology* 10, no. 11 (1999): 1478–96. https://doi.org/10.1111/j.1540-8167.1999.tb00207.x.
12. Keith, A. "The Sino-Auricular Node: A Historical Note." *Heart* 4, no. 3 (1942): 77–79. https://doi.org/10.1136/HRT.4.3.77.
13. Keith, Arthur. "The Auriculo Ventricular Bundle of His." *The Lancet* 167, no. 4305 (1906): 623–25.
14. Keith, Arthur, and Ivy Mackenzie. "Recent Researches on the Anatomy of the Heart." *The Lancet* 175, no. 4506 (January 8, 1910): 101–3. https://doi.org/10.1016/S0140-6736(01)74711-3.
15. Koch, Walter. *Der Funktionelle Bau Des Menschlichen Herzens*. 1st ed. Berlin: Urban & Schwazenberger, 1922.
16. ———. "Weiter Mitteilungen Über Den Sinusknoten Des Herzens." . . *Verh Deutscth Ges Pathol* 13 (1909): 85–92.
17. Kyle, Robert A, and Marc A Shampo. "Professor Julius Tandler, Anatomist and Public Health Advocate." *Mayo Clinic Proceedings* 65, no. 4 (1990): 530. https://doi.org/https://doi.org/10.1016/S0025-6196(12)60953-7.
18. Mori, Shumpei, Tatsuya Nishii, Tomofumi Takaya, Kazuhiro Kashio, Akira Kasamatsu, Sachiko Takamine, Tatsuro Ito, Sei Fujiwara, Atsushi K. Kono, and Ken Ichi Hirata. "Clinical Structural Anatomy of the Inferior Pyramidal Space Reconstructed from the Living Heart: Three-Dimensional Visualization Using Multidetector-Row Computed Tomography." *Clinical Anatomy*. John Wiley and Sons Inc., October 1, 2015. https://doi.org/10.1002/ca.22483.
19. Ogden, David J. "Time to Drop Eponyms: Curbing Medicalese Is the Issue." *BMJ (Clinical Research Ed.)*. England, September 2007. https://doi.org/10.1136/bmj.39332.450995.3A.
20. Ottaviani, Alessandro. "Francesco Todaro." In *Dizionario Biografico Degli Italiani*. Istituto della Enciclopedia Italiana fondata da Giovanni Treccani S.p.A, 2019. https://www.treccani.it/enciclopedia/francesco-todaro_(Dizionario-Biografico)/.
21. Ottaviani, Giulia. "Dr. Thomas N. James, MD, MACP (1925-2010): In Memoriam." *The American Journal of Cardiology*. United States, July 2011. https://doi.org/10.1016/j.amjcard.2011.04.001.
22. Stranding, S. *Gray`s Anatomy*. Edited by S Stranding. 41st ed. Elsevier, 2016.
23. Suma, K. "Sunao Tawara: A Father of Modern Cardiology." *Pacing and Clinical Electrophysiology : PACE* 24, no. 1 (January 2001): 88–96. http://www.ncbi.nlm.nih.gov/pubmed/11227976.
24. Tandler, J. *Anatomie Des Herzens*. 1st ed. Jena: Gustav Fischer, 1913.
25. Tawara, S. "Die Topographie Und Histologie Der Brückenfasern. Ein Beitrag Zur Lehre von Der Bedeutung Der Purkinjeschen Fäden." *Zentrallblatt Fur Physiologie* 19, no. 3 (1906): 70–76.
26. Tawara, S. "Anatomisch-Histologische Nachpriifung Der Schnittfuhrung an Den von Prof. H.E. Hering Ubersandten Hundeherzen." *Zentrallblatt Fur Physiologie* 111 (1906): :300-302.
27. ———. *Das Reizleitungssystem Des Säugetierherzens. Eine Anatomisch-Histologische Studie Über Das Atrioventrikularbündel Und Die Purkinjeschen Fäden*. Jena: Gustav Fischer, 1906.
28. ———. "Die Topographie Und Histologie Der Brückenfasern." *Zentrallblatt Fur Physiologie* 19, no. 3 (1906): 70–76.
29. ———. *The Conduction System of the Mammalian Heart: An Anatomico-Histological Study of the Atrioventricular Bundle and the Purkinje Fibers.* Edited by K Suma and M Shimada. *Imperial Collage Press*. 1st Englis. London: Imperial College Press, 2000.
30. Todaro, Francesco. *Novelle Ricerche Sopra La Struttura Delle Orecchiette Del Cuore Umano e Sopra Ta Valvola Di Eustachio. . Stabilimento Civelli*. Firenze, 1895.
31. Woywodt, Alexander, and Eric Matteson. "Should Eponyms Be Abandoned? Yes." *BMJ (Clinical Research Ed.)* 335, no. 7617 (September 2007): 424. https://doi.org/10.1136/bmj.39308.342639.AD.

Disclaimer/Publisher's Note: The statements, opinions and data contained in all publications are solely those of the individual author(s) and contributor(s) and not of MDPI and/or the editor(s). MDPI and/or the editor(s) disclaim responsibility for any injury to people or property resulting from any ideas, methods, instructions or products referred to in the content.

© 2025 by the author(s). Distributed under a Creative Commons CC BY license.