

Figure S1

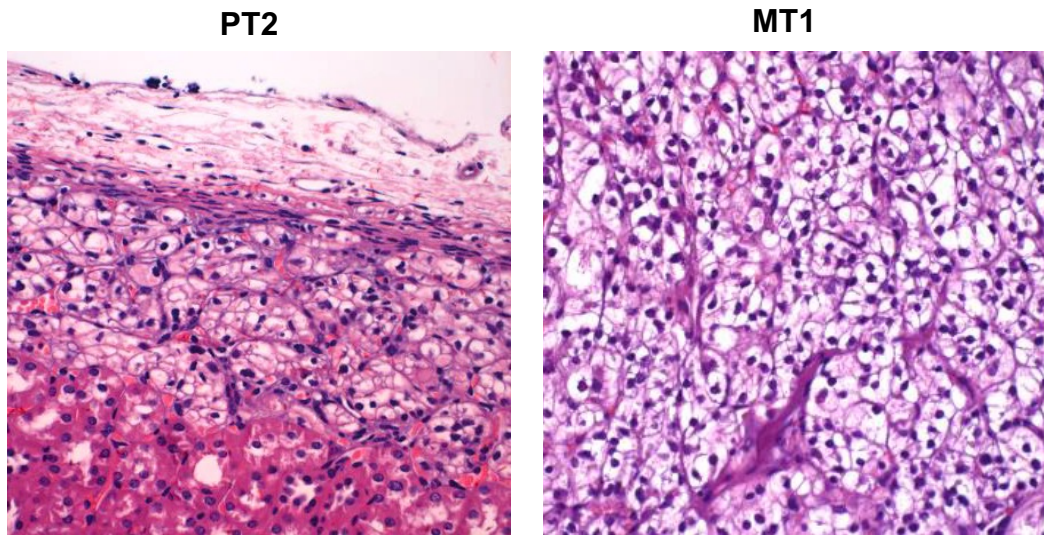


Figure S1. H&E-stained sections of subcapsular patient-derived ccRCC tumors in NOD-SCID mice, at 6 weeks post-inoculation. Left, PT2; Right, MT1. Both tumors display the clear cytoplasm characteristic of ccRCC. 40X magnification.