

Review

Not peer-reviewed version

---

# Laboratory Analyse for Liver Diseases Diagnosis

---

[Antonella A Chesca](#) \*

Posted Date: 6 February 2024

doi: 10.20944/preprints202312.0919.v3

Keywords: liver; hepatitis C; hepatic cirrhosis; laboratory technique; diagnosis



Preprints.org is a free multidiscipline platform providing preprint service that is dedicated to making early versions of research outputs permanently available and citable. Preprints posted at Preprints.org appear in Web of Science, Crossref, Google Scholar, Scilit, Europe PMC.

Copyright: This is an open access article distributed under the Creative Commons Attribution License which permits unrestricted use, distribution, and reproduction in any medium, provided the original work is properly cited.

Review

# Laboratory Analyse for Liver Diseases Diagnosis

Antonella Chesca

Transilvania University of Brasov, Romania; Clinical Hospital of Pneumophthysiology and Infectious Diseases  
Braşov, Romania; anto.chesca@gmail.com or antonella.chesca@unitbv.ro

**Abstract:** Actually, the study aimed to manage and to analyse the results of the laboratory methods, using liver samples, preparing and analyzing in pathology service. This mentioned, are known as routinely practice for hepatitis C diagnosis, which conduct to hepatic cirrhosis. In this study direction, chronic liver diseases stimulate a degree of hepatocyte injury. So previously mentioned modifications, alters that affect the liver architecture and finally ends in cirrhosis are well analyse on microscopic preparates. Following morphological steps, it is possible to analyse normal and alterate liver structure, on colored preparates.

**Keywords:** liver; hepatitis C; hepatic cirrhosis; laboratory technique; diagnosis

## Introduction

Currently, HCV infection could be consider as one of bad results after percutaneous blood administration to ill patients. Also good to mention that HCV infection it is known as one of the most commonly through injection drug use. [1] The first and most important step in the care cascade is testing for HCV. Actually, is an enlarge number of expansion of populations eligible for testing for HCV prevention. [1–3]

It is know about *care cascade*, including multiple key points in diagnosis HCV infection. An HCV *care cascade* is consider as a model for identifying opportunities and barriers in order to improve laboratory tests, linkage to care, and proper treatment access. [4,5]

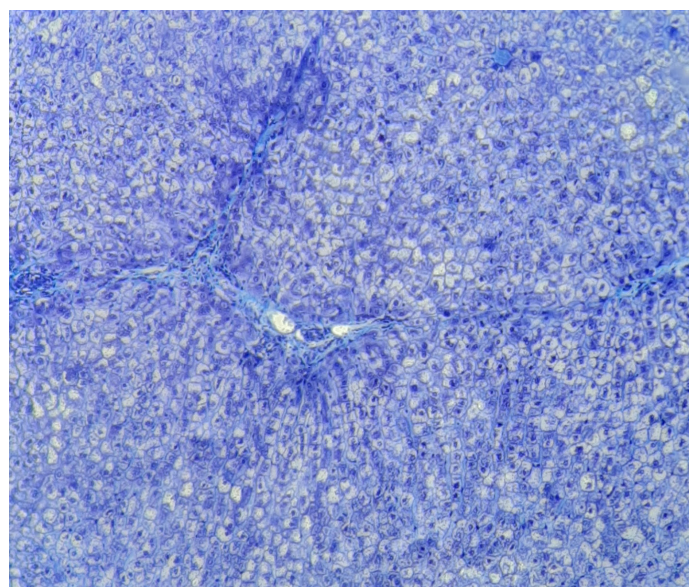
Relatively recently, there have been increases in HCV detection among women of childbearing age. [6,7] Reinfection with HCV after curative therapy in illness status in different patients, is an important key point for medical team. [8–10] The proper laboratory techniques include immunoglobulin (Ig) G antibody enzyme immunoassays (anti-HCV) and nucleic acid tests (NAT), as modern methods, in conection with blood tests.[11] In case that need to distinguish between two directions such as true or false positivity of the anti-HCV antibody result, previously mentined tests, may be done with a second FDA-approved HCV antibody assay that is different from previously used for testing [11,12] Morphologically, HCV is an enveloped, positive-sense, single-stranded RNA virus of the *Flaviviridae* family.[13–15] The great key point knowing as a start of the direct-acting antiviral (DAA) era was in 2011. The important role in this direction was the introduction of two NS3/4A protease inhibitors. Both previously mentioned were used in combination with interferon-based regimens for chronic HCV treatment to ill patients diagnosed [16]. Results of studies show that the HCV replication process is error prone. Finally results practically could be observe in variant viruses knowing as quasispecies.[17,18] Nowadays there are 7 genotypes of HCV. So there are known 6 major genotypes and the recent addition of genotype 7. This last 7 genotip has been found only in a few cases diagnosed to HCV positive patients. [19] Hepatitis C virus (HCV) infection is a great cause of various liver diseases as cirrhosis and hepatocellular carcinoma. Following promising news, significant scientific discovering things remain in attention for reducing morbidity and mortality, associated to HCV. [20,21] Understanding the properties of hepatitis C virus (HCV) viral RNA and proteins facilitates the development of diagnosis methods and also a proper treatment, including antivirals.[22–24] In addition we can mention that HCV genotyping assays approved for *in vitro* diagnostic use are commercially available[25,26] Cirrhosis, as a nowadays disease, is characterized by fibrosis and nodule formation of the liver. In the secondary plan, it is

known as a chronic injury, which leads to alteration of the normal lobular organization of the liver. A complex of factors, such as life style, or environmental, can injure the liver, and beside also including viral infections, toxins, hereditary. With each injury, the liver suffer alterations as fibrosis. Finally but after a long-standing injury, liver functional alteration, develop in time cirrhosis as a complex diseases. Ethiology of the chronic liver diseases usually progress unfortunately in cirrhosis, following pathological mechanisms.[27] Scientific knowledges referring to the severity of liver cirrhosis, as a disease with a bad prognostic on the public health, is still not well characterized. [28]

### Material and methods

In order to assist medical staff in understanding the concerns outlined, a series of digital images have been prepared. The operative pieces are intended to bring in the pathological anatomy service for macroscopic examination for diagnostic purposes. This are examined by performing the optical microscopic analysis.

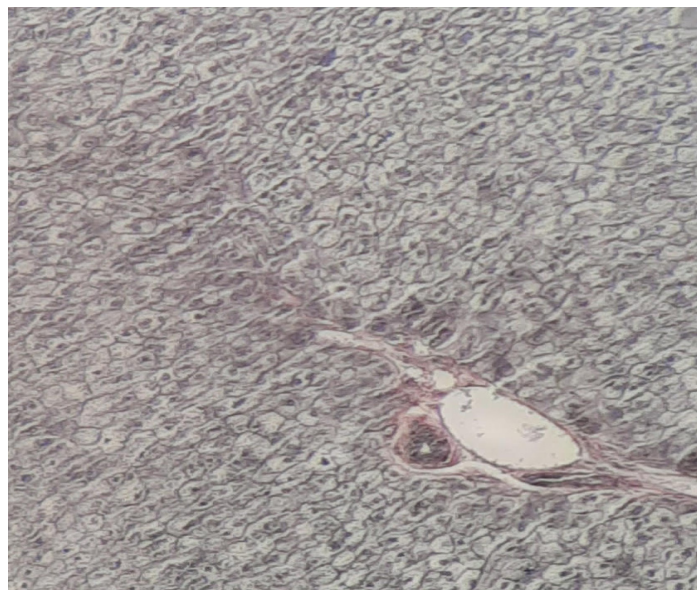Normal liver structure, using an optical microscope analyse and a special staining namely Masson. We can observe hepatocytes and interlobular spaces and septa.[Figure 1]



**Figure 1.** Normal Liver x10 Masson staining.

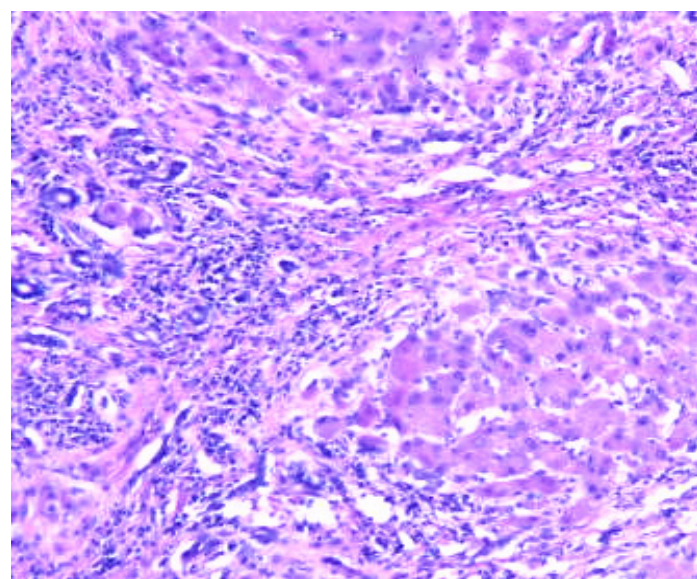
A similar observation on a normal liver structure but using another specific staining known as *Argent impregnation Gomori*. Also is possible to observe the *Kiernan space with portal vein in section and with hepatic arter in section together with biliar canaliculum in section*. [Figure 2]





**Figure 2.** Normal Liver x10. *Argentaffin impregnation.*

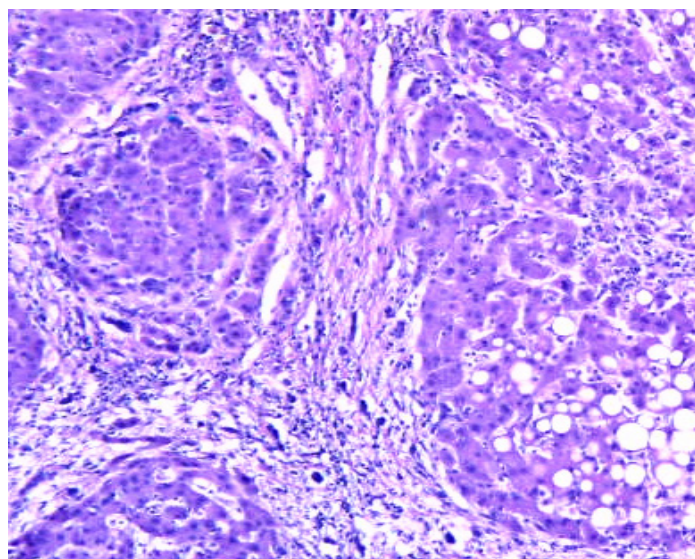
In liver cirrhosis, on samples could be observe tissue fibrosis and alterations in the normal liver architecture in abnormal structural nodules. [Figure 3]



**Figure 3.** Cirrhosis liver x10 HE.

A similar coming image with specific structural changes in liver structure and with vascularized fibrotic septa in cirrhosis More than , we can mention in this disease, about portal hypertension. [Figure 4]

Prevention and treatment of liver cirrhosis are best done by an interdisciplinary medical team.



**Figure 4.** Cirrhosis liver x10 HE.

Animal models play a significant role in liver pathology diagnosis for example in rats with cirrhosis. Cirrhosis, as a nowadays disease, is characterized by fibrosis and neoformation nodules in the liver architecture. In addition, cirrhosis it is known as a chronic injury, which leads to alteration of the normal lobular organization of the liver. [29–31] A complex of factors, such as life style, or environmental factors, can affect the liver, for better or for worse. [32,33]

## Conclusions

Research studies predict about not so a good prognosis of patients diagnosed with cirrhosis, knowing laboratory results and clinical points.. Knowing the diagnostic in the ill patients, medical specialists could apply the proper treatment, carefully to the comorbidities. In idea that hepatic cirrhosis is hard or impossible to cure, we are waiting from future research directions and plans.

## References

1. AASLD-IDSA. HCV Guidance: Recommendations for Testing, Managing, and Treating Hepatitis C 2016. Available from: [http://hcvguidelines.org/sites/default/files/HCV-Guidance\\_October\\_2016\\_a.pdf](http://hcvguidelines.org/sites/default/files/HCV-Guidance_October_2016_a.pdf). Guidance produced by the American Association for the Study of Liver Disease and the Infectious Disease Society of America (AASLD-IDSA) covering recommendations for hepatitis C testing, clinical management and treatment.
2. Recommendations for prevention and control of hepatitis C virus (HCV) infection and HCV-related chronic disease. Centers for Disease Control and Prevention. *MMWR Recomm Rep*. 1998;47(Rr-19):1–39. Recommendations from the Centers for the Disease Control and Prevention defining populations for risk-based testing of hepatitis C.
3. Moyer VA. Screening for hepatitis C virus infection in adults: U.S. Preventive Services Task Force recommendation statement. *Ann Intern Med*. 2013;159(5):349–57. Hepatitis C testing recommendations for adults from the United States Preventive Services Task Force including risk-based testing and testing for adults born from 1945–1965.
4. Holmberg SD, Spradling PR, Moorman AC, Denniston MM. Hepatitis C in the United States. *N Engl J Med*. 2013;368(20):1859–61. Description of a care cascade integrating data from the Chronic Hepatitis Cohort Study and the National Health and Nutrition Examination Survey.
5. Viner K, Kuncio D, Newbern EC, Johnson CC. The continuum of hepatitis C testing and care. *Hepatology*. 2015;61(3):783–9. Description of an HCV continuum of care in a US urban center highlighting important areas where patients become lost at each stage.
6. Koneru A, Nelson N, Hariri S, Canary L, Sanders KJ, Maxwell JF, et al. Increased Hepatitis C Virus (HCV) Detection in Women of Childbearing Age and Potential Risk for Vertical Transmission - United States and Kentucky, 2011–2014. *MMWR Morb Mortal Wkly Rep*. 2016;65(28):705–10. Analysis finding that the proportion of infants born to HCV-infected mothers increased 68% nationally and 124% in Kentucky.

7. Kuncio DE, Newbern EC, Johnson CC, Viner KM. Failure to Test and Identify Perinatally Infected Children Born to Hepatitis C Virus-Infected Women. *Clin Infect Dis*. 2016;62(8):980–5. Analysis of surveillance data from the Philadelphia Department of Public Health finding a significant number of women giving birth in Philadelphia tested positive for HCV but that most of their children were not tested for HCV.
8. Lambers FA, Prins M, Thomas X, Molenkamp R, Kwa D, Brinkman K, et al. Alarming incidence of hepatitis C virus re-infection after treatment of sexually acquired acute hepatitis C virus infection in HIV-infected MSM. *AIDS*. 2011;25(17):F21–7.
9. Martin TC, Martin NK, Hickman M, Vickerman P, Page EE, Everett R, et al. Hepatitis C virus reinfection incidence and treatment outcome among HIV-positive MSM. *AIDS (London, England)* 2013;27(16):2551–7.
10. Ingiliz P, Martin TC, Rodger A, Stellbrink HJ, Mauss S, Boesecke C, et al. HCV reinfection incidence and spontaneous clearance rates in HIV-positive men who have sex with men in Western Europe. *J Hepatol*. 2016.
11. Testing for HCV infection: an update of guidance for clinicians and laboratorians. *MMWR Morb Mortal Wkly Rep*. 2013;62(18):362–5. Updated guidance for clinicians and laboratorians from the Centers for Disease Control and Prevention on diagnostic testing procedures for hepatitis C.
12. Moyer VA. Screening for hepatitis C virus infection in adults: U.S. Preventive Services Task Force recommendation statement. *Ann Intern Med*. 2013;159(5):349–57. Hepatitis C testing recommendations for adults from the United States Preventive Services Task Force including risk-based testing and testing for adults born from 1945–1965.
13. Thomas DL, Seeff LB. Natural history of hepatitis C. *Clin Liver Dis*. 2005;9(3):383–98. vi.
14. Mack CL, Gonzalez-Peralta RP, Gupta N, Leung D, Narkewicz MR, Roberts EA, et al. NASPGHAN practice guidelines: Diagnosis and management of hepatitis C infection in infants, children, and adolescents. *J Pediatr Gastroenterol Nutr*. 2012;54(6):838–55.
15. Thein HH, Yi Q, Dore GJ, Krahn MD. Estimation of stage-specific fibrosis progression rates in chronic hepatitis C virus infection: a meta-analysis and meta-regression. *Hepatology*. 2008;48(2):418–31.
16. Conteduca V, Sansonno D, Russi S, Pavone F, Dammacco F. Therapy of chronic hepatitis C virus infection in the era of direct-acting and host-targeting antiviral agents. *J Infect*. 2014;68(1):1–20.
17. Gomez J, Martell M, Quer J, Cabot B, Esteban JI. Hepatitis C viral quasiespecies. *J Viral Hepat*. 1999;6(1):3–16.
18. Duffy S, Shackelton LA, Holmes EC. Rates of evolutionary change in viruses: patterns and determinants. *Nat Rev Genet*. 2008;9(4):267–76.
19. Bukh J. The history of hepatitis C virus (HCV): Basic research reveals unique features in phylogeny, evolution and the viral life cycle with new perspectives for epidemic control. *J Hepatol*. 2016;65(1 Suppl):S2–s21.
20. Ly KN, Hughes EM, Jiles RB, Holmberg SD. Rising Mortality Associated With Hepatitis C Virus in the United States, 2003–2013. *Clin Infect Dis*. 2016;62(10):1287–8. Describes rising HCV-associated mortality in the United States from 2003–2013. During that time period, HCV-associated deaths surpassed 60 other nationally notifiable infectious conditions combined.
21. Allison RD, Tong X, Moorman AC, Ly KN, Rupp L, Xu F, et al. Increased incidence of cancer and cancer-related mortality among persons with chronic hepatitis C infection, 2006–2010. *J Hepatol*. 2015;63(4):822–8. Analysis of a cohort of HCV-infected persons that found the the incidence of liver cancer and many types of non-liver cancers were higher, and age at diagnosis and death younger, in patients with chronic HCV infection compared to the general population.
22. Alberti A, Chemello L, Benvegnù L. Natural history of hepatitis C. *J Hepatol*. 1999;31 Suppl 1:17–24.
23. Hoofnagle JH. Course and outcome of hepatitis C. *Hepatology*. 2002;36:S21–S29.
24. Chen SL, Morgan TR. The natural history of hepatitis C virus (HCV) infection. *Int J Med Sci*. 2006;3:47–52.
25. Chevaliez S, Pawlotsky JM. Virology of hepatitis C virus infection. *Best Pract Res Clin Gastroenterol*. 2012;26:381–389.
26. Saludes V, González V, Planas R, Matas L, Ausina V, Martró E. Tools for the diagnosis of hepatitis C virus infection and hepatic fibrosis staging. *World J Gastroenterol*. 2014;20:3431–3442.
27. Naveau S, Perlemuter G, Balian A. [Epidemiology and natural history of cirrhosis]. *Rev Prat*. 2005 Sep 30;55(14):1527–32.
28. Kleinbloesem CH, van Harten J, Wilson JP, Danhof M, van Brummelen P, Breimer DD. Nifedipine: kinetics and hemodynamic effects in patients with liver cirrhosis after intravenous and oral administration. *Clin Pharmacol Ther*. 1986;40:21–8.
29. Bircher J, Benhamou JP, McIntyre N, Rizzetto M, Rodes J, editors. *Oxford Textbook of Clinical Hepatology*. 2nd Edition Oxford University Press; 1999.
30. Sherlock S, Dooley J, editors. *Diseases of the Liver and Biliary System*. 11th Edition Blackwell Science; Oxford, UK; Malden, MA: 2002.
31. Schiff ER, Sorrell MF, Maddrey EC, editors. *Schiff's Diseases of the Liver*. 9th Edition Lippincott, Williams & Wilkins; Philadelphia: 2003.

32. Desmet VJ, Roskams T. Cirrhosis reversal: a duel between dogma and myth. *J Hepatol.* 2004;40:860–7.
33. Wanless IR, Nakashima E, Sherman M. Regression of human cirrhosis. Morphologic features and the genesis of incomplete septal cirrhosis. *Arch Pathol Lab Med.* 2000;124:1599–607.

**Disclaimer/Publisher's Note:** The statements, opinions and data contained in all publications are solely those of the individual author(s) and contributor(s) and not of MDPI and/or the editor(s). MDPI and/or the editor(s) disclaim responsibility for any injury to people or property resulting from any ideas, methods, instructions or products referred to in the content.