

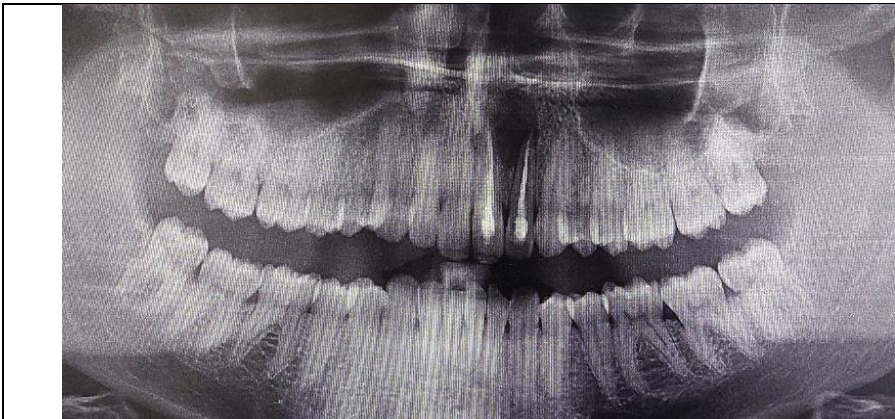

Figure 1 : Preoperative radiography : large radiolucent image in the apical area regarding 21-22

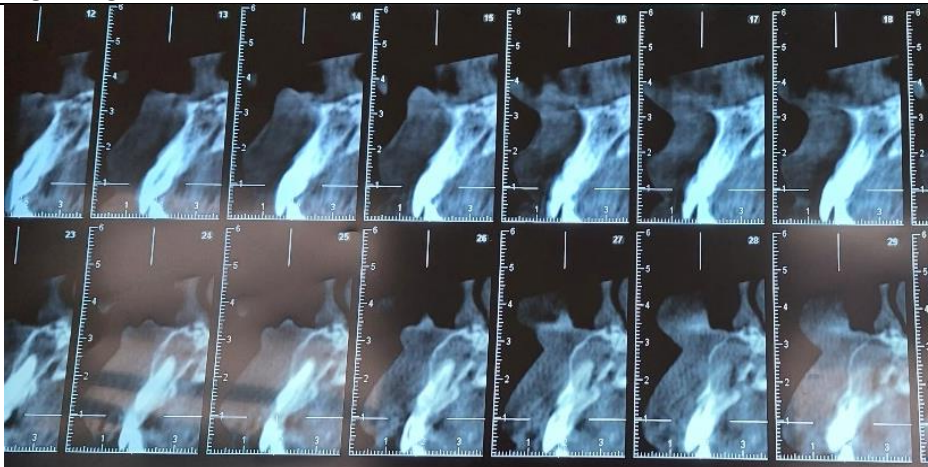

Figure 2 : CBCT investigation : confirmation of initial diagnosis : periapical cyst with bone fenestration

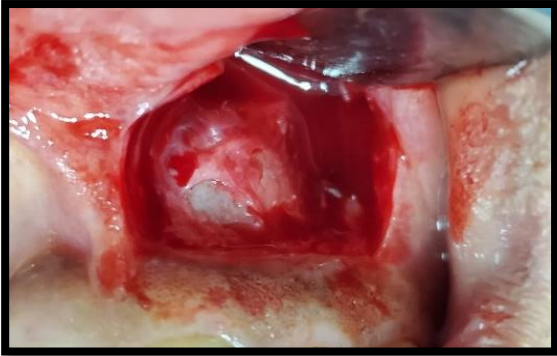


Figure 3 : Perforation of the vestibular cortical

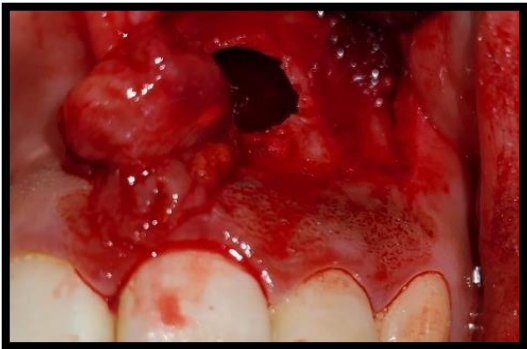

Figure 4 : remove of the whole cyst without membrane separation

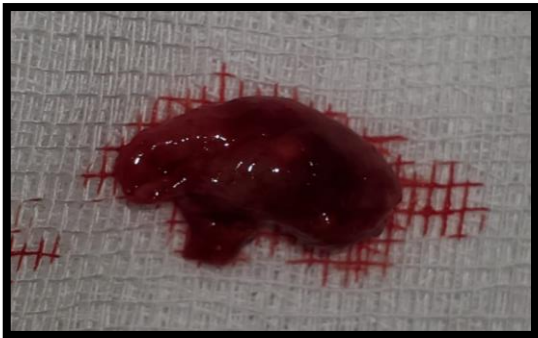

Figure 5 : excised specimen

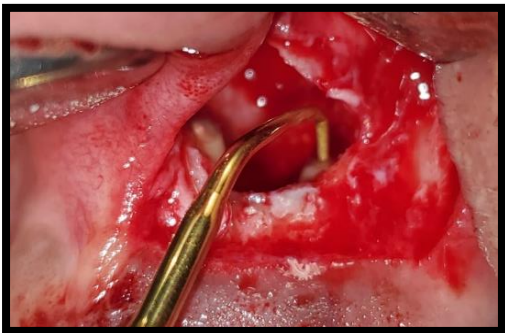

Figure 6 : root-end preparation with ultrasonic tips

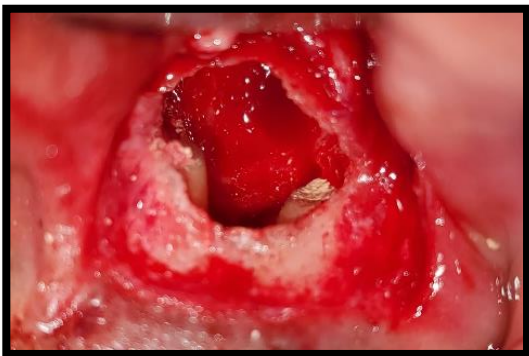


Figure 7 : cavity filled with BIODENTINE

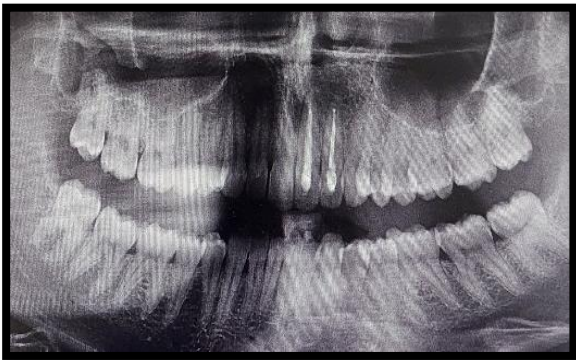


Figure 8 : Radiographic 6 months follow up : reossification of the lesion