

Anti-diabetic, Antioxidants, Anti-hepatorenal toxicity Activities of *Cyperus rotundus* rhizome extract in alloxan-induced diabetic Rats

Mohammed Sadeg A. Al-Awar^{*1,2}, Turki Yahya Alqabbani²

¹Department of Biology, Faculty of Applied Sciences, Amran University, Amran St. Amran, Yemen. ²Department of Medical Laboratory, Collage of Medical Sciences, Al-Razi University, AlRebat St, Sana'a, Yemen

*Corresponding author address: Mohammed Sadeg A. Al-Awar. Phone: 00967771227420. ORCID: 0000-0002-8847-6817.

Author	Institutional e-mail (mandatory)	Other e-mail (gmail, yahoo, etc.)
Mohammed Sadeg A. Al-Awar	dr.msadeg@auye.ac	momed.sadeg@gmail.com
Turki Yahya Alqabbani	turki@alraziuni.edu.ye	Turki3765@gmail.com

ABSTRACT

Objective: The hypoglycemic, hepatorenalprotective, and antioxidant Activities of *Cyperus rotundus* rhizomes extract in an alloxan-induced diabetic rat model were investigated in this work.

Methods: 25 Male rats were divided into 5 groups: normal control, diabetic control, diabetic of *C. rotundus* (200 mg/kg b.w), diabetic of *C. rotundus* (400 mg/kg b.w), diabetic of glibenclamide (0.6mg/kg). Treatments were administered orally for 6 weeks.

Results: A single injection of alloxan to rats (150mg/kg b.w) caused pathological alterations in all studied parameters and histological structure of the pancreas. On the other hand, results showed that oral administration of *C. rotundus* rhizomes extract in dose of 200 and 400 mg/kg caused significant reduction in glucose, HbA1C%, α -amylase level and plasma lactate together with significant elevation in serum insulin, serum pyruvate with an improvement in insulin resistance. In line with amelioration of the diabetic state, *C. rotundus* rhizomes extract improved of the liver and kidney functions, and oxidative marker levels. Moreover, the extract succeeded to reduce the elevated serum total cholesterol, triglyceride (TG) and low-density lipoprotein- cholesterol (LDL-C) levels and to elevate the reduced high-density lipoprotein- cholesterol (HDL-C) level of diabetic rats.

Conclusion: The investigation data concluded that *C. rotundus* rhizomes extract could be used as alternative treatments as antidiabetic, antioxidant and antihyperlipidemic, and agent as well as in liver and kidney protective in alloxan induced-diabetic rats. This may be related to the presence of saponin glycosides, polyphenols, flavonoids, and terpenoids in the ethanolic extract of *C. rotundus* rhizomes, which was discovered by phytochemical screening in this study to be present in the plant.

Keywords: *Cyperus rotundus* rhizomes, Diabetes, Lipids Profile, Hepatorenalprotective, Oxidative marker

INTRODUCTION

Hyperlipidemia, Hyperglycemia and oxidative stress have become major health concerns in recent years. These parameters are known to be the main risk factors contributing to the development and progression of atherosclerosis and associated cardiovascular and cerebrovascular diseases (Touiss et al., 2019). Diabetes Mellitus (DM) is a chronic metabolic disease that has far-reaching social, health, and economic ramifications (Tarr et al., 2013). The clinical state of prolonged increase in levels of plasma glucose due to ineffective or inadequate amount of insulin is referred as DM. It is the third most leading causes of death among developing countries following heart diseases and cancer which can lead to serious health complications such as cardiovascular disorders, stroke, diabetic retinopathy and kidney dysfunction (Bharathkumar et al., 2014). The prevalence of diabetes in the world was predicted to be 9.3 percent (463 million people) in 2019, and it is expected to rise to 10.2 percent (578 million people) by 2030 and 10.9 percent (700 million people) by 2045 (Saeedi et al., 2019). This demands the use of medicinal plants as a valuable source for the creation of novel medicines since they are effective, have lower costs, and have less side effects than traditional pharmaceuticals sources (Bailey and Day, 1989).

There have been several reports of medicinal plants being utilized as an alternative source of therapy for a variety of pathophysiological diseases, including diabetes mellitus and antioxidants. Among these plants is *C. rotundus* (Nutgrass, family *Cyperaceae*). Throughout the world, this plant may be found in all tropical and subtropical areas, including Yemen, where it has a widespread distribution. In Yemen widely grows between khat tree, with edible, fresh roots (Ibraheem, 2013). The use of this compound in pharmaceutical applications such as anti-inflammatory and antipyretic therapy has gained popularity (Rocha et al., 2020), antirheumatic, antiulceric and antineural agent (Pirzada et al., 2015), anticarcinogenesis effect (Mannarreddy et al., 2017), antibacterial activity (Zhang et al., 2017), antimutagenic activity (Kilani et al., 2007) and also antiaging effect (Nam et al., 2016). The methanolic extract of the rhizome also shown hepatoprotective and antioxidant activity, as well as a suppression

of lipid peroxidation, in addition to other effects (Parvez et al., 2019; Rajakrishnan et al., 2020). Numerous antioxidant assays were performed on the hydroalcoholic extract of *C. rotundus*, including the phosphomolybdenum method to determine antioxidant capacity, total antioxidant activity in linoleic acid emulsion systems to determine total antioxidant activity, DPPH, superoxide, hydroxyl radicals, and NO scavenging activity (Yazdanparast and Ardestani, 2007). As well as hypoglycemic activities (Nishikant and Naresh, 2006; Chaulya et al., 2011; Krisanapun et al., 2012; Raut and Gaikwad, 2012; Singh et al., 2015). Ardestani and Yazdanparast (2007) emphasized the protein glycation inhibitory and antioxidant activities of *C. rotundus*, which they hypothesized might be beneficial in the treatment of diabetes complications and complications of other diseases. The fractionated hydroethanol extract of *C. rotundus* was shown to be extremely efficient in the treatment of rats with alloxan-induced diabetes (Raut and Gaikwad, 2006). Researchers observed that the hydroalcoholic extract of *C. rotundus* was particularly powerful against diabetes-induced cataractogenesis, vision loss, or clouding of the ocular lens (Ramya et al., 2012).

The phytochemical constituents of *C. rotundus* rhizome include Flavonoids, Triterpenoids, Phenylpropanoids, Alkaloids, Phenolic acids, Iridoides, benzodihydrofurans sesquiterpenes and saponins (Sayed et al., 2001, 2007; Chaulya et al., 2011; Srivastava et al., 2013; Zhou and Zhang 2013) that can be responsible for its biological effects like antihyperglycemic, antioxidants and hyperlipidemic.

The importance of the current work is that it studies for the first time the *C. rotundus* rhizomes extract that grows in Yemen, where reviewing the current literature revealed that the *C. rotundus* rhizomes that grows in the Yemen are not investigated for different antihyperglycemic activities. In this study, first we assessed the safety of *C. rotundus* rhizomes extract, by conducting a toxicity test through oral administration to rats (LD₅₀), second we phytochemical screened of *C. rotundus* rhizomes extract for the detection of active components, and after then the evaluated the effects of using *C. rotundus* rhizomes Extract, and its bioactive compounds as an alternative medicine for improvement of the general properties of diabetes, carbohydrate metabolism enzymes and lipids profile, liver and kidney functions in alloxan-induced diabetic rats.

MATERIAL AND METHODS

Animals

Male rats 4-5 months old, weighing 270 - 330 g were obtained from the zoo, Sana'a- Yemen. They were housed in stainless steel cages in a well-ventilated room in animal house of the faculty of Medical Sciences, Al-Razi University. The animals were kept under controlled environmental conditions with free access to standard laboratory diet and water *ad libitum* during the entire period of the study. All animal experiments were carried out in accordance with the Guide for the Care and Use of Laboratory Animals published by the National Institute of Health (NIH, 1978). Animal handling and all related procedures were carried out by the procedures approved by the research committee of faculty of Applied Science, Amran University, Amran, Yemen (o56/FAS/2021).

Chemicals

Alloxan monohydrate was obtained from Sigma Aldrich Chemicals Pvt, Ltd, Bangalore. Glibenclamide was purchased from Chennai, Tamil Nadu (India). Glucometer, was obtained from Roche (Germany), type (Accuchek-Active. Sensitive Rat Insulin RIA kit supplied from Linco Research Inc. (USA). The Spinreact company provided diagnostic kits for the measurement of blood glucose, blood lactate, blood pyruvate, total cholesterol, high density lipoprotein cholesterol (HDL-C), low density lipoprotein cholesterol (LDL-C), triglycerides, alanine aminotransferase (ALT), aspartate aminotransferase (AST), total protein, albumin, urea, and creatinine (Spain). Glycated hemoglobin kit was obtained from Stanbio, San Antonio (USA). China's Shanghai Korian Biotech Company, Yangpu Dist. Shanghai, provided the ultrasensitive rat insulin-enzyme-linked immunosorbent test (ELISA) kit

for this study. All of the other chemicals and reagents were of the greatest quality that could be found on the market.

Plant collection and extract preparation

The rhizomes of *C. rotundus* were collected from Mbin district, Hajjah, Yemen during the April to May 2020, and was identified and authenticated by Dr. Hassan M.H. Sugil, Assistant professor of Plant Taxonomy, Department of Biology, Faculty of Science, Hajjah University, Yemen. The seeds were dried under shade at room temperature then they were finely powdered using an electric mill. The powdered sample (500gm) was extracted with ethanol 70% four times and then put on shaker at 35 °C. After continues shaking for 3 days, the mixture was filtered. The filtrate was completely dried under vacuum in the desiccator.

Oral acute toxicity study (LD₅₀)

OECD-423 criteria for the calculation of LD₅₀ were used to conduct an acute toxicity test on the rhizomes of *C. rotundus* extract in male rats, according to the results of the test. The aim of determination of LD₅₀ for the rhizomes of *C. rotundus* extract was to ensure safety in-vivo and for establishing therapeutic index of particular drug.

Phytochemical analysis

Preliminary phytochemical screening of rhizomes of *C. rotundus* extract was carried out according to the methods described by (Harbourne, 1984) for the detection of active components like carbohydrate, glycosides, alkaloids, flavonoids, steroids, triterpenes, saponins, proteins & amino acids, polyphenols, fixed oils & fats, gums & mucilage, anthroquinones, coumarins, resins and tannins.

Experimental design

Following the establishment of the diabetes model using alloxan (150mg/kg b.w), 25 rats were divided into five groups of 5 animals in each group. Treatments were administered orally for 6 weeks.

Group I: control rats received vehicle solution (Distilled water) 5 ml/kg

Group II: Diabetic rats received vehicle solution (DW) 5 ml/kg

Group III: Diabetic rats treated with rhizomes of *C. rotundus* extract at a dose 1/20 of LD₅₀ (200 mg/kg b.w).

Group IV: Diabetic rats treated with rhizomes of *C. rotundus* extract at a dose 1/10 of LD₅₀ (400 mg/kg b.w).

Group V: Diabetic rats treated with glibenclamide (0.6 mg/kg).

Testing of FBG level and Biochemical evaluation

FBG levels were measured on zero time, 4 h, 6 h, 8 h and 24 h. Also, FBG of weeks 1, 2, 3, 4, 5 and 6 were measured. Blood samples were collected from the tail vein and FBG level was measured using single touch glucometer. Body weight (initial b.w) of each rat was recorded before commencement of treatment, and was recorded at weekly intervals throughout the experimental period i.e., 6 weeks and expressed as % change in body weight compared to initial body weight. At the end of the experiment, all animals were deprived from food for 12 h. Blood samples were taken from the eye and collected into sterile tubes without anticoagulants, and centrifuged at 3000 rpm for 15 min at 4°C to separate the serum for biochemical analysis. Pancreatic tissue samples were carefully dissected and a part of these samples was stored in 10% formalin for histological examination.

Statistical Analysis

The mean±S.E.M value of each parameter was computed considering data on five rats in each group. The mean value of each parameter of normal group and diabetic group were compared using one-way analysis of variance (ANOVA) followed by Duncan's new multiple range test fixing a minimum significance level of $P \leq 0.01$.

RESULTS AND DISCUSSION

Acute toxicity study

Oral treatment of *C. rotundus* rhizomes ethanolic extract in male rats did not cause death and behavioral changes at 4000 mg/ kg b.w. No visible signs of toxicity were reported in the rats treated

with the extract indicating its safety. Accordingly, the LD₅₀ value was found to be higher than 4000 mg/ kg (Table 1). Therefore, *C. rotundus* rhizomes ethanolic extract can be categorized as quietly safe since substances possessing LD₅₀ higher than 500 mg/kg are non-toxic (Buck et al., 1976).

Table (1) LD ₅₀ of <i>C. rotundus</i> rhizomes extract		
Dose	No. of Rats	No. of rat death
500 mg/kg	5	0
1000 mg/kg	5	0
2000 mg/kg	5	0
4000 mg/kg	5	0
LD50 be higher than 4000mg/ kg b.w.		

Result of Phytochemical analysis of *C. rotundus* rhizomes ethanolic extract

Preliminary phytochemical screening of *C. rotundus* rhizomes ethanolic extract positive for carbohydrate, glycosides, alkaloids, steroids, flavonoids, triterpenes, saponins, polyphenols, coumarins, resins and tannins, in contrast the extract tested negative for Proteins & amino acids, fixed oils & fats, gums, mucilage and Anthroquinones, as shown in table 2. The current findings are consistent with those obtained by several investigations, and they indicated that the alcoholic extract of *C. rotundus* rhizomes ethanolic extract contains the following constituents: Flavonoids and phenolic acids are two types of antioxidants (Sayed et al., 2001; Jahan et al. (2013), Triterpenoids (Singh and Sharma 2015), Phenylpropanoids (Zhou and Zhang 2013; Zhang et al., 2017), Alkaloids (Jeong et al., 2000), Iridoides and benzodihydrofurans (Sayed et al., 2007; Zhou et al. 2013; Zhou and Zhang, 2013; Zhang et al. 2017), sesquiterpenes and saponins (Srivastava et al., 2015), tannins, proteins and amino acids (Chaulya et al., 2011), which may be responsible for its biological activities as antihyperglycemic and antioxidants.

Table (2) Phytochemical analysis of rhizomes of <i>C. rotundus</i> extract			
Phytoconstituents	Presence or absent	Phytoconstituents	Presence or absent
Carbohydrate	+	Polyphenols	+
Glycosides	+	Fixed oils & fats	-
Alkaloids	+	Gums & mucilage	-
Steroids	+	Anthroquinones	-
Flavonoids	+	Coumarins	+
Triterpenes	+	Resins	+
Saponins	+	Tannins	+
Proteins & amino acids	-		

Effect of *C. rotundus* rhizomes ethanolic extract on FBG level in Alloxan-diabetic rats at zero time, 2, 4, 8, 24 h, and at 6 weeks

Rats treated with a single injection of alloxan showed gradual increase in blood glucose levels at time 0, 2, 4, 8 and 24 h, in the mean percent 230.2, 280.1, 300.5, 340.7 and 415.8 respectively, as compared to control. Administration of *C. rotundus* rhizomes ethanolic extract (200 and 400 mg/kg b.w) and glibenclamide (0.6 mg/kg b.w) significantly reduced ($p < 0.01$) blood glucose levels with time (0, 2, 4 and 8 h). The onset of antihyperglycemic effect of glibenclamide was 4 h (201.2) and that of the extract at 200 mg/kg by 200.6 and 400 mg/kg by 194.5 were 4 h. The peak of the effect was attained at 8 h but the effect diminished at 24 h was 235 and 221 of the extract at 200mg/kg and 400 mg/kg respectively, and that of glibenclamide was 220, as compared to control (Fig. 1).

A study conducted on alloxan diabetic rats to determine the impact of repeated oral administration of *C. rotundus* rhizomes extract on blood glucose levels is depicted in (Fig. 2). The *C. rotundus* rhizomes extract administered at doses of 200 and 400 mg/kg to alloxan-treated diabetic rats caused significant ($p < 0.01$) reduction of blood glucose level which was related to dose and duration of treatment. Diabetes rats were given rhizomes of *C. rotundus* extract at a dose of 400 mg/kg extract, which had the greatest glucose-lowering impact. When comparing the glibenclamide group to the diabetic control

group, the glibenclamide group demonstrated a substantial drop in blood glucose levels and body weight. Oxygen free radicals have been demonstrated to be involved in the diabetogenic action of alloxan (Heikkila et al., 1974), and antioxidants have been proven to be beneficial in the treatment of diabetes (Lee et al., 2002). Using hydroxyl radical scavengers, researchers were able to protect mice against the diabetogenic effects of alloxan (Heikkila et al., 1976). It has been demonstrated in this study that *C. rotundus* is a radical scavenger, which is a first for this species. Furthermore, it has been observed that *C. rotundus* has an inhibitory impact on the generation of nitric oxide and superoxide in laboratory animals (Seo et al., 2001). This suggests that *C. rotundus*'s antihyperglycemic effect is due to its ability to scavenge free radicals generated by alloxan rather than its antioxidant activity (Nishikant and Naresh, 2006).

Figure (1): Effect of *C. rotundus* rhizomes ethanolic extract on FBG in alloxan-diabetes rats. FBG were assessed at regular interval of zero time, 2, 4, 8 and 24 h. The results are shown as Mean \pm SE. *P < 0.05 compared to normal group.

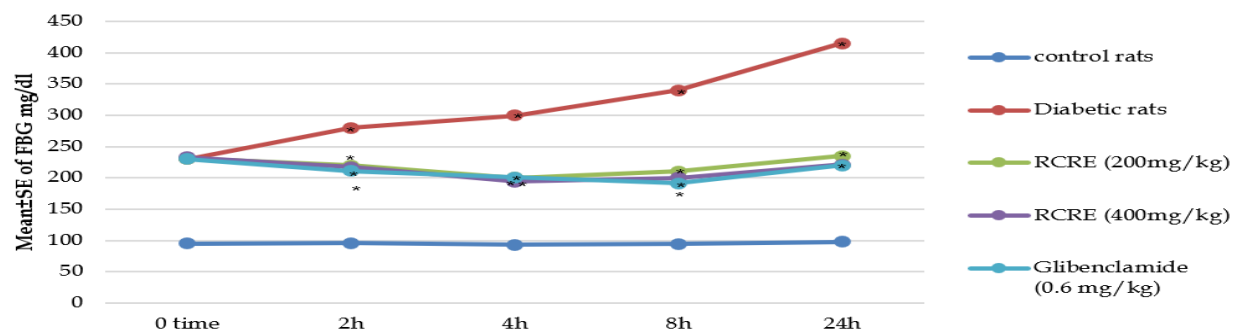
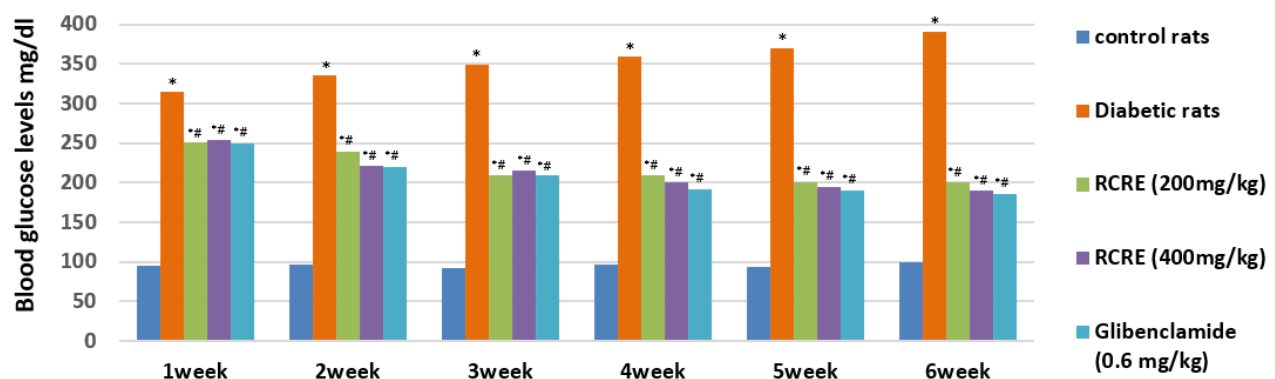


Figure (2): Effect of *C. rotundus* rhizomes extract on Blood glucose levels in alloxan-diabetes rats. Blood glucose levels were assessed of 1-6 weeks. Values are expressed mean \pm S.E.M. *P < 0.01 compared to normal group; #P < 0.01 compared to diabetic control.



Effect of *C. rotundus* rhizomes ethanolic extract on general properties of diabetes and carbohydrate metabolism enzymes in Alloxan induced-diabetic rats.

As demonstrated in table 3, rats in the alloxan-treated diabetic group had significantly higher blood glucose, HbA1C percent, and lactate levels, as well as significantly lower serum insulin and serum pyruvate levels, as compared to control rats. In contrast, a significant reduction in blood glucose

together with significant elevation in serum insulin and serum pyruvate with the concomitant elevation of plasma lactate was observed in diabetic rats treated with rhizomes extract of *C. rotundus* in dose of 200 and 400 mg/kg for 6 weeks, this marked improving could be related to the improvement in insulin release from the existing β -cells of the pancreas that resulted in improvement the glycemic state because of the presence of active compounds like flavonoids that have strong antioxidant properties, "as they are scavengers of reactive oxygen species and diminish their toxic properties" (Duthie and Crozier, 2000). *C. rotundus* rhizomes extract enhanced glucose usage in diabetic rats by boosting insulin secretion (perhaps owing to saponin and polyphenol concentration) and reducing hyperglycemia (may be due to total polyphenols content) (Sarin, 2015; Nishikant and Naresh, 2006). According to Srivastava et al. (2013), the active component in *C. rotundus* rhizomes, saponin and glycoside, increases insulin secretion. Flavonoids have been shown to repair damaged cells in diabetic rats with alloxan (Chakravarthy et al., 1980). Antihyperglycemic phenolics have been discovered to be beneficial (Manickam et al., 1997).

The levels of α -amylase are determined for diagnosing acute pancreatitis and other pancreatic disorders. In diabetic rats, α -amylase activity was higher than in nondiabetic rats, according to our findings. On the other hand, α -amylase activity reduced in the diabetic rats to 49.34 and 47.92 U/L after treatment with rhizomes extract of *C. rotundus* in dose of 200 and 400 mg/kg, respectively (Table 3). The results of the biochemical analyses were confirmed by the histopathological changes observed in the pancreas of the diabetic rats in the form of destruction and atrophy of β -cells in Langerhans islets. Several studies have reported that high levels of serum pancreatic amylase and lipase were associated with the development of DM and acute pancreatitis (Gandhi and Kulkarni, 2012; El-Desouki et al., 2015; Al-Awar, 2019). The number of β -cells and the size of the islet of Langerhans increased in diabetic rats treated with *C. rotundus*.

The oral administration of resulted in the recovery of partially destroyed β -cells, in addition to normalization of the cell size, increase in β -cell numbers, and prevention of β -cell necrosis, which clearly demonstrated the protective effects of *Spirulina* on the pancreas (Priyanka et al., 2017). Methanol extracts of *C. rotundus* rhizomes inhibited the enzymes α -glucosidase and α -amylase, indicating that they had anti-diabetic properties (Tran et al., 2014).

Insulin resistance (IR) is the major hallmark for determining the etiology and pathogenesis of DM. Our results revealed the effect of *S. platensis* biomass, phycocyanin and phycocyanopeptide on IR (HOMA-IR score) and β -cell function (HOMA- β) score in the diabetic rats (Table3). Our findings revealed that when comparing the diabetes control group to the normal control group, IR (HOMA-IR score) rose in the diabetic control group, whereas it reduced in all treatment groups when compared to the diabetic control group. Furthermore, diabetic control rats' pancreatic-cell function was reduced as compared to normal control rats. The HOMA- β score was higher in the diabetic rats administered rhizomes extract of *C. rotundus* compared with the diabetic control rats in the following order: rhizomes extract of *C. rotundus* in dose of 200 mg/kg > rhizomes extract of *C. rotundus* in dose of 400 mg/kg > Glibenclamide (10.49 mg/dL). Administration of rats with alloxan causes a rapid damage to pancreatic β -cells, resulting in impairment of glucose levels and stimulation of insulin excretion. The increase in blood glucose levels may be due to the decrease in the transport of glucose to different tissues and the increase in glycogen breakdown and glucose production in the liver (Priyanka et al., 2017).

Table 3. Effect of *C. rotundus* "rhizomes ethanolic extract on general characteristics of diabetes and carbohydrate metabolism enzymes in Alloxan" induced-diabetic rats

Parameters	Groups				
	Normal Control	Diabetic Control	Diabetic of <i>C. rotundus</i> (200 mg/kg b.w)	Diabetic of <i>C. rotundus</i> (400 mg/kg b.w)	Glibenclamide (0.6 mg/kgb.w)
Glucose (mg/dl)	83±2.65	371±2.52*	171 ±2.52*#	169±4.04*#	168±5.57*#
Insulin (μ U/ml)	15.06±0.05	6.56±0.49*	10.49±0.05*#	11.90 ±0.09*#	12.07±0.21*#
HbA1C%	5.7±1.1	13.6±1.6*	8.9±1.5*#	8.1±1.3*#	7.9±1.2*#
α -amylase (U/L)	25.72±2.05	95.32±3.04*	49.34±2.35*#	47.92±3.03*#	65.58±3.05*#

treated with rhizomes extract of *C. rotundus* in dose of 200 and 400 mg/kg was similar to that in the group treated with glibenclamide (Table 4). Our results indicate that liver function levels can be maintained in the Alloxan-induced diabetic rats after treatment with *C. rotundus* rhizomes. Furthermore, the hepatoprotective effect of *C. rotundus* rhizomes might be attributed to the presence of flavonoids and phenolic compounds, both of which are known to have antioxidant properties (Chaulya et al., 2010). Thus, the current study shows that *C. rotundus* rhizome's hepatoprotective effect is related to its free radical scavenging ability against alloxan-induced free radicals.

Table 4. Effect of *C. rotundus* rhizomes ethanolic extract on Liver function test in Alloxan induced-diabetic rats

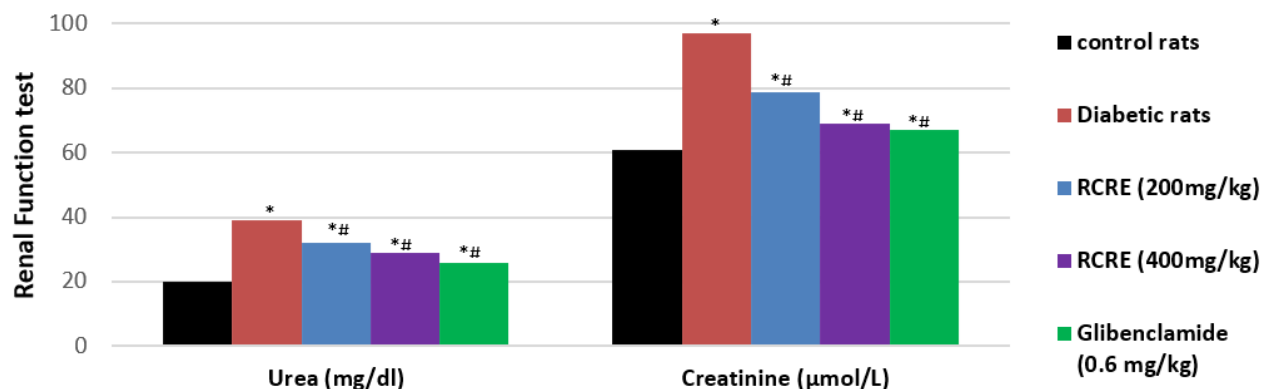
Parameters	Groups				
	Normal Control	Diabetic Control	Diabetic of <i>C. rotundus</i> (200 mg/kg b.w)	Diabetic of <i>C. rotundus</i> (400 mg/kg b.w)	Glibenclamide (0.6 mg/kgb.w)
ALT (U/L)	25.3±2.33	80.5±3.11*	52.7±2.19*#	45.8±2.56*#	40.6±3.19*#
AST (U/L)	45.5±3.89	99.8±4.89*	54.8±4.32*#	55.9±3.39*#	43.6±3.98*#
Protein (g/dl)	6.9±0.65	4.6±0.78*	6.0±0.64*#	6.1±0.72	6.2±0.71
Albumin (g/dl)	4.2±0.32	2.1±0.09*	3.1±0.11*#	3.5±0.21*#	3.7±0.38*#

Values are expressed means±S.E.M. *P < 0.01 compared to normal group; #P < 0.01 compared to diabetic control.

Effect of *C. rotundus* rhizomes extract on renal functions tests in alloxan-diabetes rats

The blood urea and creatinine levels of alloxan-induced diabetic rats increased (Fig.4), which might be attributed to a decrease in the glomerular filtration rate, which eventually leads to renal failure (Priyanka et al., 2017). We also observed high levels of creatinine and urea in the diabetic rats than in the normal control group (Figure 4). The urea and creatinine levels of rats according to the treatment were as follows: phycocyanopeptide, 20.07 and 0.653 mg/dL, respectively; *S. platensis* biomass, 31.57 and 0.974 mg/dL, respectively; and phycocyanin, 30.47 and 0.961 mg/dL, respectively. These values were lower than those in the diabetic control group (42.45 and 2.51 mg/dL, respectively) (Fig.4). Because of the antioxidant properties of *C. rotundus*, renal function was improved via reduction in oxidative stress-mediated failure in kidney function (Krisanapun et al., 2012).

Figure (4): Effect of *C. rotundus* rhizomes extract on renal function tests in alloxan-diabetes rats. *P < 0.01 compared to normal group; #P < 0.01 compared to diabetic control.



Effect of *C. rotundus* rhizomes extract on MDA, SOD and catalase in alloxan-diabetes rats

It's clear from Table 5 that rats with diabetes have higher serum MDA levels than rats who aren't diabetic. Administration of rhizomes extract of *C. rotundus* (200 and 400 mg/kg) and led to a significant decrease in the MDA content compared to the normal control group. Also, table 5 shows the SOD and catalase level in diabetic group is significantly lower in comparison to the control group. For the treatment groups, there is a dose-dependent increased significantly in SOD and catalase level as compared with the diabetic control group. Treatment with *C. rotundus* rhizomes extract leads to a reduction of lipid peroxidation and a decrease in the production of free radical derivatives as indicated by the rise serum MDA levels and lowered SOD and catalase levels (Hu et al., 2017). Various antioxidant assays, such as antioxidant capacity by the phosphomolybdenum method, total antioxidant activity in linoleic acid emulsion systems, DPPH, superoxide, hydroxyl radicals, and NO scavenging, were used to confirm the antioxidative potential of the hydroalcoholic extract of *C. rotundus* (Yazdanparast and Ardestani, 2007). Furthermore, using *C. rotundus* rhizomes improved free radical scavenging activity and reduced tissue damage (Hu et al., 2017).

Table 5. Effect of *C. rotundus* rhizomes ethanolic extract on MDA, SOD and CAT in Alloxan induced-diabetic rats

Parameters	Groups				
	Normal Control	Diabetic Control	Diabetic of <i>C. rotundus</i> (200 mg/kg b.w)	Diabetic of <i>C. rotundus</i> (400 mg/kg b.w)	Glibenclamide (0.6 mg/kg b.w)
MDA ($\mu\text{mol/g}$)	16.1 \pm 1.23	41 \pm 2.31*	28.3 \pm 1.13*#	24.8 \pm 1.89*#	38.1 \pm 2.34*#
SOD (U/g)	2.45 \pm 0.20	0.17 \pm 0.01*	1.9 \pm 0.12*#	1.4 \pm 0.10*#	0.57 \pm 0.03*#
CAT (kU/L/g)	69.34 \pm 3.71	53.6 \pm 2.32*	65.7 \pm 3.18*#	66.8 \pm 4.15*#	58.7 \pm 3.98*#

Values are expressed means \pm S.E.M. *P < 0.01 compared to normal group; #P < 0.01 compared to diabetic control.

Histopathological Results of pancreas

The histological structure of the pancreas in diabetic control rats showed normal architecture of normal acini (exocrine cells) and normal cellular population in the islets of Langerhans (endocrine cells) (Fig. 4a). The light microscopic analysis of diabetic rats, on the other hand, revealed pathological alterations in the endocrine portion of the pancreas, as evidenced by the loss and shrinkage of islets of Langerhans, vasodilation of blood vessels, and infiltration of inflammatory cells (Fig. 4b). Treatment of rhizomes with ethanolic extract (200 and 400 mg/kg) for 6 weeks resulted in an improvement and regeneration of β -cells in the islets of Langerhans, as well as an increase in the number of islets of Langerhans in the majority of the sections tested. The antihyperglycemic action that occurred through the regeneration of β -cells potentiated the pancreatic secretion of insulin (Priyanka et al., 2017).

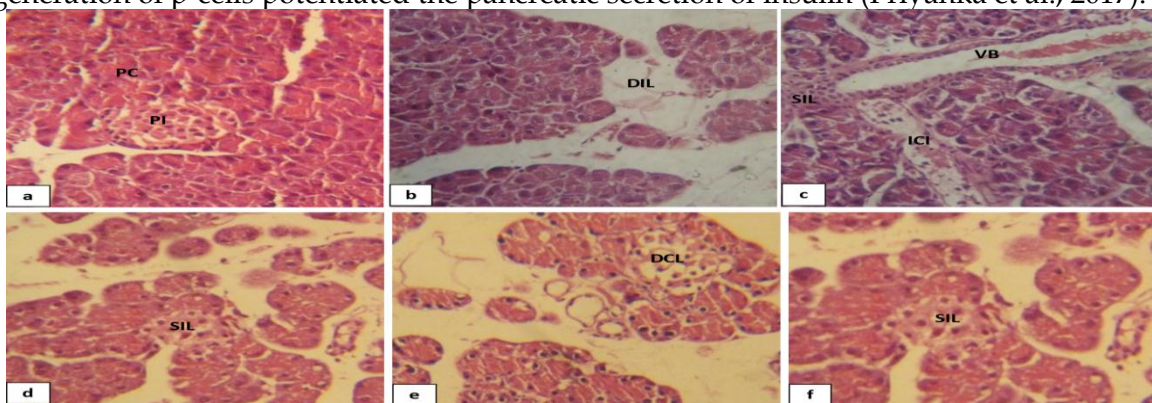


Figure (4): Photomicrographs of sections of the pancreases. (a): Normal control group showing a normal architecture without pathological alterations. Pancreatic cells (Exocrine glands; PC), Pancreatic islet (Endocrine glands; PI). (b,c): Diabetic control; showing of disappearance islets of Langerhan's (DIL); Shrinkage islets of Langerhan's (SIL); Vasodilation of Blood vessels (VB); Inflammatory cells infiltration (ICI). (d): Diabetic of *C. rotundus* (200 mg/kg) showing of Shrinkage islets of

Langerhan’s (SIL); (e): Diabetic of *C. rotundus* (400 mg/kg) showing of Decrease in islets cells of Langerhan’s and Shrinkage (SIL) (e): glibenclamide; showed no Shrinkage islets of Langerhan’s (SIL) (HE) stain.

CONCLUSION

According to the findings of the study, *C. rotundus* rhizomes extract significantly reduced the severity of diabetes diseases in rats produced by alloxan. *C. rotundus* rhizomes extract includes active components such as saponin glycosides, polyphenols, flavonoids, and terpenoids, all of which have the potential to perform various activities through a variety of pathways, including hypoglycemic and antihyperglycemic effects on glucose levels. In addition to boosting insulin release from the residual - cells, blocking glucagon secretion from β -cells, increasing antioxidant processes, and attenuating meal-derived glucose absorption, these suggested pathways include. In accordance with the amelioration of the diabetic condition, *C. rotundus* rhizomes extract was shown to have a beneficial effect on the diabetic rats' disordered glucose metabolism. Moreover, they succeeded to normalize the lipids profile levels and improved liver and kidney function of diabetic rats and in liver and kidney protective as well.

ABBREVIATIONS

C. rotundus: *Cyperus rotundus*.; b.w: Body weight.; TG: triglyceride.; LDL-C: Low Density Lipoprotein-Cholesterol.; VLDL: Very Low Density Lipoprotein- Cholesterol.; HDL-C: High Density Lipoprotein-Cholesterol.; T. Cholesterol.; Total Cholesterol.; DM: Diabetes Mellitus.; DPPH: 2,2'-diphenyl-1-picrylhydrazyl radical.; NO: Nitric oxide.; LD₅₀: Lethal Dose, 50%.; NIH: National Institute of Health.; ALT: Alanine Aminotransferase.; AST: Aspartate Aminotransferase.; ELISA: Enzyme linked immunsorbent assay.; OECD-423: Organisation For Economic Co-Operation and Development.; FBG: Fasting Blood Glucose.; ANOVA: one-way analysis of variance.; HbA1C: Hemoglobin A1C.; HOMA-IR: Homeostatic Model Assessment for Insulin Resistance.; ISO: Isoproterenol.; SOD: Determination of superoxide dismutase.; MDA: Malondialdehyde.

ACKNOWLEDGEMENTS

“The authors are thankful for Amran university for its support.”

DECLARATION

Ethics approval and consent to participate

All animal experiments were carried out in accordance with the Guide for the Care and Use of Laboratory Animals published by the National Institute of Health (NIH, 1978). Animal handling and all related procedures were carried out by the procedures approved by the research committee of faculty of Applied Science, Amran University, Amran, Yemen (o56/FMS/2021).

Consent for publication

Not applicable.

Availability of supporting data

Data are available from the corresponding author on a reasonable request.

Competing interests

The authors declare that no competing interests.

Funding

This research received no funding.

Author Contributions:

Contribution	Al-Awar MS	Alqabbani T.Y
Concepts or Ideas	✓	
Design	✓	✓
Definition of intellectual content	✓	✓

Literature search	✓	
Experimental studies	✓	
Data acquisition	✓	
Data analysis		✓
Statistical analysis		✓
Manuscript preparation	✓	
Manuscript editing	✓	✓
Manuscript review	✓	✓
All authors have read and agreed to the published version of the manuscript.		

REFERENCE

- Ardestani A, Yazdanparast R (2007) *C. rotundus* suppresses AGE formation and protein oxidation in a model of fructose-mediated protein glycoxidation. *Int J Biol Macromol* 41: 572-578.
- Al-Awar M S (2019) Anti-diabetic Activities of *Zizyphus spina-christi* Seeds Embryos Extract on General Characteristics of Diabetes, Carbohydrate Metabolism Enzymes and Lipids Profile in Rats. *Jordan J of Pharmaceutical Sci*, 12(2):91-107.
- Bailey LJ, Day C (1989) Traditional plant medicine as treatment for diabetes. *Diabe Care* 12: 553-564.
- Bharathkumar H, Sundaram M S, Jagadish S, Paricharak S, Hemshekhar M, Mason D, Kemparaju K, Girish K S, Bender A, Rangappa K S (2014) Novel benzoxazine-based aglycones block glucose uptake in vivo by inhibiting glycosidases. *PloS one* 9: e102759.
- Chakravarthy B K, Gupta S, Gambir S S, Gode K D (1980) Pancreatic beta cell regeneration – a novel antidiabetic mechanism of *Pterocarpus marsupium* roxb. *Indian J Pharmacol* 12:123.
- Chaulya N C, Haldar P K, Mukherjee A (2010) In-vitro free radical scavenging activity of methanol extract of rhizome of *Cyperus tegetum* Roxb (Cyperaceae). *Int J Curr Pharm Res* 2:39-43.
- Chaulya N C, Haldar P K, Mukherjee A (2011) Antidiabetic Activity of Methanol Extract of Rhizomes of *Cyperus Tegetum* Roxb. (Cyperaceae). *Acta Poloniae Pharmaceutica Drug Res* 68(6): 989-992.
- Duthie G, Crozier A (2000) Plant-derived phenolic antioxidants. *Current Opinion in Clin Nutr Metabo Care* 3:447-45.
- El-Desouki N I, Tabl G A, Abdel-Aziz K K, Salim E I, Nazeeh N (2015) Improvement in beta-islets of Langerhans in alloxan-induced diabetic rats by erythropoietin and *Spirulina*. *J of Basic Appl Zoology* 71: 20-31.
- Gandhi G R, and Kulkarni P (2012) Antidiabetic effect of *Merremia emarginata* Burm. F. in streptozotocin induced diabetic rats. *Asian Pac J Trop Biomed* 63: 281-286.
- Garg H (2017) Evaluation of Antihyperlipidemic Activity of The Plant *C. rotundus* on Poloxamer Induced Hyperlipidemic Rats. *World J Pharmaceutical Res* 1355-1363.
- Harbourne J B (1984) *Phytochemical Methods. A guide to modern techniques of plant analysis*. 2nd ed Chapman and Hall London. 1984: p282.
- Heikkila R E, Benden H, Cohen G J (1974) *Pharmacol Exp Ther*. 190: 501.
- Heikkila R E, Winstor B, Cohen G, Barden H (1976) *Biochem Pharmacol*. 25: 1085.
- Hu Q P, Cao X M, Hao D L, Zhang L L (2017). Chemical composition, antioxidant, DNA damage protective, cytotoxic and antibacterial activities of *C. rotundus* rhizomes essential oil against foodborne pathogens. *Sci Rep* 7: 45231.
- Hye K K, Mi Jeong K, Eun Soon L, DongHoon S (2009) Improvement of Diabetic Complication by *Hydrangea Dulcis Folium* in Streptozotocin-Induced Diabetic Rats. *Biol Pharm Bull* 32(1):153-156.
- Ibraheem HM (2013) Ph.D. Thesis, Department of Biology Faculty of Science Sana'a University Yemen.

- Jahan N, Khalil-Ur-Rahman A S, Asi M R (2013) Phenolic acid and flavonol contents of gemmo-modified and native extracts of some indigenous medicinal plants. Pak. J Bot 45: 1515-1519.
- Jahan N, Rahman K U, Ali S (2012) Cardioprotective and antilipidemic potential of *C. rotundus* in chemically induced cardiotoxicity. Int J Agric Biol 14:989-992.
- Jeong S J, Miyamoto T, Inagaki M, Kim Y C, Higuchi R (2000) Rotundines A-C, three novel sesquiterpene alkaloids from *C. rotundus*. J Nat Prod 63: 673-675.
- Kilani S, Bouhle I, Ben Ammar R, Ben Sghair M, Skandrani I, Boubaker J, Mahmoud A, Dijoux-Franca M G, Ghedira K, Chekir Ghedira L (2007) Chemical investigation of different extracts and essential oil from the tubers of (Tunisian) *C. rotundus*. Correlation with their antiradical and antimutagenic properties. Ann Microbiol 57: 657-664.
- Krisanapun C, Wongkrajang Y, Tamsiririrkkul R, Kongsaktrakoon B, Peungvicha P (2012) Anti-diabetic effect and acute toxicity of the water extract of *C. rotundus* L in rats. FASEB J 26: 686-688.
- Krisanapun C, Wongkrajang Y, Tamsiririrkkul R, Kongsaktrakoon B, Peungvicha P (2012). Anti-diabetic effect and acute toxicity of the water extract of *C. rotundus* L. in rats. FASEB J 26: 686-688.
- Lee S E, Ju E M, Kim J H (2002) Free radical scavenging and antioxidant enzyme fortifying activities of extracts from *Smilax china* root. Exp Mol Med 33(4):263-268.
- Manickam M, Ramanathan M, Farboodinay J M, Chansouria J P, Ray A B (1997) Antihyperglycemic activity of phenolics from *Pterocarpus marsupium*. J Nat Prod 60: 609.
- Mannarreddy P, Denis M, Munireddy D, Pandurangan R, Thangavelu K P, Venkatesan K (2017) Cytotoxic effect of *C. rotundus* rhizome extract on human cancer cell lines. Biomedicine Pharmacotherapy 95:1375-1387.
- Nam J H, Nam D Y, Lee D U (2016) Valencene from the rhizomes of *C. rotundus* inhibits skin photo aging-related ion channels and UV-induced melanogenesis in B16F10 melanoma cells. J Nat Prod 79(4): 1091-1096.
- Nishikant A R, Naresh J N (2006) Antidiabetic activity of hydro-ethanolic extract of *C. rotundus* in alloxan induced diabetes in rats. Fitoterapia 77: 585-588.
- Okwu G N, Abanobi S E, Nnadi U V, Ujowundu C O, Ene A (2015) C. Hypolipidemic Properties of Ethanol Extract of *C. rotundus* Rhizome. Int. J. Bioche Res Rev 7(3):132-138.
- Parvez M K, Al-Dosari M S, Arbab A H, Niyazi S (2019) The in vitro and in vivo anti-hepatotoxic, anti-hepatitis B virus and hepatic CYP450 modulating potential of *C. rotundus*. Saudi Pharmaceutical Journal 27: 558-564.
- Pirzada A M, Ali H H, Naeem M, Latif M, Bukhari A H, Tanveer A (2015) *C. rotundus* L. Traditional uses, phytochemistry, and pharmacological activities. J Ethnopharmacol 4: 540-560.
- Priyanka D, Debasmita G D, Rawat A K, Srivastava S (2017) Medicinal chemistry and biological potential of *C. rotundus* Linn.: An overview to discover elite chemotype(s) for industrial use. Industrial Crops & Products 108: 232-247.
- Rajakrishnan R, Alfarhan A H, Al-Ansari A M, Lekshmi R, Sreelakshmi R, Benil P B, Kim Y O, Tack J C, Na S W, Kim H J (2020) Therapeutic efficacy of the root tubers of *Aconitum heterophyllum* and its substitute *C. rotundus* in the amelioration of pylorus ligation induced ulcerogenic and oxidative damage in rats. Saudi Journal of Biological Sciences 27:1124-1129.
- Ramya P, Seema S, Vijayalakshmi K (2012) Impact of hydro alcoholic extract of *C. rotundus* on glucose induced cataract –an in-vitro study. Int J Pharm Biol Sci 2: 320-331.
- Raut N A, Gaikwad N J (2006) Antidiabetic activity of hydro-ethanolic extract of *C. rotundus* in alloxan induced diabetes in rats. Fitoterapia 77: 585-588.
- Rocha F G, Margareth de Mello B, Pawloski P L, Bruna da Silva Soley D S, Costa S C, Meinerz C C, Baretta I P, Otuki M F, Cabrini D A (2020) Preclinical study of the topical anti-inflammatory activity of *C. rotundus* L. extract (Cyperaceae) in models of skin inflammation. Journal of Ethnopharmacology 254:112709.

- Saeedi P, Petersohn I, Salpea P, Malanda B, Karuranga S, Unwin N, Colagiuri S, Guariguata L, Motala A A, Ogurtsova K (2019) Global and regional diabetes prevalence estimates for 2019 and projections for 2030 and 2045: Results from the International Diabetes Federation Diabetes Atlas. Diabetes research and clinical practice. 157: 107843.
- Sarin R, Samariya K (2015) In vivo and in vitro investigations on rotenoids from *C. rotundus* (Linn.). Am J Pharm Health Res 3: 2321-3647.
- Sayed H M, Mohamed M H, Farag S F, Mohamed G A (2001) Phytochemical and Biological Studies of *C. rotundus* L. growing in Egypt. Bulletin of Faculty of Pharmacy Cairo University 195-203.
- Sayed H M, Mohamed M H, Farag S F, Mohamed G A, Proksch P (2007) A new steroid glycoside and furochromones from *C. rotundus* L Nat Prod Res 21: 343-350.
- Seo W G, Pae H O, Oh G S, Chai K Y, Kwon T O, Yun Y G (2001) Inhibitory effects of methanol extract of *C. rotundus* rhizomes on nitric oxide and superoxide productions by murine macrophage cell line, RAW 264.7 cells. J Ethnopharmacol 76:59-64.
- Singh P, Khosa R L, Mishra G, Jha K K (2015). Antidiabetic activity of ethanolic extract of *C. rotundus* rhizomes in streptozotocin-induced diabetic mice. J Pharm Bioallied Sci 7: 289-292.
- Srivastava R K, A. Singh S, Shukla V (2013) Chemical investigation and pharmaceutical action of *C. rotundus* – a review. J Biol Active Prod 3: 166-172.
- Tarr J M, Kaul K, Wolanska K, Kohner E M, Chibber R (2013) Retinopathy in diabetes. Diabetes 88: 106.
- Touiss I, Harnafi M, Khatib S, Bekkouch O, Ouguerram K, Amrani S Harnafi H (2019) Rosmarinic acid-rich extract from *Ocimum basilicum* L. decreases hyperlipidemia in high fat diet-induced hyperlipidemic mice and prevents plasma lipid oxidation Physiol Pharmacol 23: 197-207.
- Weggemans R M, Trautwein E A (2003) Relation between soy-associated isoflavones and LDL and HDL cholesterol concentrations in humans: a Meta analysis. European J Clin Nutri 57(8):940-946.
- Yazdanparast R, Ardestani A (2007) In vitro antioxidant and free radical scavenging activity of *C. rotundus* . J Med Food 10: 667-674.
- Zargar A, Wandroo F A, Wadhwa M, Laway B, Masoodi S R, Shah N A (1995) Serum Lipid Profile in Non-insulin-dependent Diabetes Mellitus Associated with Obesity. Int J Diab Dev Countries 15:9-13.
- Zhang L L, Zhang L F, Qing-Ping Q, Hao D O, Jian J G (2017) Chemical composition, antibacterial activity of *C. rotundus* rhizomes essential oil against *Staphylococcus aureus* via membrane disruption and apoptosis pathway. Food Control 80: 290-296.
- Zhang X M, Qu SC, Sui D Y, Yu X F, Lv Z Z (2004) Effects of ginsenoside-Rb on blood lipid metabolism and anti-oxidation in hyperlipidemia rats 29(11):1085-1088.
- Zhao L, Sim S, Shim H, Ha W (2005) Antiobese hypolipidimic effects of platycodin saponins IN diet induced obese rats: Evidence for lipase inhibition and calorie intake restriction. Inter J Obese 29:983-990.
- Zhou Z, Zhang H (2013) Phenolic and iridoid glycosides from the rhizomes of *C. rotundus* . L Med Chem Res 22: 4830-4835.