

Case Report

Early Childhood Tooth Bud Removal Practice (“Ibyinyo”): Preventable Dental Damage

Nsabimana Evariste¹, Muhire Valens¹, Uwayezu Donat¹, Eleana Stoufi^{1,2} & Mohammed S. Razzaque^{1,2,3}

¹ Department of Preventive & Community Dentistry, University of Rwanda School of Dentistry, Kigali, Rwanda

² Department of Oral Health Policy & Epidemiology, Harvard School of Dental Medicine, Boston, MA, USA.

³ Department of Pathology, Lake Erie College of Osteopathic Medicine, Erie, PA, USA.

Key Words: Malpractice, Ibyinyo, Tooth bud extraction, Ectopic eruption

Correspondence: mrzzaque@lecom.edu (M. S. Razzaque)

Abstract

Tooth bud removal called Ibyinyo is the practice of removing the developing tooth buds, usually done on an infant, typically performed by traditional healers who believe that this practice will reduce fever and diarrhea in children. This practice is most prevalent in East-African countries, including Rwanda. These procedures are mostly performed in non-sterile conditions using basic sharp instruments. We will discuss the case of a 10-year-old female patient who was presented at the dental clinic, with two malformed permanent canine teeth. Clinical examination revealed malformed enamel and elongated permanent right maxillary canine tooth left mandibular canine tooth with crown malformation. She was also presented with retained (primary) left maxillary lateral incisor tooth and missing left maxillary canine tooth. In addition, the ectopic eruption of left maxillary central incisor tooth and missing permanent right mandibular canine tooth were noted. All these complications resulted from tooth bud removal that the patient had experienced in her early childhood. Her malformed right maxillary and left lower mandibular canine teeth were reshaped, using composite filling materials, to improve her appearance aesthetically. Ibyinyo is preventable damage, done out of ignorance and superstitious practices that can be stopped by growing social awareness. Therefore, educating parents through community-based campaigns on the detrimental consequences of early childhood tooth bud removal through Ibyinyo practice might be helpful to eradicate this harmful and unnecessary practice.

Keywords: Ectopic eruption, Ibyinyo, malpractice, tooth bud extraction

INTRODUCTION

Tooth bud extraction involves the scooping of an infant's healthy deciduous tooth germs, and the extracted tooth buds commonly referred to as false teeth "Ibyinyo." While developing mandibular deciduous canines, tooth germs are easily noticed as the whitish swelling. The traditional healers, who have no medical training, usually misinterpret this as worms responsible for the child's illness, and therefore, they attempt to remove them.^[1,2] They perform this procedure, which is mostly done in non-sterile conditions using basic sharp instruments such as regular knives, razor blades, bicycle spokes, fingernails, and hot nails, without anaesthesia. In

many reported cases, canine tooth buds are removed bilaterally, and affected children possess either two or four missing primary teeth.^[3-7]

Tooth bud removal is generally performed in children between 3 months and 6 years of age, with a peak age between 4 and 18 months. This practice has been reported in many African countries, including Sudan, Tanzania, Kenya, Ethiopia, Uganda, Somalia, Congo, Burundi, Chad, Rwanda and Burkina-Faso.^[3,4,6] Canine tooth bud extraction seems to be a challenge in developing communities including Rwanda where there is a small number of dentists and medical professionals to provide dental care service to a large population. Due to a shortage of professional dental health-care providers many people turn to traditional healers in their communities.

We present a case of malformed canine teeth in a child whose mother reported that she has dog-like teeth, with a history of canine tooth bud extraction. This case report aims to present the unusual clinical presentation due to infant oral mutilation with malformed teeth, with possible psychosocial, economic, and health implications following this practice of tooth buds removal and to increase the community awareness on the complications resulting from it, as well as to counsel the parents against this harmful practice.

CASE REPORT

This is a case report of a 10-year-old Rwandan female patient received at the Dental Consultancy Centre of the University of Rwanda College of Medicine and Health Sciences Polyclinic. The informed consent was obtained from the patient and from her parents to use the following information for this publication.

The patient's main complaint was the unpleasant appearance of the right anterior upper and lower teeth for the past 5 years, as seen in the pre-treatment images [Figures 1 and 2]. This unpleasant appearance of the tooth caused her to be humiliated by her fellow students and friends and prevented her from smiling in public places, especially when she was with other children. The history of the four canine tooth bud extraction when she was an infant was reported by her

mother. The intraoral examination revealed malformed enamel and elongated permanent right maxillary canine and permanent mandibular left canine, left maxillary lateral incisors (retained), missing left maxillary canine, the ectopic eruption of left maxillary central incisor, left mandibular canine with crown malformation and missing permanent right mandibular canine.

The panoramic radiographic view [Figure 3] demonstrating the upper dental arch showed the permanent maxillary right canine is erupting, retained deciduous maxillary left lateral incisor which had displaced the permanent maxillary left lateral incisor in the place of the erupting permanent canine. For the lower dental arch, the permanent mandibular right canine was still erupting, and the permanent mandibular left canine was present with abnormal crown morphology.

Treatment plan

After the clinical examination and radiographic investigation, the suggested following treatment plan was explained to and discussed with the patient:

- Crown shaping and contouring of permanent maxillary right canine and permanent mandibular left canine [Figures 1 and 2] to improve her aesthetic appearance
- Extraction (removal) of retained maxillary left lateral incisor to provide space for the erupting permanent maxillary left canine
- Extraction of the right mandibular deciduous first molar to provide space so that the right mandibular canine will erupt [Figure 3]
- Extraction of primary maxillary left deciduous first molar, which is grossly decayed, to control the pain
- Filling of the occlusal-mesial cavity with glass-ionomer filling material on primary maxillary right first molar to prevent extensive decay, which might lead to early tooth loss

- Follow-up every 3 to 6 months for the close monitoring of the dentition status of the patient. The retained maxillary left lateral incisor has been extracted; the crown shaping, contouring and bonding with composite were done [Figures 4 and 5], and the patient is now comfortable with her appearance and smile.

DISCUSSION

The presented case shows the consequences of tooth bud removal that the patient had undergone in her early childhood. The patient presented with malformed enamel and an elongated permanent right maxillary canine tooth and left mandibular canine tooth. The patient also showed crown malformation, retained (primary) left maxillary lateral incisor tooth, and missing left maxillary canine tooth; there was an ectopic eruption of left maxillary central incisor tooth, and the missing permanent right mandibular canine tooth, caused by the trauma induced by Ibyinyo practice. Some of the complications of the current patient are similar to those reported earlier by the Ibyinyo practice.^[1,2,5]

In addition to the above-mentioned oral complications, this traditional harmful practice has systemic health risks, such as blood-borne diseases, like HIV, hepatitis, and septicemia, which can be associated with blood transmission in patients with severe blood loss following Ibyinyo practice.^[7,8]

In our case, the patient presented psychosocial and emotional complaints of harassment, isolation, the avoidance of smiling in public places. The cumulative effect of such psychosocial behavior may adversely impact social life, studies, and work. This traditional practice (Ibyinyo) has a far-reaching impact not only on psychosocial, but it can also create a financial burden when the patient requires expensive orthodontic treatment to fix the teeth and deformities. Despite complications caused by the Ibyinyo practice, studies have shown that people still keep practicing it in different parts of Africa; as well as in some European and Asian countries, among African immigrants. This implicates that the strong traditional beliefs and practices are not easy to control, reduce, or eradicate, when people migrate to a different continent.^[2,6,9,10]

CONCLUSION

Premature tooth bud extraction is a common traditional practice among East-African communities with deep-rooted cultural beliefs. Educating parents through community-based campaigns on the detrimental consequences of canine tooth bud removal is necessary to increase their knowledge of Ibyinyo malpractice. The public health authority should initiate educational programs, involving local community health workers, to educate and encourage the traditional healers to stop harmful malpractice of Ibyinyo.

REFERENCES

1. Teshome A, Andualem G, Seifu S, Tsegie R. Knowledge, attitude and practice of mothers towards canine tooth bud removal and associated factors among mothers visiting dental clinic of Gondar University Hospital, Ethiopia. *J Community Med Health* 2016;6:396.
2. Noman AV, Wong F, Pawar RR. Canine gouging: A taboo resurfacing in migrant urban population. *Case Rep Dentist* 2015;2015:727286. [doi.org/10.1155/2015/727286].
3. Elinor A, Graham PK, Lynch H, Egbert MA. Dental injuries due to African traditional therapies for Diarrhea. *West J Med* 2000;173:135-7.
4. Wandera MN, Kasumba B. “Ebinyo”-The practice of infant oral mutilation in Uganda. *Front Public Health* 2017;5:167.
5. Hiza JF, Kikwilu EN. Missing primary teeth due to tooth bud extraction in a remote village in Tanzania. *Int J Paediatr Dent* 1992;2:31-4.
6. Girgis S, Longhurst GR, Cheng L. Infant oral mutilation-a child protection issue. *Br Dent J* 2016;220:357-60.
7. Accorsi S, Fabiani M, Ferrarese N, Iriso R, Lukwiya M, Declich S. The burden of traditional practices, Ebino and tea-tea, on child health in Northern Uganda. *Soc Sci Med* 2003;57:2183-91.

8. Hassanali J, Amwayi P, Muriithi A. Removal of deciduous canine tooth buds in Kenyan rural Maasai. *East Afr Med J* 1995;72:207-9.
9. Esti D, Eli K, Joseph S, Diana R. The traditional practice of canine bud removal in the offspring of Ethiopian immigrants. *BMC Oral Health* 2013;13:34.
10. Tirwomwe JF, Ssamula M. The magnitude of tooth bud extraction in Uganda. *Global J Med Med Sci* 2014;2:91-6.

Figure Legends

Image 1

The malformed and elongated upper right canine tooth of a 10-year old Rwandan female patient before treatment

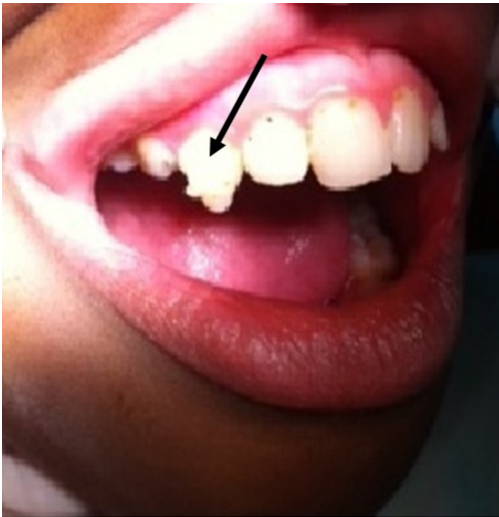

Image 2

A malformed lower left canine tooth of this case report of a 10-year old Rwandan female patient before treatment.

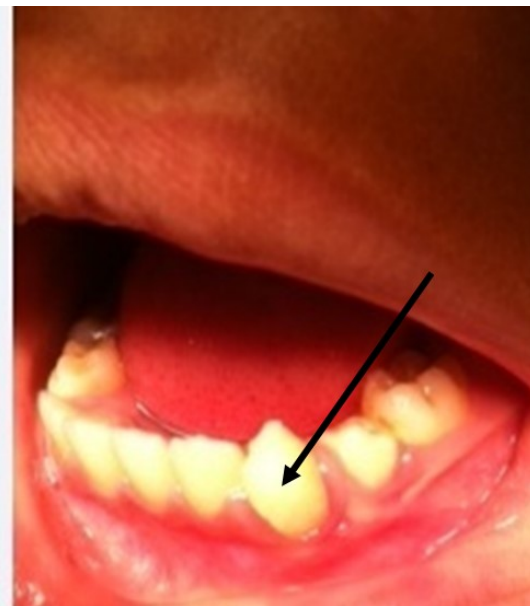

Image 3

The panoramic x-ray demonstrating the inner part of the upper and lower dental arches of this case report. **A.** Erupting right permanent canine; **B.** Retained left primary maxillary lateral incisor tooth; **C.** Permanent mandibular left canine present with abnormal root formation; **D.** Erupting permanent right mandibular canine.

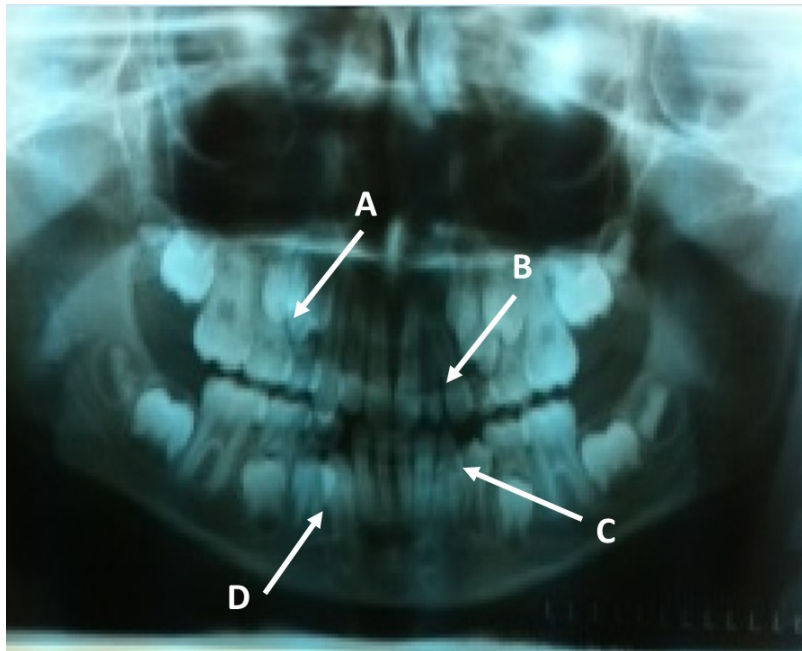


Image 4

The post-treatment features of the previously malformed right maxillary canine tooth (arrow) after crown shaping and contouring with flowable composite with a restorative material.

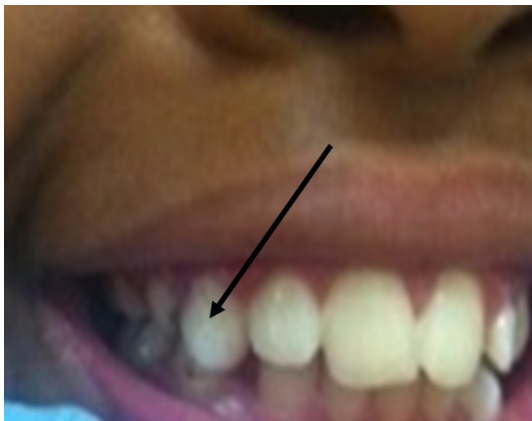

Image 5

The post-treatment features of the previously malformed left canine tooth (arrow) after crown shaping and contouring with flowable composite with a restorative material.

