

Article

The Addition of High Doses of Hyaluronic Acid to a Biphasic Bone Substitute Decreases the Proinflammatory Tissue Response

Dominik Sieger^{1,†}, Tadas Korzinskas^{1,†}, Ole Jung¹, Sanja Stojanovic², Sabine Wenisch³, Ralf Smeets^{1,4}, Martin Gosau^{1,4}, Reinhard Schnettler^{1,4}, Stevo Najman^{2,†}, Mike Barbeck^{1,5,†,*}

¹ University Hospital Hamburg-Eppendorf, Department of Oral and Maxillofacial Surgery, Division for Regenerative Orofacial Medicine, Hamburg, Germany; siegerdominik@gmail.com (D.S.); tadaskorzinskas@yahoo.de (T.K.); ol.jung@uke.de (O.J.); r.smeets@uke.de (R.S.); m.gosau@uke.de (M.G.); reiner.schnettler@mac.com (R.S.); mike.barbeck@icloud.com (M.B.)

² University of Niš, Faculty of Medicine, Department for Cell and Tissue Engineering; Institute of Biology and Human Genetics, Niš, Serbia; s.sanja88@gmail.com (S.S.); stevo.najman@gmail.com (S.N.)

³ Clinic of Small Animals, c/o Institute of Veterinary Anatomy, Histology and Embryology, Justus Liebig University of Giessen, Giessen, Germany; Sabine.Wenisch@vetmed.uni-giessen.de (S.W.)

⁴ Department of Oral Maxillofacial Surgery, University Medical Center Hamburg-Eppendorf; 20246 Hamburg, Germany

⁵ BerlinAnalytix GmbH, Berlin, Germany

* Correspondence: mike.barbeck@icloud.com; Tel.: +49-176-81022467

† These authors contributed equally to this work.

Abstract: Biphasic bone substitutes (BBS) are nowadays established biomaterials. Through their constant development even natural components like hyaluronic acid (HY) are added to improve both their handling and also their regenerative properties. However, low knowledge exists regarding the consequences of the HY addition for their biocompatibility and the inflammatory tissue reactions. Thus, the present study was conducted aiming to analyze the influence of two different amounts of high molecular weight HY (HMWHY) combined with a BBS on the *in vitro* biocompatibility and the *in vivo* tissue reaction. Established *in vitro* procedures using L929 cells were used for cytocompatibility analyses under the test conditions of DIN EN:ISO 10993-5. For the *in vivo* study part, calvarial defects were created in 20 Wistar rats and subsequently filled with the BBS and the BBS combined with two different HMWHY amounts, i.e., BBS+HY(L) and BBS+HY(H). As controls empty defects were used. Established histological, immunohistochemical and histomorphometrical methods were applied to analyze the tissue reactions to the three different materials, including the induction of pro- and anti-inflammatory macrophages and multinucleated giant cells (BMGCs).

The *in vitro* results showed that none of the materials or compositions caused biological damages to the L929 cells and can be considered to be non-toxic. The *in vivo* results showed that only the addition of high doses of HY to a biphasic bone substitute significantly decreases the occurrence of proinflammatory macrophages (* $p < 0.05$) comparable to the numbers found in the control group, while no significant differences within the three study groups for M2-macrophages nor BMGCs were detected. In conclusion, the addition of different amounts of

HMWHY does not seem to affect the inflammation response to the BBS while improving the material handling properties.

Keywords: hyaluronic acid; biphasic bone substitute; biocompatibility; tissue reaction; inflammation; macrophage; M1; M2; multinucleated giant cells

1. Introduction

Bone substitute materials (BSM) are daily applied for different indications in the medical fields of orthopedics, traumatology and dentistry. Most often BSM are used in form of granules or blocks, while for different indications such as sinus augmentations, extraction sockets, bone cysts or implantation sides around a screw for augmentation bone substitute pastes (BSP) are more suitable due to their improved handling properties [1]. Beside a “classic” BSM in granular form, different hydrophilic and water-binding molecules have already been included into BSP to achieve their flow ability and, thus, their improved applicability [2]. The bone substitute granules that are part of a BSP are most often based on calcium phosphates that are of either natural (NBSM) or synthetic origin (SBSM) [3]. Especially SBSM are used as basis for BSP as these materials can easily be produced with suitable properties such as the required granule size for minimal invasive application via a syringe [4].

In this context, it has been shown that the application of SBSM based on pure hydroxyapatite (HA) or pure beta-tricalcium phosphate (β -TCP) based granules has been associated with disadvantages regarding their biodegradation processes [5]. Thus, HA and β -TCP have different solubility behaviors and induce different levels of a material-induced foreign body response, which includes phagocytosing cells such as macrophages or biomaterial-induced multinucleated giant cells (BMGCs) [6]. While HA-based materials have shown to exhibit a low dissolution and biodegradation behavior, BSM based on β -TCP becomes very fast degraded via both processes [7]. To overcome these opposite biodegradation behaviors, both compounds have been mixed in different ratios to so called biphasic bone substitutes (BBSM) and it has already been revealed that the mixture of HA and β -TCP combines their respective biological tissue responses [8]. In this context, it has been determined that the mixture of both compounds with a HA/ β -TCP ratio of 60/40 wt% induced a tissue reaction including a high BMGC formation and vascularization rate comparable to pure β -TCP within the initial time span after implantation, while later the tissue reaction was comparable to the HA-group [5,9]. Altogether, these and different other preclinical and clinical results substantiate the applicability of BBSM as their biodegradation rate has shown to correlate with the process of bone tissue regeneration [10,11]. Moreover, their degradation pattern has demonstrated to comply with the process of creeping substitution [5,12,13]. Thus, BBSM are also assumed to be a suitable component of a BSP.

The further component of a BSP is a liquid or one with more hydrophilic molecules that obtain rheologic properties after the addition of blood or water [2].

Different natural-based polymers, such as cellulose and its derivatives, collagen from different sources, hyaluronic acid (HY) amongst a variety of other polymers, have already been used as component of different BSP [14–20]. Beside the improvement of the rheologic properties of a BSP, these molecules have suspected to provide additional regenerative features [4]. Especially extracellular matrix proteins such as collagen or HY are considered key players in the tissue regeneration process by providing a matrix for (bone) tissue growth or ingrowth of vessels and moreover by interacting with different cell types such as osteoblasts [21–23]. Even HY as a member of the glycosaminoglycan (GAG) family has been proven to modulate wound healing and related processes such as inflammation, cellular migration, and angiogenesis via specific receptors [24–29]. In the context of bone regeneration, it has revealed that HY positively influences the vascularization within the implantation bed of a BSP and also osteoblastic growth [30]. Interestingly, it has also shown in a former preclinical *in vivo* study using the subcutaneous implantation model in Wistar rats that an injectable paste-like material containing β -TCP granules and HY served as a stable and barrier-like structure over a period of at least 60 days, without allowing premature cell and tissue invasion inside the central implant regions [4]. Thus, material degradation was shown to take place from the peripheral area towards the center of the implantation bed over time. Based on these results, it was assumed that the BSP featured an integration behavior that is in accordance with the concept of the Guided Bone Regeneration (GBR). Furthermore, the performance of the same biomaterial was analyzed for bone tissue regeneration in a preclinical and clinical study [30][31]. The results of these both studies showed that the BSP contributes to sufficient bone regeneration by serving as a scaffold-like structure.

However, in these studies the influence of the addition of HY onto the material-associated inflammatory tissue reaction could not sufficiently be analyzed. It is assumable that the HY addition has influence on the inflammatory alignment of the tissue reaction to a biomaterial to support the material-related healing processes as it has already been shown in different other indications [32–34]. In this context, it is assumed that the application of a biomaterial that enables to induce a more anti-inflammatory tissue reaction may also lead to improved bone tissue regeneration [35]. Macrophages and also biomaterial-induced multinucleated giant cells (BMGCs) have identified as key players of the tissue reaction to a biomaterial as both cell types are involved in both the biodegradation process as well as the inflammatory responses within the implant bed [36][10]. Even based on the above-described regenerative properties of HY, it is a special interest if the addition of this molecule to a BSP allows to direct the cellular basis of the tissue repair process. Interestingly, it has more detailed analyzed HY fragments of different molecular sizes, i.e., high and low molecular weight hyaluronan (HMWHY / LMWHY), lead to different, sometimes opposing regenerative properties [37–40]. It has already been revealed that HMWHY exhibits anti-inflammatory and immunosuppressive characteristics, whereas LMWHY stimulates proinflammatory tissue reactions [21].

Thus, it can be expected that the combination of a BBSM with HMWHY might lead to better consolidation of the bone healing process.

However, the question arises which amount of HMWHY is necessary to optimally stimulate the process of bone tissue regeneration. Thus, the aim of the present study was to analyze the influence of two different HMWHY amounts combined with a BBSM on the inflammatory tissue reaction into bone defects. For conduction of the in vivo study, the critical-size calvarian bone model in Wistar rats was used in combination with established and previously published histological, immunohistochemical and histomorphometrical methods [41–44].

2. Results

2.1. Results of the in vitro cytocompatibility analysis

The extract of the test material caused no toxicological or biological damages to subconfluent monolayer of L929 cells under the test conditions of DIN EN:ISO 10993-5:2009. After 24 hours incubation there was no intracellular damage/alteration microscopically visible (data not shown). The L929 fibroblasts showed discrete intracytoplasmatic granules, no cell lysis and no cell growth inhibition.

Moreover, the measurements of the cytotoxicity showed that in case of all extracts in all study groups comparable values were found that did not significantly differ from the values of the negative control (Fig. 1). Moreover, the values in the group of the positive control were significantly lower ($*** p < 0.001$) as assumed and expected (Fig. 1).

Altogether, these results led to the conclusion that all of the tested biomaterials can be considered as non-cytotoxic and all of them meet the requirements of DIN EN ISO 10993-5.

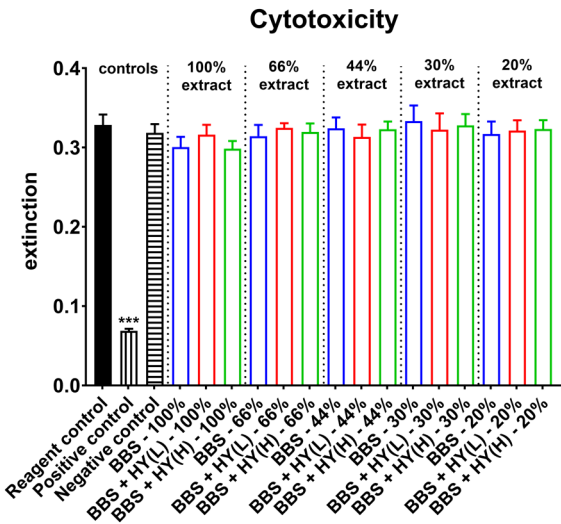


Figure 1. Results of the cell viability measurements of L9292 fibroblasts used as measure for cytotoxicity ($*** p < 0.001$).

2.2. Results of the *in vivo* study part

2.2.1 Results of the histopathological examinations

In all study groups including the bone substitutes, the granules were found within their bony implantation beds without any microscopical signs of the added HMWHY in the respective study groups (Fig. 2A-F). Moreover, the histological analysis showed that the granules of the BBSM were only partially integrated within newly formed bone tissue in the peripheral regions of the implant beds that were neighbored to the bone defect borders without visibly differences in the amounts of newly formed bone in all study groups. Thus, the BBSM granules were embedded within a cell- and vessel-rich connective tissue within the central regions of the critical-size defects (Fig. 2A-F). In the control group also minor amounts of newly formed bone were observable outgoing from the defect borders, while a thin layer of condensed connective tissue was found that seems to cross the bone defect (Fig. 2G and H).

Additionally, the histopathological analysis revealed that most of the cells found in the implantation beds of the bone substitutes were macrophages beside minor amounts of granulocytes, lymphocytes and fibroblasts (Fig. 2A-F). In the control group mainly fibroblasts and macrophages have been observed (Fig. 2G and H). At the surfaces of the BBS granules in the respective study groups mainly macrophages beside single biomaterial-induced multinucleated giant cells (BMGCs) were found (Fig. 2A-F). No visible differences in the numbers of BMGCs have been observed in the study groups including the BBS. In contrast, no multinucleated cells were found in the control group (Fig. 2G and H).

Moreover, the histopathological analysis of the immunohistochemically stained sections revealed that comparable high numbers of CD163-positive macrophages were found in the groups of the pure BBS as well as in the group of the BBS combined with the low concentrations of HMWHY (Fig. 2A and C). Lower numbers of CD163-positive macrophages were found in the group of the BBS combined with the high HMWHY concentrations and in the control group without biomaterial insertion (Fig. 2E and G). Moreover, comparable numbers of CD206-positive macrophages were detected within all study groups including the control group (Fig. 1B, D, F and H). Furthermore, the histopathological analysis showed that comparable of both proinflammatory CD163- and anti-inflammatory CD206-positive BMGCs were found in all study groups containing the BBS (Fig. 2A-F).

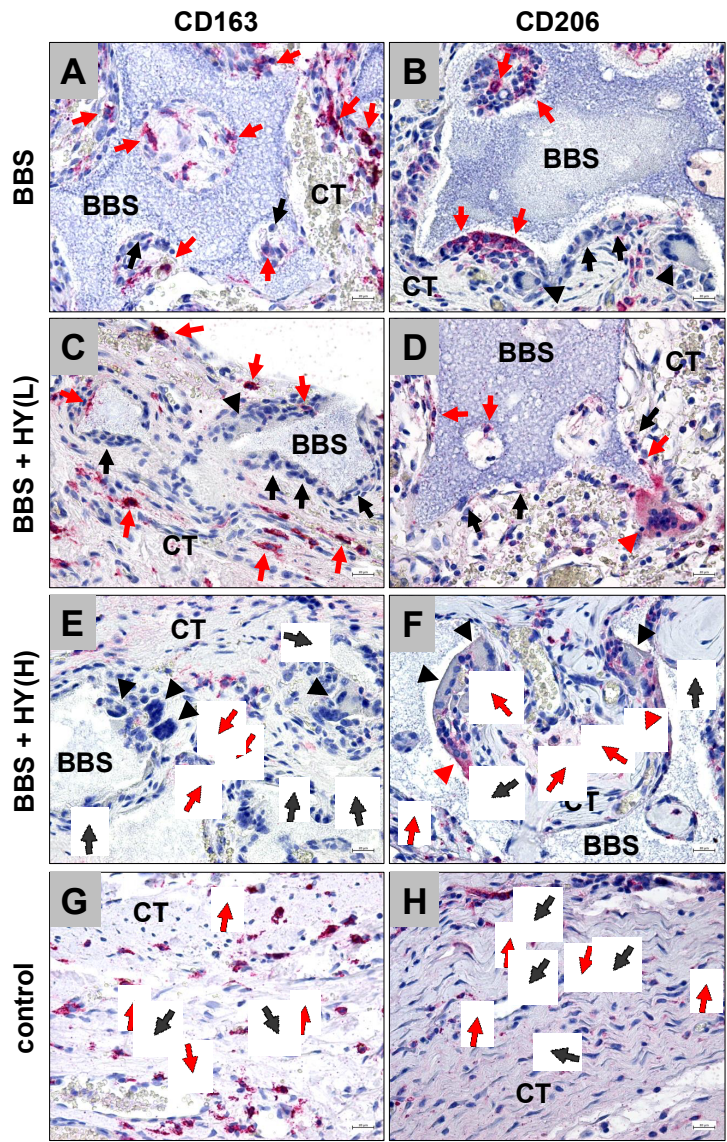


Figure 2. Exemplary histological images from the implantation beds of the analyzed pure biphasic bone substitute (BBS) (A and B) and the groups of the BBS combined with low (BBS+HY(L), C and D) and high (BBS+HY(H), E and F) concentrations of HMWHY embedded in connective tissue (CT) and the control group (G and H). CD163- and CD206-positive macrophages (red arrows), negative macrophages (black arrows), CD163- and CD206-positive (red arrowheads) and -negative (black arrowheads) BMGCs (CD163- and CD206- immunostainings, 200x magnifications, scale bars = 20 μ m).

2.2.2 Results of the histomorphometrical measurements

The histomorphometrical analysis showed that comparable high numbers of CD163-positive macrophages were found in the groups of the pure BBS (185.1 ± 54.43 cells/ mm^2), of the BBS combined with the low concentration of HY (173.0 ± 89.72 cells/ mm^2) and of the BBS combined with the high concentration of HY (112.6 ± 56.3 cells/ mm^2) (Fig. 2). The highest numbers were detected in the groups of pure BBS and of the BBS combined with the low concentration of HY, which were both significantly higher (* $p < 0.05$ and ** $p < 0.01$) compared to the number of CD163-positive macrophages in the control group (54.15 ± 35.24 cells/ mm^2) (Fig. 3). Thus,

the only group whose values did not significantly differ in comparison to the number of CD163-positive macrophages in the control group was the study group of the BBS combined with the high concentration of HY (Fig. 3). Moreover, comparably high numbers of CD206-positive macrophages were found in all study groups (Fig. 3). Thus, in the group of the pure BBS a mean of 110.9 ± 26.06 cells/mm², in the group of the BBS combined with the low concentration of HY of 94.9 ± 53.2 cells/mm², in the group of the BBS combined with the high concentration of HY of 98.53 ± 65.19 cells/mm² and in the control group of 115.3 ± 67.24 cells/mm² were measured (Fig. 3).

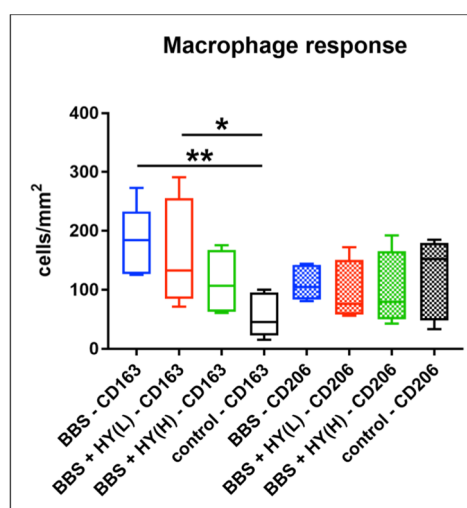


Figure 3. Results of the histomorphometrical analysis of CD163- and CD206-positive macrophages (* $p < 0.05$ and ** $p < 0.01$).

The histomorphometrical analysis of the occurrence of biomaterial-induced multinucleated giant cells (BMGCs) showed that comparable total numbers of this cell type were found in the implantation beds of all three study groups (Fig. 4). Thus, a mean of 11.31 ± 3.02 BMGC/mm² was detected in the group of the pure BBS, while in the group of the BBS combined with the low concentration of HY of 9.76 ± 2.63 BMGCs/mm² and in the group of the BBS combined with the high concentration of HY of 12.86 ± 65.19 BMGCs/mm² were measured (Fig. 4).

Moreover, comparable amounts of both CD163- and CD206-positive BMGCs were found in all study groups without any significant differences between the numbers in the different groups nor the numbers of the different subtypes of the respective study groups (Fig. 4). Thus, a mean of 2.81 ± 1.18 CD163-positive BMGCs/mm² were found the group of the pure BBS, while in the group of the BBS combined with the low concentration of HY of 2.31 ± 1.47 CD163-positive BMGCs/mm² and in the group of the BBS combined with the high concentration of HY of 3.59 ± 2.06 CD163-positive BMGCs/mm² were measured (Fig. 4). Additionally, a mean of 5.18 ± 1.56 CD206-positive BMGCs/mm² were detected the group of the pure BBS, while in the group of the BBS combined with the low concentration of HY

of 5.85 ± 1.30 CD206-positive BMCGs/mm² and in the group of the BBS combined with the high concentration of HY of 6.47 ± 1.67 CD206-positive BMGCs/mm² were detected (Fig. 4).

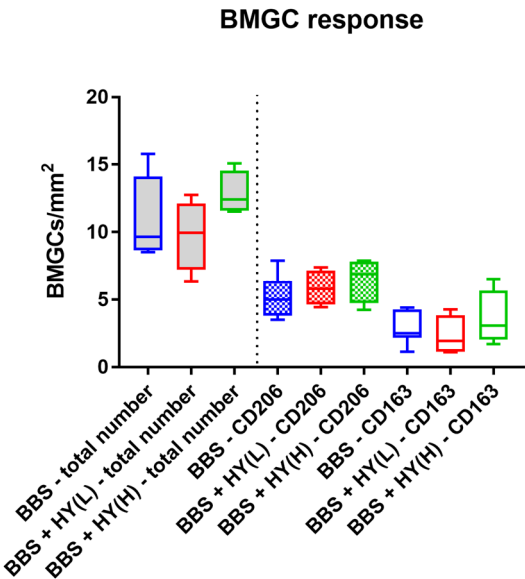


Figure 4. Results of the histomorphometrical analysis of the total number of biomaterial-induced multinucleated giant cells (BMGCs) (left side, grey fillings) and their CD163- and CD206-positive subtypes (right side).

3. Discussion

In the last decades it has been revealed that the immune system is a very important factor also for (bone) tissue healing [45,46]. In this context, it has been shown that correlations between the cytokine expression pattern of migrating macrophages and also so-called osteomacs, which are bone-resistant tissue macrophages, are of enormous importance for the material-mediated bone healing process [47]. In this context, it has been elucidated that nearly every biomaterial induces an inflammatory tissue reaction including cells such as macrophages as key regulators of the extent of inflammation being an answer to the entirety of the physicochemical properties of a bone substitute materials (BSM) and especially of synthetic BSM based on calcium phosphates [10,48–50]. Moreover, it has been declared that the material-associated inflammatory granulation tissue includes also biomaterial-induced multinucleated giant cells (BMGCs) that are the fused end stage of macrophages, which are involved in the biodegradation process of the BSM and are – even like their mononuclear precursors – involved in the healing cascade by expression both pro- and also anti-inflammatory molecules such as the vascular endothelial growth factor (VEGF) or the heme oxygenase 1 (HO-1) [6]. Thus, the composition of a bone substitute is of enormous importance to guide the regeneration process and underlying processes that support the bone tissue healing.

However, poor knowledge about the effect of BSM on the immune environment and the underlying mechanisms is existing.

Interestingly, it has already been shown that bone substitute pastes (BSP), which are mixtures of “classic” BSM in granular form, with hydrophilic and water-binding molecules such as hyaluronic acid (HY) support an integration behavior that is in accordance with the concept of the Guided Bone Regeneration (GBR) [4]. Moreover, the combination of BSM granules with such molecules helps to improve their applicability [2]. HY is of special interest as a component of biomaterials in general and also of BSP by providing additional regenerative features via modulation of processes such as wound healing, cellular migration, and angiogenesis via specific receptors such as the CD44 molecule [4,24–29]. It has already been shown in an *in vivo* study that an BSP containing β -TCP granules and a liquid phase combined of HY and methylcellulose triggers the implant bed vascularization as an important factor of bone tissue regeneration [4]. In this context, especially high molecular weight hyaluronan (HMWHY) is suspected to trigger anti-inflammatory and immunosuppressive characteristics in contrast to low molecular weight hyaluronan (LMWHY) that stimulates proinflammatory tissue reactions [21]. Thus, it can be expected that the combination of a BBSM with HMWHY might lead to better consolidation of the bone healing process.

However, in the afore-mentioned studies the influence of the addition of HMWHY onto the material-associated inflammatory tissue reaction was not sufficiently be analyzed. It is assumable that the HY addition has influence on the inflammatory alignment of the tissue reaction to a biomaterial to support the material-related healing processes as it has already been shown in different other indications [32–34]. In general, it is assumed that the application of a biomaterial that enables to induce a more anti-inflammatory tissue reaction may also lead to improved bone tissue regeneration [35]. Thus, it is a special interest if the addition of this molecule to a BSP allows directing the cellular basis of the tissue repair process.

Therefore, the design of this study was to analyze the influence of two different amounts of HMWHY combined with a BBSM on the cytocompatibility and the inflammatory tissue reaction into bone defects. In particular, the identification of pro- and anti-inflammatory macrophages and BMGCs in the *in vivo* study part was conducted following established und previously published histological and histomorphometrical methods [30,41,42,44,51].

Initially, the *in vitro* analysis of the cytocompatibility showed that none of the materials caused toxilogical or biological damages to the L929 cells. Furthermore, the cytotoxicity measurements revealed that in case of all extracts no differences between the values in the three study groups were found. This is not directly in accordance with the literature as it has manifoldly been shown that HY induces the proliferation as well as the collagen and protein synthesis of fibroblasts via interaction of the molecule especially with the Receptor for HA-Mediated

Mobility (RHAMM) [52–54]. The results might on the one hand be explainable by the test procedure, which included the extract preparation and not a direct contact of the cells with the materials. Thus, it is conceivable that the solubility of the HMWHY that was added to the BBSM granules into water was too low to have influence onto the cellular activity. However, also another explanation is thinkable: It is mainly known that the HY molecule induces cellular responses to growth factors and cell migration, particularly for fibroblasts [55–57]. Thus, the added HMWHY might have more influence onto the expression pattern and the mobility of the fibroblasts rather than on the proliferation. However, these analyses were not part of the *in vitro* testing setup and must be examined in a further study. Interestingly, these analysis steps are also not a part of the ISO norms, which demonstrates the limitations of these test procedures. Based on these facts, it might be reasonable to extent the related ISO norms in the future.

The results of the *in vivo* study part showed that the BBSM granules were detectable within their implants beds in all respective study groups, while no histological signs of the added HMWHY were found. Interestingly, comparable amounts of newly formed bone were detected in all study groups including bone substitutes in contrast to the control group that contained considerably less regenerated bone matrix. Moreover, the histological analysis of all samples demonstrated that all three materials integrated within the implantation bed without inducing an undesired severe foreign body reaction. It was demonstrated that the implantation beds consisted of BBSM granules embedded in a cell and vessel rich connective or granulation tissue. Most of the cells found in the implantation beds of the bone substitutes were macrophages and especially at the BBSM granule surfaces mainly macrophages beside single biomaterial-induced multinucleated giant cells (BMGCs) were detected. In contrast, a thin layer of condensed connective tissue containing mainly fibroblasts and macrophages have been observed.

Additionally, both histopathological and histomorphometrical analysis of the immunohistochemically stained sections revealed that comparable high numbers of CD163-positive macrophages were found in the groups of the pure BBS as well as in the group of the BBS combined with the low concentrations of HMWHY, while lower numbers of CD163-positive macrophages were found in the group of the BBS combined with the high HMWHY concentration and in the control group without biomaterial implantation. However, significant differences were only found between the cell numbers in the in the groups of pure BBS and of the BBS combined with the low concentration of HMWHY, which were both significantly higher compared to the number of CD163-positive macrophages in the control group. Furthermore, comparable numbers of CD206-positive macrophages were detected within all study groups including the control group. Finally, the analyses showed that comparable of total numbers and of both proinflammatory CD163- and anti-inflammatory CD206-positive BMGCs were found in all study groups containing the BBS.

Altogether, these results lead to the conclusion that the higher concentration of HMWHY induced a minimal decrease of the pro-inflammatory tissue response, while no influence onto the anti-inflammatory reactivity of the three materials were found. This means that all analyzed materials seem to have comparable levels of regenerative potential, which has also been reflected by comparable levels of newly formed bone into their implantation beds. However, these results lead to the question which effects the decrease of the pro-inflammatory response might have for the process of bone tissue regeneration.

On the one hand, it is thinkable that this decrease might have influence onto the resorption of the BBSM granules via mononuclear phagocytes such as the analyzed macrophages. In this context, it is known that both macrophages and BMGCs are involved in to the material degradation via phagocytosis [10,58]. Moreover, the process is (most often) associated with expression of pro-inflammatory molecules such as reactive oxygen species (ROS) and the tartrate-resistant acid phosphatase (TRAP) that are involved in the cellular degradation process of biomaterials and especially of BSM [59]. Thus, a decrease of the pro-inflammatory tissue response might also be correlating with a reduced resorbability of the materials. This might reduce the resorption pattern of a biomaterial so that no correlation with the concept of “creeping substitution” might no longer be possible [60][5]. Interestingly, a reduced resorption time might be also a favor even in case of patients with an impaired (cell) metabolism or healing time such as tumor patients, diabetics or elderly persons.

However, the unchanged induction of (pro-inflammatory) BMGCs seems to rebut this presumption as this multinucleated cell type is especially induced by large foreign bodies in the purpose of their degradation via phagocytosis [36,41,61]. As no reduction of their pro-inflammatory sub type was detected, the resorption pattern of the analyzed BSP might not be influenced. However, little knowledge exists about the process of material degradation and especially about the phagocytosis capacity of macrophages and BMGCs, so that further studies including more exact visualization methods such as trans electron microscopy (TEM) have to declare even this phenomenon to get more insights into the cellular interactions with biomaterials and especially with BSMs.

Beyond this, it is conceivable that the decrease of the pro-inflammatory tissue response is an indicator for the preponderance of the anti-inflammatory reactivity. This would mean that the addition of higher concentrations of HMWHY lead the tissue response towards an M2-driven reaction, which has assumed to be correlated with tissue healing [62]. Thus, a higher level of bone regeneration might have been induced after the time point analyzed in the present study. In this context, several studies examined how HY with different molecular weights affected the activation and reprogramming of macrophages [27,37,63,64] These results suggest that macrophages undergo phenotypic changes dependent on molecular weight of hyaluronic and support the conclusion that high molecular weight HY is mostly anti-inflammatory, whereas LMWHY induces a pro-inflammatory cell alignment

and works as an alarm signal to the immune system. However, again the unaltered response of both pro- and anti-inflammatory could be seen as an indicator of the unchanged alignment of the tissue response to the analyzed BSPs.

Interestingly, other studies showed similar results. For example, an *in vivo* study of Agrali *et al.* revealed similar findings to the results of the present study. The authors showed that HY used alone or in combination with a resorbable collagen membrane and a bovine-derived xenograft, did not contribute significantly to bone regeneration in rat calvarial bone defects [65]. Similar findings were presented by Maus *et al.* declaring that the application of an injectable hyaluronic acid (Hyalart®) with and without BMP-2 addition is not advantageous as a sole bone substitute for the filling of osseous defects [66].

An explanation for the similar cellular responses within the three groups could be the fast metabolization of the added HMWHY. Hence the exogenous HY addition may be less stimulatory to cells because of limited contact with the cellular environment and the absence of local biomechanical stimuli when compared to direct incorporation of HY into a biomaterial. Since HY is rich in carboxyl and hydroxyl groups, it can easily be modified through crosslinking or photo-crosslinking. HY should, therefore, be incorporated in one of the promising approaches based on a range of crosslinking techniques. [67][21].

However, the present study has also limitations, which led to limited information about the degree of the inflammation response that was won by counting of cells. In this context, the quantification of the expression of pro-and anti-inflammatory molecules might lead to further clarification of the tissue response induced by the HMWHY addition. However, more complex methods such as laser-assisted cell microdissection, which allows for the measurement of cytokine release from single cells or cell types, are needed for examination of the cytokine levels released from biomaterial-induced macrophages and BMGCs. Moreover, the time span up to 60 days might not be sufficient to evaluate the long time effects of the addition of HMWHY and its support onto bone regeneration so that further studies including more a prolonged observation period will also be needed.

Altogether, the results of the present study showed that the tissue response both the pure BBSM and the both BSP are more or less comparable with only slight differences in the pro-inflammatory response of macrophages, which might be induced by the addition of high concentrations of HMWHY. Moreover, the results showed that all analyzed materials are biocompatible and the handling properties of the BBSM have been improved by the molecule addition.

4. Materials and Methods

4.1 Biomaterials

For preparation of the BBS a mixture of granules of a synthetic biphasic calcium phosphate, i.e., 60% HA and 40% β -TCP, with a porosity of approx. 80% and a

granule size of 0.5 - 1.0 mm and of 50 mg or 100 mg of hyaluronate with a molecular weight of 2 MDa was prepared (Table 1). The resulting bone grafting materials were sterilized by ethylene oxide (EO) and packed. The final biomaterials had a powder-like appearance and were estimated to be hydrated before application to get a gel-like consistency.

Table 1. shows the different study groups and mixing ratios.

	Group 1 (sham operation)	Group 2 (BBS)	Group 3 (BBS + HY(L))	Group 4 (BBS + HY(H))
Biphasic bone substitute (BBS)	/	0,5 g	0,5 g	0,5 g
Hyaluronate, 2 MDa	/	/	50 mg	100 mg

4.2 in vitro cytocompatibility analysis

The biphasic bone substitute and the negative control group (Polypropylene) were immersed in DMEM culture medium (Fisher scientific GmbH) during 24 hours to prepare an extraction medium. After extraction procedure the extract was centrifuged at 2500 x g for ten minutes to eliminate the residual sample. This was necessary to avoid possible undesirable influences of the material extract onto the cells.

A fibroblast (L929) suspension was prepared in complete DMEM supplemented with 10% fetal calf serum (FCS; Pan-Biotech GmbH) to obtain 1,5x10⁵ cells / ml. The wells of 96 wells tissue culture plates were inoculated with 100µl of cell suspension per well. The plates were incubated for 24 hours in an humidified incubator in 5 % CO₂ at 37 Co..

A 100 µl aliquot of the test material of different concentrations (100%,66%,44%,30%,20%) were administered into each of the four wells following 24 hours of incubation (5 % CO₂, 37 Co ,98% humidity). Afterwards the cell culture plates were examined microscopically using a subjective grading system assessing morphological aspects.

After microscopically examination the culture medium was eliminated and 120 µl per well of MTS (3-(4,5-dimethylthiazol-2-yl)-5(3-carboxymethonyphenol)- 2-(4-sulfophenyl)-2H-tetrazolium) was added. After 40 minutes, colorimetric reaction in the MTS- treated plates was measured by spectrophotometry (absorbance at 490 and 630 nm). Cell viability was calculated from assay results divided by those of negative control.

4.2 In vivo biocompatibility analysis

4.2.1 Experimental animals, surgical procedure and explantation procedure

In total, 20 female, 6-8 week-old Wistar rats obtained from the Military Medical Academy (Belgrade, Serbia) were randomly allocated into four study groups with 5 animals per group ($n = 5$) after authorization by the Local Ethical Committee (Faculty of Medicine, University of Niš, Serbia). The *in vivo* experiments and animal housing were conducted at the Faculty of Medicine (University of Niš, Serbia). The animals were kept under standard conditions (water *ad libitum*, artificial light and regular rat pellet) and standard pre- and postoperative care was ensured.

The animals obtained implantation of the afore-mentioned biomaterials for one study time point of 15 days. The implantations were conducted as follows: Initially, the animals were anesthetized via an intraperitoneal injection (10 ml ketamine [50 mg/ml] with 1.6 ml Xylazine [2%]) and the implantation side was shaved and disinfected. Afterwards, the surgical field was prepared by midline sagittal incisions combined with anterior and posterior subperiosteal dissection. Following, the frontal and parietal regions of the calvarias were exposed and bilateral cranial bone defects (2 defects/calvaria) using a trephine bur (GC, Tokyo, Japan) were created. Afterwards, in the material groups the biomaterials were inserted into both bone defects (Fig. 5), while the no materials were implanted in the control group. Finally, the wounds were covered by a collagen membrane (Jason membrane, botiss biomaterials GmbH, Berlin, Germany) and sutured.

After the healing period of two months, the explantation and the histological preparations were conducted as previously described [6,30,41,42] Initially, the implanted bone substitutes were cut out together with the peri-implant bone tissue immediately after the euthanasia and these explants were fixed in 10% neutral-buffered formalin for 48 h.

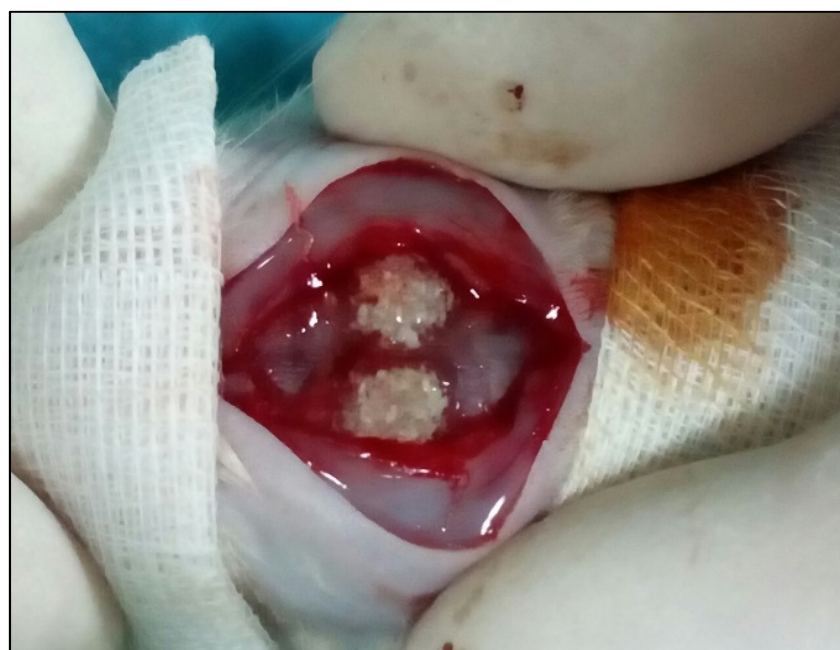

Figure 5. Exemplary image of the surgical procedure. Two calvarial defects filled with biphasic bone substitute combined with the low HMWHY concentration.

495

496 *4.2.2 Histological preparations and staining methods*

497 The histological preparations started with a decalcification step via 10%
498 ethylenediaminetetraacetic acid (Fluka, Germany) at room temperature for 7-10
499 days. After that, the further histological workup was performed by subsequent
500 dehydration in a series of increasing alcohol concentrations followed by xylol. All
501 explants were cut in two halves and subsequently embedded in paraffin. Then,
502 sections with a thickness of 3-5 μm were cut using a rotation microtome (Leica
503 RM2255, Wetzlar, Germany). Furthermore, immunohistochemical stainings were
504 performed as previously described by Barbeck et al. and Korzinskas et al. [43]. In
505 brief, one section of every biopsy was stained via hematoxylin and eosin (HE), while
506 four sections of every tissue explant were used for the immunohistochemical
507 detection of the M1- and M2-subforms of phagocytes, i.e., macrophages and
508 biomaterial-induced multinucleated giant cells (BMGCs) using antibodies against
509 the pro- and anti-inflammatory molecules hemoglobin scavenger receptor (CD163)
510 and mannose receptor (MR, also known as CD206). These slides were pretreated
511 with citrate buffer and proteinase K at pH8 for 20 min in a water bath at 96 °C.
512 Afterwards, equilibration using TBS-T buffer was conducted and the slides were
513 then treated by H₂O₂ and avidin and biotin blocking solutions (Avidin/Biotin
514 Blocking Kit, Vector Laboratories, Burlingame, CA, USA). Subsequently, incubation
515 with the respective first antibody for 30 min was done, followed by incubation with
516 the secondary antibody (goat anti- rabbit IgG-B, sc-2040, 1:200, Santa Cruz
517 Biotechnology, Shandon, CA, USA). After this step, the avidin–biotin–peroxidase
518 complex (ThermoFisher Scientific, Dreieich, Germany) was applied for 30 min.
519 Finally, counterstaining by hematoxylin and blueing was conducted.

520

521 *4.2.3 Histopathological analysis*

522 The histopathological analysis focused on the comparison of the tissue reactions
523 to the different biomaterials on basis of the immunohistochemical stainings for the
524 detection of the M1- and M2-subforms of phagocytes, i.e., macrophages and
525 biomaterial-induced multinucleated giant cells (BMGCs). For this analysis, a light
526 microscope Axio Scope.A1 (Carl Zeiss Microscopy GmbH, Germany) was used and
527 an established protocol was applied as previously published [30,41,42,44,51]. In
528 brief, the qualitative histological evaluation included the observation of the cells
529 participating in the process of biomaterial integration and degradation, the
530 implantation bed vascularization and the possible adverse reactions such as fibrotic
531 encapsulation or necrosis. A light microscope (Nikon ECLIPSE 80i microscope,
532 Tokyo, Japan) was used for the analyses. Histological figures were taken by a
533 microscope camera (Nikon DS-Fi1, Tokyo, Japan) that was connected to an
534 acquisition unit (Nikon digital sight control unit, Tokyo, Japan).

535

4.2.4 Histomorphometrical analysis

The histomorphometrical analyses included the comparative measurements of the numbers of the pro- and anti-inflammatory mono- and multinucleated phagocytes, on basis of previously published methods [30,41,42,44,51]. Briefly, so-called “total scans” were generated by means of a specialized scanning microscope, which is a combination of an Axio Scope.A1 (Carl Zeiss Microscopy GmbH, Germany) equipped with a digital camera and an automatic scanning table (Merzhäeuser, Germany) connected to an PC system running the Zen Core software (Zeiss, Tokyo, Japan). The resulting images were composed of 100 to 120 single images with a 100x magnification in a resolution of 2500x1200 pixels and contained the complete implant area of the different bone substitutes as well as the peri-implant tissue. To measure the numbers of cells within the bone defects, the complete area of the defect sides was first calculated with the “area tool” (in mm²). Afterwards, the different cells were manually marked using the “counting tool”. Finally, cell numbers per mm² per defect area were determined by calculating the respective cell number in relation to the total implant area.

4.3 Statistical analysis

Quantitative data are shown as mean ± standard deviation after an analysis of variance (ANOVA) and a LSD post-hoc test using the GraphPad Prism 7.0d software (GraphPad Software Inc., La Jolla, California, USA). Statistical differences were designated as significant if p-values were less than 0.05 (* p ≤ 0.05), and highly significant if P-values were less than 0.01 (** p ≤ 0.01) or less than 0.001 (***) p ≤ 0.001).

Author Contributions: D.S., S.S., S.N., O.J., R.S. and M.B. conducted animal experiments. D.S., T.K. and O.J. conducted the histomorphometrical analysis. D.S., O.J., and M.B. conducted the histopathological analysis. D.S., O.J., K.G., S.S., S.W., M.G., R.S. and M.B. wrote the manuscript. R.S., S.N., S.W., M.G., R.S., and M.B. provided lab space and materials.

Funding: The authors declare no conflict of interest.

Acknowledgments: The authors want to thank Ms. Annekathrin Kopp for her excellent technical assistance and Mr. Torsten Müller for his excellent organization support.

Conflicts of Interest: The authors declare no conflicts of interest.

Abbreviations

BBS	Biphasic bone substitutes
HY	Hyaluronic acid
HMWHY	High molecular weight Hyaluronic Acid
HA	Hydroxyapatite
β-TCP	beta-tricalcium phosphate
BMGC	Biomaterial induced multinucleated Giant Cell
BSM	Bone Substitute Material
BSP	Bone Substitute Paste
FBR	Foreign Body Reaction
GBR	Guided Bone Regeneration
GTR	Guided Tissue Regeneration

References

- (1) Moore, W. R.; Graves, S. E.; Bain, G. I. Synthetic Bone Graft Substitutes. *ANZ Journal of Surgery*. 2001. <https://doi.org/10.1046/j.1440-1622.2001.02128.x>.
- (2) Larsson, S.; Hannink, G. Injectable Bone-Graft Substitutes: Current Products, Their Characteristics and Indications, and New Developments. *Injury* **2011**. <https://doi.org/10.1016/j.injury.2011.06.013>.
- (3) Kao, S. T.; Scott, D. D. A Review of Bone Substitutes. *Oral and Maxillofacial Surgery Clinics of North America*. 2007. <https://doi.org/10.1016/j.coms.2007.06.002>.
- (4) Ghanaati, S.; Barbeck, M.; Hilbig, U.; Hoffmann, C.; Unger, R. E.; Sader, R. A.; Peters, F.; Kirkpatrick, C. J. An Injectable Bone Substitute Composed of Beta-Tricalcium Phosphate Granules, Methylcellulose and Hyaluronic Acid Inhibits Connective Tissue Influx into Its Implantation Bed in Vivo. *Acta Biomater.* **2011**, 7 (11), 4018–4028. <https://doi.org/10.1016/j.actbio.2011.07.003>.
- (5) Ghanaati, S.; Barbeck, M.; Detsch, R.; Deisinger, U.; Hilbig, U.; Rausch, V.; Sader, R.; Unger, R. E.; Ziegler, G.; Kirkpatrick, C. J. The Chemical Composition of Synthetic Bone Substitutes Influences Tissue Reactions in Vivo: Histological and Histomorphometrical Analysis of the Cellular Inflammatory Response to Hydroxyapatite, Beta-Tricalcium Phosphate and Biphasic Calcium Phosphate Cer. *Biomed. Mater.* **2012**, 7 (1). <https://doi.org/10.1088/1748-6041/7/1/015005>.
- (6) Barbeck, M.; Motta, A.; Migliaresi, C.; Sader, R.; Kirkpatrick, C. J.; Ghanaati, S. Heterogeneity of Biomaterial-Induced Multinucleated Giant Cells: Possible Importance for the Regeneration Process? *J. Biomed. Mater. Res. - Part A* **2016**. <https://doi.org/10.1002/jbm.a.35579>.
- (7) Legeros, R. Z.; Lin, S.; Rohanizadeh, R.; Mijares, D.; Legeros, J. P. Biphasic Calcium Phosphate Bioceramics: Preparation, Properties and Applications. *Journal of Materials Science: Materials in Medicine*. 2003. <https://doi.org/10.1023/A:1022872421333>.
- (8) Ebrahimi, M.; Botelho, M. G.; Dorozhkin, S. V. Biphasic Calcium Phosphates Bioceramics (HA/TCP): Concept, Physicochemical Properties and the Impact of Standardization of Study Protocols in Biomaterials Research. *Materials Science and Engineering C*. 2017. <https://doi.org/10.1016/j.msec.2016.11.039>.
- (9) Jensen, S. S.; Bornstein, M. M.; Dard, M.; Bosshardt, D. D.; Buser, D. Comparative Study of Biphasic Calcium Phosphates with Different HA/TCP Ratios in Mandibular Bone Defects. A Long-Term Histomorphometric Study in Minipigs. *J. Biomed. Mater. Res. - Part B Appl. Biomater.* **2009**. <https://doi.org/10.1002/jbm.b.31271>.
- (10) Anderson, J. M.; Rodriguez, A.; Chang, D. T. Foreign Body Reaction to Biomaterials. *Semin. Immunol.* **2008**, 20 (2), 86–100. <https://doi.org/10.1016/j.smim.2007.11.004>.
- (11) Ghanaati, S.; Barbeck, M.; Orth, C.; Willershausen, I.; Thimm, B. W.; Hoffmann, C.; Rasic, A.; Sader, R. A.; Unger, R. E.; Peters, F.; et al. Influence of β -Tricalcium Phosphate Granule Size and Morphology on Tissue Reaction in Vivo. *Acta Biomater.* **2010**. <https://doi.org/10.1016/j.actbio.2010.07.006>.
- (12) Lobo, S. E.; Arinzeh, T. L. Biphasic Calcium Phosphate Ceramics for Bone Regeneration and Tissue Engineering Applications. *Materials (Basel)*. **2010**. <https://doi.org/10.3390/ma3020815>.
- (13) Daculsi, G.; Legeros, R. Z.; Nery, E.; Lynch, K.; Kerebel, B. Transformation of Biphasic Calcium Phosphate Ceramics in Vivo: Ultrastructural and Physicochemical Characterization. *J. Biomed. Mater. Res.* **1989**. <https://doi.org/10.1002/jbm.820230806>.
- (14) Miyamoto, T.; Takahashi, S. -i; Ito, H.; Inagaki, H.; Noishiki, Y. Tissue Biocompatibility of Cellulose and Its Derivatives. *J. Biomed. Mater. Res.* **1989**. <https://doi.org/10.1002/jbm.820230110>.
- (15) Mårtson, M.; Viljanto, J.; Hurme, T.; Saukko, P. Biocompatibility of Cellulose Sponge with Bone. *Eur.*

- Surg. Res.* **1998**. <https://doi.org/10.1159/000008609>.
- (16) Muller-Mai, C.; Voigt, C.; Hering, A.; Rahmanzadeh, R.; Gross, U. [Madrepore Hydroxyapatite Granulates for Filling Bone Defects]. *Unfallchirurg* **2001**.
- (17) Barbié, C.; Chauveaux, D.; Barthe, X.; Baquey, C.; Poustis, J. Biological Behaviour of Cellulosic Materials after Bone Implantation: Preliminary Results. *Clin. Mater.* **1990**. [https://doi.org/10.1016/0267-6605\(90\)90023-O](https://doi.org/10.1016/0267-6605(90)90023-O).
- (18) Solchaga, L. A.; Yoo, J. U.; Lundberg, M.; Dennis, J. E.; Huibregtse, B. A.; Goldberg, V. M.; Caplan, A. I. Hyaluronan-Based Polymers in the Treatment of Osteochondral Defects. *J. Orthop. Res.* **2000**. <https://doi.org/10.1002/jor.1100180515>.
- (19) Solchaga, L. A.; Temenoff, J. S.; Gao, J.; Mikos, A. G.; Caplan, A. I.; Goldberg, V. M. Repair of Osteochondral Defects with Hyaluronan- and Polyester-Based Scaffolds. *Osteoarthr. Cartil.* **2005**. <https://doi.org/10.1016/j.joca.2004.12.016>.
- (20) Tognana, E.; Borrione, A.; De Luca, C.; Pavesio, A. Hyalograft® C: Hyaluronan-Based Scaffolds in Tissue-Engineered Cartilage. *Cells Tissues Organs*. 2007. <https://doi.org/10.1159/000102539>.
- (21) Allison, D. D.; Grande-Allen, K. J. Review. Hyaluronan: A Powerful Tissue Engineering Tool. *Tissue Eng.* **2006**, *12* (8), 2131–2140. <https://doi.org/10.1089/ten.2006.12.ft-153>.
- (22) Wagner-Ecker, M.; Voltz, P.; Egermann, M.; Richter, W. The Collagen Component of Biological Bone Graft Substitutes Promotes Ectopic Bone Formation by Human Mesenchymal Stem Cells. *Acta Biomater.* **2013**. <https://doi.org/10.1016/j.actbio.2013.03.037>.
- (23) Marina, A.; Gentile, P.; Chiono, V.; Ciardelli, G. Collagen for Bone Tissue Regeneration. *Acta Biomater.* **2012**, *8* (9), 3191–3200. <https://doi.org/10.1016/j.actbio.2012.06.014>.
- (24) Trochon, V.; Mabilat, C.; Bertrand, P.; Legrand, Y.; Smadja-Joffe, F.; Soria, C.; Delpech, B.; Lu, H. Evidence of Involvement of CD44 in Endothelial Cell Proliferation, Migration and Angiogenesis in Vitro. *Int. J. Cancer* **1996**. [https://doi.org/10.1002/\(SICI\)1097-0215\(19960529\)66:5<664::AID-IJC14>3.0.CO;2-4](https://doi.org/10.1002/(SICI)1097-0215(19960529)66:5<664::AID-IJC14>3.0.CO;2-4).
- (25) Ishida, O.; Tanaka, Y.; Morimoto, I.; Takigawa, M.; Eto, S. Chondrocytes Are Regulated by Cellular Adhesion through CD44 and Hyaluronic Acid Pathway. *J. Bone Miner. Res.* **1997**. <https://doi.org/10.1359/jbmr.1997.12.10.1657>.
- (26) Lesley, J.; Hascall, V. C.; Tammi, M.; Hyman, R. Hyaluronan Binding by Cell Surface CD44. *J. Biol. Chem.* **2000**. <https://doi.org/10.1074/jbc.M002527200>.
- (27) McKee, C. M.; Penno, M. B.; Cowman, M.; Burdick, M. D.; Strieter, R. M.; Bao, C.; Noble, P. W. Hyaluronan (HA) Fragments Induce Chemokine Gene Expression in Alveolar Macrophages: The Role of HA Size and CD44. *J. Clin. Invest.* **1996**. <https://doi.org/10.1172/JCI119054>.
- (28) Schmits, R.; Filmus, J.; Gerwin, N.; Senaldi, G.; Kiefer, F.; Kundig, T.; Wakeham, A.; Shahinian, A.; Catzavelos, C.; Rak, J.; et al. CD44 Regulates Hematopoietic Progenitor Distribution, Granuloma Formation, and Tumorigenicity. *Blood* **1997**.
- (29) Travis, J. A.; Hughes, M. G.; Wong, J. M.; Wagner, W. D.; Geary, R. L. Hyaluronan Enhances Contraction of Collagen by Smooth Muscle Cells and Adventitial Fibroblasts Role of CD44 and Implications for Constrictive Remodeling. *Circ. Res.* **2001**. <https://doi.org/10.1161/01.RES.88.1.77>.
- (30) Barbeck, M.; Dard, M.; Kokkinopoulou, M.; Markl, J.; Booms, P.; Sader, R. A.; Kirkpatrick, C. J.; Ghanaati, S. Small-Sized Granules of Biphasic Bone Substitutes Support Fast Implant Bed Vascularization. *Biomatter* **2015**. <https://doi.org/10.1080/21592535.2015.1056943>.
- (31) Rothamel, P. D. Surface Morphology , Biocompatibility and Osseous Organization of a New Biphasic Bone Substitute (Maxresorb ®). A Combined in-Vitro / in-Vivo Analysis . P 248. **2008**, *22* (1), 50931.

- 655 (32) Masuko, K.; Murata, M.; Yudoh, K.; Kato, T.; Nakamura, H. Anti-Inflammatory Effects of Hyaluronan
656 in Arthritis Therapy: Not Just for Viscosity. *International Journal of General Medicine*. 2009.
- 657 (33) Manuskiatti, W.; Maibach, H. I. Hyaluronic Acid and Skin: Wound Healing and Aging. *Int. J. Dermatol.*
658 **1996**, 35 (8), 539–544.
- 659 (34) Roehrs H; Stocco JGD; Pott F; Blanc G; Crozeta K; Meier MJ; Dias FAL. Dressings and Topical Agents
660 Containing Hyaluronic Acid for Chronic Wound Healing (Protocol). **2016**.
661 <https://doi.org/10.1002/14651858.CD012215>.
- 662 (35) Thomas, M. V.; Puleo, D. A. Infection, Inflammation, and Bone Regeneration: A Paradoxical
663 Relationship. *Journal of Dental Research*. 2011. <https://doi.org/10.1177/0022034510393967>.
- 664 (36) Miron, richard; Bosshardt, D. Multi-Nucleated Giant Cells: Good Guys or Bad Guys? *Tissue Eng. Part*
665 *B Rev.* **2017**, ten.TEB.2017.0242. <https://doi.org/10.1089/ten.TEB.2017.0242>.
- 666 (37) Baeva, L. F.; Lyle, D. B.; Rios, M.; Langone, J. J.; Lightfoote, M. M. Different Molecular Weight Hyaluronic
667 Acid Effects on Human Macrophage Interleukin 1 β Production. *J. Biomed. Mater. Res. - Part A* **2014**, 102
668 (2), 305–314. <https://doi.org/10.1002/jbm.a.34704>.
- 669 (38) Sasaki, T.; Watanabe, C. Stimulation of Osteoinduction in Bone Wound Healing by High-Molecular
670 Hyaluronic Acid. *Bone* **1995**. [https://doi.org/10.1016/8756-3282\(95\)80005-B](https://doi.org/10.1016/8756-3282(95)80005-B).
- 671 (39) Rayahin, J. E.; Buhrman, J. S.; Zhang, Y.; Koh, T. J.; Gemeinhart, R. A. High and Low Molecular Weight
672 Hyaluronic Acid Differentially Influence Macrophage Activation. *ACS Biomater. Sci. Eng.* **2015**, 1 (7), 481–
673 493. <https://doi.org/10.1021/acsbiomaterials.5b00181>.
- 674 (40) Bauer, C.; Niculescu-Morzsza, E.; Jeyakumar, V.; Kern, D.; Späth, S. S.; Nehrer, S. Chondroprotective
675 Effect of High-Molecular-Weight Hyaluronic Acid on Osteoarthritic Chondrocytes in a Co-Cultivation
676 Inflammation Model with M1 Macrophages. *J. Inflamm. (United Kingdom)* **2016**, 13 (1), 1–9.
677 <https://doi.org/10.1186/s12950-016-0139-y>.
- 678 (41) Ghanaati, S.; Udeabor, S.; Kirkpatrick, C.; Lorenz, J.; Kubesch, A.; Choukroun, J.; Sader, R.; Barbeck, M.
679 Induction of Multinucleated Giant Cells in Response to Small Sized Bovine Bone Substitute (Bio-Oss TM
680) Results in an Enhanced Early Implantation Bed Vascularization . *Ann. Maxillofac. Surg.* **2014**.
681 <https://doi.org/10.4103/2231-0746.147106>.
- 682 (42) Barbeck, M.; Serra, T.; Booms, P.; Stojanovic, S.; Najman, S.; Engel, E.; Sader, R.; Kirkpatrick, C. J.;
683 Navarro, M.; Ghanaati, S. Analysis of the in Vitro Degradation and the in Vivo Tissue Response to Bi-
684 Layered 3D-Printed Scaffolds Combining PLA and Biphasic PLA/Bioglass Components – Guidance of
685 the Inflammatory Response as Basis for Osteochondral Regeneration. *Bioact. Mater.* **2017**.
686 <https://doi.org/10.1016/j.bioactmat.2017.06.001>.
- 687 (43) Ghanaati, S.; Barbeck, M.; Willershausen, I.; Thimm, B.; Stuebinger, S.; Korzinskas, T.; Obreja, K.; Landes,
688 C.; Kirkpatrick, C. J.; Sader, R. A. Nanocrystalline Hydroxyapatite Bone Substitute Leads to Sufficient
689 Bone Tissue Formation Already after 3 Months: Histological and Histomorphometrical Analysis 3 and
690 6 Months Following Human Sinus Cavity Augmentation. *Clin. Implant Dent. Relat. Res.* **2013**.
691 <https://doi.org/10.1111/j.1708-8208.2011.00433.x>.
- 692 (44) Barbeck, M.; Unger, R. E.; Booms, P.; Dohle, E.; Sader, R. A.; Kirkpatrick, C. J.; Ghanaati, S. Monocyte
693 Preseeding Leads to an Increased Implant Bed Vascularization of Biphasic Calcium Phosphate Bone
694 Substitutes via Vessel Maturation. *J. Biomed. Mater. Res. - Part A* **2016**.
695 <https://doi.org/10.1002/jbm.a.35834>.
- 696 (45) Khan, S. N. The Biology of Bone Grafts. *Orthopedics* **2003**, 26 (9), 923–924.
- 697 (46) Schmidt-Bleek, K.; Schwarz, C.; Dienelt, A.; Duda, G. N.; Petersen, A. Initiation and Early Control of

- Tissue Regeneration – Bone Healing as a Model System for Tissue Regeneration. *Expert Opin. Biol. Ther.* **2014**, *14* (2), 247–259. <https://doi.org/10.1517/14712598.2014.857653>.
- (47) Miron, R. J.; Bosshardt, D. D. OsteoMacs: Key Players around Bone Biomaterials. *Biomaterials* **2016**, *82*, 1–19. <https://doi.org/10.1016/j.BIOMATERIALS.2015.12.017>.
- (48) Tang, L.; Eaton, J. W. Inflammatory Responses to Biomaterials. *Am. J. Clin. Pathol.* **1995**, *103* (4), 466–471.
- (49) Egyedi, P.; van Palenstein Helderman, W. H. Sterilization of Infected Bone by Lyophilization and Rehydration with Antibiotic Solutions. *J. Maxillofac. Surg.* **1976**, *4* (1), 65–66.
- (50) Hu, W. J.; Eaton, J. W.; Ugarova, T. P.; Tang, L. Molecular Basis of Biomaterial-Mediated Foreign Body Reactions. *Blood* **2001**, *98* (4), 1231–1238.
- (51) Tawil, G.; Barbeck, M.; Witte, F.; Tawil, P.; Unger, R. Sinus Floor Elevation Using the Lateral Approach and Window Repositioning and a Xenogeneic Bone Substitute as a Grafting Material: A Histologic, Histomorphometric, and Radiographic Analysis. *Int. J. Oral Maxillofac. Implants* **2018**. <https://doi.org/10.11607/jomi.6226>.
- (52) Mast, B. A.; Diegelmann, R. F.; Krummel, T. M.; Cohen, I. K. Hyaluronic Acid Modulates Proliferation, Collagen and Protein Synthesis of Cultured Fetal Fibroblasts. *Matrix* **1993**. [https://doi.org/10.1016/S0934-8832\(11\)80110-1](https://doi.org/10.1016/S0934-8832(11)80110-1).
- (53) Greco, R. M.; Iocono, J. A.; Ehrlich, H. P. Hyaluronic Acid Stimulates Human Fibroblast Proliferation within a Collagen Matrix. *J. Cell. Physiol.* **1998**. [https://doi.org/10.1002/\(SICI\)1097-4652\(199812\)177:3<465::AID-JCP9>3.0.CO;2-5](https://doi.org/10.1002/(SICI)1097-4652(199812)177:3<465::AID-JCP9>3.0.CO;2-5).
- (54) Landau, M.; Fagien, S. Science of Hyaluronic Acid beyond Filling: Fibroblasts and Their Response to the Extracellular Matrix. *Plast. Reconstr. Surg.* **2015**. <https://doi.org/10.1097/PRS.0000000000001823>.
- (55) Ruoslahti, E.; Yamaguchi, Y. Proteoglycans as Modulators of Growth Factor Activities. *Cell* **1991**, *64* (5), 867–869. [https://doi.org/10.1016/0092-8674\(91\)90308-L](https://doi.org/10.1016/0092-8674(91)90308-L).
- (56) Balaji, S.; King, A.; Marsh, E.; LeSaint, M.; Bhattacharya, S. S.; Han, N.; Dhamija, Y.; Ranjan, R.; Le, L. D.; Bollyky, P. L.; et al. The Role of Interleukin-10 and Hyaluronan in Murine Fetal Fibroblast Function In Vitro: Implications for Recapitulating Fetal Regenerative Wound Healing. *PLoS One* **2015**, *10* (5), e0124302. <https://doi.org/10.1371/journal.pone.0124302>.
- (57) Melrose, J. Glycosaminoglycans in Wound Healing. *Bone Tissue Regen. Insights* **2016**, *7*, BTRL.S38670. <https://doi.org/10.4137/BTRL.S38670>.
- (58) DANIE` L T. LUTTIKHUIZEN, M.Sc., MARTIN C. HARMSSEN, Ph.D., and MARJA J.A. VAN LUYN, P. D. Cellular and Molecular Dynamics in the Foreign Body Reaction. *Physiol Rev* **1966**, *16* (7), 327. <https://doi.org/10.1053/nbin.2001.23176>.
- (59) Kobayashi, S. D.; Voyich, J. M.; Burlak, C.; Deleo, F. R. *Neutrophils in the Innate Immune Response*; 2005; Vol. 53.
- (60) Cypher, T. J.; Grossman, J. P. Biological Principles of Bone Graft Healing. *J. Foot Ankle Surg.* **35** (5), 413–417.
- (61) Florencio-Silva, R.; Sasso, G. R. D. S.; Sasso-Cerri, E.; Simões, M. J.; Cerri, P. S. Biology of Bone Tissue: Structure, Function, and Factors That Influence Bone Cells. *Biomed Res. Int.* **2015**, *2015*, 1–17. <https://doi.org/10.1155/2015/421746>.
- (62) Shahbazi, M.-A.; Sedighi, M.; Bauleth-Ramos, T.; Kant, K.; Correia, A.; Poursina, N.; Sarmiento, B.; Hirvonen, J.; Santos, H. A. Targeted Reinforcement of Macrophage Reprogramming Toward M2 Polarization by IL-4-Loaded Hyaluronic Acid Particles. *ACS Omega* **2018**, *3* (12), 18444–18455. <https://doi.org/10.1021/acsomega.8b03182>.

741 (63) Noble, P. W.; McKee, C. M.; Cowman, M.; Shin, H. S. Hyaluronan Fragments Activate an NF-Kappa B/I-
742 Kappa B Alpha Autoregulatory Loop in Murine Macrophages. *J Exp Med* **1996**, *183* (5), 2373–2378.
743 <https://doi.org/10.1084/jem.183.5.2373>.
744 (64) Turley, E. A.; Noble, P. W.; Bourguignon, L. Y. W. Signaling Properties of Hyaluronan Receptors. *Journal*
745 *of Biological Chemistry*. 2002. <https://doi.org/10.1074/jbc.R100038200>.
746 (65) Agrali, O. B.; Yildirim, S.; Ozener, H. O.; Köse, K. N.; Ozbeyli, D.; Soluk-Tekkesin, M.; Kuru, L.
747 Evaluation of the Effectiveness of Esterified Hyaluronic Acid Fibers on Bone Regeneration in Rat
748 Calvarial Defects. *Biomed Res. Int.* **2018**, *2018*. <https://doi.org/10.1155/2018/3874131>.
749 (66) Maus, U.; Andereya, S.; Gravius, S.; Siebert, C. H.; Ohnsorge, J. A. K.; Niedhart, C. Lack of Effect on Bone
750 Healing of Injectable BMP-2 Augmented Hyaluronic Acid. *Arch. Orthop. Trauma Surg.* **2008**, *128* (12),
751 1461–1466. <https://doi.org/10.1007/s00402-008-0608-8>.
752 (67) Chang, Y. L.; Lo, Y. J.; Feng, S. W.; Huang, Y. C.; Tsai, H. Y.; Lin, C. T.; Fan, K. H.; Huang, H. M. Bone
753 Healing Improvements Using Hyaluronic Acid and Hydroxyapatite/Beta-Tricalcium Phosphate in
754 Combination: An Animal Study. *Biomed Res. Int.* **2016**, *2016*. <https://doi.org/10.1155/2016/8301624>.
755
756