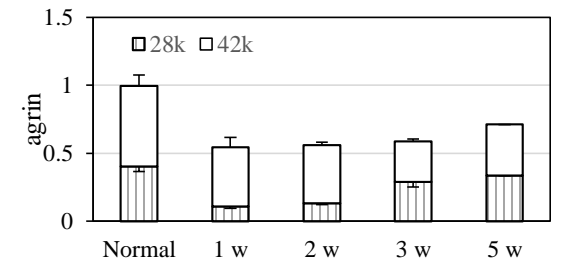
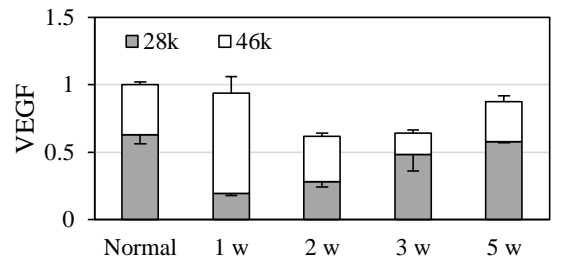
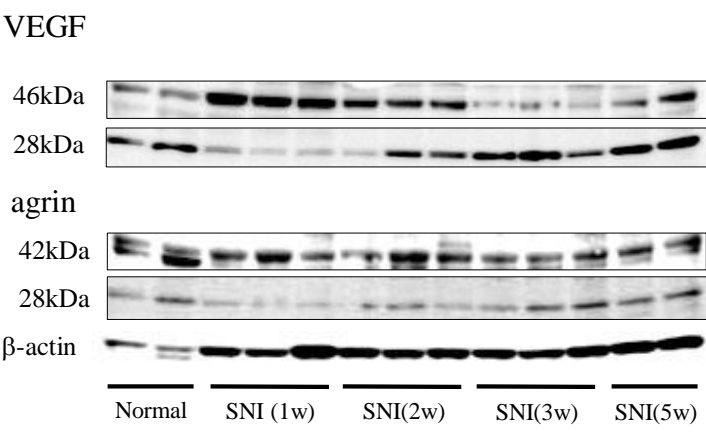
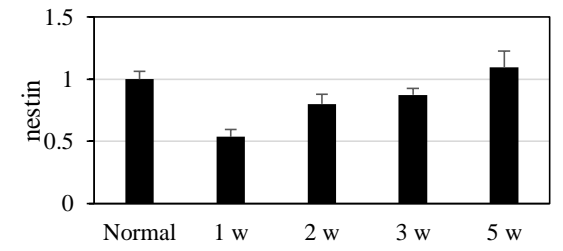
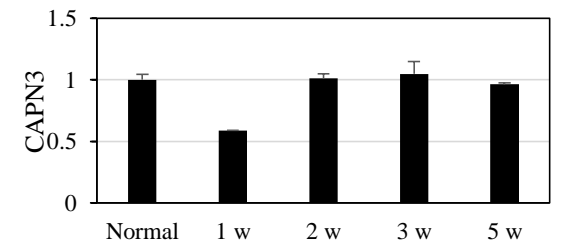
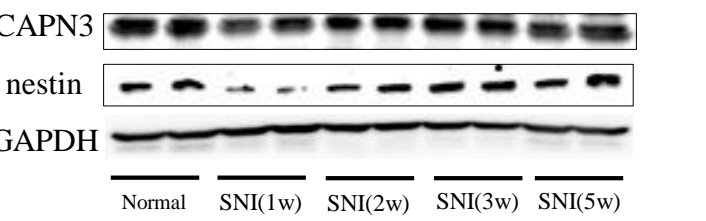
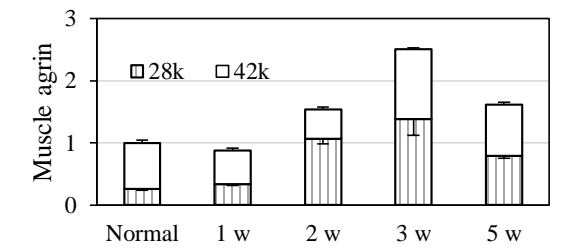
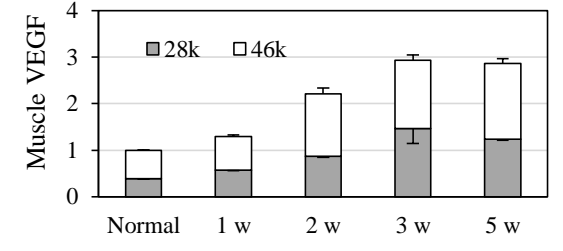
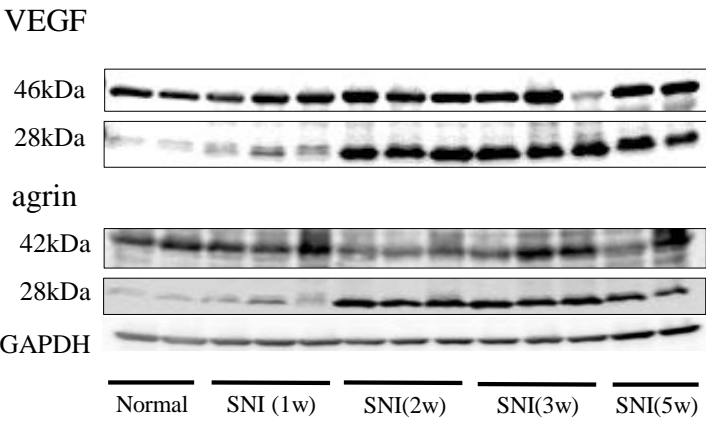


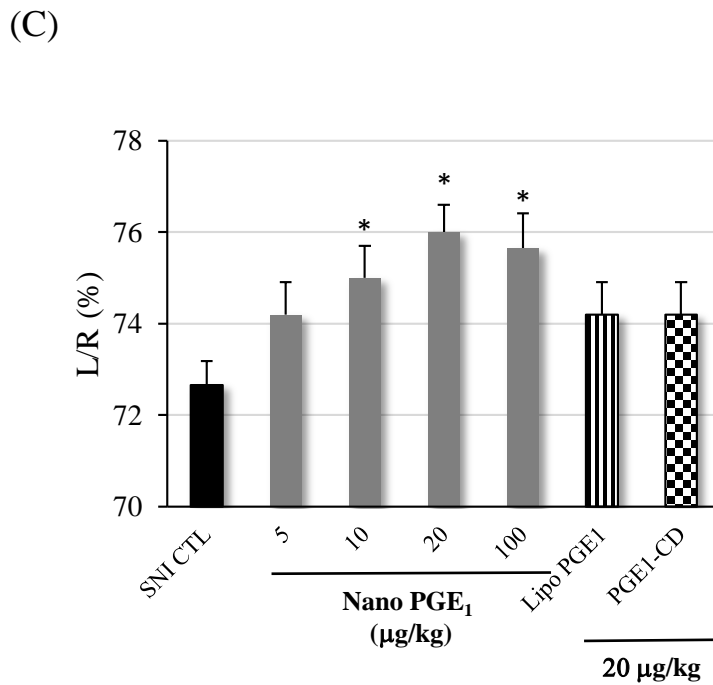
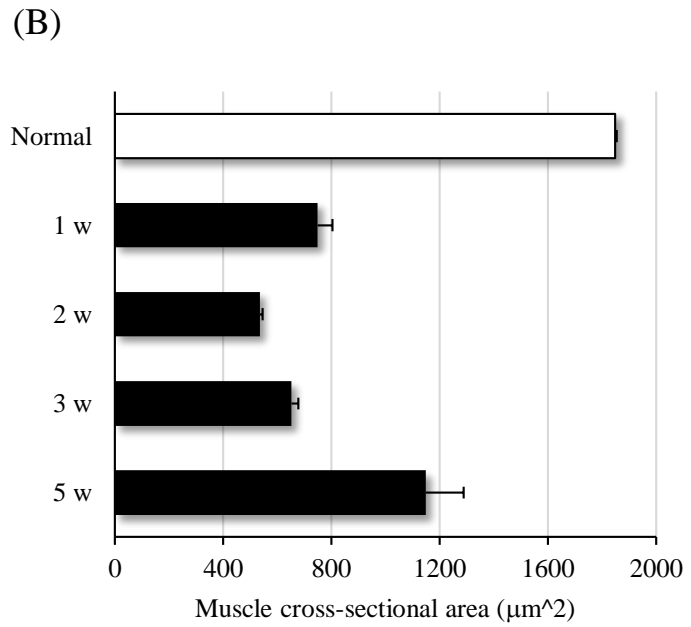
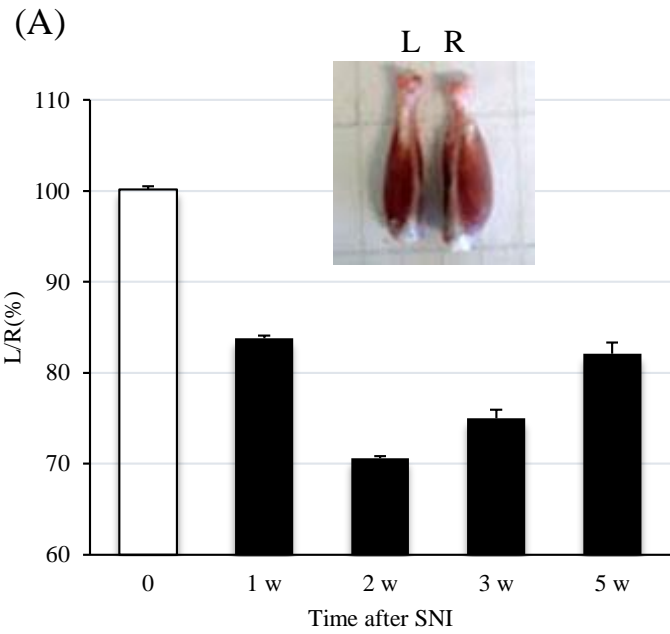
(A) Injured sciatic nerve



(B) Atrophic muscle



Supplemental Fig. 1 (Fig. S1)



Supplemental Fig. 2 (Fig. S2)