

The technique for organ retrieval with inner transverse transection of abdominal wall floors except for skin

Tuğrul Çakır, Arif Aslaner, Kemal Eyvaz, Murat Kazım Kazan

University of Health Sciences, Antalya Training and Research Hospital, Department of Organ Transplantation and General Surgery, Antalya, TURKEY

Abstract:

Aim: To describe a technique for retrieval of abdominal organs of a cadaveric donor

Methods: Only the inner transverse transection of abdominal wall floors except skin was performed

Results: The good exposure of abdominal closure with the retrieval of the liver, both kidneys and spleen easily.

Conclusion: The technique can be feasible in cadaveric organ retrieval from the abdomen.

Keywords: technique, transplantation, cadaveric, donor, retrieval

1. Introduction

A usable technique of harvesting of the cadaveric donor helps to ensure a good exposure. The aim of reporting this technique is to describe a simple, feasible and easy method for retrieval of the liver, both kidneys and spleen from a cadaveric donor performing an inner transverse intraabdominal incision except skin only.

2. Surgical procedure

Exact details of the procedure were explained and a patient informed consent was obtained from her parent. After induction of anaesthesia, a midline incision is made with a lancet and electrocautery from the infrasternal notch to pubis and also hemostasis is obtained. To achieve a good exposure, at the umbilical level abdomen is hanged with two Kocher clamps and parietal peritoneum is cut with electrocautery. Then all the abdominal wall floors except the skin were sealed and cut with vessel sealers to the lateral abdominal walls. From the edges of the inner fascia corners the abdominal wall was strengthened to the outside four quadrant of abdominal skin. (Figure 1) After this retraction routine abdominal exploration was performed. The liver is evaluated with its consistency, color, and size. After the retrieval of all intraabdominal organs such as liver, both kidneys, spleen and in such cases the vessels, abdominal incision was closed

anatomically. Inner layer was adducted with 1 no PDS from both lateral edges to middle at the umbilical level. The abdomen was closed from craniocaudally with 1 no PDS. Skin was closed with titanium staplers or 3/0 prolene sutures. (Figure 2)

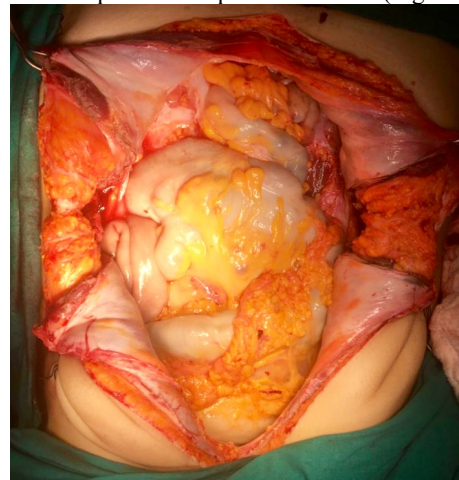


Fig-1: Effective exposure was occurred with an outside vertical incision not seeing the inner transverse transection.

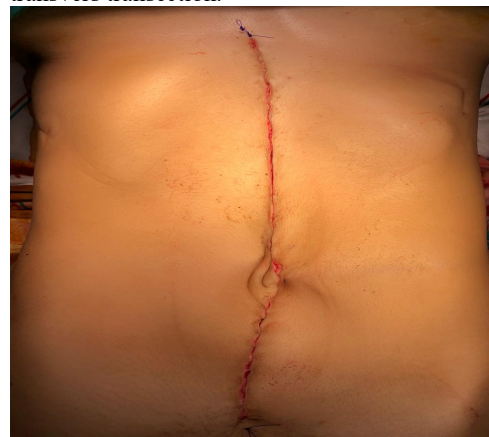

Fig-2: The abdomen was closed from craniocaudally with 1 no PDS. Skin was closed with 3/0 prolene suture.

3. Discussion

Since the earliest description of a standardized technique for multiple organ procurement [1], some modifications have been suggested to simplify the surgical methods and minimize the damage risk to the graft [2-5].

The advantage of this technique was avoidance of the need to additional outside transvers incision. The technique was simplified the surgical procedure. In the case of sensitive patient relatives of cadaver we can prefer this incision according to the wishes of the relatives.

The technique also allows a good exposure to evaluate the intraabdominal organs. After the retrieval of solid abdominal organs such as liver; kidneys and spleen, the abdominal incision was closed easily. Outside view of the abdomen of the cadaver was seen only a vertical incision without the seeing the inner transvers transection.

4. References

1. Starzl TE, Hakala TR, Shaw BW, Hardesty RL, Rosenthal TJ, Griffith BP, Iwatsuki S, Bahnson HT. A flexible procedure for multiple cadaveric organ procurement. *Surg Gynecol Obstet.* 1984;158:223–230. [PMC free article] [PubMed]
2. Lerut J, Reding R, de Ville de Goyet J, Baranski A, Barker A, Otte JB. Technical problems in shipped hepatic allografts: the UCL experience. *Transpl Int.* 1994;7:297–301. [PubMed]
3. Sheil AG, Thompson JF, Stephen MS, Graham JC, Evers AA, Bookallil M, Kalpokas M, McCaughan GW, Dorney SF, Ekberg HB. Liver graft revascularization by donor portal vein arterialization following "no touch" donor hepatectomy. *HPB Surg.* 1988;1:57–66. [PMC free article] [PubMed]
4. Starzl TE, Miller C, Broznick B, Makowka L. An improved technique for multiple organ harvesting. *Surg Gynecol Obstet.* 1987;165:343–348. [PMC free article] [PubMed]
5. A Flexible Procedure For Multiple Cadaveric Organ Procurement Thomas E. Starzl, Thomas R. Hakala, Byers W. Shaw, Jr, Robert L. Hardesty, Thomas J. Rosenthal, Bartley P. Griffith, Shunzaburo Iwatsuki, Henry T. Bahnson *Surg Gynecol Obstet.* Author manuscript; available in PMC 2009 Aug 17. Published in final edited form as: *Surg Gynecol Obstet.* 1984 Mar; 158(3): 223–230. PMID: PMC2728063