

The Expanding Role of Radiosurgery for Brain Metastases

Mark O'Beirn¹, Helen Benghiat¹, Sara Meade¹, Geoff Heyes¹, Vijay Sawlani², Anthony Kong¹, Andrew Hartley¹, Paul Sanghera¹.

¹Hall-Edwards Radiotherapy Research Group, Queen Elizabeth Hospital Birmingham

²Neuroradiology, Queen Elizabeth Hospital Birmingham

Author for Correspondence: Paul Sanghera, Queen Elizabeth Hospital Birmingham, B15 2TH.
paul.sanghera@uhb.nhs.uk

Abstract

Stereotactic radiosurgery (SRS) has become increasingly important in the management of brain metastases due to improving systemic disease control and rising incidence. Initial trials demonstrated SRS with whole brain radiotherapy (WBRT) improved local control rates versus WBRT alone. Concerns with WBRT associated neurocognitive toxicity have contributed to greater use of SRS alone, including for patients with multiple metastases and following surgical resection. Molecular information, targeted agents and immunotherapy have also altered the landscape for the management of brain metastases. This review summarises current and emerging data on the role of SRS in the management of brain metastases.

Keywords

stereotactic radiosurgery (SRS); stereotactic radiotherapy (SRT); brain metastasis; immunotherapy; whole brain radiotherapy (WBRT)

Background

Intracranial stereotactic radiosurgery (SRS) was pioneered in the 1950s by the Swedish neurosurgeon Lars Leksell. The technique relies upon multiple beams of radiation intersecting at a target precisely located within 3 dimensions. A single high dose of radiation is delivered with very rapid dose fall off to minimise the risk of damage to adjacent tissue. The Gamma Knife was the first commercial intracranial SRS system and was based upon Lars Leksell's initial prototype, utilising fixed cobalt sources and surgical immobilisation of the skull to manage motion [1]. Subsequently the technique was replicated using linear accelerators subject to additional quality assurance and motion management strategies [2]. The Cyberknife is a specialist linear accelerator mounted on a robot also capable of delivering SRS without the need for surgical immobilisation of the skull. Small well-demarcated tumours are the most suitable targets for SRS and brain metastases are now one of the most common indications. (See figure 1)

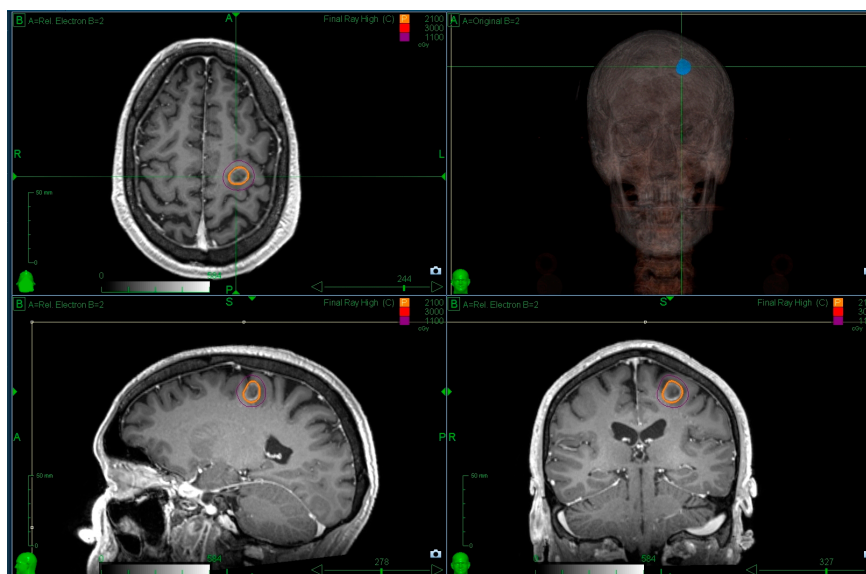


Figure 1: Radiosurgery for patients with a single metastasis and a favourable prognosis is standard practice. The figure illustrates a single metastasis covered with a prescription dose of 21Gy prescribed to the 70% isodose line using Cyberknife.

Brain metastases represent a significant cause of cancer morbidity, occurring in around 30% of patients with a malignancy originating outside the central nervous system (CNS) [3]. The management of intracranial metastatic disease is complicated by the impermeability of the blood-brain barrier to many chemotherapeutic agents, rendering this region a 'sanctuary site' for malignancies, most commonly breast, lung, melanoma and renal cell carcinoma [4]. In 1999, a single centre RCT, in which patients with 2-4 brain metastases were treated with WBRT alone or in combination with SRS, was stopped early due a significant improvement in local control in the combination arm. All the patients had local failure at 1 year in the WBRT group, compared to 8% following WBRT with SRS [5]. In 2004, the RTOG 9508 randomised trial demonstrated the addition of SRS to WBRT improved survival for patients with a single metastasis compared to WBRT alone (median survival 6.5 months v 4.9 months, $p=0.04$). Patients in the SRS group were more likely to have a stable Karnofsky Performance Status (KPS) score at six months compared to WBRT alone (43% v 27% respectively, $p=0.03$) [6]. These early studies helped to establish a role for SRS. As the principle benefit of SRS was durable control, several groups developed tools to help select those patients more likely to have a prolonged survival [7-13]. One of the earliest and simplest tools was the recursive partitioning analysis (RPA) derived from patients treated with WBRT within RTOG studies [14]. Patients were assigned to one of 3 prognostic groups based upon KPS, age, presence of extracranial disease and control of primary disease. Median survivals were 7.1, 4.2 and 2.3 months within RPA groups 1, 2 and 3 respectively. Although patients within group 1 would be candidates for SRS, the range within the middle category was broad. Subsequently, more sophisticated tools such as the disease specific graded prognostic analysis (dsGPA) have been developed which take into account the primary disease site to help selection [10]. However an analysis evaluating the utility of 6 tools found that the benefits with more sophisticated tools were modest [15]. Recently the dsGPAs have been updated for selected primary sites, taking into account molecular information where possible [16,17].

Despite the modest survival benefit limited to a single metastasis within the original RTOG randomised trial [6], on-going improvements in systemic survival, imaging and more efficient SRS technology have led to considerable expansion in practice. Furthermore, the potential for WBRT associated neurotoxicity in long-term survivors has led to a shift in practice [18]. The purpose of this review is to provide an update on the use of SRS for brain metastases within the contemporary era.

Methodology for search selection

Although not a systematic review, a literature search of Medline, the Cochrane Library, CINAHL, Embase and Google Scholar was performed using the following terms: “Stereotactic radiosurgery” or “Stereotactic radiotherapy” or “SRS” or “SRT” and “Brain Metastasis” or “Immunotherapy” or “resection”. The search focused on prospective studies, meta-analyses, systematic reviews and retrospective studies with greater than 20 cases.

Whole brain radiotherapy in combination with radiosurgery

WBRT was the historic standard of care prior to widespread use of SRS [19]. However, the principle concern with WBRT, particularly in patients with a more favourable prognosis, is the negative impact on neurocognitive function (NCF) and quality of life (QoL) [20]. NCF data is challenging to collect beyond a year and baseline impairment often occurs in the presence of brain metastases [21-23]. An imaging study with a median follow up of 6.25 years post-WBRT did show a significant impact upon the rate of cerebral atrophy [24] and several clinical studies have reported shorter term outcomes comparing WBRT with observation following SRS.

Aoyama et al. assessed NCF using mini-mental state examination (MMSE) in 92 patients randomised to SRS alone versus SRS with WBRT and reported the median time to deterioration in MMSE score by ≥ 3 points was 12.0 versus 6.6 months ($p=0.05$), respectively [25]. However, the MMSE is a poor tool to evaluate post WBRT NCF impairment [26]. Chang et al used a validated NCF tool and randomised 58 patients with 1-3 metastases between SRS alone and SRS with WBRT. The study was stopped early based upon an interim analysis of 31 patients. Patients assigned to the WBRT group were more likely to have deterioration in the primary endpoint of total recall at 4 months [27]. A larger multi-institutional study randomised 213 patients between SRS alone and SRS plus WBRT with a primary endpoint of cognitive deterioration using a validated battery of tests. There was also significantly greater deterioration at 3 months using SRS with WBRT compared to SRS alone, 91.7% versus 63.5% ($P<0.001$). The quality of life was also improved with SRS alone at 3 months ($p=0.001$). The median follow up was only 7.2 months, however, within a small subset of longer term survivors selected cognitive benefits were seen at 12 months. ($p=0.04$) [28]. A multi-centre European study randomised 359 patients with 1-3 metastases undergoing SRS or surgery between observation and adjuvant WBRT. There was no difference in the primary end point of duration of patients' functional

independence ($p=0.89$) [29]. A secondary endpoint was quality of life and patients had significantly higher global health related quality of life mean scores at 9 months with observation alone [30].

These aforementioned RCTs have consistently shown that WBRT improves intracranial control of disease, predominantly through a reduction of distant brain relapse, without a survival advantage [25, 27-29]. A meta-analysis of individual patient data within the 3 of these RCTs evaluated 364 out of 389 pooled patients. Subset analyses were performed and patients with a single metastasis had a significantly lower risk of distant brain failure than patients with 2-4 metastases ($HR=0.63$, $CI = 0.56-1.14$). Age was an important factor as a continuous variable and there was no difference in distant brain relapse between observation and WBRT in patients aged ≤ 50 years. There was also a significant survival advantage for patients aged ≤ 50 years with SRS alone and hazard ratios for patients 35, 40, 45, and 50 years of age were 0.46 (95% confidence interval (CI) 0.24-0.90), 0.52 (95% CI Z 0.29-0.92), 0.58 (95% CI Z 0.35-0.95), and 0.64 (95% CI Z 0.42-0.99), respectively [31]. The only data to support a survival advantage from the addition of WBRT to SRS comes from a post-hoc analysis of lung cancer patients treated with SRS alone or SRS and WBRT within the JROSG 99-1 study [32]. Patients with favourable prognosis lung cancer (dsGPA 2.4-4.0) had a survival advantage, median survival of 16.7 months versus 10.6 months ($p=0.04$). With any observation strategy the ability to detect progression and offer prompt salvage therapy is important to reduce the chance of neurological morbidity and death. However, most now regard the new standard for patients with 1-3 brain metastases as SRS alone [18].

Radiosurgery following surgical resection

Surgical excision is preferred for brain metastases where histological confirmation is required. Alternatively, removal of large symptomatic masses can improve quality of life and permit more prompt withdrawal of steroids. For these reasons direct comparison of SRS to surgical resection has proved difficult with one attempted prospective study failing to accrue and closing early without providing an answer [33].

Failure in the surgical bed occurs in approximately 60% of cases at 2 years following resection alone and this is significantly reduced by adjuvant WBRT [29]. However, due to WBRT associated neurotoxicity there has been increasing interest in conformal therapy to the surgical cavity including SRS. In a single centre RCT, patients who had a complete resection of 1-3 brain metastases were randomly assigned to SRS of the cavity or observation. The 12-month freedom from local recurrence was 72% in the SRS group compared with 43% in the observation group with no adverse events or treatment-related deaths [34]. The median time to recurrence was 7.6 months in the observation group (95% CI 5.3months to NR) and not reached in the SRS group (95% CI 15.6 months to NR).

There was no difference in median overall survival (OS). Metastasis size was inversely correlated with better local control (LC) and tumours below 2.5cm had a 90% freedom from local recurrence. In a multicentre RCT, patients with a single resected brain metastasis were assigned to cavity SRS or WBRT with the co-primary endpoints of cognitive-deterioration-free survival and OS. Patients with a cavity of <5cm were included and the dose was determined by surgical cavity volume. The target volume consisted of the surgical cavity plus a 2mm margin. The cognitive deterioration-free survival was slightly longer in patients assigned to SRS compared to those assigned to WBRT: 3.7 months versus 3 months respectively. Cognitive deterioration at 6 months was more frequent in patients who received WBRT than those who received SRS (85% versus 52% respectively). There was no difference in the median OS between the groups, however the SRS group had inferior 6 month LC:

80.4% versus 87.1% ($p=0.00068$) and 12 month LC, 61% versus 81%, and a shorter time to intracranial tumour progression, median 6.4 months versus 27.5 months in the WBRT group ($p<0.0001$) [35]. In a small Polish study, patients undergoing resection of a single brain metastasis were randomised to WBRT or SRS or fractionated stereotactic radiotherapy (FSRT). A dose of 15-18Gy was used, or 25 Gy in 5 fractions for cavities larger than 5cm or irregular in shape. The study was underpowered to make conclusions, although the surgical bed relapse was similar in both arms and distant brain relapse was reduced with WBRT. Unlike other trials, the 2 year OS rates appeared better in the early WBRT group than the SRS group: 37 % versus 10% $p=0.015$ [36].

Although the LC with cavity SRS may be lower than with WBRT, the improvement over observation with minimal associated morbidity has led many to adopt this as standard practice. The suitability of SRS for treating targets of larger size and irregular shape is challenging due to the interpretation of postoperative changes. The approach requires cooperation with a neuro-radiologist familiar with SRS and is often suited to small cavities, many of which may be suited to primary SRS alone. Recent guidelines serve to maximise LC when choosing cavity SRS [37]. It is possible that fractionated conformal therapy offer the benefits of improve LC without WBRT associated neurotoxicity; however this remains to be evaluated prospectively against SRS and/or observation.

The role of radiosurgery for multiple metastases

Due to the aforementioned reasons, the use of WBRT has declined for patients with a favourable prognosis. With SRS technology advances, the ability to treat a larger number of metastases efficiently has evolved and become routine practice in a number of centres, although high quality evidence does not yet exist to support this approach. RCTs are currently open and evaluating the role of SRS alone versus WBRT for patients with multiple (≥ 4) metastases with regards to quality of life and neuro-cognition primary endpoints. Whilst awaiting these data to inform practice, we present a summary of the published clinical evidence.

Yamamoto et al [38] present the largest observational series of patients treated with primary SRS alone and no previous WBRT. This paper demonstrated non-inferiority in OS between cohorts of patients treated with SRS for 2-4 as compared to 5-10 metastases (10.8 months in both groups, $p = 0.78$). LC and distant brain failure rates were also not significantly different between these cohorts; suggesting number of metastases does not influence local control outcome or likelihood of distant relapse in brain. The risk of presenting with leptomeningeal disease however was significantly higher in those patients with the largest number of metastases (5-10). Importantly, median total volume of metastases was similar between the two cohorts with multiple metastases, illustrating the importance of total volume of disease when selecting patients with more numerous metastases. Furthermore, these are often highly selected patients based upon a favourable prognosis.

A number of retrospective series have also reported outcomes of patients treated with SRS for ≥ 4 brain metastases with OS data presented in Table 1 for selected series. Importantly, all of these series contain a proportion of patients treated with SRS for multiple metastases who had already received WBRT [39-42]. It is currently unknown whether the use of SRS upfront versus post WBRT differs in outcome.

Table 1. Retrospective series of patients with greater than 4 metastases treated with SRS

Reference	Year	Number of metastases	Number of patients	1 year rate of distant brain failure	Median overall survival (months)
Chang [39]	2010	6-10	58	NR	10
		11-15	17	53.1%	13
		>15	33	80.3%	8
Mohammadi [40]	2012	5-20	178	77.6%	4
Bhatnagar [41]	2006	4-18	205	43%	8
Raldow [42]	2013	5-9	84	NR	7.6
		≥ 10	19	NR	8.3

NR (Not Reported)

It appears, that OS outcomes for patients with multiple lesions treated with SRS are not inferior to those with fewer lesions, however, as with all single centre, retrospective data; this is subject to bias and randomised, prospective evaluation is required. Many confounding variables influence outcome in patients with multiple brain metastases, most importantly, performance status, age, histology, and whether the primary tumour / systemic disease is controlled. As such it is not possible to recommend a single therapeutic option of either SRS alone or WBRT at present. Patients with multiple metastases should be managed by a multi-disciplinary team with access to SRS. Those treated with SRS alone should receive regular surveillance MRI as rates of distant brain failure are high and salvage therapy should be offered (whether further SRS or WBRT) prior to neurological deterioration.

In conclusion, it is likely that both SRS and WBRT are important therapies in the management of patients with multiple brain metastases. However, the timing and combination of these still remain debatable.

Hypofractionated stereotactic radiotherapy

For large lesions or lesions close to critical structures the delivery of stereotactic radiotherapy in multiple fractions may be radiobiologically advantageous due to the higher tolerances of normal tissues to fractionation. Table 2 details fifteen series employing 2-7 fractions of radiotherapy where 2 month local control ranging between 49 and 96% are reported [43-57]. Studies were excluded from table 2 if 12 month LC outcomes were not analysed or if hypofractionated stereotactic radiotherapy (hFSRT) was performed postoperatively to the tumour cavity and these patients not separated in the analysis [58-64].

Reference	Year	No of Patients/ (Lesions)	Whole Brain RT	Median Dose /fraction	Median GTV (cm ³)	12 month local Control	Size specific 12month local control
Aoyama [43]	2003	87 (159)	0 (0%)	35Gy/4#	3.3 (0.006-48.3)	81%	>3cm ³ 59%
Ernst Stecken [44]	2006	51 (72)	29 (57%) ^A	30-35Gy/5#	6 (0.29-65.57)	76%	NR
Aoki [45]	2006	44 (65)	0 (0%)	24Gy/4#	NR	72%	>2cm diameter 79%
Narayana [46]	2007	20 (20)	0 (0%)	30Gy/5#	3.5 (2-5)	70%	NR
Giubilei [47]	2009	30 (41)	30 (100%) ^A	18Gy/3#	4.8 (0.4-24.3)	86%	>2.1cm diameter 80%
Higuchi [48]	2009	43 (46)	0 (0%)	30Gy/3#	17.6 (10-35.5)	76%	NR
Kwon [49]	2009	27 (52)	NR ^B	25Gy/5#	NR	68%	>2cm diameter 38%
Kim [50]	2011	40 (49)	16 (40%)	36Gy/6#	NR	69%	NR
Fokas [51]	2012	61 (NR)	0 (0%)	35Gy/7#	NR	75%	NR
		61 (NR)	0 (0%)	40Gy/4#	NR	71%	NR
Märtens [52]	2012	75 (108)	34 (45%) ^C	35Gy/7#	NR	52%	NR
		41 (52)	0 (0%)	35Gy/7#	1 (0.1-19)	55%	NR
		34 (56)	34 (100%) ^C	30Gy/6#	2 (0.1-29.2)	49%	NR
Matsuyama [53]	2013	299 (NR)	31 (10%) ^D	36Gy/2#	NR	95%	>2cm diameter 85%
Rajakesari [54]	2014	70 (NR)	40 (58%) ^E	25Gy/5#	NR	56%	NR
Minniti [55]	2014	135 (171)	0 (0%)	27Gy/3#	10.1 (1.6-48.4)	88%	NR
Navarria [56]	2016	102 (102)	0 (0%)	27Gy/3#, 32Gy/4#	16.3 (3.9-64.5)	96%	NR
Marcrom [57]	2017	72 (182)	5 (7%) ^F	30Gy/5#	2.02 (0.01-39)	86%	>3cm diameter 61%, >2cm 74%

Table 2. Fractionated Stereotactic Radiotherapy for Brain Metastasis Series

RT radiotherapy; GTV gross tumour volume; Gy Gray; # number of fractions; NR not reported; A: WBRT followed by FSRT boost; B: 45/52 (86.5%) lesions treated with whole brain radiotherapy followed by FSRT boost; C: Median time from WBRT to FSRT in months of 12.7 months (0.5-28.8); D: Received WBRT before or after FSRT; E: 10 patients (14%) treated with FSRT within 3 months of WBRT; F: Previous WBRT, not given to lesions of interest

The data are difficult to interpret as detail on the size of lesions treated is omitted in some series and the use and size of a PTV margin is variable. In addition, some series included patients who had received WBRT. In three series, where 10% or less patients received WBRT, the rate of 12 month local control in patients with tumours > 2cm control was 74-85% [45, 53, 57]. In two series, where significant numbers of patients received WBRT, the corresponding range was 38-80% [47, 49]. A comparison of late toxicity rates between these series is hampered by heterogeneity in reporting and definition. However, the rates of reported significant late toxicity appear low.

A pooled quantitative analysis of 10 retrospective studies of hFSRT demonstrated higher rates of local control when higher biological effective dose regimes were used [65]. Although hFSRT is in widespread use; a definitive prospective study to define appropriate dose, fractionation and provide the evidence base for this treatment is desirable. Further retrospective studies are likely to be confounded by the factors described above.

Combining immunotherapy with SRS

The ability to boost the immune response against malignant tumours has been one of most significant oncological advances in recent years. New agents are used to target checkpoint pathways, including the cytotoxic T-lymphocyte-associated antigen 4 (CTLA-4) pathway, which downregulates early T-cell function, and the programmed death 1 (PD-1) pathway, which regulates T-cell activity. Immune checkpoint inhibition (ICI) prevents down-regulation of T-cell activation and potentiates the anti-tumour response. Prolonged survival from metastatic disease has been demonstrated in several cancers including melanoma, non-small cell lung cancer and renal cell cancer [66-69]. Early RCTs excluded patients with brain metastases, however recent phase 2 data support that ICI can have an impact within the brain [70,71]

There has been significant debate with regards to a synergy between ICI and radiotherapy, including SRS. The immune cells including both T cells and myeloid cells are critical in mediating treatment response to radiotherapy [72-74]. Radiotherapy has been shown to induce the accumulation of myeloid-derived suppressive cells (MDSCs) and up-regulate programmed death ligand 1 (PD-L1) expression in the tumour microenvironment, restricting its anti-tumour effect [75]. The addition of PD-1 antibody with radiotherapy has been shown to be synergistic in inhibiting tumour growth as well as mediating an abscopal effect on distant non-irradiated tumours by increasing CD8+ T cell response and reducing the local accumulation of MDSCs through TNF [75]. In addition to preclinical models, PD-L1 expression and tumour-infiltration lymphocytes have been found in brain metastasis samples across several solid tumour sites supporting the hypothesis of benefit from targeting this pathway [76-78].

Although an early retrospective series evaluating a mixture of systemic therapies suggested an increased risk of toxicity with concurrent ICI [79], evidence is now mounting in favour of a

combination approach. A single prospective phase I study has confirmed the short-term safety of the CTLA-4 antibody ipilimumab with SRS [80]. Several retrospective series have also reported the safety profile of SRS with ipilimumab to be similar to SRS alone [81-86]. Some studies have suggested outcomes were better with a combined approach of ipilimumab and SRS [83,86,87]. A combined institutional analysis of 99 patients with metastatic melanoma reported improved intracranial control using SRS within 5.5 months of ipilimumab (median 3.63 vs. 8.09 months; hazard ratio [HR] 2.07, 95% confidence interval [CI] 1.03–4.16, $p = 0.041$) [87]. In another study of SRS for melanoma patients with brain metastases, concurrent treatment with ipilimumab improved local control compared to sequential treatment of SRS after ipilimumab [86].

Prospective data of anti-PD1 therapy with SRS is lacking, however an analysis combining data from 2 prospective trials of patients with melanoma looked at 26 patients with brain metastases treated with SRS within 6 months of receiving nivolumab (either before, during, or after nivolumab administration). There was 1 grade 2 headache following SRS but no other treatment-related neurological toxicities [88]. Several retrospective cohorts have reported acceptable toxicity and possible advantages combining anti-PD1 therapy with SRS [89-91]. One retrospective study evaluated 623 brain metastases within 260 patients and used multivariate analysis (MVA) to explore the impact of sequencing and type of ICI [89]. Using MVA, OS for patients treated with SRS/SRT and concurrent ICI was significantly higher than with non-concurrent SRS/SRT ($p=0.006$) and SRS/SRT alone ($p=0.002$). OS was also better for patients receiving anti PD1 therapy compared to anti CTLA-4 therapy ($p=0.004$) and concurrent ICI reduced the likelihood of new brain metastases ($p=0.045$).

Phase III data have shown that combination CTLA-4 and PD -1 inhibition improves progression free survival within melanoma establishing a new standard of care [67]. Phase II data have recently been reported suggesting that this combination approach also gives a greater response within the brain leading some to question the need for radiotherapy [70]. However, the durability of local control with ICI therapy alone compared to SRS remains unclear. It is possible that combination ICI with SRS

offers the optimum outcome with regards to intracranial control and such a strategy is currently under evaluation for patients with limited melanoma brain metastases [92].

Available data to guide decisions using ICI with SRS are retrospective, subject to a multiple confounding variables and complicated by a dynamic landscape with regards to the licensing of new agents and combinations. It is important that SRS is incorporated into prospective studies and patients with brain metastases are not automatically excluded from evaluation of new agents.

Response assessment following radiosurgery

Serial structural Magnetic Resonance Imaging (MRI) remains the standard method of assessing response following SRS to brain metastases. However, in assessing response to SRS, structural MRI is reliant upon contrast enhancement pattern changes and alterations in T2/fluid-attenuated inversion recovery (FLAIR) weighting, which cannot sufficiently differentiate local tumour recurrence from SRS-induced changes [93]. In a series of 500 brain metastases treated with SRS, Patel et al. reported one-third of the lesions had a transient size increase following treatment, starting as early as six weeks, and could be observed up to 15 months post-SRS [94]. It is estimated that between 30-75% of radiographically enlarging SRS-treated brain metastases are due to radiation-related changes alone [95-100]. In recognition of the increasing proportion of patients with brain metastases treated with more aggressive local treatment, and the increasing inclusion of this patient cohort in clinical trials, the international multidisciplinary Response Assessment in Neuro-Oncology Brain Metastases (RANO-BM) working group has published a guideline on standard response and progression criteria based on MRI [93]. However, the guidelines acknowledge the challenges in response assessment following SRS, recommending a short interval follow-up MRI in situations of uncertainty and consideration of more advanced tests dependent upon local experience.

The use of MRI with delayed contrast extravasation more than one hour following contrast injection has been reported to show differentiation between tumour recurrence and radiation changes [101]. Zach et al used delayed contrast to develop treatment response assessment maps for both primary and metastatic brain tumours. The study included 26 brain metastases evaluated with histological correlation and sensitivity/PPV for active tumour was reported as 100%/89%. Other advanced MRI methods that can monitor physiological and metabolic properties of tumour are being investigated to help distinguish radiation change from progression. These include diffusion-weighted imaging (DWI), perfusion-weighted imaging (PWI), and MR spectroscopy (MRS). The authors have been

investigating the use of apparent diffusion coefficient (ADC), relative cerebral blood volume (rCBV) and the relative metabolite levels, particularly the choline to creatinine ratio from MR spectroscopy (Cho:Cr). Although there is data supporting the utility of each of these methods [95, 96, 98, 100], limitations remain such that no single method is currently validated. It is possible that a combination multiparametric MRI protocol may provide a higher degree of confidence in gauging brain metastasis response post-SRS, however prospective validation is required.

Radiosurgery technical developments

As discussed above, based on the available evidence there is a trend away from WBRT and towards the use of SRS for multiple metastases. With modern dedicated SRS platforms such as Gamma Knife and Cyberknife it is possible to routinely treat multiple metastases in a single session (see figure 2). Linear accelerators are more readily available than dedicated SRS machines and are also capable of delivering highly conformal therapy with increasing accuracy. Exploiting such readily available technology may help to meet the rising demand for SRS to brain metastases. Other advantages include the speed with which patients could be treated using techniques such as volumetric modulated arc therapy (VMAT) and the avoidance of surgical immobilisation. Conventional linear accelerator SRS uses several beams or arcs to treat individual targets at the isocentre and can prove inefficient when treating multiple metastases [104]. Hyperarc™ (Varian Medical System Inc., Palo Alto, CA, USA) is a recent software development automating the delivery of multiple non co-planar VMAT arcs to several targets around a single isocentre, thereby avoiding the need for verification at each isocentre [102,103]. HyperArc™ has been shown to be capable of delivering a higher Conformity Index, Gradient Index and reduced treatment times compared to conventional multiple isocentre VMAT SRS [102]. At treatment planning level this single isocentre VMAT technique can achieve similar dose metrics to Gamma Knife and cyberknife for multiple metastases [103,104]. However, dedicated SRS machines such as Cyberknife and Gamma Knife routinely deliver treatment without the application of an uncertainty margin, including without surgical immobilisation, and this factor has to be taken into account.

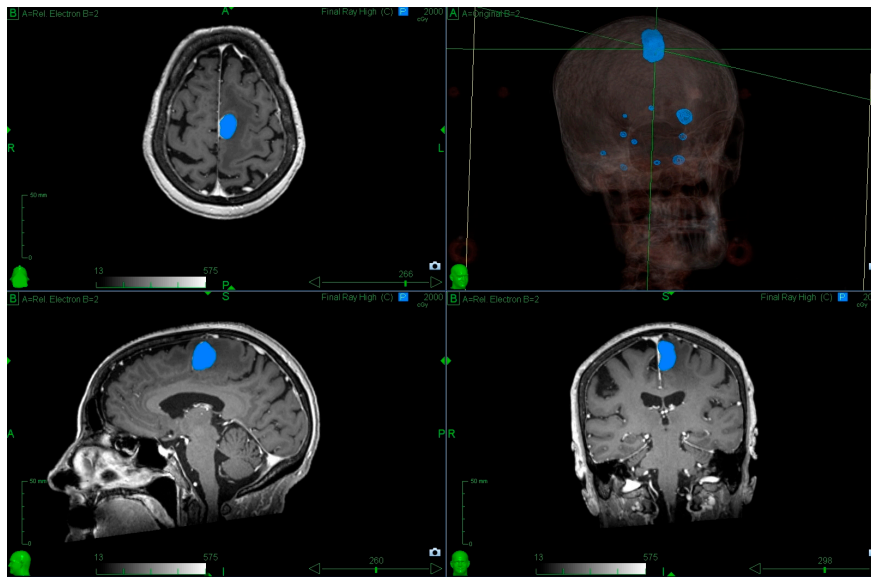


Figure 2: Radiosurgery to multiple metastases. The patient was referred with a symptomatic left frontal lobe metastasis; however there were 11 metastases in total and it was possible to treat all within a single session. The blue outline indicates the 20Gy isodose (minimum dose prescribed to the left frontal lobe metastasis).

Adapted conventional machines, with a comprehensive quality assurance programme can achieve 1mm positional uncertainty for frameless deliveries with interfraction imaging [105]. For the treatment of multiple metastasis, however, single isocentre treatments can lead to a magnification of spatial positioning uncertainties at increasing distances from the isocentre[106]. This leads to the requirement to add a CTV-PTV margin in order to ensure target coverage, which may be up to 2mm for distant lesions [106]. Studies using non-invasive head frames and CBCT imaging have been shown to be able to achieve millimetre accuracy, but even with these systems there is reluctance to treat metastases in eloquent locations [107]. Although there will be inherent uncertainties to all systems, the application of a margin has to be considered carefully given that it may be associated with an increased risk of toxicity [108]. Many of the published series to date have used platforms that have not applied a margin establishing a reference standard of care. The combined steep gradient achievable via conical collimation and the ability to treat without a margin, still makes dedicated platforms highly suited for small multiple lesions.

Summary

The use of SRS for brain metastases used to be confined to highly selected patients and often restricted to a small number of units. Significant improvements in systemic control and increasing concerns with WBRT associated toxicity have changed the landscape. Technical developments permit SRS to be delivered to multiple metastases providing the prognosis warrants such an approach. To optimise outcomes, at present patients with brain metastases should be managed collaboratively between systemic cancer specialists and neurosciences centres with access to SRS, neurosurgery and specialist imaging.

References

1. Leksell, L. The stereotaxic method of radiosurgery of the brain. *Acta Chir Scand.* 1951 1002:316-319
2. Winston, K.R.; Lutz, W. Linear accelerator as a neurosurgical tool for stereotactic radiosurgery. *Neurosurgery.* 1987 22:454-464
3. Frisk, G.; Svensson, T.; Bäcklund, L.M.; Lidbrink, E.; Blomqvist, P.; Smedby, K.E. Incidence and time trends of brain metastases admissions among breast cancer patients in Sweden. *British Journal of Cancer.* 2012 106(11):1850-1853. doi : 10.1038/bjc.2012.163.
4. Schouten, L.J.; Rutten, J.; Huveneers, H.A.; Twijnstra, A. Incidence of brain metastases in a cohort of patients with carcinoma of the breast, colon, kidney, and lung and melanoma. *Cancer.* 2002 May 15;94(10):2698-705. doi : 10.1002/cncr.10541
5. Kondziolka, D.; Patel, A.; Lunsford, L.D.; Kassam, A.; Flickinger, J.C. Stereotactic radiosurgery plus whole brain radiotherapy versus radiotherapy alone for patients with multiple brain metastases. *Int. J. Radiat. Oncol. Biol. Phys.* 1999 45:427–434
6. Andrews, D.W.; Scott, C.B.; Sperduto, P.W.; Flanders, A.E.; Gaspar, L.E.; Schell, M.C.; Werner-Wasik, M.; Demas, W.; Ryu, J.; Bahary, J.P.; Souhami, L.; Rotman, M.; Mehta, M.P.; Curran, W.J.Jr. Whole brain radiation therapy with or without stereotactic radiosurgery boost for patients with one

to three brain metastases: phase III results of the RTOG 9508 randomised trial. *Lancet*. 2004
363:1665–1672. doi : 10.1016/S0140-6736(04)16250-8.

7. Lagerwaard, F.J.; Levendag, P.C.; Nowak, P.J.; Eijkenboom, W.M.; Hanssens, P.E.; Schmitz, P.I.

Identification of prognostic

factors in patients with brain metastases: a review of 1292 patients. *Int J*

Radiat Oncol Biol Phys. 1999 43:795–803.

8. Weltman, E.; Salvajoli, J.V.; Brandt, R.A.; de Moraes Hanriot, R.; Prisco, F.E.; Cruz, J.C.; de Oliveira

Borges, S.R.; Wajsbrot, D.B. Radiosurgery for brain metastases: a

score index for predicting prognosis. *Int J Radiat Oncol Biol Phys*.

2000 46:1155–61.

9. Lorenzoni, J.; Devriendt, D.; Massager, N.; David, P.; Ruíz, S.; Vanderlinden, B.; Van Houtte, P.;

Brotchi, J.; Levivier, M. Radiosurgery for treatment of brain

metastases: estimation of patient eligibility using three stratification systems.

Int J Radiat Oncol Biol Phys. 2004 60:218–24. doi : 10.1016/j.ijrobp.2004.02.017

10. Sperduto, P.W.; Berkey, B.; Gaspar, L.E.; Mehta, M.; Curran, W.

A new prognostic index and comparison to three other indices for patients with brain metastases: an
analysis of 1,960 patients in the RTOG database.

Int J Radiat Oncol Biol Phys. 2008 Feb 1;70(2):510-4. doi : 10.1016/j.ijrobp.2007.06.074

11. Golden, D.W.; Lamborn, K.R.; McDermott, M.W.; Kunwar, S. Wara, W.M.; Nakamura, J.L.; Sneed,

P.K. Prognostic factors and grading systems for overall survival in patients treated with radiosurgery for brain metastases: variation by primary site. *J Neurosurg.* 2008 Dec;109 Suppl:77-86. doi : 10.3171/JNS/2008/109/12/S13.

12. Sperduto, P.W.; Chao, S.T.; Sneed, P.K.; Luo, X.; Suh, J.; Roberge, D.; Bhatt, A.; Jensen, A.W.; Brown, P.D.; Shih, H.; Kirkpatrick, J.; Schwer, A.; Gaspar, L.E.; Fiveash, J.B.; Chiang, V.; Knisely, J.; Sperduto, C.M.; Mehta, M. Diagnosis-specific prognostic factors, indexes, and treatment outcomes for patients with newly diagnosed brain metastases: a multi-institutional analysis of 4,259 patients. *Int J Radiat Oncol Biol Phys.* 2010 Jul 1;77(3):655-61. doi : 10.1016/j.ijrobp.2009.08.025.

13. Rades, D.; Dziggel, L.; Haatanen, T.; Veninga, T.; Lohynska, R.; Dunst, J.; Schild, S.E. Int J Scoring systems to estimate intracerebral control and survival rates of patients irradiated for brain metastases. *Radiat Oncol Biol Phys.* 2011 Jul 15;80(4):1122-7. doi : 10.1016/j.ijrobp.2010.03.031.

14. Gaspar, L.; Scott, C.; Rotman, M.; Asbell, S.; Phillips, T.; Wasserman, T.; McKenna, W.G.; Byhardt, R. Recursive partitioning analysis (RPA) of prognostic factors in three Radiation Therapy Oncology Group (RTOG) brain metastases trials. *Int J Radiat Oncol Biol Phys.* 1997 37, 745–751

15. Zindler, J.D.; Rodrigues, G.; Haasbeek, C.J.A.; De Haan, P.F.; Meijer, O.W.M.; Slotman, B.J.; Lagerwaard, F.J. The clinical utility of prognostic scoring systems in patients with brain metastases treated with radiosurgery. *Radiother Oncol.* 2013 Mar; 106(3): 370–374. doi : 10.1016/j.radonc.2013.01.015

16. Sperduto, P.W.; Jiang, W.; Brown, P.D.; Braunstein, S.; Sneed, P.; Wattson, D.A.; Shih, H.A.;

Bangdiwala, A.; Shanley, R.; Lockney, N.A.; Beal, K.; Lou, E.; Amatruda, T.; Sperduto, W.A.; Kirkpatrick, J.P.; Yeh, N.; Gaspar, L.E.; Molitoris, J.K.; Masucci, L.; Roberge, D.; Yu, J.; Chiang, V.; Mehta, M. Estimating Survival in Melanoma Patients With Brain Metastases: An Update of the Graded Prognostic Assessment for Melanoma Using Molecular Markers (Melanoma-molGPA). *International Journal of Radiation Oncology Biology Physics*. 2017 99 (4) , pp. 812-816. doi : 10.1016/j.ijrobp.2017.06.2454

17. Sperduto, P.W.; Yang, T.J.; Beal, K.; Pan, H.; Brown, P.D.; Bangdiwala, A.; Shanley, R.; Yeh, N.; Gaspar, L.E.; Braunstein, S.; Sneed, P.; Boyle, J.; Kirkpatrick, J.P.; Mak, K.S.; Shih, H.A.; Engelman, A.; Roberge, D.; Arvold, N.D.; Alexander, B.; Awad, M.M.; Contessa, J.; Chiang, V.; Hardie, J.; Ma, D.; Lou, E.; Sperduto, W.; Mehta, M.P. Estimating Survival in Patients With Lung Cancer and Brain Metastases: An Update of the Graded Prognostic Assessment for Lung Cancer Using Molecular Markers (Lung-molGPA). *JAMA Oncol*. 2017 Jun 1;3(6):827-831. doi : 10.1001/jamaoncol.2016.3834.

18. Brown, P.D.; Ahluwalia, M.S.; Khan, O.H.; Asher, A.L.; Wefel, J.S.; Gondi, V. Whole-Brain Radiotherapy for Brain Metastases: Evolution or Revolution? *Journal of Clinical Oncology*. 2018 36:5, 483-491. doi : 10.1200/JCO.2017.75.9589.

19. Borgelt, B.; Gelber, R.; Kramer, S.; Brady, L.W.; Chang, C.H.; Davis, L.W.; Perez, C.A.; Hendrickson, F.R. The palliation of brain metastases: Final results of the first two studies by the radiation therapy oncology group. *International Journal of Radiation Oncology, Biology, Physics*. 1980 6 (1) , pp. 1-9.

20. Pinkham, M.B.; Sanghera, P.; Wall, G.K.; Dawson, B.D.; Whitfield, G.A. Neurocognitive Effects Following Cranial Irradiation for Brain Metastases. *Clinical Oncology*. 2015 27 (11) , pp. 630-639.

21. Meyers, C.A.; Smith, J.A.; Bezjak, A.; Mehta, M.P.; Liebmann, J.; Illidge, T.; Kunkler, I.; Caudrelier, J-M.; Eisenberg, P.D.; Meerwaldt, J.; Siemers, R.; Carrie, C.; Gaspar, L.E.; Curran, W.; Phan, S-C.; Miller, R.A.; Renschler, M.F. Neurocognitive Function and Progression in Patients With Brain Metastases Treated With Whole-Brain Radiation and Motexafin Gadolinium: Results of a Randomized Phase III Trial. *Journal of Clinical Oncology*. 2004 22:1, 157-165. doi : 10.1200/JCO.2004.05.128

22. Regine W.F, Scott C., Murray K., Curran W. Neurocognitive outcome in brain metastases patients treated with accelerated-fractionation vs. accelerated-hyperfractionated radiotherapy: An analysis from Radiation Therapy Oncology Group Study 91-04. *International Journal of Radiation Oncology Biology Physics*. 2001 51 (3) , pp. 711-717. doi : 10.1016/S0360-3016(01)01676-5

23. Corn, B.W.; Moughan, J.; Knisely, J.P.S.; Fox, S.W.; Chakravarti, A.; Yung, W.K.A.; Curran, Jr. W.J.; Robins, H.I.; Brachman, D.G.; Henderson, R.H.; Mehta, M.P.; Movsas, B. Prospective Evaluation of Quality of Life and Neurocognitive Effects in Patients With Multiple Brain Metastases Receiving Whole-Brain Radiotherapy With or Without Thalidomide on Radiation Therapy Oncology Group (RTOG) Trial 0118. *International Journal of Radiation Oncology Biology Physics*. 2008 71 (1) , pp. 71-78. doi : 10.1016/j.ijrobp.2007.09.015

24. Sanghera, P.; Gardner, S.L.; Scora, D.; Davey, P. Early Expansion of the Intracranial CSF Volume After Palliative Whole-Brain Radiotherapy: Results of a Longitudinal CT Segmentation Analysis. *International Journal of Radiation Oncology Biology Physics*. 2010 76 (4) , pp. 1171-1176. doi :

10.1016/j.ijrobp.2009.03.016

25. Aoyama, H.; Shirato, H.; Tago, M.; Nakagawa, K.; Toyoda, T.; Hatano, K.; Kenjyo, M.; Oya, N.; Hirota, S.; Shioura, H.; Kunieda, E.; Inomata, T.; Hayakawa, K.; Katoh, N.; Kobashi, G. Stereotactic radiosurgery plus whole-brain radiation therapy vs stereotactic radiosurgery alone for treatment of brain metastases: a randomized controlled trial. *JAMA*. 2006 295: 2483–2491. doi : doi :10.1001/jama.295.21.2483

26. Meyers CA, Wefel JS. The use of the mini-mental state examination to assess cognitive functioning in cancer trials: no ifs, ands, buts, or sensitivity. *J Clin Oncol*. 2003 Oct 1;21(19):3557-8. doi : 10.1200/JCO.2003.07.080

27. Chang, E.L.; Wefel, J.S.; Hess, K.R.; Allen, P.K.; Lang, F.F.; Kornguth, D.G.; Arbuckle, R.B.; Swint, J.M.; Shiu, A.S.; Maor, M.H.; Meyers, C.A. Neurocognition in patients with brain metastases treated with radiosurgery or radiosurgery plus whole-brain irradiation: a randomised controlled trial. *Lancet Oncol*. 2009 10: 1037–1044. doi :10.1016/S1470-2045(09)70263-3

28. Brown, P.D.; Jaeckle, K.; Ballman, K.V.; Farace, E.; Cerhan, J.H.; Anderson, S.K.; Carrero, X.W.; Barker, F.G. 2nd; Deming, R.; Burri, S.H.; Ménard, C.; Chung, C.; Stieber, V.W.; Pollock, B.E.; Galanis, E.; Buckner, J.C.; Asher, A.L. Effect of Radiosurgery Alone vs Radiosurgery With Whole Brain Radiation Therapy on Cognitive Function in Patients With 1 to 3 Brain Metastases: A Randomized Clinical Trial. *JAMA*. 2016 316(4), 401–409. doi : 10.1001/jama.2016.9839

29. Kocher, M.; Soffietti, R.; Abacioglu, U.; Villà, S.; Fauchon, F.; Baumert, B.G.; Fariselli, L.;

TzukShina, T.; Kortmann, R.D.; Carrie, C.; Ben Hassel, M.; Kouri, M.; Valeinis, E.; van den Berge, D.; Collette, S.; Collette, L.; Mueller, R.P.; Adjuvant whole-brain radiotherapy versus observation after radiosurgery or surgical resection of one to three cerebral metastases: results of the EORTC 22952-26001 study. *J Clin Oncol*. 2011 Jan 10;29(2):134-41. doi :10.1200/JCO.2010.30.1655

30. Soffietti, R.; Kocher, M.; Abacioglu, U.M.; Villa, S.; Fauchon, F.; Baumert, B.G.; Fariselli, L.; Tzuk-Shina, T.; Kortmann, R.D.; Carrie, C.; Ben Hassel, M.; Kouri, M.; Valeinis, E.; van den Berge, D.; Mueller, R.P.; Tridello, G.; Collette, L.; Bottomley, A. A European Organisation for Research and Treatment of Cancer phase III trial of adjuvant whole-brain radiotherapy versus observation in patients with one to three brain metastases from solid tumors after surgical resection or radiosurgery: Quality-of-life results. *J Clin Oncol*. 2013 Jan 1; 31(1): 65–72. doi :10.1200/JCO.2011.41.0639

31. Sahgal, A.; Aoyama, H.; Kocher, M.; Neupane, B.; Collette, S.; Tago, M.; Shaw, P.; Beyene J.; Chang, E.L. Phase 3 trials of stereotactic radiosurgery with or without whole-brain radiation therapy for 1 to 4 brain metastases: individual patient data meta-analysis. *Int J Radiat Oncol Biol Phys*. 2015 91: 710–717. doi :10.1016/j.ijrobp.2014.10.024.

32. Aoyama, H.; Tago, M.; Shirato, H.; for the Japanese Radiation Oncology Study Group 99-1 (JROSG 99-1) Investigators. Stereotactic Radiosurgery With or Without Whole-Brain Radiotherapy for Brain MetastasesSecondary Analysis of the JROSG 99-1 Randomized Clinical Trial. *JAMA Oncol*. 2015 1(4):457–464. doi :10.1001/jamaoncol.2015.1145

33. Roos, D.E.; Smith, J.G.; Stephens, S.W. Radiosurgery versus surgery, both with adjuvant whole brain radiotherapy, for solitary brain metastases: A randomised controlled trial. *Clin Oncol (R Coll Radiol)*. 2011 23:646–651. doi :10.1016/j.clon.2011.04.009

34. Mahajan, A.; Ahmed, S.; McAleer, M.F.; Weinberg, J.S.; Li, J.; Brown, P.; Settle, S.; Prabhu, S.S.; Lang, F.F.; Levine, N. McGovern, S.; Sulman, E.; McCutcheon, I.E.; Azeem, S.; Cahill, D.; Tatsui, C.; Heimberger, A.B.; Ferguson, S.; Ghia, A.; Demonte, F.; Raza, S.; Guha-Thakurta, N.; Yang, J.; Sawaya, R.; Hess, K.R.; Rao, G. Post-operative stereotactic radiosurgery versus observation for completely resected brain metastases: a single-centre, randomised, controlled, phase 3 trial. *Lancet Oncol.* 2017 Aug;18(8):1040-1048. doi :10.1016/S1470-2045(17)30414-X.

35. Brown, P.D.; Ballman, K.V.; Cerhan, J.H.; Anderson, S.K.; Carrero, X.W.; Whitton, A.C.; Greenspoon, J.; Parney, I.F.; Laack, N.N.I.; Ashman, J.B.; Bahary, J.P.; Hadjipanayis, C.G.; Urbanic, J.J.; Barker, F.G.2nd; Farace, E.; Khuntia, D.; Giannini, C.; Buckner, J.C.; Galanis, E.; Roberge, D. Postoperative stereotactic radiosurgery compared with whole brain radiotherapy for resected metastatic brain disease (NCCTG N107C/CEC-3): a multicentre, randomised, controlled, phase 3 trial. *Lancet Oncol.* 2017 Aug;18(8):1049-1060. doi :10.1016/S1470-2045(17)30441-2.

36. Kepka, L.; Tyc-Szczepaniak, D.; Bujko, K.; Olszyna-Serementa, M.; Michalski, W.; Sprawka, A.; Trabska-Kluch, B.; Komosińska, K.; Wasilewska-Teśluk, E.; Czeremyszynska, B. Stereotactic radiotherapy of the tumor bed compared to whole brain radiotherapy after surgery of single brain metastasis: Results from a randomized trial. *Radiother Oncol.* 2016 Nov;121(2):217-224. doi :10.1016/j.radonc.2016.10.005.

37. Soliman, H.; Ruschin, M.; Angelov, L.; Brown, P.D.; Chiang, V.L.S.; Kirkpatrick, J.P.; Lo, S.S.; Mahajan, A.; Oh, K.S.; Sheehan, J.P.; Soltys, S.G.; Sahgal, A. Consensus Contouring Guidelines for Postoperative Completely Resected Cavity Stereotactic Radiosurgery for Brain Metastases. *Int J Radiat Oncol Biol Phys.* 2018 Feb 1;100(2):436-442. doi :10.1016/j.ijrobp.2017.09.047.

38. Yamamoto, M.; Serizawa, T.; Shuto, T.; Akabane, A.; Higuchi, Y.; Kawagishi, J.; Yamanaka, K.; Sato, Y.; Jokura, H.; Yomo, S.; Nagano, O.; Kenai, H.; Moriki, A.; Suzuki, S.; Kida, Y.; Iwai, Y.; Hayashi, M.; Onishi, H.; Gondo, M.; Sato, M.; Akimitsu, T.; Kubo, K.; Kikuchi, Y.; Shibasaki, T.; Goto, T.; Takanashi, M.; Mori, Y.; Takakura, K.; Saeki, N.; Kunieda, E.; Aoyama, H.; Momoshima, S.; Tsuchiya, K.

Stereotactic radiosurgery for patients with multiple brain metastases (JLGK0901): a multi-institutional prospective observational study. *Lancet Oncol.* 2014 Apr;15(4):387-95. doi :10.1016/S1470-2045(14)70061-0.

39. Chang, W.S.; Kim, H.Y.; Chang, J.W.; Park, Y.G.; Chang, J.H. Analysis of radiosurgical results in patients with brain metastases according to the number of brain lesions: is stereotactic radiosurgery effective for multiple brain metastases? *J Neurosurg.* 2010 Dec;113 Suppl:73-8. doi : 10.3171/2010.8.GKS10994

40. Mohammadi, A.M.; Recinos, P.F.; Barnett, G.H.; Weil, R.J.; Vogelbaum, M.A.; Chao, S.T.; Suh, J.H.; Marko, N.F.; Elson, P.; Neyman, G.; Angelov, L.
Role of Gamma Knife surgery in patients with 5 or more brain metastases. *J Neurosurg.* 2012 Dec;117 Suppl:5-12. doi : 10.3171/2012.8.GKS12983.

41. Bhatnagar, A.K.; Flickinger, J.C.; Kondziolka, D.; Lunsford, L.D. Stereotactic radiosurgery for four or more intracranial metastases. *Int J Radiat Oncol Biol Phys.* 2006 Mar 1;64(3):898-903. doi : 10.1016/j.ijrobp.2005.08.035

42. Raldow, A.C.; Chiang, V.L.; Knisely, J.P.; Yu, J.B. Survival and intracranial control of patients with 5

or more brain metastases treated with gamma knife stereotactic radiosurgery. *Am J Clin Oncol*. 2013 Oct;36(5):486-90. doi : 10.1097/COC.0b013e31825494ef.

43. Aoyama, H.; Shirato, H.; Onimaru, R.; Kagei, K.; Ikeda, J.; Ishii, N.; Sawamura, Y.; Miyasaka, K. Hypofractionated stereotactic radiotherapy alone without whole-brain irradiation for patients with solitary and oligo brain metastasis using noninvasive fixation of the skull. *Int J Radiat Oncol Biol Phys*, 2003 56, 793–800.

44. Ernst-Stecken, A.; Ganslandt, O.; Lambrecht, U.; Sauer, R.; Grabenbauer, G. Phase II trial of hypofractionated stereotactic radiotherapy for brain metastases: results and toxicity. *Radiother Onco*. 2006 81, 18–24. doi :10.1016/j.radonc.2006.08.024

45. Aoki, M.; Abe, Y.; Hatayama, Y.; Kondo, H.; Basaki, K. Clinical outcome of hypofractionated conventional conformation radiotherapy for patients with single and no more than three metastatic brain tumors, with noninvasive fixation of the skull without whole brain irradiation. *Int J Radiat Oncol Biol Phys*. 2006 64: 414–18. doi :10.1016/j.ijrobp.2005.03.017

46. Narayana, A.; Chang, J.; Yenice, K.; Chan, K.; Lymberis S.; Brennan, C.; Gutin, P.H. Hypofractionated stereotactic radiotherapy using intensity-modulated radiotherapy in patients with one or two brain metastases. *Stereotact Funct Neurosurg*. 2007 85: 82–7. doi :10.1159/000097923

47. Giubilei, C.; Ingrosso, G.; Andrea, M.; Benassi, M.; Santoni, R. Hypofractionated stereotactic radiotherapy in combination with whole brain radiotherapy for brain metastases. *J Neurooncol*.

2008 91:207–212. doi : 10.1007/s11060-008-9700-8

48. Higuchi, Y.; Serizawa, T.; Nagano, O.; Matsuda, S.; Ono, J.; Sato, M.; Iwadate, Y.; Saeki, N. Three-
Staged Stereotactic Radiotherapy without Whole Brain Irradiation for Large Metastatic Brain
Tumors. *Int J Radiat Oncol*. 2009 74(5):1543–8. doi : 10.1016/j.ijrobp.2008.10.035.

49. Kwon, A.K.; Dibiase, S.J.; Wang, B.; Hughes, S.L.; Milcarek, B.; Zhu, Y. Hypofractionated
stereotactic radiotherapy for the treatment of brain metastases. *Cancer*. 2009 115: 890–8. doi
:10.1002/cncr.24082

50. Kim, Y.J.; Cho, K.H.; Kim, J.Y.; Lim, Y.K.; Min, H.S.; Lee, S.H.; Kim, H.J.; Gwak, H.S.; Yoo, H.; Lee,
S.H. Single-dose *versus* fractionated stereotactic radiotherapy for brain metastases. *Int J Radiat
Oncol Biol Phys*. 2011 81: 483–9. doi :10.1016/j.ijrobp.2010.05.033

51. Fokas, E.; Henzel, M.; Surber, G.; Kleinert, G.; Hamm, K.; Engenhart-Cabillic, R. Stereotactic
radiosurgery and fractionated stereotactic radiotherapy: comparison of efficacy and toxicity in 260
patients with brain metastases. *J Neurooncol*. 2012 109: 91–8. doi :10.1007/s11060-012-0868-6

52. Märten, B.; Janssen, S.; Werner, M.; Frühauf, J.; Christiansen, H.; Bremer, M.; Steinmann, D.
Hypofractionated stereotactic radiotherapy of limited brain metastases: A single-centre
individualized treatment approach. *BMC Cancer*. 2012 12:497–505. doi :10.1186/1471-2407-12-497

53. Matsuyama, T.; Kogo, K.; Oya, N. Clinical outcomes of biological effective dose-based fractionated stereotactic radiation therapy for metastatic brain tumors from non-small cell lung cancer. *Int J Radiat Oncol Biol Phys.* 2013 85: 984–990 doi :10.1016/j.ijrobp.2012.07.764
54. Rajakesari, S.; Arvold, N.D.; Jimenez, R.B.; Christianson, L.W.; Horvath, M.C.; Claus, E.B.; Golby, A.J.; Johnson, M.D.; Dunn, I.F.; Lee, E.Q.; Lin, N.U.; Friesen, S.; Mannarino, E.G.; Wagar, M.; Hacker, F.L.; Weiss, S.E.; Alexander, B.M. Local control after fractionated stereotactic radiation therapy for brain metastases. *J Neurooncol.* 2014 120: 339–46. doi :10.1007/s11060-014-1556-5
55. Minniti, G.; D'Angelillo, R.M.; Scaringi, C.; Trodella, L.E.; Clarke, E.; Matteucci, P.; Osti, M.F.; Ramella, S.; Enrici, R.M.; Trodella, L. Fractionated stereotactic radiosurgery for patients with brain metastases. *J Neurooncol.* 2014 117: 295–301. doi :10.1007/s11060-014-1388-3
56. Navarria, P.; Pessina, F.; Cozzi, L.; Ascolese, A.M.; De Rose, F.; Fogliata, A.; Franzese, C.; Franceschini, D.; Tozzi, A.; D'Agostino, G.; Comito, T.; Iftode, C.; Maggi, G.; Reggiori, G.; Bello, L.; Scorsetti, M. Hypo-fractionated stereotactic radiotherapy alone using volumetric modulated arc therapy for patients with single, large brain metastases unsuitable for surgical resection. *Radiation Oncology (London, England).* 2016 11, 76. doi :10.1186/s13014-016-0653-3
57. Marcrom, S.R.; McDonald, A.M.; Thompson, J.W.; Popple, R.A.; Riley, K.O.; Markert, J.M.; Willey, C.D.; Bredel, M.; Fiveash, J.B. Fractionated stereotactic radiation therapy for intact brain metastases. *Advances in Radiation Oncology.* 2017 2(4), 564–571. doi :10.1016/j.adro.2017.07.006

58. Eaton, B.; Gebhardt, B.; Prabhu, R.; Shu, H.; Curran, W.; Crocker, I. Hypofractionated radiosurgery for intact or resected brain metastases: Defining the optimal dose and fractionation. *Radiat Oncol.* 2013 8:135–141

59. Manning, M.; Cardinale, R.; Benedict, S. Hypofractionated stereotactic radiotherapy as an alternative to radiosurgery for the treatment of patients with brain metastases. *Int J Radiat Oncol Biol Phys.* 2000 47:603–608. doi :10.1186/1748-717X-8-135

60. Lindvall, P.; Bergström, P.; Löfroth, P.O.; Henriksson, R.; Bergenheim, A.T. Hypofractionated conformal stereotactic radiotherapy alone or in combination with whole-brain radiotherapy in patients with cerebral metastases. *Int J Radiat Oncol Biol Phys.* 2005 Apr 1;61(5):1460-6. doi :10.1016/j.ijrobp.2004.08.027

61. Fahrig, A.; Ganslandt, O.; Lambrecht, U. Grabenbauer, G.; Kleinert, G.; Sauer, R.; Hamm, K. Hypofractionated stereotactic radiotherapy for brain metastases. *Strahlenther Onkol.* 2007 183:625–630. doi :10.1007/s00066-007-1714-1

62. Kim, J.W.; Park, H.R.; Lee, J.M.; Kim, J.W.; Chung, H.T.; Kim, D.G.; Jung, H.W.; Paek, S.H. Fractionated Stereotactic Gamma Knife Radiosurgery for Large Brain Metastases: A Retrospective, Single Center Study. *PLoS One.* 2016 11:e0163304. doi :10.1371/journal.pone.0163304.

63. Lockney, N.A.; Wang, D.G.; Gutin, P.H.; Brennan, C.; Tabar, V.; Ballangrud, A.; Pei, X.; Chan, T.A.;

Yamada, Y.; Yang, T.J.; Beal, K. Clinical Outcomes of Patients with Limited Brain Metastases Treated with Hypofractionated (5 × 6 Gy) Conformal Radiotherapy. *Radiotherapy and Oncology : Journal of the European Society for Therapeutic Radiology and Oncology*. 2017 123(2), 203–208. doi :10.1016/j.radonc.2017.03.018

64. Rades, D.; Bohlen, G.; Pluemer, A.; Veninga, T.; Hanssens, P.; Dunst, J.; Schild, S.E. Stereotactic radiosurgery alone versus resection plus whole-brain radiotherapy for 1 or 2 brain metastases in recursive partitioning analysis class 1 and 2 patients. *Cancer*. 2007 109(12):2515–2521. doi : 10.1002/cncr.22729.

65. Baliga, S.; Garg, M.K.; Fox, J.; Kalnicki, S.; Lasala, P.A.; Welch, M.R.; Tomé, W.A.; Ohri, N. Fractionated stereotactic radiation therapy for brain metastases: a systematic review with tumour control probability modelling. *The British Journal of Radiology*, 2017 90(1070), 20160666. doi :10.1259/bjr.20160666

66. Hodi, F.S.; Chesney, J.; Pavlick, A.C.; Robert, C.; Grossmann, K.F.; McDermott, D.F.; Linette, G.P.; Meyer, N.; Giguere, J.K.; Agarwala, S.S.; Shaheen, M.; Ernstoff, M.S.; Minor, D.R.; Salama, A.K.; Taylor, M.H.; Ott, P.A.; Horak, C.; Gagnier, P.; Jiang, J.; Wolchok, J.D.; Postow, M.A. Combined nivolumab and ipilimumab versus ipilimumab alone in patients with advanced melanoma: 2-year overall survival outcomes in a multicentre, randomised, controlled, phase 2 trial. *The Lancet Oncology*. 2016 17 (11) , pp. 1558-1568. doi :10.1016/S1470-2045(16)30366-7

67. Larkin, J.; Chiarion-Sileni, V.; Gonzalez, R.; Grob, J.J.; Cowey, C.L.; Lao, C.D.; Schadendorf, D.;

Dummer, R.; Smylie, M.; Rutkowski P.; Ferrucci P.F.; Hill, A.; Wagstaff, J.; Carlino, M.S.; Haanen, J.B.; Maio M.; Marquez-Rodas I.; McArthur, G.A.; Ascierto, P.A.; Long, G.V.; Callahan, M.K.; Postow, M.A.; Grossmann, K.; Sznol, M.; Dreno, B.; Bastholt, L.; Yang, A.; Rollin, L.M.; Horak, C.; Hodi, F.S.; Wolchok, J.D. Combined Nivolumab and Ipilimumab or Monotherapy in Untreated Melanoma. *N Engl J Med*. 2015 Sep 24; 373(13): 1270–1271. doi :10.1056/NEJMc1509660,

68. Gettinger, S.; Rizvi, N.A.; Chow, L.Q.; Borghaei, H.; Brahmer, J.; Ready, N.; Gerber, D.E.; Shepherd, F.A.; Antonia, S.; Goldman, J.W.; Juergens, R.A.; Laurie, S.A.; Nathan, F.E.; Shen, Y.; Harbison, C.T.; Hellmann, M.D. Nivolumab Monotherapy for First-Line Treatment of Advanced Non–Small-Cell Lung Cancer. *J Clin Oncol*. 2016 34:25, 2980-2987, doi :10.1200/JCO.2016.66.9929

69. McDermott, D.F.; Drake, C.G.; Sznol, M.; Choueiri, T.K.; Powderly, J.D.; Smith, D.C.; Brahmer, J.R.; Carvajal, R.D.; Hammers, H.J.; Puzanov, I.; Hodi, F.S.; Kluger, H.M.; Topalian, S.L.; Pardoll, D.M.; Wigginton, J.M.; Kollia, G.D.; Gupta, A.; McDonald, D.; Sankar, V.; Sosman, J.A.; Atkins, M.B. Survival, Durable Response, and Long-Term Safety in Patients With Previously Treated Advanced Renal Cell Carcinoma Receiving Nivolumab. *J Clin Oncol*. 2015 Jun 20;33(18):2013-20. doi : 10.1200/JCO.2014.58.1041.

70. Long G.V., Atkinson V., Lo S., Sandhu S., Guminski A.D., Brown M.P., Wilmott J.S.; Edwards, J.; Gonzalez, M.; Scolyer, R.A.; Menzies, A.M.; McArthur G.A. Combination nivolumab and ipilimumab or nivolumab alone in melanoma brain metastases: a multicentre randomised phase 2 study. *The Lancet Oncology*. 2018 19 (5) , pp. 672-681. doi :10.1016/S1470-2045(18)30139-6.

71. Goldberg, S.B.; Gettinger, S.N.; Mahajan, A.; Chiang, A.C.; Herbst, R.S.; Sznol, M.; Tsiouris, A.J.; Cohen, J.; Vortmeyer, A.; Jilaveanu, L.; Yu, J.; Hegde, U.; Speaker, S.; Madura, M.; Ralabate, A.; Rivera, A.; Rowen, E.; Gerrish, H.; Yao, X.; Chiang, V.; Kluger, H.M. A Phase II trial of pembrolizumab for patients with melanoma or non-small cell lung cancer and untreated brain metastases. *The Lancet. Oncology*. 2016 17(7), 976–983. doi :10.1016/S1470-2045(16)30053-5

72. Formenti, S.C.; Demaria, S. Combining Radiotherapy and Cancer Immunotherapy: A Paradigm Shift. *JNCI Journal of the National Cancer Institute*. 2013 105(4):256-265. doi :10.1093/jnci/djs629.

73. Shiao, S.L.; Coussens, L.M. The Tumor-Immune Microenvironment and Response to Radiation Therapy. *Journal of Mammary Gland Biology and Neoplasia*. 2010 15(4):411-421. doi :10.1007/s10911-010-9194-9.

74. Shiao, S.L.; Ganesan, A.P.; Rugo, H.S.; Coussens, L.M. Immune microenvironments in solid tumors: new targets for therapy. *Genes & Development*. 2011 25(24):2559-2572. doi :10.1101/gad.169029.111.

75. Deng, L.; Liang H.; Burnette B.; Beckett, M.; T Darga, T.; Weichselbaum, R.R.; Fu, Y.X. Irradiation and anti-PD-L1 treatment synergistically promote antitumor immunity in mice. *The Journal of Clinical Investigation*. 2014 124(2):687-695. doi :10.1172/JCI67313.

76. Berghoff, A.S.; Kiesel, B.; Georg Widhalm, G.; Rajky, O.; Ricken, G.; Wöhrer, A.; Oberndorfer, F.; Dieckmann, K.; Filipits, J.; Marosi, C.; Höller, C.; Wick, W.; Preusser, M. IB-02 ROLE OF TUMOR INFILTRATING LYMPHOCYTES AND PDL1 EXPRESSION IN GLIOBLASTOMA (GBM) AND BRAIN METASTASES (BM): COMPARATIVE ANALYSIS. *Neuro-Oncology*. 2014 16(Suppl 5):v107. doi :10.1093/neuonc/nou257.2.

77. Berghoff, A.S.; Ricken, G.; Widhalm, G.; Rajky, O.; Dieckmann, K.; Birner, P.; Bartsch, R.; Höller, C.; Preusser, M. Tumour-infiltrating lymphocytes and expression of programmed death ligand 1 (PD-L1) in melanoma brain metastases. *Histopathology*. 2015 66:289–299. doi : 10.1111/his.12537.

78. Berghoff, A.S.; Inan, C.; Ricken, G.; Widhalm, G.; Dieckmann, K.; Birner, P.; Oberndorfer, F.; Dome, B.; Bartsch, R.; Zielinski, C.; Preusser, M. 1324P TUMOR-INFILTRATING LYMPHOCYTES (TILS) AND PD-L1 EXPRESSION IN NON- SMALL CELL LUNG CANCER BRAIN METASTASES (BM) AND MATCHED PRIMARY TUMORS (PT). *Annals of Oncology*. 2014 25:(suppl_4), iv465–iv466, doi : 10.1093/annonc/mdu349.103

79. Colaco, R.J.; Martin, P.; Kluger, H.M.; Yu, J.B.; Chiang, V.L. Does immunotherapy increase the rate of radiation necrosis after radiosurgical treatment of brain metastases? *J Neurosurg*. 2016 Jul;125(1):17-23. doi :10.3171/2015.6.JNS142763.

80. Williams, N.L.; Wuthrick, E.J.; Kim, H.; Palmer, J.D.; Garg, S.; Eldredge-Hindy, H.; Daskalakis, C.; Feeney, K.J.; Mastrangelo, M.J.; Kim, L.J.; Sato, T.; Kendra, K.L.; Olencki, T.; Liebner, D.A.; Farrell, C.J.; Evans, J.J.; Judy, K.D.; Andrews, D.W.; Dicker, A.P.; Werner-Wasik, M.; Shi, W. Phase 1 Study of

Ipilimumab Combined With Whole Brain Radiation Therapy or Radiosurgery for Melanoma Patients With Brain Metastases. *Int J Radiat Oncol Biol Phys*. 2017 Sep 1;99(1):22-30. doi :10.1016/j.ijrobp.2017.05.028.

81. Silk, A.W.; Bassetti, M.F.; West, B.T.; Tsien, C.I.; Lao, C.D. Ipilimumab and radiation therapy for melanoma brain metastases. *Cancer Medicine*. 2013 2(6):899-906. doi :10.1002/cam4.140

82. Patel, K.R.; Shoukat, S.; Oliver, D.E.; Chowdhary, M.; Rizzo, M.; Lawson, D.H.; Khosa, F.; Liu, Y.; Khan, M.K. Ipilimumab and Stereotactic Radiosurgery Versus Stereotactic Radiosurgery Alone for Newly Diagnosed Melanoma Brain Metastases. *American Journal of Clinical Oncology*. 2017 40(5): p. 444-450. doi : 10.1097/COC.000000000000199

83. Knisely, J.P.; Yu, J.B.; Flanigan, J.; Sznol, M.; Kluger, H.M.; Chiang, V.L. Radiosurgery for melanoma brain metastases in the ipilimumab era and the possibility of longer survival. *J Neurosurg*. 2012 Aug;117(2):227-33. doi : 10.3171/2012.5.JNS111929.

84. Mathew, M.; Tam, M.; Ott, P.A.; Pavlick, A.C.; Rush, S.C.; Donahue, B.R.; Golfinos, J.G.; Parker, E.C.; Huang, P.P.; Narayana, A. Ipilimumab in melanoma with limited brain metastases treated with stereotactic radiosurgery. *Melanoma Res*. 2013 Jun;23(3):191-5. doi :10.1097/CMR.0b013e32835f3d90.

85. Koller, K. M.; Mackley, H. B.; Liu, J.; Wagner, H.; Talamo, G.; Schell, T. D.; Pameijer, C.; Neves, R.I.; Anderson, B.; Kokolus, K.M.; Mallon, C. A.; Drabick, J. J. Improved survival and complete response rates in patients with advanced melanoma treated with concurrent ipilimumab and radiotherapy versus ipilimumab alone. *Cancer Biology & Therapy*. 2017 18(1),36–42. doi :10.1080/15384047.2016.1264543

86. Kiess, A. P., Wolchok, J. D., Barker, C. A., Postow, M. A., Tabar, V., Huse, J. T., Chan, T.A.; Yamada, Y.; Beal, K. Stereotactic Radiosurgery for Melanoma Brain Metastases in Patients Receiving Ipilimumab: Safety Profile and Efficacy of Combined Treatment. *International Journal of Radiation Oncology, Biology, Physics*. 2015 92(2), 368–375. doi :10.1016/j.ijrobp.2015.01.004

87. An, Y.; Jiang, W.; Kim, B.Y.S.; Qian, J.M.; Tang, C.; Fang, P.; Logan, J.; D'Souza, N.M.; Haydu, L.E.; Wang, X.A.; Hess, K.R.; Kluger, H.; Glitza, I.C.; Mahajan, A.; Welsh, J.W.; Lin, S.H.; Yu, J.B.; Davies, M.A.; Hwu, P.; Sulman, E.P.; Brown, P.D.; Chiang, V.L.S.; Li, J. Stereotactic radiosurgery of early melanoma brain metastases after initiation of anti-CTLA-4 treatment is associated with improved intracranial control. *Radiother Oncol*. 2017 Oct;125(1):80-88. doi :10.1016/j.radonc.2017.08.009.

88. Ahmed, K.A.; Stallworth, D.G.; Kim, Y.; Johnstone, P.A.; Harrison, L.B.; Caudell, J.J.; Yu, H.H.; Etame, A.B.; Weber, J.S.; Gibney, G.T. Clinical outcomes of melanoma brain metastases treated with stereotactic radiation and anti-PD-1 therapy. *Ann Oncol*. 2016 Mar;27(3):434-41. doi : 10.1093/annonc/mdv622.

89. Chen, L.; Douglass, J.; Kleinberg, L.; Ye, X.; Marciscano, A.E.; Forde, P.M.; Brahmer, J.; Lipson, E.; Sharfman, W.; Hammers, H.; Naidoo, J.; Bettegowda, C.; Lim, M.; Redmond, K.J. Concurrent Immune Checkpoint Inhibitors and Stereotactic Radiosurgery for Brain Metastases in Non-Small Cell Lung Cancer, Melanoma, and Renal Cell Carcinoma. *Int J Radiat Oncol Biol Phys.* 2018 Mar 15;100(4):916-925. doi : 10.1016/j.ijrobp.2017.11.041.

90. Nardin, C.; Mateus, C.; Texier, M.; Lanoy, E.; Hibat-Allah, S.; Ammari, S.; Robert, C.; Dhermain, F. Tolerance and outcomes of stereotactic radiosurgery combined with anti-programmed cell death-1 (pembrolizumab) for melanoma brain metastases. *Melanoma Res.* 2018 Apr;28(2):111-119. doi : 10.1097/CMR.0000000000000413.

91. Anderson, E.S.; Postow, M.A.; Wolchok, J.D.; Young, R.J.; Ballangrud, Å.; Chan, T.A.; Yamada, Y.; Beal, K. Melanoma brain metastases treated with stereotactic radiosurgery and concurrent pembrolizumab display marked regression; efficacy and safety of combined treatment. *J Immunother Cancer.* 2017 5: 76. doi : 10.1186/s40425-017-0282-x

92. Anti-PD 1 Brain Collaboration + Radiotherapy: The ABC-X Study. 2018. Retrieved from <http://clinicaltrials.gov> (Identification No. NCT03340129)

93. Lin, N.U.; Lee, E.Q.; Aoyama, H.; Barani, I.J.; Barboriak, D.P.; Baumert, B.G.; Bendszus, M.; Brown, P.D.; Camidge, D.R.; Chang, S.M.; Dancey, J.; de Vries, E.G.; Gaspar, L.E.; Harris, G.J.; Hodi, F.S.; Kalkanis, S.N.; Linskey, M.E.; Macdonald, D.R.; Margolin, K.; Mehta, M.P.; Schiff, D.; Soffiatti, R.; Suh, J.H.; van den Bent, M.J.; Vogelbaum, M.A.; Wen, P.Y.; Response Assessment in Neuro-Oncology

(RANO) group. Response assessment criteria for brain metastases: proposal from the RANO group.

Lancet Oncol. 2015 Jun;16(6):e270-8. doi :10.1016/S1470-2045(15)70057-4.

94. Patel, T.R.; Mchugh, B.J.; Bi, W.L.; Minja, F.J.; Knisely, J.P.; Chiang, V.L. A comprehensive review of MR imaging changes following radiosurgery to 500 brain metastases. *AJNR Am J Neuroradiol.*

2011 32(10):1885-92. doi : 10.3174/ajnr.A2668

95. Hoefnagels, F. W. A.; Lagerwaard, F. J.; Sanchez, E.; Haasbeek, C. J. A.; Knol, D. L.; Slotman, B. J.; Vandertop, P.W. Radiological progression of cerebral metastases after radiosurgery: assessment of perfusion MRI for differentiating between necrosis and recurrence. *Journal of Neurology.* 2009

256(6), 878–887. Doi :10.1007/s00415-009-5034-5

96. Mitsuya, K.; Nakasu, Y.; Horiguchi, S.; Harada, H.; Nishimura, T.; Bando, E.; Okawa, H.; Furukawa, Y.; Hirai, T.; Endo, M. Perfusion weighted magnetic resonance imaging to distinguish the recurrence of metastatic brain tumors from radiation necrosis after stereotactic radiosurgery. *J Neurooncol.*

2010 99(1):81–8. Doi :10.1007/s11060-009-0106-z

97. Huang, B.Y.; Kwock, L.; Castillo, M.; Smith, J.K. Association of choline levels and tumor perfusion in brain metastases assessed with proton MR spectroscopy and dynamic susceptibility contrast enhanced perfusion weighted MRI. *Technol Cancer Res Treat.* 2010 Aug;9(4):32737. Doi

:10.1177/153303461000900403

98. Chernov, M.F.; Hayashi, M.; Izawa, M. Usukura, M.; Yoshida, S.; Ono, Y.; Muragaki, Y.; Kubo, O.; Hori, T.; Takakura, K. Multivoxel proton MRS for differentiation of radiation-induced necrosis and tumor recurrence after gamma knife radiosurgery for brain metastases. *Brain Tumor Pathol.* 2006 Apr; 23(1): 19–27. doi : 10.1007/s10014-006-0194-9
99. Stockham, A.L.; Suh, J.H.; Chao, S.T.; Barnett, G.H. Management of recurrent brain metastasis after radiosurgery. *Prog Neurol Surg.* 2012 25:273-86. doi : 10.1159/000331200
100. Barajas, R.F.; Chang, J.S.; Sneed, P.K.; Segal, M.R.; McDermott, M.W.; Cha, S. Distinguishing recurrent intra-axial metastatic tumor from radiation necrosis following Gamma Knife radiosurgery using dynamic susceptibility-weighted contrast-enhanced perfusion MR imaging. *AJNR Am J Neuroradiol.* 2009 30:367–372. doi :10.3174/ajnr.A1362
101. Zach, L.; Guez, D.; Last, D.; Daniels, D.; Grober, Y.; Nissim, O.; Hoffmann, C.; Nass, D.; Talianski, A.; Spiegelmann, R.; Tsarfaty, G.; Salomon, S.; Hadani, M.; Kanner, A.; Blumenthal, D.T.; Bukstein, F.; Yalon, M.; Zauberman, J.; Roth, J.; Shoshan, Y.; Fridman, E.; Wygoda, M.; Limon, D.; Tzuk, T.; Cohen, Z.R.; Mardor, Y. Delayed contrast extravasation MRI: a new paradigm in neuro-oncology. *Neuro-Oncology.* 2015 17(3), 457–465. Doi :10.1093/neuonc/nou230
102. Ruggieri, R.; Naccarato, S.; Mazzola, R.; Ricchetti, F.; Corradini, S.; Fiorentino, A.; Alongi, F. Linac-based VMAT radiosurgery for multiple brain lesions: comparison between a conventional multi-isocenter approach and a new dedicated mono-isocenter technique. *Radiat Oncol.* 2018 13: 38. doi :10.1186/s13014-018-0985-2

103. Slosarek, K.; Bekman, B.; Wendykier, J.; Grządziel, A.; Fogliata, A.; Cozzi, L. In silico assessment of the dosimetric quality of a novel, automated radiation treatment planning strategy for linac-based radiosurgery of multiple brain metastases and a comparison with robotic methods. *Radiation Oncology (London, England)*. 2018 13:41. doi :10.1186/s13014-018-0997-y.

104. Liu, H.; Andrews, D. W.; Evans, J. J.; Werner-Wasik, M.; Yu, Y.; Dicker, A. P.; Shi, W. Plan Quality and Treatment Efficiency for Radiosurgery to Multiple Brain Metastases: Non-Coplanar RapidArc vs. Gamma Knife. *Frontiers in Oncology*. 2016 6, 26. doi :10.3389/fonc.2016.00026

105. Luo, G.; Neimat, J.S.; Cmelak, A.; Kirschner, A.N.; Attia, A.; Morales-Paliza, M.; Ding, G.X. Margin of error for a frameless image guided radiosurgery system: Direct confirmation based on posttreatment MRI scans. *Practical Radiation Oncology*. 2017 7 (3) , pp. e223-e231. doi :10.1016/j.prro.2016.08.006

106. Ezzell, G.A. The spatial accuracy of two frameless, linear accelerator-based systems for single-isocenter, multitarget cranial radiosurgery. *Journal of Applied Clinical Medical Physics*. 2017 18(2):37-43. doi :10.1002/acm2.12044.

107. Babic, S.; Lee, Y.; Ruschin, M.; Lochray, F.; Lightstone, A.; Atenafu, E.; Phan, N.; Mainprize, T.; Tsao, M.; Soliman, H.; Sahgal, A. To frame or not to frame? Cone-beam CT-based analysis of head immobilization devices specific to linac-based stereotactic radiosurgery and radiotherapy. *Journal of Applied Clinical Medical Physics*. 2018 19(2), 111–120. doi :10.1002/acm2.12251

108. Nataf, F.; Schlienger, M.; Liu, Z.; Foulquier, J.N.; Gres, B.; Orthuon, A.; Vannetzel, J.M.; Escudier, B.; Meder, J-F.; Roux, F.X.; Touboul, E. Radiosurgery With or Without A 2-mm Margin for 93 Single Brain Metastases. *International Journal of Radiation Oncology Biology Physics*. 2008 70 (3) , pp. 766-772