

Case Report

Utility of Genetic Testing for Confirmation of Abnormal Newborn Screening in Disorders of Long-Chain Fatty Acids: A Missed Case of Carnitine Palmitoyltransferase 1A (CPT1A) Deficiency

Leah Dowsett ^{1,2}, Lauren Lulis ¹, Can Ficicioglu ^{1,2} and Sanmati Cuddapah ^{1,2}

¹ Department of Pediatrics, Division of Human Genetics, The Children's Hospital of Philadelphia, Philadelphia, PA 19104, USA; leahkdowsett@gmail.com (L.D.); lulisl@email.chop.edu (L.L.); ficicioglu@email.chop.edu (C.F.)

² Perelman School of Medicine at the University of Pennsylvania, Philadelphia, PA 19104, USA

* Correspondence: cuddapahs@email.chop.edu; Tel.: +1-215-590-3376

Abstract: An 18 month-old male was evaluated after presenting with disproportionate transaminitis in the setting of acute gastroenteritis. He had marked hepatomegaly on physical exam that was later confirmed with an abdominal ultrasound. Given this clinical picture, suspicion for a fatty acid oxidation disorder was raised. Further investigation revealed that his initial newborn screen was positive for carnitine palmitoyltransferase 1A (CPT1A) deficiency - a rare autosomal recessive disorder of long-chain fatty acid oxidation. Confirmatory biochemical testing in the newborn period showed carnitine levels to be unexpectedly low with a normal acylcarnitine profile. Thus, it was considered to be a false-positive newborn screen and metabolic follow up was not recommended. Repeat biochemical testing during this hospitalization revealed a normal acylcarnitine profile. The only abnormalities noted were a low proportion of acylcarnitine species from plasma, an elevated free-to-total carnitine ratio, and mild hypoketotic medium chain decarboxylic aciduria on urine organic acids. Gene sequencing of *CPT1A* revealed a novel homozygous splice site variant that confirmed his diagnosis. CPT1A deficiency has a population founder effect in the Inuit and other Arctic groups, but has not been previously reported in persons of Ashkenazi Jewish ancestry.

Keywords: carnitine palmitoyltransferase deficiency; CPT1A; fatty acid oxidation disorders; transaminitis; Ashkenazi Jewish; neonatal screening

1. Introduction

Carnitine palmitoyltransferase 1A (CPT1A) deficiency is a rare autosomal recessive disorder of long-chain fatty acid oxidation. Patients are at risk for hypoglycemia and liver failure during times of fasting or illness. Lab abnormalities seen during such a crisis includes hypoglycemia, hyperammonemia, low acylcarnitines, elevated levels of total and /or free carnitine, transaminitis, and elevated coagulation studies. Diagnosis is established by corresponding biochemical profile and confirmed with molecular sequencing of the *CPT1A* gene. Residual enzyme activity is typically reduced to 1-5% in affected individuals, but testing for this via skin fibroblasts is unreliable. The mainstay of treatment is dextrose-containing IV fluids to replete hepatic glycogen stores to prevent metabolic crisis and hepatic encephalopathy [1].

Here, we describe a patient who had normal biochemical profiles in the newborn period who was subsequently diagnosed with CPT1A deficiency only after molecular testing revealed him to be homozygous for a splice-site variant in this gene. This condition, which has a population

founder effect in the Inuit and other arctic groups, has not been previously reported in persons of Ashkenazi Jewish ancestry [2, 3, 4].

2. Case Report

An 18 month-old male child presented with complaints of transaminitis in the setting of vomiting and diarrhea. He had initially presented to a local hospital where he was admitted for treatment of dehydration secondary to acute viral gastroenteritis. On the second day of hospitalization his transaminitis worsened and he was transferred to our facility for further evaluation and management. His initial labs revealed normal CK, ammonia, and coagulation studies. However, he did have elevated AST (517 U/L, normal 20-60 U/L) and ALT (388 U/L, normal 5-25 U/L). Alkaline phosphatase was also normal (191 U/L, normal 145-320 U/L). On further investigation, hepatic function testing revealed transaminitis that was nearly 10-fold elevated from normal values. Creatine phosphokinase (CK) was at the upper end of normal (304 U/L, normal 60-305 U/L). Ultrasound of the abdomen revealed an enlarged liver with increased heterogeneous echogenicity and a thickened gallbladder wall with slightly complicated appearing ascites.

Given this clinical picture, suspicion for a fatty acid oxidation disorder was raised, and the Metabolism team was consulted for evaluation. Further history obtained from the family revealed that the patient was the fourth child born to non-consanguineous parents of Ashkenazi Jewish ancestry. He was born at term and there were no complications reported during the pregnancy. There was also no history for teratogenic exposures during the pregnancy. Parents reported that everything in the newborn period was routine. This patient had no prior history of documented hypoglycemia. He had both motor and speech delays, and at the time of presentation at 18 months of age had just begun to walk and knew 1-2 words. His weight was 10.9 kg (24%), length was 83.0 cm (61%), and weight-for-length was at the 25th percentile. Physical examination at the time revealed mild dysmorphic features including a beaked nose and mild retrognathia. Abdominal exam was notable for hepatomegaly 4 cm below the right costal margin. The child also had truncal hypotonia.

Upon review of the patient's newborn screen, it was found that his screen had been positive for CPT1 deficiency at birth. A positive newborn screen results when there is a low C16 value with increased ratios of free carnitine to the sum of C16:0 plus C18 acylcarnitines [5]. The C16 was low at 0.21 $\mu\text{mol/L}$ (normal $>0.66 \mu\text{mol/L}$). His C0/C16 ratio was 377 (cutoff <68), and C0/18 ratio was 1119 (cutoff <170). Records indicated that his primary care physician sent an acylcarnitine profile and carnitine levels based on recommendations from a metabolic physician. Results of these studies showed carnitine levels to be unexpectedly low. Total carnitine was 16 mmol/L (normal 33-70 mmol/L) and free carnitine was 14 mmol/L (normal 28-52 mmol/L). The acylcarnitine profile was normal. Given these findings, the case was considered to be a false-positive result (see Figure 1) and no metabolic follow-up was recommended.

With the patient's prolonged transaminitis during the current hospitalization and history of an abnormal newborn screen, the diagnosis of CPT1A was again considered during his hospitalization at 18 months of age. Aside from a positive newborn screen, other expected supportive laboratory findings in patients with CPT1A deficiency include hypoketotic

hypoglycemia, transaminitis (2-10 times the upper limit of normal), hyperammonemia, elevated total serum carnitine, and elevated C6-12 species on urine organic acids [6]. Our patient did not have documented hypoglycemia during his hospital course. He had normal total serum carnitine but slightly elevated free carnitine levels (total carnitine 67.8 nmol/mL, normal 25-69 nmol/mL; free carnitine 62.6 nmol/mL, normal 17-59 nmol/mL; acylcarnitine 5.2 nmol/mL, normal 4-14 nmol/mL). His ammonia level was normal (<9 mmol/L). Though the values were reported as normal, closer review of his laboratory studies showed that the acylcarnitine species only comprised 8% of the sample, whereas normal patients without a disorder of fatty acid oxidation are expected to have >20% acylcarnitine species present in their plasma. His free-to-total carnitine ratio was elevated at 0.92 (normal 0.68-0.86), also suggestive of CPT1A deficiency. His acylcarnitine profile was again within normal limits. Aside from the transaminitis, the only additional biochemical evidence to suggest CPT1A deficiency was the presence of hypoketotic medium chain decarboxylic aciduria on urine organic acids.

Gene sequencing of *CPT1A* revealed the patient to be homozygous for a splice site variant that destroys the canonical splice donor site in intron 10 (c.1163+1 G>A) and was therefore reported as pathogenic. This variant has not been previously reported.

In outpatient follow-up one month later, the AST and ALT had normalized and his other biochemical labs remained unremarkable. He was started on a low-fat diet with medium chain triglyceride supplementation. Parents were explained the nature of the condition including avoidance of fasting and dietary recommendations. The recurrence risk for future pregnancies was discussed, and testing for family members (parents and siblings) was encouraged. The patient was seen again for routine follow-up in Metabolism Clinic 6 months later. He had not had any intercurrent illness or evidence of metabolic decompensation. The family reported that his energy level improved after starting medium chain triglyceride supplementation. Again, genetic counseling was provided, and testing of siblings was recommended given the possibility of one of the siblings having a mild form of disease that could have also been missed on newborn screening. Genetic testing confirmed that none of the other siblings were affected.

3. Figures

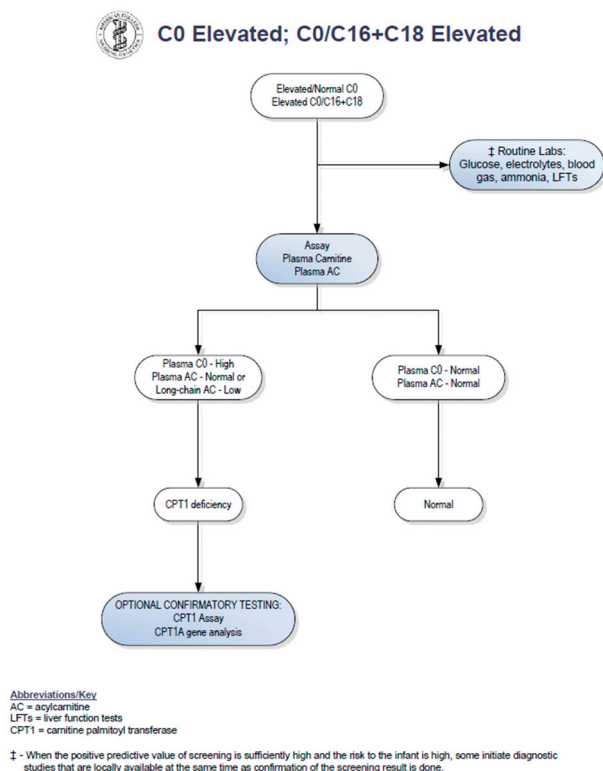


Figure 1. Confirmatory Algorithm for CPT1 Deficiency on Newborn Screening (www.ncbi.nlm.nih.gov/books/NKBK55827).

4. Discussion

Our patient had an abnormal newborn screen which was positive for CPT1 deficiency. At the time of initial follow up with a consulting metabolic physician when the patient was 2 weeks of age, the acylcarnitine profile and plasma carnitine levels did not suggest biochemical evidence of CPT1 deficiency. By following the NBS ACT sheet guidelines (see Figure 1), physicians are prompted to stop investigations if the confirmatory biochemical profile after the initial abnormal screen is within normal limits. There have been reports of disorders of long-chain fatty acid oxidation being missed by newborn screening [7,8]. Patients with fatty acid oxidation defects can have normal biochemical profiles in the absence of physiologic stressors. It is therefore possible to have an abnormal newborn screen but normal confirmatory metabolic testing. As a result of these missed cases, our group has adopted the practice of obtaining genetic sequencing for all abnormal newborn screens for disorders of fatty acid oxidation.

Presenting with acute liver failure during an episode of acute viral gastroenteritis is characteristic of CPT1A deficiency. The CPT1A protein lies within the outer mitochondrial matrix and is essential for the conversion of long-chain fatty acids to acylated species so that they can be transported into the inner mitochondrial matrix for fatty acid oxidation. Molecular analysis confirmed his diagnosis of CPT1A deficiency despite only mild suggestions of biochemical disease

in plasma and urine studies. While we cannot make direct correlations at present time, it is possible that our patient has suffered neurologic sequelae due to unrecognized episodes of hypoglycemia and metabolic crises, as evidenced by his growth failure and developmental delays.

5. Conclusions

This case report illustrates how a patient with molecularly confirmed CPT1A deficiency was missed based on the current newborn screening ACT sheet guidelines. Although the newborn screen flagged as abnormal for the appropriate disease, the absence of biochemical evidence on subsequent metabolic testing allowed this patient to remain undiagnosed until he was 18 months of age and had evidence of metabolic decompensation. While the current guidelines suggest confirmatory genetic testing as an optional test only when biochemical testing is abnormal, we recommend including sequencing of the *CPT1A* gene as a mandatory step after an abnormal newborn screen for carnitine palmitoyltransferase 1A deficiency.

Conflicts of Interest: The authors declare no conflicts of interest.

References

1. Sarafoglou, K., Hoffman, G., & Roth, K. (Eds.). (2009). *Pediatric Endocrinology and Inborn Errors of Metabolism* (First). McGraw-Hill Education.
2. Clemente, F. J., Cardona, A., Inchley, C. E., Peter, B. M., Jacobs, G., Pagani, L., ... Kivisild, T. (2014). A selective sweep on a deleterious mutation in CPT1A in Arctic populations. *American Journal of Human Genetics*, 95(5), 584–589. <https://doi.org/10.1016/j.ajhg.2014.09.016>
3. Korman, S. H., Waterham, H. R., Gutman, A., Jakobs, C., & Wanders, R. J. A. (2005). Novel metabolic and molecular findings in hepatic carnitine palmitoyltransferase I deficiency. *Molecular Genetics and Metabolism*, 86(3), 337–343. <https://doi.org/10.1016/j.yimgme.2005.07.022>
4. Tsuburaya, R., Sakamoto, O., Arai, N., Kobayashi, H., Hasegawa, Y., Yamaguchi, S., ... Tsuchiya, S. (2010). Molecular analysis of a presymptomatic case of carnitine palmitoyl transferase I (CPT I) deficiency detected by tandem mass spectrometry newborn screening in Japan. *Brain and Development*, 32(5), 409–411. <https://doi.org/10.1016/j.braindev.2009.03.004>
5. Bennett, M. J., & Santani, A. B. (2016). Carnitine Palmitoyltransferase 1A Deficiency. Retrieved August 2, 2017, from <https://www.ncbi.nlm.nih.gov/books/NBK1527/>
6. Stanley, C., Palmieri, F., & Bennett, M. (2014). *The Online Metabolic and Molecular Bases of Inherited Disease (OMMBID)*. (D. Valle, Ed.). New York, NY: McGraw-Hill Education. Retrieved from <http://ommbid.mhmedical.com/ommbid-index.aspx>.
7. Edmonson, A., Salant, J., Ierardi-Curto, L., Ficicioglu, C. (2016). Missed newborn screening case of Carnitine Palmitoyltransferase-II Deficiency. *JIMD Rep*, ePub ahead of print.
8. Ficicioglu, C., Coughlin, C., Bennett, M., Yudkoff, M. (2010). Very long-chain acyl-CoA dehydrogenase deficiency in a patient with normal newborn screening by tandem mass spectrometry. *J Pediatr*, 156 (3), 492-494.

