

Review

Not peer-reviewed version

Ocular Manifestations of Flavivirus Infections

Sourour MEZIOU ZINA , Gautier HOARAU , Marc LABETOULLE , Moncef KHAIRALLAH , [Antoine ROUSSEAU](#)

*

Posted Date: 1 November 2023

doi: 10.20944/preprints202310.2045.v1

Keywords: Flavivirus; Eye; West Nile Virus; Dengue fever Virus; Yellow Fever; Zika virus; Japanese Encephalitis Virus; Kyasanur Forest Disease Virus



Preprints.org is a free multidiscipline platform providing preprint service that is dedicated to making early versions of research outputs permanently available and citable. Preprints posted at Preprints.org appear in Web of Science, Crossref, Google Scholar, Scilit, Europe PMC.

Copyright: This is an open access article distributed under the Creative Commons Attribution License which permits unrestricted use, distribution, and reproduction in any medium, provided the original work is properly cited.

Review

Ocular Manifestations of Flavivirus Infections

Sourour Meziou Zina ^{1,2}, Gautier Hoarau ¹, Marc Labetoulle ^{1,3}, Moncef Khairallah ² and Antoine Rousseau ^{1,3,*}

¹ Department of Ophthalmology, Bicêtre Hospital, Public Assistance, Hospitals of Paris, Reference Network for Rare Diseases in Ophthalmology (OPHTARA), 94270 Le Kremlin-Bicêtre, France; marc.labetoulle@aphp.fr

² Department of Ophthalmology, Faculty of Medicine, University of Monastir, Monastir 5019, Tunisia; sourour.meziou@aphp.com; moncef.khairallah@rns.tn

³ Center for Immunology of Viral, Auto-Immune, Hematological and Bacterial Diseases (IMVA-HB), Infectious Diseases Models for Innovative Therapies (IDMIT), French Alternative Energies and Atomic Commission (CEA), 92260 Fontenay-aux-Roses, France; antoine.rousseau@aphp.fr

* Correspondence: antoine.rousseau@aphp.fr

Abstract: Flaviviruses are a group of positive sense single-stranded RNA viruses predominantly transmitted by arthropods (mainly mosquitoes), that cause severe endemic infections and epidemics on a global scale. It represents a major cause of systemic morbidity and death that are expanding worldwide. Among this group, Dengue fever, West Nile virus, Yellow Fever, Japanese Encephalitis, and recently Zika virus have been linked to a spectrum of ocular manifestations. The latter encompass subconjunctival hemorrhage and conjunctivitis, anterior and posterior uveitis (inclusive of vitritis, chorioretinitis, and retinal vasculitis), maculopathy, retinal hemorrhages, and optic neuritis. Clinical diagnosis of these infectious diseases is primarily based on epidemiological data, history, systemic symptoms and signs, and the pattern of ocular involvement. Diagnosis confirmation relies on laboratory testing, including RT-PCR and serological testing. Ocular involvement typically follows a self-limited course but can result in irreversible visual impairment. Effective treatment for flavivirus infections is currently unavailable. Prevention remains the mainstay for arthropod vector and zoonotic disease control. Effective vaccines are available only for Yellow Fever virus, Dengue virus and Japanese Encephalitis virus. This review comprehensively summarizes the current knowledge regarding the ophthalmic manifestations of the foremost flavivirus-associated human diseases.

Keywords: flavivirus; eye; west nile virus; dengue fever virus; yellow fever; zika virus; japanese encephalitis virus; kyasanur forest disease virus

1. Introduction

Flaviviruses constitute a group of 90 positive-sense, single-stranded RNA viruses, with 30 capable of causing severe disease in both humans and animals. This viral family is primarily transmitted by hematophagous arthropods, notably ticks and mosquitoes, resulting in widespread endemic infections and global epidemics [1,2]. Some members of the flavivirus family continue to pose a significant global threat, leading to systemic morbidity and an expanding worldwide mortality [3]. Flaviviral infections often manifest as either asymptomatic or non-specific febrile illnesses. However, severe and potentially fatal systemic complications, such as hemorrhagic fever and neurological involvement, can occur. In addition to systemic infections that entail hemorrhage, vascular leakage, encephalitis, microcephaly, and Guillain-Barre syndrome, certain specific flaviviruses, including Dengue fever (DFV), West Nile virus (WNV) infection, Yellow fever virus (YFV), Japanese Encephalitis virus (JEV), and Zika virus, have recently been linked to uveitis and other ocular manifestations[4–8]. There are no specific antiviral therapies for flavivirus infections and

treatment is essentially symptomatic [3–5,7]. This manuscript aims to provide an overview of the ophthalmic-manifestations associated with the most significant flavivirus-related human diseases.

2. General aspects

2.1. Virological features:

Flaviviruses are a family of enveloped viruses with a compact, positive-sense single-stranded RNA genome of approximately 10.5 kb (**Figure 1**). This genome encodes three structural and seven non-structural proteins. These ten essential proteins serve crucial functions in virion assembly, cell receptor binding and entry, viral polyprotein processing, and viral replication. After entering the host via an infected vector, the virus infects macrophages, monocytes, and dendritic cells [9–11]. Flaviviruses enter cells through receptor-mediated endocytosis, binding with host endosomes in an acidic environment, leading to conformational changes in their envelope (E) glycoprotein [2]. These changes facilitate fusion of the host and viral membranes, releasing the nucleocapsid and viral RNA genome into the host cell's cytoplasm. The polypeptide is then translated into the ten viral proteins, comprising three structural proteins (C, prM, and E protein) and seven non-structural proteins (NS1, NS2A, NS2B, NS3, NS4A, NS4B, and NS5) [1,2]. The non-structural proteins oversee viral genome replication, budding, and the hijacking of host cell machinery. Following translation, RNA-dependent RNA polymerase (RdRp), NS5, generates a negative-strand from genomic RNA, serving as a template for the production of a new positive strand. In the rough Endoplasmic Reticulum (ER), viral proteins commence assembly, packaging viral RNA with structural proteins—C, E, and prM. Viral particles are subsequently transported to the trans-Golgi network, where prM is cleaved into M. The mature virus is then released from the host into the extracellular space through exocytosis [2].

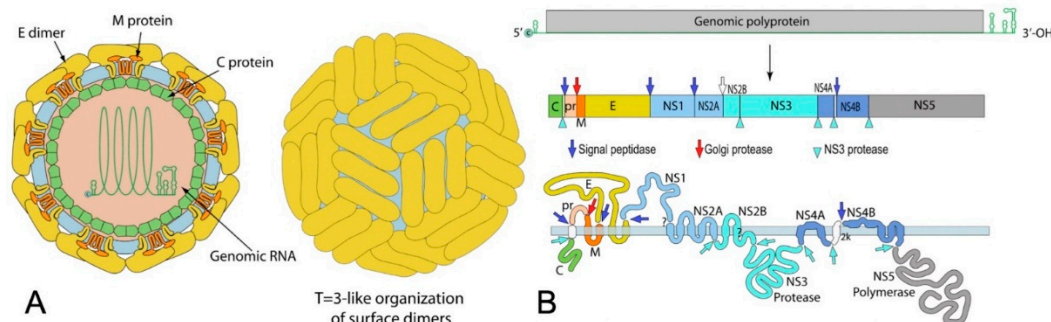


Figure 1. Schematic representation of a flavivirus viral particle (A) and genome (B). Adapted from <https://viralzone.expasy.org/24> with authorization [138].

2.2. Transmission:

Flaviviruses persist in an enzootic cycle, primarily involving mosquitoes as the main vectors and mammals and birds as the amplifying hosts, and are incidentally transmitted to humans [3]. While arthropod-borne transmission is predominant, alternative transmission routes have been documented. For instance, WNV can be transmitted among humans via blood transfusions, organ transplants, or from mother to newborn through transplacental transmission [12–14]. WNV can also be transmitted orally in hamsters, birds, and mice [15–17]. Some cases of human-to human DENV transmissions via blood transfusions have been reported [18,19]. JEV and Zika virus can be transmitted transplacentally from an infected mother to the fetus in the first and second trimester [20,21]. Seminal transmission of JEV in pigs, resulting in embryo abortion, has been documented [22]. Similarly, ZIKV has been shown to persist in bodily fluids, suggesting a route of horizontal transmission[23].

2.3. Diagnosis:

The diagnosis of flavivirus infections is typically carried out using conventional methods, including serology and molecular assays [24]. Reverse Transcription Polymerase Chain Reaction (RT-

PCR) is commonly employed during the early stage of the disease, typically within the first week of infection. Serological testing, specifically Enzyme-Linked Immunosorbent Assays (ELISA), is generally used during the acute phase to detect IgM antibodies and in the later stages to detect IgG antibodies. However, it is important to note that cross-reactivity is common among viruses in the *Flaviviridae* family, which can reduce the specificity of the diagnosis [24]. In this context, a specific technique of ELISA called "antibody capture ELISA," also known as "sandwich ELISA," has been developed to enhance the accuracy of the assay [25]. Moreover, the plaque reduction neutralization test (PRNT), often considered as a gold standard, is used to confirm equivocal results. PRNT is highly specific among serological assays, showing minimal cross-reactivity, and it is used to detect neutralizing antibodies [24]. Finally, cell culture procedures may be conducted at designated research facilities, aimed at isolating the viral strain. Handling of the isolated virus should take place in biosafety level 3 laboratories, especially in the case of JEV[24,26].

3. Ocular complications of Flaviviruses

3.1. Dengue Fever (DF)

3.1.1. Epidemiology

Dengue virus comprises four distinct serotypes (DF-1 to DF-4), each lacking cross-immunity, thus allowing for multiple dengue fever infections in a given individual [27]. Transmission occurs via the bite of an infected female *Aedes aegypti/albopictus* mosquito. *Aedes albopictus* vectors tend to trigger slower outbreaks compared to the rapid epidemics associated with *Aedes aegypti* [28]. DF ranks as a significant arthropod-borne disease in tropical and subtropical regions, endemic in over 100 countries spanning America, Southeast Asia, the Western Pacific, Africa, and the Eastern Mediterranean [29]. The incidence of DF has surged 30-fold in recent decades, affecting an estimated 390 million people annually [5]. This results in approximately 96 million symptomatic infections yearly, with two million cases of severe Dengue and an annual death toll of 21,000 [30–32]. Manifesting in endemic-epidemic cycles within densely populated tropical urban areas, the majority of infections occur in children across Asia and young adults within the American tropics, though the impact extends to other continents [33].

3.1.2. Systemic manifestations

Dengue fever occurs 3–14 days after a mosquito bite [27]. Infection can be asymptomatic, result in a non-specific febrile illness, or exhibit classic DF symptoms, including a sudden high fever, severe headache, myalgias, arthralgias, nausea, vomiting, hepatomegaly, lymphopenia, and a maculopapular rash. Most DF cases resolve spontaneously. However, a minority of patients may progress to a life-threatening condition known as dengue hemorrhagic fever (or dengue shock syndrome), characterized by thrombocytopenia, hypotension, and the potential for multi-system organ failure [5].

3.1.3. Ocular manifestations

The precise incidence of ocular manifestations during DF remains uncertain since most studies focus on cases seen by hospital specialists. Nevertheless, reported incidences have ranged from 7.1% to 40.3%, likely reflecting varying disease severities and the diverse ocular assessments used in each study [34,35]. Ocular involvement in DF, typically bilateral, can result from thrombocytopenia, inflammation, and ischemic mechanisms [5,36]. These ocular manifestations can occur from days to months after the onset of fever.

-Dengue fever associated maculopathy:

DF-associated maculopathy, the most common ocular manifestation of acute DFV infection, is reported in 10% of hospitalized patients and is serotype-dependent [37,38]. Notably, one study linked maculopathy to serotype specificity, with a 10% incidence during DENV-1 epidemic but none during DENV-2 outbreak [38]. Symptoms typically emerge 3-11 days after fever onset and recover over 2-4

weeks. Patients may present with sudden vision loss, central scotoma, or floaters. The lesions are typically asymmetric and often bilateral, primarily associated with intraretinal hemorrhages, manifesting as dot, blot, or flame-shaped hemorrhages. However, some patients remain asymptomatic, with lesions visible only through fluorescein or indocyanine green angiography (ICGA) [4,7,39,40]. Fluorescein angiography (FA) commonly reveals retinal vascular leakage (**Figure 2**) and occlusion, while ICGA identifies hypofluorescent spots corresponding to subretinal lesions and additional spots in areas without clinically evident dots[36]. OCT is valuable in detecting and monitoring dengue-induced inflammatory ischemic foveolitis and outer maculopathy, showing disruptions in outer retinal layers, conical foveal elevation, and focal thickening of the outer neurosensory retina-RPE, aligning with round foveal yellowish lesions seen clinically (**Figure 3**). OCT is also instrumental in detecting and assessing associated serous retinal detachment (SRD) and macular edema. Teoh et al. used OCT to categorize patients into three groups: (1) diffuse retinal thickening, (2) cystoid macular edema, and (3) foveolitis, correlating these findings with visual acuity and prognosis [39]. DF-related foveolitis pertains to the yellow-orange central foveal lesion in patients with dengue maculopathy, visible on OCT as conical foveal elevation and focal outer neurosensory retina-RPE thickening, often associated with prolonged scotomata persistence [39,41]. More recently, OCT-angiography (OCTA) has revealed ischemia in the deep retinal capillary plexus [39,42].

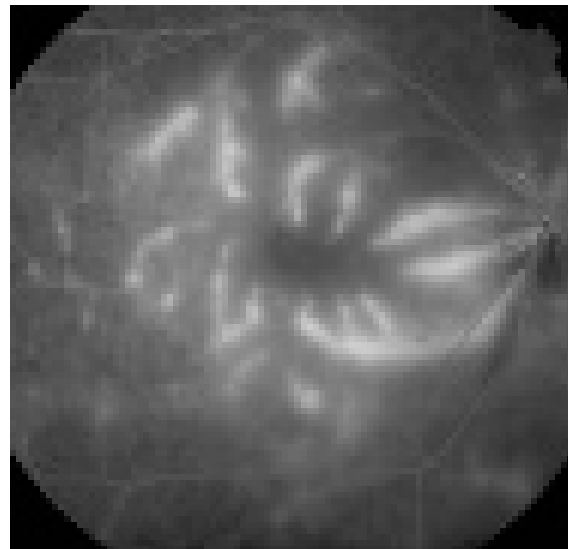


Figure 2. Fluorescein angiogram of the right eye of a 33-year-old woman presenting with sudden loss of vision 1 week after the onset of dengue hemorrhagic fever showing dengue maculopathy manifesting as severe retinal vasculitis with prominent vascular leakage (Courtesy, Pr Soon Phaik Chee).

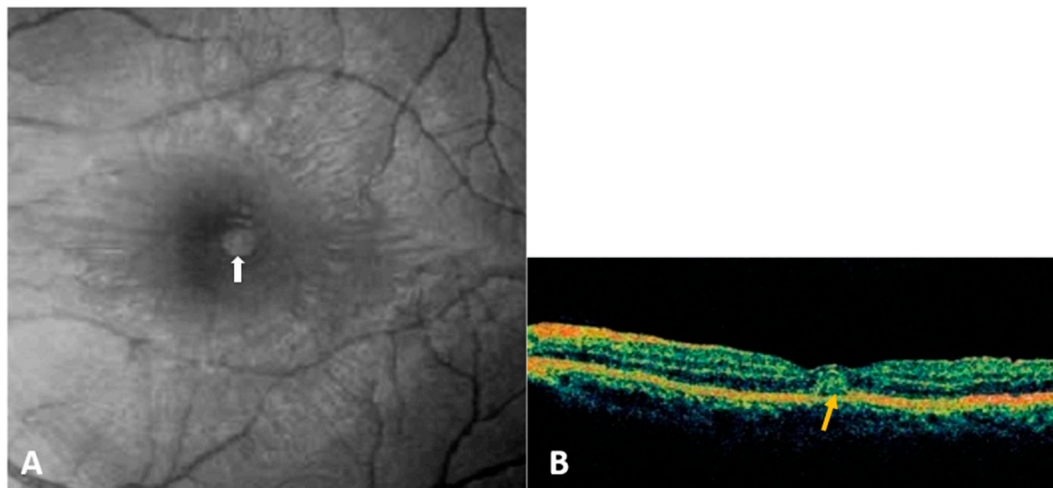


Figure 3. A. Red-free fundus photograph of the left eye of a patient with Dengue fever shows a subretinal round, yellowish lesion at the fovea (white arrow). B. Optical coherence tomography through the lesion demonstrates conical foveal elevation (yellow arrow) with focal outer neurosensory retina-retinal pigment epithelium thickening (Courtesy, Pr Soon Phaik Chee).

-Other posterior segment manifestations

Other posterior ocular features associated with DF include posterior uveitis, and less commonly vascular occlusions, panuveitis, vitritis, retinal and vitreous hemorrhage, choroidal changes and yellow sub-retinal spots [6,36,41,43,44].

-Anterior segment manifestations

In addition to the common subconjunctival hemorrhage observed in nearly half of the patients, reported anterior segment manifestations include anterior uveitis, and less frequently, shallow anterior chambers, acute angle-closure glaucoma due to ciliochoroidal effusion, superficial corneal punctate erosions, keratitis, and scleritis [7,35,41,45,46].

-Other ocular manifestations

There are rare reports of neuro-ophthalmic complications including optic disc swelling, optic neuritis, neuroretinitis, neuromyelitis optica and abducens palsy [41]. A few cases of DF-associated panophthalmitis were reported [47,48].

3.1.4. Diagnosis

DF diagnosis relies on the characteristic clinical presentation and is confirmed through laboratory tests, including dengue virus nonstructural protein 1 detection and IgM/IgG antibody analysis [6,45]. Real-time RT-PCR or NS1 antigen detection is used for confirmation within the first 5 days, while ELISA-based detection of anti-dengue IgM or seroconversion in paired acute and convalescent serum samples is the more common method for confirmation after 5 days [27].

3.1.5. Treatment and prognosis

Treatment is essentially symptomatic [49]. A live-attenuated tetravalent vaccine is currently available, reserved for populations in which the seroprevalence is over 70% in the age bracket for vaccination, due to the weak efficacy of the vaccine and the potential long-term risks of severe DF in vaccinated seronegative subjects. Vaccination is not recommended for children under 9 years of age [50]. In most cases, ocular manifestations resolve spontaneously with a favorable visual prognosis. However, severe cases have been treated with customized immunomodulatory therapies, including topical, periocular, oral, intravenous steroids, and immune globulins, with varying degrees of success depending on clinical presentation [40,51]. The visual prognosis is good in most patients. However,

permanent visual impairment may occur mainly due to retinal vasculitis, dengue maculopathy, or optic neuropathy [6].

3.2. *West Nile virus infection (WNV):*

3.2.1. Epidemiology

West Nile virus (WNV), a zoonotic disease within the Japanese encephalitis serocomplex of viruses [52], has five distinct phylogenetic lineages. Among these, lineage one, globally distributed, and lineage two, primarily found in Africa, are known to cause human disease [52,53]. WNV primarily resides in birds, with transmission to humans occurring via *Culex* mosquitoes. Bird-mosquito-human transmission accounts for the majority of human cases [52]. The virus was first isolated in Uganda in 1937 and has since spread to Europe, Australia, Asia, and, since 1999, the United States, Canada, Mexico, the Caribbean, and parts of Central and South America [54]. Recently, co-circulation with Usutu virus, another neurotropic mosquito-borne Flavivirus, has been observed in Europe, raising the potential for WNV to expand to regions previously only affected by Usutu virus and vice versa [55].

3.2.2. Systemic manifestations:

The incubation period for WNV infection ranges from 3 to 14 days and is most often followed in humans by an asymptomatic infection. Only approximately 25% of infected persons develop a self-limiting, non-specific viral illness including fever, headache, fatigue, nausea and vomiting, lymphadenopathy and skin rash, that typically lasts less than a week [52]. Severe neurologic manifestations may develop in less than 1% of cases including encephalitis, meningoencephalitis, acute flaccid paralysis, movement disorders, poliomyelitis-like syndrome, and Guillain-Barré Syndrome [53]. Asymmetric paralysis of acute onset and absence of reflexes without pain are characteristic of WNV [56]. Neuroinvasive disease is associated with high rates of morbidity and mortality, especially in patients with advanced age or diabetes [56].

3.2.3. Ocular manifestations:

Multifocal chorioretinitis, typically bilateral, is the most common ocular manifestation of acute WNV infection, occurring in nearly 80% of patients with neurologic symptoms [57,58]. WNV-associated chorioretinitis often presents with minimal symptoms, such as floaters, mild vision reduction, redness, ocular pain, visual field defects, or diplopia [4,7,57,59,60].

Active chorioretinal lesions are circular, deep, yellowish on ophthalmoscopy, with early hypofluorescence and late staining on FA [57]. Inactive lesions appear round and atrophic, sometimes with central pigmentation, typically showing a "target-like appearance" on FA, featuring central hypofluorescence and peripheral hyperfluorescence (**Figure 4**) [57]. These lesions vary in number and size (ranging from 100 to 1500 μm in diameter), involving the midperiphery, possibly with posterior pole involvement [7,57]. They typically align radially in the nasal and peripheral fundus or follow a curvilinear pattern in the temporal posterior fundus, associated with the course of retinal nerve fibers [57,61].

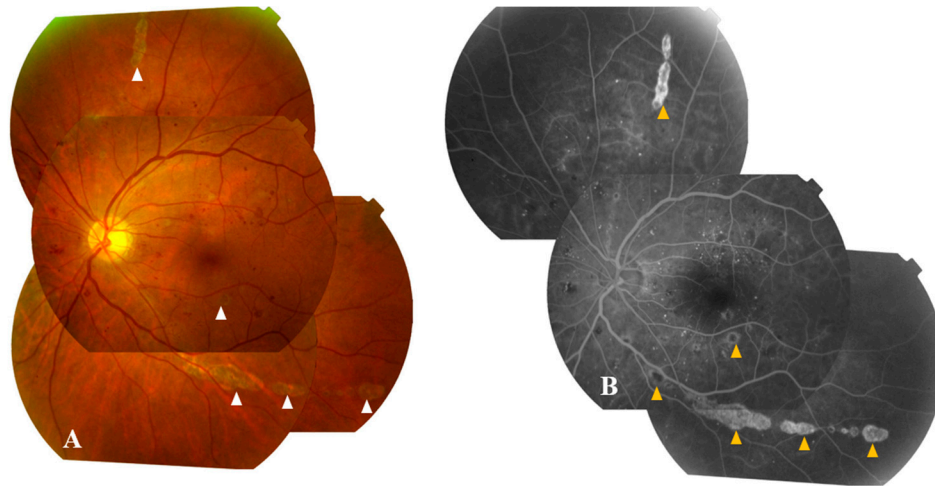


Figure 4. Color fundus photograph (A) and fluorescein angiogram (B) of the left eye of a diabetic patient with WNV infection show inactive multifocal chorioretinitis with typical linear clustering and 'target-like appearance' of chorioretinal lesions (white arrowheads) with central hypofluorescence and peripheral hyperfluorescence (yellow arrowheads). Note the presence of associated moderate to severe non-proliferative diabetic retinopathy.

OCT through lesions reveals their deep retinal location with focal disruption of the outer nuclear layer and retinal pigment epithelium (RPE) [62]. ICGA highlights well-defined hypofluorescent choroidal spots, often more numerous than clinically appreciated or seen on FA [63]. Chorioretinitis is more common in individuals over 50 and those with diabetes mellitus, with a significant proportion also displaying concurrent diabetic retinopathy.

Other manifestations have been described, including nongranulomatous anterior uveitis, retinal hemorrhages, focal or diffuse retinal vascular sheathing, vascular leakage, occlusive vasculitis, congenital chorioretinal scarring, zones of atrophy and mottling of RPE, macular edema, optic neuritis, papilledema, and binocular diplopia related to 6th cranial nerve involvement[6,7,43,57,58,60,64,65].

Noteworthy, OCTA allows detection and precise delineation of areas of retinal capillary nonperfusion in both the superficial and deep capillary plexuses in case of associated occlusive retinal vasculitis [66].

3.2.4. Diagnosis:

WNV infection is diagnosed primarily based on clinical features and confirmed through the detection of IgM antibodies in serum or cerebrospinal fluid [67]. However, serological tests may show cross-reactivity with other Flaviviruses or yield false-negative results [24]. Therefore, virus detection using RT-PCR is increasingly becoming the gold standard for WNV diagnosis [67].

3.2.5. Treatment and prognosis

Neurological manifestations are addressed through intensive supportive care. Ongoing clinical trials are exploring novel therapeutic strategies, including interferon alpha-2b, interferon beta, and high-titer intravenous immunoglobulin[68–70]. The primary approach to WNV infection control remains prevention, achieved by reducing mosquito populations (such as draining standing water and using larvicides) and implementing personal protection measures (such as repellents, window screens, and protective clothing) [52]. Specific ophthalmic treatments may be necessary to address intraocular inflammation or posterior segment complications. These treatments include topical steroids for anterior uveitis, peripheral retinal photocoagulation for neovascularization resulting from occlusive vasculitis, pars plana vitrectomy for non-clearing vitreous hemorrhage or tractional retinal detachment, and intravitreal injection of anti-vascular endothelial growth factor agents for

choroidal neovascularization or associated macular edema in cases of chorioretinitis [71–73]. The benefit of systemic steroids is not evidence-based, but the positive role in recovery could justify their use in cases of severe posterior segment involvement. Ocular disease associated with WNV infection usually has a self-limited course, and visual acuity returns to baseline in most patients [57]. However, persistent visual impairment can occur due to various factors, including chorioretinal scarring, choroidal neovascularization, vitreous hemorrhage, tractional retinal detachment, severe ischemic maculopathy, optic atrophy, and retrogeniculate damage [6,43,57,58,64,74,75].

3.3. Yellow fever virus:

3.3.1. Epidemiology

Yellow fever virus (YFV) is primarily transmitted to humans through bites from infected *Aedes aegypti* and *Aedes albopictus* mosquitoes. It is maintained through sylvatic (jungle) transmission cycles involving mosquitoes and non-human primates, as well as mosquito-human transmission cycles in urban areas [76,77]. YFV is a reemerging arboviral disease that can be potentially lethal, causing an estimated 30,000-60,000 fatalities annually in endemic regions across Africa, South, and Central America [78].

3.3.2. Systemic manifestations:

Yellow fever is characterized by rapid jaundice development and liver dysfunction, which are distinctive clinical features of the disease. Most YFV-infected individuals are either asymptomatic or experience an acute febrile phase lasting around 4 days, accompanied by symptoms like myalgia, headache, back pain, nausea, and vomiting. This phase typically resolves within days. However, approximately 15-25% of patients progress to a severe toxic form of the disease, which includes symptoms such as viremia, fever, jaundice, prostration, hematemesis, hemorrhagic diathesis, and failure of the liver, kidneys, and myocardium. This severe form is associated with a 50% mortality rate.[76]

3.3.3. Ocular manifestations:

In the initial phase of yellow fever, conjunctivitis is the most common ocular finding. However, scleral icterus often occurs during the toxic phase [4,7].-Some case reports have suggested additional ocular manifestations. In yellow fever patients, retinopathy, encompassing retinal nerve fiber layer defects, superficial hemorrhages, and grayish deep lesions, may occur in 20% of cases [79]. Silvana Vianello *et al.* documented two intensive care patients in Brazil who exhibited increased choroidal thickness bilaterally, retinal vein congestion in one patient, and a 360° mid-peripheral choroidal detachment with yellowish subretinal lesions in the other patient [80]. Another publication reported the case of a 53-year-old Brazilian patient with YFV infection with unilateral retinal edema, macular exudates, and hemorrhages during the convalescent stage, possibly due to an immune-mediated mechanism rather than direct viral invasion or infection of the ocular tissues [80]

3.3.4. Diagnosis:

Diagnosis of YFV is based on PCR of blood or urine samples in the early stages, and ELISA or PRNT antibodies detection in later stages [76,80].

3.3.5. Treatment and prognosis

The development of two live-attenuated YF vaccines in the 1930s, and their wide deployment in the 1940s, led to a significant decline of the disease. However some ocular complications related to YFV vaccination have been reported, particularly when the live YFV vaccine is administered alongside other vaccines such as Hepatitis A/B, *Neisseria Meningitidis*, or Typhoid [7]. These complications vary and encompass anterior and intermediate uveitis, unilateral optic neuropathy, multifocal choroiditis, evanescent white dot syndrome, arteriolar occlusion, and conditions

resembling Vogt–Koyanagi–Harada disease [4,81,82]. There is currently no proven specific antiviral drug available with a strong emphasis on prevention through public health measures and vaccination [83,84]. In cases of severe systemic disease, intensive supportive therapy is indicated. Ocular complications associated with YFV and its vaccine are most often self-limiting with a favorable course with supportive care.

3.4. Zika Virus

3.4.1. Epidemiology

Zika virus is primarily transmitted by *Aedes* mosquitoes [85], but it can also be transmitted vertically during pregnancy [21], through sexual contact [86], and via contaminated blood transfusions [87]. The first human case was reported in Uganda, Africa, in 1952 [88], and subsequent epidemics have occurred globally since 2007, including in Micronesia, French Polynesia, and South America [85]. In 2016, a significant outbreak occurred in Brazil, affecting 1.6 million people, with 1950 cases of infection-related microcephaly in newborns [89]. The infection can pose a substantial burden, especially in infants with congenital Zika syndrome (CZS) and adult patients with Guillain-Barre syndrome.

3.4.2. Systemic manifestations

In adults, Zika infection is asymptomatic in 80% of cases [90]. After an incubation of 3-12 days, infected patients experienced nonspecific flu-symptoms [85]. Neurological complications may occur, including encephalitis, myelitis and Guillain Barre syndrome [91]. Generally, the median time between the onset of the infectious disease and neurologic features vary between 5 and 12 days [92]. Intrauterine infection and maternal-fetal transmission can occur during pregnancy in patients which experienced Zika infection. In newborns, CZS is defined by a pattern of anomalies including microcephaly, brain abnormalities, osteoskeletal abnormalities (mainly arthrogryposis and club foot), neurosensorial defects, and ocular manifestations (see below) [93].

3.4.3. Ocular manifestations:

In the acute phase, reported ophthalmological signs include non-purulent conjunctivitis and retroorbital pain [8,94]. Mild non-granulomatous anterior uveitis may be present in approximately half of patients presenting with red eyes [94][33237306]. Less frequent manifestations have been described. An acute maculopathy has been reported in a 64-year-old man. OCT showed a disruption of the outer retinal layer in the central macula [95]. Otherwise, a bilateral posterior uveitis with chorioretinal lesions was described in a 26-year-old man [96]. OCT showed hyperreflective nodules in the outer retina, and indocyanine green angiography confirmed active choroidal lesions.

Ocular findings have been observed in 21.4%-55% of CZS newborns [97]. Risk factors for ocular involvement in CZS include a smaller cephalic diameter at birth and infective symptoms during the first trimester of pregnancy [98]. However, ocular findings may occur in infants without microcephaly, suggesting that the absence of this feature does not preclude CZS screening. Posterior segment lesions are the most common ocular signs, including chorioretinal atrophy (**Figure 5**) and pigment mottling in the macular area [99,100]. Optical coherence tomography (OCT) of these lesions shows ellipsoid zone disruption, retinal and choroidal thinning [101]. Retinal hemorrhages can also be observed on ocular fundus and are considered a screening criterion for CZS [102]. Anterior segment lesions include iris coloboma, corneal ectasia, lens subluxation, cataract, and congenital glaucoma [103–105]. Neuroophthalmological lesions encompass strabismus, disc hypoplasia, increased cup-to-disc ratio, disc pallor, and horizontal nystagmus [99]. Histopathological studies on deceased fetuses have revealed pupillary membranes, immature anterior chamber angles, loss of pigment, retinal pigment epithelium thinning, choroidal thinning, and undifferentiated nuclear layers of the retina [106].

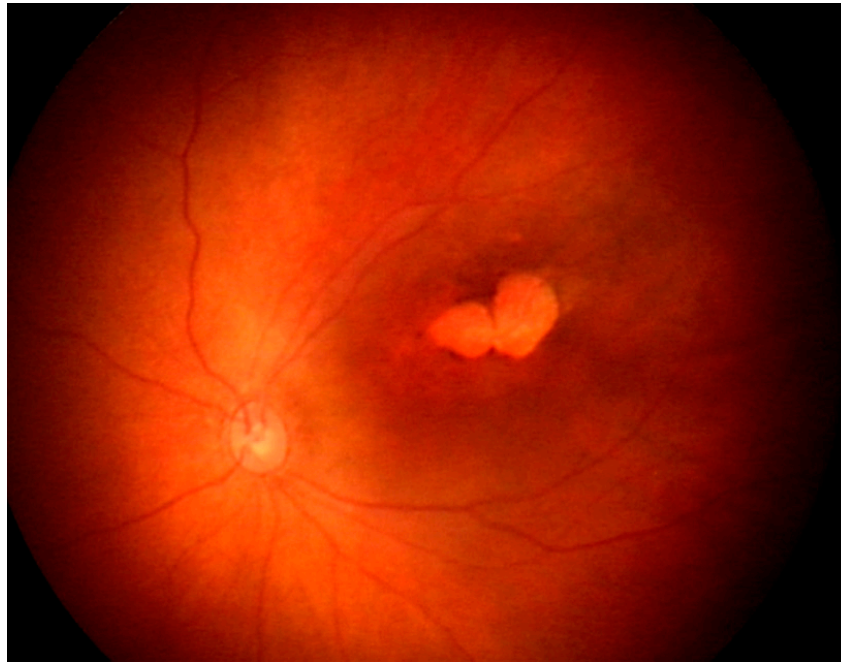


Figure 5. Fundus photograph of the left eye of a newborn with congenital Zika virus syndrome shows macular well-delineated atrophic lesions (Courtesy, Pr Rubens Belfort).

3.4.4. Diagnosis

Biological diagnosis can be conducted using various samples, including urine, amniotic fluid, serum, cerebrospinal fluid, semen, and tears, employing molecular biology techniques such as RT-PCR and serology methods like ELISA [85,107]. Molecular diagnosis is typically carried out during the acute phase of the disease, approximately 3-5 days after incubation[108]. RNA detection in urine samples can remain positive for up to three weeks [108]. IgM antibodies can be detected in serum and cerebrospinal fluid samples within the first week of illness [109]. If IgM results are equivocal, confirmation can be obtained using PRNT [107,109].

3.4.5. Treatment and prognosis

Well-tolerated vaccine candidates have progressed through phase 1 or phase 2 development [110]. Supportive care is recommended for adult patients experiencing inflammatory ocular manifestations. Corticosteroid eye drops can be employed to manage anterior uveitis [94].

The burden of Zika virus infection can be substantial, particularly in cases of Congenital Zika Syndrome (CZS). Ophthalmologists play a crucial role in early CZS assessment in newborns and the treatment of visual impairment and related ocular issues. Recommendations from the French High Council for Public Health [111] and the CDC [112] advise comprehensive ophthalmic screenings for all infants born from mothers infected during pregnancy, with the first examination before one month of age and a follow-up at one year. Public health campaigns should reinforce preventive measures, including the use of repellents to prevent mosquito bites and advising pregnant women in their first two trimesters to avoid traveling to disease-endemic areas [107].

3.5. Japanese Encephalitis Virus

3.5.1. Epidemiology

Japanese encephalitis (JE), caused by JEV, is predominantly found in Asia and the Western Pacific, including Australia where outbreaks have been reported recently [113]. Annually, an estimated 50,000 cases of JE are reported globally, resulting in approximately 15,000 deaths [114]. JE primarily occurs in rural areas and is transmitted through an enzootic cycle involving *Culex*

mosquitoes and vertebrate hosts, including water birds and swine [115]. Vertical transmission has also been documented [20].

3.5.2. Systemic manifestations

After an incubation period of 5 to 15 days [116], infected individuals develop flu-like symptoms with fever. Neurological complications, such as encephalitis, occur in only 1 out of 200-300 infected individuals [117]. During the encephalitic phase, various neurological symptoms may arise depending on the anatomical lesions. JEV infection can lead to a parkinsonian syndrome or polio-like acute flaccid paralysis [118]. The case fatality rate is estimated to be as high as 30% among patients with neurological complications [119]. Survivors may experience a high burden of the disease, with 30-50% developing long-term sequelae [119].

3.5.3. Ocular manifestations

Reports of ocular complications related to JEV are rare and likely underdiagnosed. One case occurred in a 53-year-old woman in 2006, who developed ischemic maculopathy during the infection [120]. Fundus examination revealed a "white" macula and retinal hemorrhages, while FA showed non-perfusion areas of the macula. Another case was reported in 2020, involving a 45-year-old man who had visited Bali [121]. He experienced febrile confusion with dysphasia and bilateral conjunctival injection. Ophthalmological examination revealed moderate non-granulomatous anterior uveitis, and the ocular fundus showed bilateral vessel tortuosity and pale chorioretinal lesions, suggestive of chorioretinitis [121].

3.5.4. Diagnosis

Available diagnostic tests include serology (antibody capture ELISA) and RT-PCR, performed on serum and cerebrospinal fluid samples [26]. The gold standard for diagnosing JEV is IgM testing by ELISA in cerebrospinal fluid, with specific IgM detectable during the first week of illness [122]. Cross-reactions are common among Flaviviruses, which is concerning in regions where both Dengue Virus and JEV are present. The sensitivity of both serological and molecular diagnosis is low, at less than 25% in the acute phase [123,124]. Combining the two techniques can increase sensitivity to 31% [125].

3.5.5. Treatment and prognosis

JEV infection can lead to severe systemic disease, including neurological manifestations managed with supportive care. While specific antiviral therapies are lacking, vaccination with a live-attenuated strain has reduced the burden of JEV disease [126]. It is advisable, according to the CDC's advisory committee on immunization practices to recommend JEV vaccination for long-term travel to endemic regions, or for persons moving to an endemic country to live [116]. JEV vaccine is also considered in residents of rural areas in endemic locations. Indeed, implementations of vaccinations programs reduced the incidence of JEV diseases in these countries [127]. The scarcity of reports on ocular manifestations hinders definitive conclusions about visual prognosis in JEV-related ocular issues. Nevertheless, cases of severe ischemic macular involvement indicate a potentially high burden of ocular complications [120].

3.6. Kyasanur Forest Disease Virus

3.6.1. Epidemiology

Kyasanur Forest Disease Virus (KFDV) is a biosafety level 4 organism belonging to the tick-borne encephalitis serocomplex, causing a rare hemorrhagic fever disease currently limited to India [128]. First reported in 1957 in Kyasanur Forest, Karnataka, India [129], there have been about 500 annual cases in recent decades [130]. KFDV is transmitted to humans and animals through the bite of infected hard ticks (*Hemaphysalis turturis/spinigera*) or contact with an infected animal [131].

Variants of KFDV have been identified in patients with hemorrhagic fever in Saudi Arabia, referred to as Alkhurma hemorrhagic fever disease, sharing 97% homology with KFDV and suggesting a common ancestral origin [128].

3.6.2. Systemic manifestations

KFD typically follows a biphasic course. After an incubation period of 2-7 days, patients experience an acute febrile phase characterized by flu-like symptoms and hemorrhagic manifestations, lasting up to two weeks [128]. In the convalescent phase, 10-20% of patients may experience severe hemorrhagic fever symptoms, including gastrointestinal bleeding and pneumonia, along with neurological complications resembling meningoencephalitis [128]. The estimated case fatality rate ranges from 3 to 10% [132].

3.6.3. Ocular manifestations

Ocular manifestations are common in KFD, with historical studies reporting conjunctival congestion as the most frequent ocular sign (92%)[133]. Other ophthalmic features include hemorrhages in various ocular sites (conjunctiva, vitreous humor, retina), iritis, lens opacification, keratitis, and papilledema that may occur in encephalitic patients [133].

3.6.4. Diagnosis

Biological diagnosis can be performed on serum samples in the early stage (two first weeks) using RT-PCR [134]. Serology (antibody capture ELISA) can be used in the acute (IgM) and convalescent phase (IgG) [134].

3.6.5. Treatment and prognosis

A vaccination strategy was developed in the 1990s using a formalin-inactivated tissue culture vaccine [135]. Public health campaigns in affected areas promote the use of repellents to prevent tick bites [128]. Limited data are available on the visual outcomes of this rare disease, which mainly occurs in low-resource rural areas [128].

4. Conclusions

Flavivirus infections are on the rise due to various human activities, including climate change and deforestation, which promote vector-borne zoonotic diseases[136,137]. This emergence represents a potential public health issue, affecting not only conditions that can be life-threatening but also those that can jeopardize vision. This was illustrated by recent Zika virus outbreaks that have resulted in substantial ocular morbidity [89]. In accordance with the information provided in this review, most cases of human flavivirus infections are linked to eye-related symptoms, which might be inaugural. Nevertheless, these symptoms can vary widely. On one hand, certain clinical features can be distinctive and indicative of the infection, such as the linear pattern of chorioretinitis seen in WNV cases. On the other hand, some viruses can cause non-specific symptoms, making the diagnosis challenging. The screening for flavivirus infections should be tailored to the specific clinical context, taking into consideration epidemiological factors like current outbreaks and recent travel history. Additionally, a thorough ophthalmologic evaluation seems crucial if visual symptoms develop during the course of a flavivirus infection.

Author Contributions: Writing—original draft preparation, Sourour Meziou Zina and Gautier Hoarau.; Review and editing, Antoine Rousseau and Moncef Khairallah.; Supervision, Marc Labetoulle. All authors have read and agreed to the published version of the manuscript

Funding: This research received no external funding

Institutional Review Board Statement: Not applicable

Conflicts of Interest: The authors declare no conflict of interest

References

- Ludwig, G.V.; Iacono-Connors, L.C. Insect-Transmitted Vertebrate Viruses: Flaviviridae. *In Vitro Cell Dev Biol Anim* **1993**, *29A*, 296–309, doi:10.1007/BF02633958.
- Fernandez-Garcia, M.-D.; Mazzon, M.; Jacobs, M.; Amara, A. Pathogenesis of Flavivirus Infections: Using and Abusing the Host Cell. *Cell Host Microbe* **2009**, *5*, 318–328, doi:10.1016/j.chom.2009.04.001.
- Pandit, P.S.; Doyle, M.M.; Smart, K.M.; Young, C.C.W.; Drape, G.W.; Johnson, C.K. Predicting Wildlife Reservoirs and Global Vulnerability to Zoonotic Flaviviruses. *Nat Commun* **2018**, *9*, 5425, doi:10.1038/s41467-018-07896-2.
- Merle, H.; Donnio, A.; Jean-Charles, A.; Guyomarch, J.; Hage, R.; Najioullah, F.; Césaire, R.; Cabié, A. Ocular Manifestations of Emerging Arboviruses: Dengue Fever, Chikungunya, Zika Virus, West Nile Virus, and Yellow Fever. *J Fr Ophtalmol* **2018**, *41*, e235–e243, doi:10.1016/j.jfo.2018.05.002.
- Lucena-Neto, F.D.; Falcão, L.F.M.; Moraes, E.C. da S.; David, J.P.F.; Vieira-Junior, A. de S.; Silva, C.C.; de Sousa, J.R.; Duarte, M.I.S.; Vasconcelos, P.F. da C.; Quaresma, J.A.S. Dengue Fever Ophthalmic Manifestations: A Review and Update. *Rev Med Virol* **2023**, *33*, e2422, doi:10.1002/rmv.2422.
- Khairallah, M.; Mahendradas, P.; Curi, A.; Khohtali, S.; Cunningham, E.T. Emerging Viral Infections Causing Anterior Uveitis. *Ocul Immunol Inflamm* **2019**, *27*, 219–228, doi:10.1080/09273948.2018.1562080.
- Venkatesh, A.; Patel, R.; Goyal, S.; Rajaratnam, T.; Sharma, A.; Hossain, P. Ocular Manifestations of Emerging Viral Diseases. *Eye (Lond)* **2021**, *35*, 1117–1139, doi:10.1038/s41433-020-01376-y.
- Benzekri, R.; Belfort, R.; Ventura, C.V.; de Paula Freitas, B.; Maia, M.; Leite, M.; Labetoulle, M.; Rousseau, A. [Ocular manifestations of Zika virus: What we do and do not know]. *J Fr Ophtalmol* **2017**, *40*, 138–145, doi:10.1016/j.jfo.2017.01.002.
- Marianneau, P.; Steffan, A.M.; Royer, C.; Drouet, M.T.; Jaeck, D.; Kirn, A.; Deubel, V. Infection of Primary Cultures of Human Kupffer Cells by Dengue Virus: No Viral Progeny Synthesis, but Cytokine Production Is Evident. *J Virol* **1999**, *73*, 5201–5206, doi:10.1128/JVI.73.6.5201-5206.1999.
- Tassaneetrithep, B.; Burgess, T.H.; Granelli-Piperno, A.; Trumpfheller, C.; Finke, J.; Sun, W.; Eller, M.A.; Pattanapanyasat, K.; Sarasombath, S.; Birk, D.L.; et al. DC-SIGN (CD209) Mediates Dengue Virus Infection of Human Dendritic Cells. *J Exp Med* **2003**, *197*, 823–829, doi:10.1084/jem.20021840.
- Krishnan, M.N.; Sukumaran, B.; Pal, U.; Agaisse, H.; Murray, J.L.; Hodge, T.W.; Fikrig, E. Rab 5 Is Required for the Cellular Entry of Dengue and West Nile Viruses. *J Virol* **2007**, *81*, 4881–4885, doi:10.1128/JVI.02210-06.
- Alpert, S.G.; Ferguson, J.; Noël, L.P. Intrauterine West Nile Virus: Ocular and Systemic Findings. *Am J Ophthalmol* **2003**, *136*, 733–735, doi:10.1016/s0002-9394(03)00452-5.
- Iwamoto, M.; Jernigan, D.B.; Guasch, A.; Trepka, M.J.; Blackmore, C.G.; Hellinger, W.C.; Pham, S.M.; Zaki, S.; Lanciotti, R.S.; Lance-Parker, S.E.; et al. Transmission of West Nile Virus from an Organ Donor to Four Transplant Recipients. *N Engl J Med* **2003**, *348*, 2196–2203, doi:10.1056/NEJMoa022987.
- Centers for Disease Control and Prevention (CDC) Intrauterine West Nile Virus Infection--New York, 2002. *MMWR Morb Mortal Wkly Rep* **2002**, *51*, 1135–1136.
- Sbrana, E.; Tonry, J.H.; Xiao, S.-Y.; da Rosa, A.P.A.T.; Higgs, S.; Tesh, R.B. Oral Transmission of West Nile Virus in a Hamster Model. *Am J Trop Med Hyg* **2005**, *72*, 325–329.
- Komar, N.; Langevin, S.; Hinten, S.; Nemeth, N.; Edwards, E.; Hettler, D.; Davis, B.; Bowen, R.; Bunning, M. Experimental Infection of North American Birds with the New York 1999 Strain of West Nile Virus. *Emerg Infect Dis* **2003**, *9*, 311–322, doi:10.3201/eid0903.020628.
- Odelola, H.A.; Oduye, O.O. West Nile Virus Infection of Adult Mice by Oral Route. *Arch Virol* **1977**, *54*, 251–253, doi:10.1007/BF01314791.
- Sabino, E.C.; Loureiro, P.; Lopes, M.E.; Capuani, L.; McClure, C.; Chowdhury, D.; Di-Lorenzo-Oliveira, C.; Oliveira, L.C.; Linnen, J.M.; Lee, T.-H.; et al. Transfusion-Transmitted Dengue and Associated Clinical Symptoms During the 2012 Epidemic in Brazil. *J Infect Dis* **2016**, *213*, 694–702, doi:10.1093/infdis/jiv326.
- Slavov, S.N.; Cilião-Alves, D.C.; Gonzaga, F.A.C.; Moura, D.R.; de Moura, A.C.A.M.; de Noronha, L.A.G.; Cassemiro, É.M.; Pimentel, B.M.S.; Costa, F.J.Q.; da Silva, G.A.; et al. Dengue Seroprevalence among Asymptomatic Blood Donors during an Epidemic Outbreak in Central-West Brazil. *PLoS One* **2019**, *14*, e0213793, doi:10.1371/journal.pone.0213793.
- Chaturvedi, U.C.; Mathur, A.; Chandra, A.; Das, S.K.; Tandon, H.O.; Singh, U.K. Transplacental Infection with Japanese Encephalitis Virus. *J Infect Dis* **1980**, *141*, 712–715, doi:10.1093/infdis/141.6.712.

21. Oliveira Melo, A.S.; Malinger, G.; Ximenes, R.; Szejnfeld, P.O.; Alves Sampaio, S.; Bispo de Filippis, A.M. Zika Virus Intrauterine Infection Causes Fetal Brain Abnormality and Microcephaly: Tip of the Iceberg? *Ultrasound Obstet Gynecol* **2016**, *47*, 6–7, doi:10.1002/uog.15831.
22. Guérin, B.; Pozzi, N. Viruses in Boar Semen: Detection and Clinical as Well as Epidemiological Consequences Regarding Disease Transmission by Artificial Insemination. *Theriogenology* **2005**, *63*, 556–572, doi:10.1016/j.theriogenology.2004.09.030.
23. Paz-Bailey, G.; Rosenberg, E.S.; Doyle, K.; Munoz-Jordan, J.; Santiago, G.A.; Klein, L.; Perez-Padilla, J.; Medina, F.A.; Waterman, S.H.; Gubern, C.G.; et al. Persistence of Zika Virus in Body Fluids - Final Report. *N Engl J Med* **2018**, *379*, 1234–1243, doi:10.1056/NEJMoa1613108.
24. Kuno, G. Serodiagnosis of Flaviviral Infections and Vaccinations in Humans. *Adv Virus Res* **2003**, *61*, 3–65, doi:10.1016/s0065-3527(03)61001-8.
25. Alhajj, M.; Zubair, M.; Farhana, A. Enzyme Linked Immunosorbent Assay. In *StatPearls*; StatPearls Publishing: Treasure Island (FL), 2023.
26. Roberts, A.; Gandhi, S. Japanese Encephalitis Virus: A Review on Emerging Diagnostic Techniques. *Front Biosci (Landmark Ed)* **2020**, *25*, 1875–1893, doi:10.2741/4882.
27. Guzman, M.G.; Gubler, D.J.; Izquierdo, A.; Martinez, E.; Halstead, S.B. Dengue Infection. *Nat Rev Dis Primers* **2016**, *2*, 16055, doi:10.1038/nrdp.2016.55.
28. Halstead, S.B. Dengue. *Curr Opin Infect Dis* **2002**, *15*, 471–476, doi:10.1097/00001432-200210000-00003.
29. Murray, N.E.A.; Quam, M.B.; Wilder-Smith, A. Epidemiology of Dengue: Past, Present and Future Prospects. *Clin Epidemiol* **2013**, *5*, 299–309, doi:10.2147/CLEP.S34440.
30. *Dengue: Guidelines for Diagnosis, Treatment, Prevention and Control: New Edition*; WHO Guidelines Approved by the Guidelines Review Committee; World Health Organization: Geneva, 2009; ISBN 978-92-4-154787-1.
31. Bhatt, S.; Gething, P.W.; Brady, O.J.; Messina, J.P.; Farlow, A.W.; Moyes, C.L.; Drake, J.M.; Brownstein, J.S.; Hoen, A.G.; Sankoh, O.; et al. The Global Distribution and Burden of Dengue. *Nature* **2013**, *496*, 504–507, doi:10.1038/nature12060.
32. World Health Organization *Global Strategy for Dengue Prevention and Control 2012-2020*; World Health Organization, 2012;
33. Gubler, D.J. Dengue, Urbanization and Globalization: The Unholy Trinity of the 21(St) Century. *Trop Med Health* **2011**, *39*, 3–11, doi:10.2149/tmh.2011-S05.
34. Kapoor, H.K.; Bhai, S.; John, M.; Xavier, J. Ocular Manifestations of Dengue Fever in an East Indian Epidemic. *Can J Ophthalmol* **2006**, *41*, 741–746, doi:10.3129/i06-069.
35. Gupta, A.; Srinivasan, R.; Setia, S.; Soundravally, R.; Pandian, D.G. Uveitis Following Dengue Fever. *Eye (Lond)* **2009**, *23*, 873–876, doi:10.1038/eye.2008.124.
36. Loh, B.-K.; Bacsal, K.; Chee, S.-P.; Cheng, B.C.-L.; Wong, D. Foveolitis Associated with Dengue Fever: A Case Series. *Ophthalmologica* **2008**, *222*, 317–320, doi:10.1159/000144074.
37. Su, D.H.-W.; Bacsal, K.; Chee, S.-P.; Flores, J.V.P.; Lim, W.-K.; Cheng, B.C.-L.; Jap, A.H.-E.; Dengue Maculopathy Study Group Prevalence of Dengue Maculopathy in Patients Hospitalized for Dengue Fever. *Ophthalmology* **2007**, *114*, 1743–1747, doi:10.1016/j.ophtha.2007.03.054.
38. Chee, E.; Sims, J.L.; Jap, A.; Tan, B.H.; Oh, H.; Chee, S.-P. Comparison of Prevalence of Dengue Maculopathy during Two Epidemics with Differing Predominant Serotypes. *Am J Ophthalmol* **2009**, *148*, 910–913, doi:10.1016/j.ajo.2009.06.030.
39. Teoh, S.C.; Chee, C.K.; Laude, A.; Goh, K.Y.; Barkham, T.; Ang, B.S.; Eye Institute Dengue-related Ophthalmic Complications Workgroup Optical Coherence Tomography Patterns as Predictors of Visual Outcome in Dengue-Related Maculopathy. *Retina* **2010**, *30*, 390–398, doi:10.1097/IAE.0b013e3181bd2fc6.
40. Bacsal, K.E.; Chee, S.-P.; Cheng, C.-L.; Flores, J.V.P. Dengue-Associated Maculopathy. *Arch Ophthalmol* **2007**, *125*, 501–510, doi:10.1001/archophth.125.4.501.
41. Yip, V.C.-H.; Sanjay, S.; Koh, Y.T. Ophthalmic Complications of Dengue Fever: A Systematic Review. *Ophthalmol Ther* **2012**, *1*, 2, doi:10.1007/s40123-012-0002-z.
42. Agarwal, A.; Aggarwal, K.; Dogra, M.; Kumar, A.; Akella, M.; Katoch, D.; Bansal, R.; Singh, R.; Gupta, V.; OCTA Study Group Dengue-Induced Inflammatory, Ischemic Foveolitis and Outer Maculopathy: A Swept-Source Imaging Evaluation. *Ophthalmol Retina* **2019**, *3*, 170–177, doi:10.1016/j.oret.2018.09.008.
43. Khairallah, M.; Yahia, S.B.; Attia, S. Arthropod Vector-Borne Uveitis in the Developing World. *Int Ophthalmol Clin* **2010**, *50*, 125–144, doi:10.1097/IIO.0b013e3181d2cf2e.

44. Tabbara, K. Dengue Retinochoroiditis. *Ann Saudi Med* **2012**, *32*, 530–533, doi:10.5144/0256-4947.2012.30.4.1105.
45. Somkijrungsroj, T.; Kongwattananon, W. Ocular Manifestations of Dengue. *Curr Opin Ophthalmol* **2019**, *30*, 500–505, doi:10.1097/ICU.0000000000000613.
46. Dhoot, S.K. Bilateral Ciliochoroidal Effusion with Secondary Angle Closure and Myopic Shift in Dengue Fever. *Ocul Immunol Inflamm* **2023**, *31*, 847–850, doi:10.1080/09273948.2022.2053548.
47. Saranappa S B, S.; Sowbhagya, H.N. Panophthalmitis in Dengue Fever. *Indian Pediatr* **2012**, *49*, 760, doi:10.1007/s13312-012-0142-1.
48. Arya, D.; Das, S.; Shah, G.; Gandhi, A. Panophthalmitis Associated with Scleral Necrosis in Dengue Hemorrhagic Fever. *Indian J Ophthalmol* **2019**, *67*, 1775–1777, doi:10.4103/ijo.IJO_2050_18.
49. Kularatne, S.A.; Dalugama, C. Dengue Infection: Global Importance, Immunopathology and Management. *Clin Med (Lond)* **2022**, *22*, 9–13, doi:10.7861/clinmed.2021-0791.
50. Scherwitzl, I.; Mongkolsapaja, J.; Screaton, G. Recent Advances in Human Flavivirus Vaccines. *Curr Opin Virol* **2017**, *23*, 95–101, doi:10.1016/j.coviro.2017.04.002.
51. Lim, W.-K.; Mathur, R.; Koh, A.; Yeoh, R.; Chee, S.-P. Ocular Manifestations of Dengue Fever. *Ophthalmology* **2004**, *111*, 2057–2064, doi:10.1016/j.ophtha.2004.03.038.
52. Petersen, L.R.; Brault, A.C.; Nasci, R.S. West Nile Virus: Review of the Literature. *JAMA* **2013**, *310*, 308–315, doi:10.1001/jama.2013.8042.
53. Garg, S.; Jampol, L.M. Systemic and Intraocular Manifestations of West Nile Virus Infection. *Surv Ophthalmol* **2005**, *50*, 3–13, doi:10.1016/j.survophthal.2004.10.001.
54. Troupin, A.; Colpitts, T.M. Overview of West Nile Virus Transmission and Epidemiology. *Methods Mol Biol* **2016**, *1435*, 15–18, doi:10.1007/978-1-4939-3670-0_2.
55. Zannoli, S.; Sambri, V. West Nile Virus and Usutu Virus Co-Circulation in Europe: Epidemiology and Implications. *Microorganisms* **2019**, *7*, 184, doi:10.3390/microorganisms7070184.
56. Gyure, K.A. West Nile Virus Infections. *J Neuropathol Exp Neurol* **2009**, *68*, 1053–1060, doi:10.1097/NEN.0b013e3181b88114.
57. Khairallah, M.; Ben Yahia, S.; Ladjimi, A.; Zeghidi, H.; Ben Romdhane, F.; Besbes, L.; Zaouali, S.; Messaoud, R. Chorioretinal Involvement in Patients with West Nile Virus Infection. *Ophthalmology* **2004**, *111*, 2065–2070, doi:10.1016/j.ophtha.2004.03.032.
58. Chan, C.K.; Limstrom, S.A.; Tarasewicz, D.G.; Lin, S.G. Ocular Features of West Nile Virus Infection in North America: A Study of 14 Eyes. *Ophthalmology* **2006**, *113*, 1539–1546, doi:10.1016/j.ophtha.2006.04.021.
59. Sivakumar, R.R.; Prajna, L.; Arya, L.K.; Muraly, P.; Shukla, J.; Saxena, D.; Parida, M. Molecular Diagnosis and Ocular Imaging of West Nile Virus Retinitis and Neuroretinitis. *Ophthalmology* **2013**, *120*, 1820–1826, doi:10.1016/j.ophtha.2013.02.006.
60. Dahal, U.; Mobarakai, N.; Sharma, D.; Pathak, B. West Nile Virus Infection and Diplopia: A Case Report and Review of Literature. *Int J Gen Med* **2013**, *6*, 369–373, doi:10.2147/IJGM.S42853.
61. Khairallah, M.; Ben Yahia, S.; Attia, S.; Zaouali, S.; Ladjimi, A.; Messaoud, R. Linear Pattern of West Nile Virus-Associated Chorioretinitis Is Related to Retinal Nerve Fibres Organization. *Eye (Lond)* **2007**, *21*, 952–955, doi:10.1038/sj.eye.6702355.
62. Learned, D.; Nudleman, E.; Robinson, J.; Chang, E.; Stec, L.; Faia, L.J.; Wolfe, J.; Williams, G.A. Multimodal Imaging of West Nile Virus Chorioretinitis. *Retina* **2014**, *34*, 2269–2274, doi:10.1097/IAE.0000000000000213.
63. Khairallah, M.; Ben Yahia, S.; Attia, S.; Zaouali, S.; Jelliti, B.; Jenzri, S.; Ladjimi, A.; Messaoud, R. Indocyanine Green Angiographic Features in Multifocal Chorioretinitis Associated with West Nile Virus Infection. *Retina* **2006**, *26*, 358–359, doi:10.1097/00006982-200603000-00019.
64. Khairallah, M.; Jelliti, B.; Jenzri, S. Emergent Infectious Uveitis. *Middle East Afr J Ophthalmol* **2009**, *16*, 225–238, doi:10.4103/0974-9233.58426.
65. Khairallah, M.; Kahloun, R. Ocular Manifestations of Emerging Infectious Diseases. *Curr Opin Ophthalmol* **2013**, *24*, 574–580, doi:10.1097/ICU.0b013e3283654e09.
66. Khairallah, M.; Kahloun, R.; Gargouri, S.; Jelliti, B.; Sellami, D.; Ben Yahia, S.; Feki, J. Swept-Source Optical Coherence Tomography Angiography in West Nile Virus Chorioretinitis and Associated Occlusive Retinal Vasculitis. *Ophthalmic Surg Lasers Imaging Retina* **2017**, *48*, 672–675, doi:10.3928/23258160-20170802-11.
67. Shukla, J.; Saxena, D.; Rathinam, S.; Lalitha, P.; Joseph, C.R.; Sharma, S.; Soni, M.; Rao, P.V.L.; Parida, M. Molecular Detection and Characterization of West Nile Virus Associated with Multifocal Retinitis in Patients from Southern India. *Int J Infect Dis* **2012**, *16*, e53–59, doi:10.1016/j.ijid.2011.09.020.

68. Lazear, H.M.; Pinto, A.K.; Vogt, M.R.; Gale, M.; Diamond, M.S. Beta Interferon Controls West Nile Virus Infection and Pathogenesis in Mice. *J Virol* **2011**, *85*, 7186–7194, doi:10.1128/JVI.00396-11.
69. Ben-Nathan, D.; Gershoni-Yahalom, O.; Samina, I.; Khinich, Y.; Nur, I.; Laub, O.; Gottreich, A.; Simanov, M.; Porgador, A.; Rager-Zisman, B.; et al. Using High Titer West Nile Intravenous Immunoglobulin from Selected Israeli Donors for Treatment of West Nile Virus Infection. *BMC Infect Dis* **2009**, *9*, 18, doi:10.1186/1471-2334-9-18.
70. Gorman, M.J.; Poddar, S.; Farzan, M.; Diamond, M.S. The Interferon-Stimulated Gene Ifitm3 Restricts West Nile Virus Infection and Pathogenesis. *J Virol* **2016**, *90*, 8212–8225, doi:10.1128/JVI.00581-16.
71. Seth, R.K.; Stoessel, K.M.; Adelman, R.A. Choroidal Neovascularization Associated with West Nile Virus Chorioretinitis. *Semin Ophthalmol* **2007**, *22*, 81–84, doi:10.1080/08820530701418375.
72. Afshar, A.R.; Hariprasad, S.M.; Jampol, L.M.; Sheth, V.S. Use of Intravitreal Bevacizumab to Treat Macular Edema in West Nile Virus Chorioretinitis. *Arch Ophthalmol* **2012**, *130*, 396–398, doi:10.1001/archophthalmol.2011.1630.
73. Sanz, G.; De Jesus Rodriguez, E.; Vila-Delgado, M.; Oliver, A.L. An Unusual Case of Unilateral Chorioretinitis and Blind Spot Enlargement Associated with Asymptomatic West Nile Virus Infection. *Am J Ophthalmol Case Rep* **2020**, *18*, 100723, doi:10.1016/j.ajoc.2020.100723.
74. Khairallah, M.; Yahia, S.B.; Letaief, M.; Attia, S.; Kahloun, R.; Jelliti, B.; Zaouali, S.; Messaoud, R. A Prospective Evaluation of Factors Associated with Chorioretinitis in Patients with West Nile Virus Infection. *Ocul Immunol Inflamm* **2007**, *15*, 435–439, doi:10.1080/09273940701798488.
75. Khairallah, M.; Ben Yahia, S.; Attia, S.; Jelliti, B.; Zaouali, S.; Ladjimi, A. Severe Ischemic Maculopathy in a Patient with West Nile Virus Infection. *Ophthalmic Surg Lasers Imaging* **2006**, *37*, 240–242, doi:10.3928/15428877-20060501-11.
76. Monath, T.P. Yellow Fever: An Update. *Lancet Infect Dis* **2001**, *1*, 11–20, doi:10.1016/S1473-3099(01)00016-0.
77. Lucey, D.; Gostin, L.O. A Yellow Fever Epidemic: A New Global Health Emergency? *JAMA* **2016**, *315*, 2661–2662, doi:10.1001/jama.2016.6606.
78. Douam, F.; Ploss, A. Yellow Fever Virus: Knowledge Gaps Impeding the Fight Against an Old Foe. *Trends Microbiol* **2018**, *26*, 913–928, doi:10.1016/j.tim.2018.05.012.
79. Brandão-de-Resende, C.; Cunha, L.H.M.; Oliveira, S.L.; Pereira, L.S.; Oliveira, J.G.F.; Santos, T.A.; Vasconcelos-Santos, D.V. Characterization of Retinopathy Among Patients With Yellow Fever During 2 Outbreaks in Southeastern Brazil. *JAMA Ophthalmol* **2019**, *137*, 996–1002, doi:10.1001/jamaophthalmol.2019.1956.
80. Vianello, S.; Silva de Souza, G.; Maia, M.; Belfort, R.; de Oliveira Dias, J.R. Ocular Findings in Yellow Fever Infection. *JAMA Ophthalmol* **2019**, *137*, 300–304, doi:10.1001/jamaophthalmol.2018.6408.
81. Biancardi, A.L.; Moraes, H.V. de Anterior and Intermediate Uveitis Following Yellow Fever Vaccination with Fractional Dose: Case Reports. *Ocul Immunol Inflamm* **2019**, *27*, 521–523, doi:10.1080/09273948.2018.1510529.
82. Campos, W.R.; Cenachi, S.P.F.; Soares, M.S.; Gonçalves, P.F.; Vasconcelos-Santos, D.V. Vogt-Koyanagi-Harada-like Disease Following Yellow Fever Vaccination. *Ocul Immunol Inflamm* **2021**, *29*, 124–127, doi:10.1080/09273948.2019.1661498.
83. Vannice, K.; Wilder-Smith, A.; Hombach, J. Fractional-Dose Yellow Fever Vaccination - Advancing the Evidence Base. *N Engl J Med* **2018**, *379*, 603–605, doi:10.1056/NEJMp1803433.
84. Yellow Fever Vaccine. In *Drugs and Lactation Database (LactMed®)*; National Institute of Child Health and Human Development: Bethesda (MD), 2006.
85. Plourde, A.R.; Bloch, E.M. A Literature Review of Zika Virus. *Emerg Infect Dis* **2016**, *22*, 1185–1192, doi:10.3201/eid2207.151990.
86. Musso, D.; Roche, C.; Robin, E.; Nhan, T.; Teissier, A.; Cao-Lormeau, V.-M. Potential Sexual Transmission of Zika Virus. *Emerg Infect Dis* **2015**, *21*, 359–361, doi:10.3201/eid2102.141363.
87. Musso, D.; Nhan, T.; Robin, E.; Roche, C.; Bierlaire, D.; Zisou, K.; Shan Yan, A.; Cao-Lormeau, V.M.; Broult, J. Potential for Zika Virus Transmission through Blood Transfusion Demonstrated during an Outbreak in French Polynesia, November 2013 to February 2014. *Euro Surveill* **2014**, *19*, 20761, doi:10.2807/1560-7917.es2014.19.14.20761.
88. Dick, G.W.A.; Kitchen, S.F.; Haddow, A.J. Zika Virus. I. Isolations and Serological Specificity. *Trans R Soc Trop Med Hyg* **1952**, *46*, 509–520, doi:10.1016/0035-9203(52)90042-4.

89. de Oliveira, W.K.; de França, G.V.A.; Carmo, E.H.; Duncan, B.B.; de Souza Kuchenbecker, R.; Schmidt, M.I. Infection-Related Microcephaly after the 2015 and 2016 Zika Virus Outbreaks in Brazil: A Surveillance-Based Analysis. *Lancet* **2017**, *390*, 861–870, doi:10.1016/S0140-6736(17)31368-5.
90. Duffy, M.R.; Chen, T.-H.; Hancock, W.T.; Powers, A.M.; Kool, J.L.; Lanciotti, R.S.; Pretrick, M.; Marfel, M.; Holzbauer, S.; Dubray, C.; et al. Zika Virus Outbreak on Yap Island, Federated States of Micronesia. *N Engl J Med* **2009**, *360*, 2536–2543, doi:10.1056/NEJMoa0805715.
91. Muñoz, L.S.; Barreras, P.; Pardo, C.A. Zika Virus-Associated Neurological Disease in the Adult: Guillain-Barré Syndrome, Encephalitis, and Myelitis. *Semin Reprod Med* **2016**, *34*, 273–279, doi:10.1055/s-0036-1592066.
92. Leonhard, S.E.; Bresani-Salvi, C.C.; Lyra Batista, J.D.; Cunha, S.; Jacobs, B.C.; Brito Ferreira, M.L.; P Militão de Albuquerque, M. de F. Guillain-Barré Syndrome Related to Zika Virus Infection: A Systematic Review and Meta-Analysis of the Clinical and Electrophysiological Phenotype. *PLoS Negl Trop Dis* **2020**, *14*, e0008264, doi:10.1371/journal.pntd.0008264.
93. Moore, C.A.; Staples, J.E.; Dobyns, W.B.; Pessoa, A.; Ventura, C.V.; Fonseca, E.B. da; Ribeiro, E.M.; Ventura, L.O.; Neto, N.N.; Arena, J.F.; et al. Characterizing the Pattern of Anomalies in Congenital Zika Syndrome for Pediatric Clinicians. *JAMA Pediatr* **2017**, *171*, 288–295, doi:10.1001/jamapediatrics.2016.3982.
94. Troumani, Y.; Touhami, S.; Jackson, T.L.; Ventura, C.V.; Stanesco-Segall, D.M.; Errera, M.-H.; Rousset, D.; Bodaghi, B.; Cartry, G.; David, T.; et al. Association of Anterior Uveitis With Acute Zika Virus Infection in Adults. *JAMA Ophthalmol* **2021**, *139*, 95–102, doi:10.1001/jamaophthalmol.2020.5131.
95. Parke, D.W.; Almeida, D.R.P.; Albin, T.A.; Ventura, C.V.; Berrocal, A.M.; Mittra, R.A. Serologically Confirmed Zika-Related Unilateral Acute Maculopathy in an Adult. *Ophthalmology* **2016**, *123*, 2432–2433, doi:10.1016/j.ophtha.2016.06.039.
96. Kodati, S.; Palmore, T.N.; Spellman, F.A.; Cunningham, D.; Weistrop, B.; Sen, H.N. Bilateral Posterior Uveitis Associated with Zika Virus Infection. *Lancet* **2017**, *389*, 125–126, doi:10.1016/S0140-6736(16)32518-1.
97. Ventura, C.V.; Ventura, L.O. Ophthalmologic Manifestations Associated With Zika Virus Infection. *Pediatrics* **2018**, *141*, S161–S166, doi:10.1542/peds.2017-2038E.
98. Ventura, C.V.; Maia, M.; Travassos, S.B.; Martins, T.T.; Patriota, F.; Nunes, M.E.; Agra, C.; Torres, V.L.; van der Linden, V.; Ramos, R.C.; et al. Risk Factors Associated With the Ophthalmoscopic Findings Identified in Infants With Presumed Zika Virus Congenital Infection. *JAMA Ophthalmol* **2016**, *134*, 912–918, doi:10.1001/jamaophthalmol.2016.1784.
99. Ventura, C.V.; Maia, M.; Bravo-Filho, V.; Góis, A.L.; Belfort, R. Zika Virus in Brazil and Macular Atrophy in a Child with Microcephaly. *Lancet* **2016**, *387*, 228, doi:10.1016/S0140-6736(16)00006-4.
100. Marquezan, M.C.; Ventura, C.V.; Sheffield, J.S.; Golden, W.C.; Omiadze, R.; Belfort, R.; May, W. Ocular Effects of Zika Virus—a Review. *Surv Ophthalmol* **2018**, *63*, 166–173, doi:10.1016/j.survophthal.2017.06.001.
101. Ventura, C.V.; Ventura, L.O.; Bravo-Filho, V.; Martins, T.T.; Berrocal, A.M.; Góis, A.L.; de Oliveira Dias, J.R.; Araújo, L.; Escarião, P.; van der Linden, V.; et al. Optical Coherence Tomography of Retinal Lesions in Infants With Congenital Zika Syndrome. *JAMA Ophthalmol* **2016**, *134*, 1420–1427, doi:10.1001/jamaophthalmol.2016.4283.
102. Zin, A.A.; Tsui, I.; Rossetto, J.; Vasconcelos, Z.; Adachi, K.; Valderramos, S.; Halai, U.-A.; Pone, M.V. da S.; Pone, S.M.; Silveira Filho, J.C.B.; et al. Screening Criteria for Ophthalmic Manifestations of Congenital Zika Virus Infection. *JAMA Pediatr* **2017**, *171*, 847–854, doi:10.1001/jamapediatrics.2017.1474.
103. de Paula Freitas, B.; de Oliveira Dias, J.R.; Prazeres, J.; Sacramento, G.A.; Ko, A.I.; Maia, M.; Belfort, R. Ocular Findings in Infants With Microcephaly Associated With Presumed Zika Virus Congenital Infection in Salvador, Brazil. *JAMA Ophthalmol* **2016**, *134*, 529–535, doi:10.1001/jamaophthalmol.2016.0267.
104. Vasconcelos, G.C.; Macedo Pereira, C.M.; Toledo de Paula, C.H.; de Souza Haueisen Barbosa, P.; Machado de Souza, D.; Coelho, L.M. Corneal Ectasia and High Ametropia in an Infant with Microcephaly Associated with Presumed Zika Virus Congenital Infection: New Ocular Findings. *J AAPOS* **2019**, *23*, 354–356, doi:10.1016/j.jaapos.2019.08.281.
105. Yopez, J.B.; Murati, F.A.; Pettito, M.; Peñaranda, C.F.; de Yopez, J.; Maestre, G.; Arevalo, J.F.; Johns Hopkins Zika Center Ophthalmic Manifestations of Congenital Zika Syndrome in Colombia and Venezuela. *JAMA Ophthalmol* **2017**, *135*, 440–445, doi:10.1001/jamaophthalmol.2017.0561.
106. Fernandez, M.P.; Parra Saad, E.; Ospina Martinez, M.; Corchuelo, S.; Mercado Reyes, M.; Herrera, M.J.; Parra Saavedra, M.; Rico, A.; Fernandez, A.M.; Lee, R.K.; et al. Ocular Histopathologic Features of Congenital Zika Syndrome. *JAMA Ophthalmol* **2017**, *135*, 1163–1169, doi:10.1001/jamaophthalmol.2017.3595.

107. Agrawal, R.; Oo, H.H.; Balne, P.K.; Ng, L.; Tong, L.; Leo, Y.S. Zika Virus and the Eye. *Ocul Immunol Inflamm* **2018**, *26*, 654–659, doi:10.1080/09273948.2017.1294184.
108. Gourinat, A.-C.; O'Connor, O.; Calvez, E.; Goarant, C.; Dupont-Rouzeyrol, M. Detection of Zika Virus in Urine. *Emerg Infect Dis* **2015**, *21*, 84–86, doi:10.3201/eid2101.140894.
109. Rabe, I.B.; Staples, J.E.; Villanueva, J.; Hummel, K.B.; Johnson, J.A.; Rose, L.; MTS; Hills, S.; Wasley, A.; Fischer, M.; et al. Interim Guidance for Interpretation of Zika Virus Antibody Test Results. *MMWR Morb Mortal Wkly Rep* **2016**, *65*, 543–546, doi:10.15585/mmwr.mm6521e1.
110. Wang, Y.; Ling, L.; Zhang, Z.; Marin-Lopez, A. Current Advances in Zika Vaccine Development. *Vaccines (Basel)* **2022**, *10*, 1816, doi:10.3390/vaccines10111816.
111. *Statement on the Medical Care Provided for and the Monitoring of New-Borns and Infants Having Been Exposed to the Zika Virus in Utero or Present* <https://www.hcsp.fr/Explore.cgi/AvisRapportsDomaine?Clefr=675>; Haut conseil de la sante publique, 2017;
112. Adebajo, T.; Godfred-Cato, S.; Viens, L.; Fischer, M.; Staples, J.E.; Kuhnert-Tallman, W.; Walke, H.; Oduyebo, T.; Polen, K.; Peacock, G.; et al. Update: Interim Guidance for the Diagnosis, Evaluation, and Management of Infants with Possible Congenital Zika Virus Infection - United States, October 2017. *MMWR Morb Mortal Wkly Rep* **2017**, *66*, 1089–1099, doi:10.15585/mmwr.mm6641a1.
113. Yakob, L.; Hu, W.; Frentiu, F.D.; Gyawali, N.; Hugo, L.E.; Johnson, B.; Lau, C.; Furuya-Kanamori, L.; Magalhaes, R.S.; Devine, G. Japanese Encephalitis Emergence in Australia: The Potential Population at Risk. *Clin Infect Dis* **2023**, *76*, 335–337, doi:10.1093/cid/ciac794.
114. Solomon, T. Control of Japanese Encephalitis--within Our Grasp? *N Engl J Med* **2006**, *355*, 869–871, doi:10.1056/NEJMp058263.
115. Buescher, E.L.; Scherer, W.F.; Rosenberg, M.Z.; Gresser, I.; Hardy, J.L.; Bullock, H.R. Ecologic Studies of Japanese Encephalitis Virus in Japan. II. Mosquito Infection. *Am J Trop Med Hyg* **1959**, *8*, 651–664, doi:10.4269/ajtmh.1959.8.651.
116. Fischer, M.; Lindsey, N.; Staples, J.E.; Hills, S.; Centers for Disease Control and Prevention (CDC) Japanese Encephalitis Vaccines: Recommendations of the Advisory Committee on Immunization Practices (ACIP). *MMWR Recomm Rep* **2010**, *59*, 1–27.
117. Hills, S.L.; Netravathi, M.; Solomon, T. Japanese Encephalitis among Adults: A Review. *Am J Trop Med Hyg* **2023**, *108*, 860–864, doi:10.4269/ajtmh.23-0036.
118. Turtle, L.; Solomon, T. Japanese Encephalitis - the Prospects for New Treatments. *Nat Rev Neurol* **2018**, *14*, 298–313, doi:10.1038/nrneurol.2018.30.
119. Solomon, T.; Dung, N.M.; Kneen, R.; Gainsborough, M.; Vaughn, D.W.; Khanh, V.T. Japanese Encephalitis. *J Neurol Neurosurg Psychiatry* **2000**, *68*, 405–415, doi:10.1136/jnnp.68.4.405.
120. Fang, S.-T.; Chu, S.-Y.; Lee, Y.-C. Ischaemic Maculopathy in Japanese Encephalitis. *Eye (Lond)* **2006**, *20*, 1439–1441, doi:10.1038/sj.eye.6702301.
121. Van, K.; Korman, T.M.; Nicholson, S.; Troutbeck, R.; Lister, D.M.; Woolley, I. Case Report: Japanese Encephalitis Associated with Chorioretinitis after Short-Term Travel to Bali, Indonesia. *Am J Trop Med Hyg* **2020**, *103*, 1691–1693, doi:10.4269/ajtmh.19-0330.
122. Chanama, S.; Sukprasert, W.; Sa-ngasang, A.; A-nuegonpipat, A.; Sangkitporn, S.; Kurane, I.; Anantapreecha, S. Detection of Japanese Encephalitis (JE) Virus-Specific IgM in Cerebrospinal Fluid and Serum Samples from JE Patients. *Jpn J Infect Dis* **2005**, *58*, 294–296.
123. Swami, R.; Ratho, R.K.; Mishra, B.; Singh, M.P. Usefulness of RT-PCR for the Diagnosis of Japanese Encephalitis in Clinical Samples. *Scand J Infect Dis* **2008**, *40*, 815–820, doi:10.1080/00365540802227102.
124. Sarkar, A.; Taraphdar, D.; Mukhopadhyay, S.K.; Chakrabarti, S.; Chatterjee, S. Serological and Molecular Diagnosis of Japanese Encephalitis Reveals an Increasing Public Health Problem in the State of West Bengal, India. *Trans R Soc Trop Med Hyg* **2012**, *106*, 15–19, doi:10.1016/j.trstmh.2011.08.011.
125. Sarkar, A.; Datta, S.; Pathak, B.K.; Mukhopadhyay, S.K.; Chatterjee, S. Japanese Encephalitis Associated Acute Encephalitis Syndrome Cases in West Bengal, India: A Sero-Molecular Evaluation in Relation to Clinico-Pathological Spectrum. *J Med Virol* **2015**, *87*, 1258–1267, doi:10.1002/jmv.24165.
126. Igarashi, A. Control of Japanese Encephalitis in Japan: Immunization of Humans and Animals, and Vector Control. *Curr Top Microbiol Immunol* **2002**, *267*, 139–152, doi:10.1007/978-3-642-59403-8_7.
127. Erlanger, T.E.; Weiss, S.; Keiser, J.; Utzinger, J.; Wiedenmayer, K. Past, Present, and Future of Japanese Encephalitis. *Emerg Infect Dis* **2009**, *15*, 1–7, doi:10.3201/eid1501.080311.

128. Shah, S.Z.; Jabbar, B.; Ahmed, N.; Rehman, A.; Nasir, H.; Nadeem, S.; Jabbar, I.; Rahman, Z.U.; Azam, S. Epidemiology, Pathogenesis, and Control of a Tick-Borne Disease- Kyasanur Forest Disease: Current Status and Future Directions. *Front Cell Infect Microbiol* **2018**, *8*, 149, doi:10.3389/fcimb.2018.00149.
129. Work, T.H.; Trapido, H.; Murthy, D.P.N.; Rao, R.L.; Bhatt, P.N.; Kulkarni, K.G. Kyasanur Forest Disease. III. A Preliminary Report on the Nature of the Infection and Clinical Manifestations in Human Beings. *Indian J Med Sci* **1957**, *11*, 619–645.
130. Chakraborty, S.; Andrade, F.C.D.; Ghosh, S.; Uelmen, J.; Ruiz, M.O. Historical Expansion of Kyasanur Forest Disease in India From 1957 to 2017: A Retrospective Analysis. *Geohealth* **2019**, *3*, 44–55, doi:10.1029/2018GH000164.
131. Sadanandane, C.; Gokhale, M.D.; Elango, A.; Yadav, P.; Mourya, D.T.; Jambulingam, P. Prevalence and Spatial Distribution of Ixodid Tick Populations in the Forest Fringes of Western Ghats Reported with Human Cases of Kyasanur Forest Disease and Monkey Deaths in South India. *Exp Appl Acarol* **2018**, *75*, 135–142, doi:10.1007/s10493-018-0223-5.
132. Pattnaik, P. Kyasanur Forest Disease: An Epidemiological View in India. *Rev Med Virol* **2006**, *16*, 151–165, doi:10.1002/rmv.495.
133. Ocular Manifestations of Kyasanur Forest Disease (a Clinical Study). *Indian J Ophthalmol* **1983**, *31*, 700–702.
134. Mourya, D.T.; Yadav, P.D.; Mehla, R.; Barde, P.V.; Yergolkar, P.N.; Kumar, S.R.P.; Thakare, J.P.; Mishra, A.C. Diagnosis of Kyasanur Forest Disease by Nested RT-PCR, Real-Time RT-PCR and IgM Capture ELISA. *J Virol Methods* **2012**, *186*, 49–54, doi:10.1016/j.jviromet.2012.07.019.
135. Kiran, S.K.; Pasi, A.; Kumar, S.; Kasabi, G.S.; Gujjarappa, P.; Shrivastava, A.; Mehendale, S.; Chauhan, L.S.; Laserson, K.F.; Murhekar, M. Kyasanur Forest Disease Outbreak and Vaccination Strategy, Shimoga District, India, 2013–2014. *Emerg Infect Dis* **2015**, *21*, 146–149, doi:10.3201/eid2101.141227.
136. Ogden, N.H.; Bigras-Poulin, M.; O'Callaghan, C.J.; Barker, I.K.; Lindsay, L.R.; Maarouf, A.; Smoyer-Tomic, K.E.; Waltner-Toews, D.; Charron, D. A Dynamic Population Model to Investigate Effects of Climate on Geographic Range and Seasonality of the Tick *Ixodes Scapularis*. *Int J Parasitol* **2005**, *35*, 375–389, doi:10.1016/j.ijpara.2004.12.013.
137. Satish, K.V.; Saranya, K.R.L.; Reddy, C.S.; Krishna, P.H.; Jha, C.S.; Rao, P.V.V.P. Geospatial Assessment and Monitoring of Historical Forest Cover Changes (1920–2012) in Nilgiri Biosphere Reserve, Western Ghats, India. *Environ Monit Assess* **2014**, *186*, 8125–8140, doi:10.1007/s10661-014-3991-3.
138. Hulo, C.; de Castro, E.; Masson, P.; Bougueleret, L.; Bairoch, A.; Xenarios, I.; Le Mercier, P. ViralZone: A Knowledge Resource to Understand Virus Diversity. *Nucleic Acids Res* **2011**, *39*, D576–582, doi:10.1093/nar/gkq901.

Disclaimer/Publisher's Note: The statements, opinions and data contained in all publications are solely those of the individual author(s) and contributor(s) and not of MDPI and/or the editor(s). MDPI and/or the editor(s) disclaim responsibility for any injury to people or property resulting from any ideas, methods, instructions or products referred to in the content.