Preprints.org

Review

Not peer-reviewed version

Fetal Ebstein Anomaly: From Integrated Echocardiographic Assessment to Evolving Prognostic Scoring Models

Mohammed Kamal Badawy [†] and Suhair Omar Shebani [*,†]

Posted Date: 15 June 2026

doi: 10.20944/preprints202606.1179.v1

Keywords: Ebstein anomaly; fetal echocardiography; prenatal diagnosis; risk stratification; prognostic scoring; tricuspid regurgitation; circular shunt

Preprints.org is a free multidisciplinary platform providing preprint service that is dedicated to making early versions of research outputs permanently available and citable. Preprints posted at Preprints.org appear in Web of Science, Crossref, Google Scholar, Scilit, Europe PMC, OpenAlex.

Copyright: This open access article is published under a Creative Commons CC BY 4.0 license, which permit the free download, distribution, and reuse, provided that the author and preprint are cited in any reuse.

Preprints.org (www.preprints.org) | NOT PEER-REVIEWED | Posted: 15 June 2026 doi:10.20944/preprints202606.1179.v1

Disclaimer/Publisher's Note: The statements, opinions, and data contained in all publications are solely those of the individual author(s) and contributor(s) and not of MDPI and/or the editor(s). MDPI and/or the editor(s) disclaim responsibility for any injury to people or property resulting from any ideas, methods, instructions, or products referred to in the content.

Review

Fetal Ebstein Anomaly: From Integrated Echocardiographic Assessment to Evolving Prognostic Scoring Models

Mohammed Kamal Badawy † and Suhair Omar Shebani *,†

Paediatric Cardiology Department, East Midlands Congenital Heart Centre, University Hospitals of Leicester NHS Trust, Leicester, United Kingdom

* Correspondence: suhair.shebani1@nhs.net

† These authors contributed equally to this work.

Abstract

Ebstein anomaly is a rare congenital cardiac malformation with a highly variable prenatal course, ranging from stable physiology to progressive fetal heart failure and perinatal death. Predicting outcome remains difficult because anatomical severity alone does not reliably reflect physiological burden, ventricular performance, or disease progression. Therefore, fetal echocardiography plays a central role in both diagnosis and risk stratification. This review summarises the current approaches to fetal echocardiographic assessment of Ebstein anomaly, focusing on anatomical, functional, and Doppler-derived markers associated with adverse outcomes, including severe tricuspid regurgitation, cardiomegaly, right and left ventricular dysfunction, abnormal pulmonary and ductal flow patterns, and circular shunt physiology. Established prognostic scoring systems were reviewed, highlighting their contributions to risk stratification. Emerging functional parameters and serial assessment strategies have been discussed as complementary tools to better capture the dynamic nature of the disease.

Keywords: Ebstein anomaly; fetal echocardiography; prenatal diagnosis; risk stratification; prognostic scoring; tricuspid regurgitation; circular shunt

Introduction

Ebstein anomaly (EA) is a rare congenital cardiac anomaly characterised by apical displacement and malformation of the tricuspid valve (TV) leaflets, caused by faulty embryological delamination. This results in atrialisation of the right ventricle (RV), reduced functional RV volume, and tricuspid regurgitation (TR) [1]. The clinical presentation ranges from asymptomatic adults to severe fetal and neonatal disease. Detailed fetal echocardiography is essential for parental counselling and risk stratification [2]. This review outlines the current fetal echocardiographic assessment of EA, key prognostic factors, and existing scoring systems to propose updated recommendations to improve perinatal outcome prediction.

Anatomical Abnormalities and Haemodynamic Consequences

EA results from the failure of delamination of the TV leaflets from the interventricular septum, predominantly affecting the septal and posterior leaflets, leading to their apical displacement into the RV cavity. The anterior leaflet often maintains its hinge-point position, but may be redundant, sail-like, or tethered. Apical displacement divides the RV into a proximal atrialised portion and a distal functional ventricle.

The atrialised portion, located between the true atrioventricular annulus and the apically displaced leaflets, is incorporated into the right atrium (RA) and receives regurgitant blood from the malformed TV, resulting in marked enlargement of both the RA and the atrialised RV [3].

© 2026 by the author(s). Distributed under a Creative Commons CC BY license.

Preprints.org (www.preprints.org) | NOT PEER-REVIEWED | Posted: 15 June 2026 doi:10.20944/preprints202606.1179.v1

In severe cases, tricuspid regurgitation (TR) leads to progressive dilatation of the RA and atrialised RV compressing the left heart, thereby reducing left ventricular (LV) filling and function [4]. LV systolic dysfunction is characterised by mechanical dyssynchrony and absence of spherical remodelling, which is typically observed in other right-sided obstructive lesions [5].

The functional RV is hypoplastic with systolic dysfunction. Inadequate RV pressure generation produces functional pulmonary stenosis or atresia, necessitating ductal-dependent pulmonary blood flow [6].

A circular shunt develops from combined severe TR and pulmonary regurgitation (PR), creating a circuit: blood flows retrogradely from the RV to the RA, then across the foramen ovale, and shunts right-to-left to the systemic circulation. From the aorta, blood is redirected through the ductus arteriosus into the pulmonary artery and, in the presence of pulmonary regurgitation, returns to the right ventricle, completing the loop [7] as shown in Figure 1. This produces ineffective systemic output, elevated right-sided pressures, and impaired end-organ perfusion. Its presence is a critical prognostic indicator that warrants close surveillance [8].

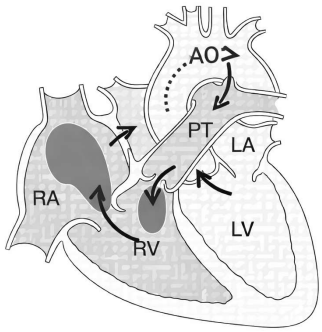

Figure 1. Circular shunt: Severe TR and PR create a loop from RV (right ventricle) → RA (right atrium) → systemic circulation via foramen ovale → AO(aorta) → ductus arteriosus →PT (pulmonary trunk) →regurgitate back to RV.

Fetal Echocardiographic Diagnosis

The apical four-chamber view is the primary echocardiographic plane for evaluating fetal Ebstein anomaly. The hallmark feature is apical displacement of the septal and posterior tricuspid valve leaflets into the right ventricle below the true atrioventricular junction. The anterior leaflet typically remains attached at the annulus but is often elongated, producing a characteristic "sail-like" appearance [9]. In fetal echocardiography, diagnosis relies on the relative displacement of the septal tricuspid leaflet compared to mitral valve insertion rather than fixed indexed measurements, as cardiac size changes throughout gestation; therefore, interpretation is made in relation to gestational age and overall cardiac morphology [10,11].

Additional findings include marked right atrial dilatation due to atrialisation of the proximal right ventricle, leaving a small functional distal right ventricle [12]. Cardiomegaly is common, and a cardiothoracic ratio >0.65 has been associated with adverse neonatal outcomes [13].

Celermajer Index

Also known as the Great Ormond Street Echocardiographic Score (GOSE) is a validated measure of the morphological severity of EA. It is calculated from the apical four-chamber view at end-diastole as the ratio of the combined areas of the right atrium and atrialised right ventricle to the sum of the

© 2026 by the author(s). Distributed under a Creative Commons CC BY license.

Preprints.org (www.preprints.org) | NOT PEER-REVIEWED | Posted: 15 June 2026 doi:10.20944/preprints202606.1179.v1

functional right ventricle, left atrium, and left ventricle, requiring accurate endocardial tracing [14] as illustrated in Figure 2.

Higher values correlate with adverse perinatal outcomes. However, this index reflects structural severity only and does not account for functional or haemodynamic parameters [15].

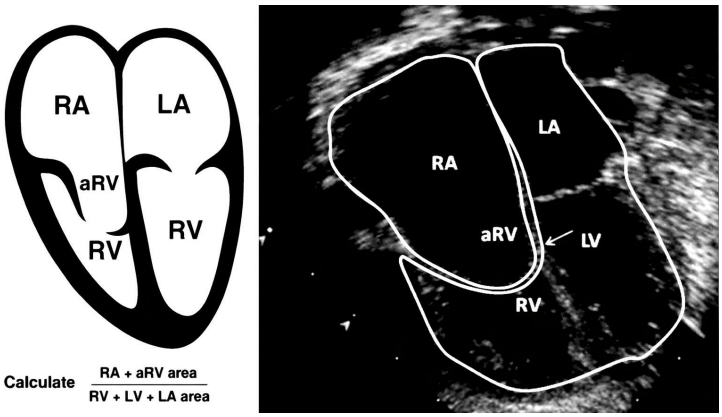

Figure 2. Calculation of the Celermajer Index. RA, right atrium; aRV, atrialised right ventricle; RV, right ventricle; LV, left ventricle; LA, left atrium.

Tricuspid Annular Dimensions and Z-Scores

The tricuspid annulus diameter is measured in the apical four-chamber view at end-diastole between the hinge points of the tricuspid valve leaflets. Measurements are normalized using gestational age–adjusted Z-scores to account for normal fetal cardiac growth [16]. Annular dilatation is a common feature of Ebstein anomaly and correlates with the severity of tricuspid regurgitation and right ventricular volume overload. Serial assessment of Z-scores can aid in monitoring annular dilatation and disease progression during fetal follow-up [17].

Right-to-Left Ventricular Ratios

RV/LV ratios compare ventricular sizes using diameters or traced areas from the four-chamber views. In EA, hypoplasia of the functional RV, enlargement of the RA and atrialised RV result in ventricular disproportion. Elevated RV/LV ratios reflect right-sided volume or pressure overload and are associated with more severe disease. Serial measurements may help assess disease progression over time [18].

Tricuspid Regurgitation (TR) Jet Velocity/Gradient

The TR jet velocity, measured by continuous-wave Doppler, reflects the pressure gradient between the RV and the RA during systole. The maximal TR velocity/gradient provides an indirect estimate of the residual RV systolic pressure and contractile reserve. Lower maximal TR velocities (<40 mmHg gradient) are paradoxically associated with poorer outcomes, as they indicate severe RV dysfunction and an inability to generate adequate pressure, often in the context of significant volume overload and reduced forward flow. Conversely, high TR velocities might suggest better RV contractile function, but also significant regurgitation [18].

Tricuspid Regurgitation dP/dt (RV Contractile Reserve)

It provides a dynamic assessment of RV systolic performance by quantifying the rate of pressure rise during early systole from continuous-wave Doppler of the TR jet. In a cohort of fetuses with EA, higher TR dP/dt values (≥350 mmHg/s) were associated with a preserved right ventricular contractile reserve. Conversely, lower TR dP/dt values reflect impaired systolic pressure generation and

© 2026 by the author(s). Distributed under a Creative Commons CC BY license.

Preprints.org (www.preprints.org) | NOT PEER-REVIEWED | Posted: 15 June 2026 doi:10.20944/preprints202606.1179.v1

advanced ventricular dysfunction. Although supported by limited fetal data, TR dP/dt may complement conventional parameters in prenatal risk stratification [19].

Myocardial Performance Index (MPI) (Tei Index)

Doppler-derived parameter used to assess global ventricular function. It combines the systolic and diastolic time intervals and is calculated as the sum of the isovolumetric contraction time and isovolumetric relaxation time divided by the ejection time. It can be obtained from the pulsed-wave Doppler of ventricular inflow and outflow [20,21]. An elevated MPI indicates impaired ventricular function and has been associated with increased perinatal mortality in fetal EA, reflecting the impact of severe right-sided pathology on left ventricular performance through ventricular interdependence [22]. Its clinical application is limited by measurement variability and the lack of gestation-specific reference values [23].

Speckle-Tracking, Strain, and Deformation Imaging

Two-dimensional speckle-tracking echocardiography (2D-STE) provides a non-Doppler method for measuring fetal myocardial strain. By tracking natural "speckles" in the myocardium, it offers a detailed insight into ventricular function. In EA, 2D-STE helps detect early ventricular dysfunction [24].

Tricuspid Annular Plane Motion Excursion (TAPSE)

TAPSE assesses the longitudinal movement of the tricuspid annulus toward the apex during systole, providing simple measures of ventricular longitudinal motion. Although well-established postnatally, it is less studied in fetal EA and further research is needed to establish its prognostic significance in EA [25].

Doppler Markers

Doppler echocardiography provides a dynamic assessment of fetal blood flow providing key prognostic markers in fetal EA.

- Pulmonary Valve Flow Pattern: The absence of antegrade pulmonary flow indicates functional pulmonary atresia, which is a poor prognostic sign, with pulmonary circulation entirely dependent on the ductus arteriosus. Retrograde pulmonary flow further reflects severe RV outflow obstruction and pulmonary hypoplasia [26].
- Pulmonary Regurgitation (PR): Continuous PR into the RV is characteristic of circular shunt physiology. It is also associated with adverse perinatal outcomes. PR severity and persistence are other prognostic markers [22].
- Ductus Arteriosus (DA) Flow Direction: Bidirectional or predominantly retrograde flow in the DA signifies excessive aorto-pulmonary steal phenomenon, which worsens right-sided compromise and contributes to the development of fetal hydrops. A restrictive DA, on the other hand, can exacerbate right ventricular pressure overload [27].
- Venous Dopplers: Abnormal flow patterns in the umbilical vein, ductus venosus, and inferior vena cava, such as reversal or absence of the a-wave (atrial contraction wave) and increased pulsatility, suggest elevated right atrial pressure, indicating right-sided heart failure and are strong predictors of poor outcomes [28].
- Umbilical Artery Doppler: Abnormal umbilical artery Doppler findings (absent or reversed end-diastolic flow) in EA may also suggest elevated systemic resistance and reduced placental reserve, reflecting advanced cardiac dysfunction [29].

Serial Doppler monitoring is crucial in fetal EA, as late-onset haemodynamic deterioration can occur even after normal early scans [26].

© 2026 by the author(s). Distributed under a Creative Commons CC BY license.

Preprints.org (www.preprints.org) | NOT PEER-REVIEWED | Posted: 15 June 2026 doi:10.20944/preprints202606.1179.v1

Associated Cardiac Anomalies

Common associated cardiac lesions include atrial septal defects (ASD), ventricular septal defects (VSDs), pulmonary stenosis or atresia, congenitally corrected transposition of the great arteries (ccTGA), and left ventricular non-compaction (LVNC). Associated hydrops fetalis indicates advanced heart failure [30].

Differential Diagnosis of Tricuspid Regurgitation on Fetal Echocardiography

Fetal tricuspid regurgitation (TR) can result from primary structural valve disease or secondary causes. Primary lesions include Ebstein anomaly (EA) and tricuspid valve dysplasia (TVD), characterised by thickened, poorly coapting leaflets without apical displacement; and the rare unguarded tricuspid orifice with partial or complete leaflet agenesis, causing a free to-and-fro flow jet that arises near the RV apex. Less common primary mechanisms include the parachute tricuspid valve and ruptured papillary muscle. Secondary TR reflects either RV pressure overload from pulmonary stenosis or ductal restriction, or global RV dysfunction and placental insufficiency [31,32].

Differentiation relies on measuring the annular offset, defining leaflet morphology, and the exact origin of the TR jet relative to the atrioventricular groove, as well as assessing RV size/function and pulmonary valve/ductal patency. Mild isolated TR, especially in early gestation, can be transient and benign, whereas moderate–severe TR or TR with outflow obstruction warrants detailed anatomic assessment [33].

Prognostic Factors and Scoring Systems

Poor prognosis in fetal EA is associated with earlier gestation at diagnosis, severe TR, RV dysfunction, the presence of a circular shunt, significant cardiomegaly, hydrops fetalis, pulmonary atresia or hypoplasia, fetal arrhythmias, and left ventricular dysfunction [2,34].

Several scoring systems have been developed to standardise risk assessment in fetal EA, combining multiple parameters to provide a comprehensive prognostic evaluation.

1. *Great Ormond Street Echocardiography (GOSE) score (Celemajer index):*

The GOSE score classifies disease severity into four grades based on the ratio of the combined atrial and ventricular areas (Table 1). A GOSE ratio ≥ 1.5 (grade 4) is associated with nearly 100% early mortality, whereas lower grades (1–3) correlate with improved survival outcomes [14,35]. However, the GOSE metric in fetal imaging is limited by variability in fetal position, acoustic window constraints, and the dynamic geometry of the heart; therefore, it should be integrated with Doppler flow indices and serial follow-up to guide prognosis and perinatal planning [18].

Table 1. Great Ormond Street Echocardiography (GOSE) score (Celermajer index).

GOSE score	Ratio (RA + aRV) / (RV + LV + LA)	Mortality
I	< 0.5	8%
II	0.5–1.0	8%
III (acyanotic)	1.1–1.4	Early mortality 10%; late mortality 45%[a]
III (cyanotic)	1.1–1.4	100%
IV	> 1.5	100%

[a] Early and late mortality as reported in the original description of the GOSE score. **Source:** Adapted from Celermajer DS et al. *Outcome in Neonates with Ebstein's Anomaly. J. Am. Coll. Cardiol.* 1992.

2. *The Simpson-Andrews-Sharland (SAS) score*

This score integrates five echocardiographic parameters: cardiothoracic ratio, Celermajer index, right-to-left ventricular (RV/LV) ratio, pulmonary valve flow, and ductus arteriosus flow. Each is graded from 0 to 2 according to severity (Table 2). The cardiothoracic ratio reflects cardiomegaly and

© 2026 by the author(s). Distributed under a Creative Commons CC BY license.

Preprints.org (www.preprints.org) | NOT PEER-REVIEWED | Posted: 15 June 2026 doi:10.20944/preprints202606.1179.v1

indirectly pulmonary hypoplasia; the Celermajer index and RV/LV ratio quantify right heart dilatation; and abnormal pulmonary or ductal flows signal advanced right heart failure and poor pulmonary perfusion. The total score ranges from 0 to 10, with higher values indicating a more severe disease. In the original study, a SAS score of ≥5 predicted 100% mortality, whereas scores of ≤3 were associated with approximately 91% survival. These cut-offs values are more predictive of advancing gestation, highlighting the progressive nature of the disease. Serial application of the SAS score during pregnancy may capture deterioration over time [36]. The SAS score is limited by dependency on optimal four-chamber visualisation and does not incorporate LV function, which may influence disease progression [18].

Table 2. Simpson-Andrews-Sharland (SAS) Score.

Variable	0 points	1 point	2 points
Cardiothoracic ratio	<0.65	0.65–0.75	>0.75
Celermajer index	<1.0	1.0–1.5	>1.5
Pulmonary valve flow	Normal	Reduced	Absent
Ductal flow direction	Antegrade	Bidirectional	Retrograde
Right-to-left ventricular ratio	<1.5	1.5–2.0	> 2.0

Source: Adapted from Andrews, R.E.; Tibby, S.M.; Sharland, G.K.; Simpson, J.M. Prediction of Outcome of Tricuspid Valve Malformations Diagnosed During Fetal Life. Am. J. Cardiol. 2008.

3. The Sick kids (SK) (Toronto)score

This score was developed at SickKids Hospital in Toronto as an adaptation of the SAS score, to more accurately reflect the significant haemodynamic alterations. It combines five distinct echocardiographic findings, with each variable assigned a value from 0 to 2, resulting in a total score ranging from 0 to 10. Table 3 illustrates these variables. In a multicentre validation study, the SK score demonstrated superior predictive accuracy for fetal and neonatal death compared to the SAS score. A score ≤3 was highly predictive of a good outcome, with no survivors reported for scores >8. Scores between 4 and 8 were associated with 63% mortality [2,37].

Table 3. SickKids (Toronto) score for fetal Ebstein anomaly.

Variable	0 points	1 point	2 points
Cardiothoracic ratio	< 0.65	0.65–0.75	> 0.75
Right atrial area index (RAAI)[a]	< 0.75	0.75–1.0	> 1.0
Pulmonary forward flow	Normal	Reduced	Absent
Tricuspid regurgitation severity and gradient[b]	No or mild	Moderate–severe with gradient > 40 mmHg	Moderate–severe with gradient < 40 mmHg
Pulmonary regurgitation and umbilical artery end-diastolic flow[c]	Absent	Present with antegrade UA flow	Present with absent or reversed UA flow

[a] Right atrial area index calculated as (right atrium + atrialised right ventricle) / (functional right ventricle + left atrium + left ventricle) at end-diastole. [b] Lower tricuspid regurgitation gradients reflect impaired right ventricular systolic pressure generation. [c] UA indicates umbilical artery; abnormal end-diastolic flow reflects advanced hemodynamic compromise. **Source:** Adapted from the SickKids

© 2026 by the author(s). Distributed under a Creative Commons CC BY license.

Preprints.org (www.preprints.org) | NOT PEER-REVIEWED | Posted: 15 June 2026 doi:10.20944/preprints202606.1179.v1

(Toronto) echocardiographic risk model for fetal Ebstein anomaly, with outcome data reported by Wertaschnigg et al. *Can. J. Cardiol.* 2016.

4. *TRIcuspid Malformation Prognosis Prediction (TRIPP) Score*

Torigoe et al. developed the TRIPP score as a Doppler-based model to predict perinatal mortality in fetal EA. It incorporates four fetal echocardiographic parameters that together capture essential biventricular haemodynamic (Table 4): tricuspid regurgitation (TR) peak velocity, myocardial performance (Tei) index, antegrade pulmonary artery (PA) flow, and ductal flow direction.

Low TR velocity (<2.5 m/s) indicates impaired right ventricular (RV) systolic pressure generation, while a high LV Tei index (>0.8) reflects reduced global LV performance due to ventricular–ventricular interaction and septal shift. Absent antegrade PA flow and retrograde ductal flow signal progressive RV dysfunction with reversal of the PA–aortic pressure gradient.

In the original cohort of 31 fetuses, a cumulative TRIPP score ≥5 was associated with an increased risk of perinatal death (sensitivity 87.5%, specificity 85%). As it relies solely on pulsed Doppler findings, the TRIPP score can be applied even when imaging is suboptimal, offering a reproducible assessment of haemodynamic compromise in fetal EA [18].

Table 4. TRIcuspid Malformation Prognosis Prediction (TRIPP) score.

Parameter	0 points	1 point	2 points	Physiologic interpretation
Tricuspid regurgitation (TR) peak velocity (m/s)	> 2.8	2.5–2.8	< 2.5	Reflects RV systolic pressure generation; low velocity indicates impaired RV contractile reserve
LV myocardial performance (Tei) index	< 0.6	0.6–0.8	> 0.8	Higher values indicate worsening global LV performance due to ventricular–ventricular interaction
Pulmonary artery (PA) flow	Normal	Reduced	Absent	Loss of antegrade RV output to the pulmonary circulation
Ductal flow direction	Antegrade	Bidirectional	Retrograde	Retrograde flow reflects aortic-to-PA shunting associated with advanced RV failure

Source: Torigoe et al. Fetal echocardiographic prediction score for perinatal mortality in tricuspid valve dysplasia and Ebstein's anomaly. Ultrasound Obstet Gynecol. 2020.

5-Cardiovascular profile score (CVPS)

This is a composite echocardiographic tool developed to assess fetal cardiovascular compromise, integrating five parameters: hydrops, cardiomegaly, ventricular function, arterial Doppler, and venous Doppler, as shown in Table 5, to yield a maximum score of 10 [18].In congenital heart disease (CHD) cohorts, a CVPS ≤7 correlates with adverse perinatal outcomes, supporting its use as a non-invasive marker of fetal heart failure [39]. Its application in fetal EA is not well established. Chen et al. reported that fetuses with EA had significantly lower median CVPS than controls, which was linked to worse ventricular function and higher cerebral vascular resistance. CVPS was not designed to account for the unique physiology of the Ebstein anomaly and may therefore have limited prognostic value when used alone; however, it remains helpful for serial assessment of overall cardiovascular status [40,41].

Antenatal scoring systems provide structured risk stratification to support parental counselling and delivery planning. Higher SAS or TRIPP scores identify high-risk fetuses who may benefit from delivery in tertiary cardiac centres with neonatal support. Serial assessment throughout gestation can detect clinical deterioration, such as worsening Doppler indices or the development of pulmonary regurgitation, allowing for timely management [42]. Table 6 summarises the principal prognostic scoring systems used for fetal Ebstein anomaly.

© 2026 by the author(s). Distributed under a Creative Commons CC BY license.

Preprints.org (www.preprints.org) | NOT PEER-REVIEWED | Posted: 15 June 2026 doi:10.20944/preprints202606.1179.v1

Table 5. Cardiovascular Profile Score (CVPS).

Category	2 points	1 point	0 points
Hydrops	Absent	Ascites or pleural or pericardial effusion	Skin edema
Heart size (CA/TA ratio)[a]	0.20–0.35	0.35–0.50	> 0.50 or < 0.20
Cardiac function[b]	Normal biphasic AV inflow; RV and LV shortening fraction > 0.28	Holosystolic TR or RV/LV shortening fraction < 0.28	Holosystolic MR or TR dP/dt < 400 mmHg/s, or monophasic AV inflow
Venous Doppler[c]	Non-pulsatile umbilical vein and normal ductus venosus	Non-pulsatile umbilical vein with absent or reversed a-wave in ductus venosus	Pulsatile umbilical vein
Arterial Doppler[d]	Forward end-diastolic flow in umbilical artery	Absent end-diastolic flow in umbilical artery	Reversed end-diastolic flow in umbilical artery

[a] CA/TA indicates cardiac area–to–thoracic area ratio. [b] AV indicates atrioventricular; RV, right ventricle; LV, left ventricle; TR, tricuspid regurgitation; MR, mitral regurgitation. [c] Abnormal venous Doppler patterns reflect elevated central venous pressure. [d] Progressive umbilical artery Doppler abnormalities reflect worsening systemic and placental resistance. **Source:** Adapted from Huhta, J.C. Fetal Congestive Heart Failure. Semin. Fetal Neonatal Med. 2005; and Wieczorek, A.P. et al. Prediction of Outcome of Fetal Congenital Heart Disease Using a Cardiovascular Profile Score. Ultrasound Obstet Gynecol. 2008.

Table 6 provides a comparative summary of all five prognostic scoring systems, their constituent parameters, outcome thresholds, and principal limitations.

Table 6. Comparison of prognostic scoring systems used in fetal Ebstein anomaly.

Scoring System	Primary Focus	Parameters checked	Advantages	Limitations
GOSE Score	Morphometric Severity (Right-sided enlargement and Atrialisation)	RA area, atrialised RV (aRV) area, functional RV area, LA area, LV area	Simple single-ratio measure quantifying anatomical severity of right-sided dilation and atrialisation	Anatomical assessment only; does not incorporate functional or haemodynamic parameters. Measurement reproducibility may be affected by fetal position and acoustic windows
(SAS) Score	Multi-parametric Risk (Anatomy and Flow)	Cardiothoracic ratio (CTR), Celermajer index, RV/LV ratio, pulmonary valve flow, ductus arteriosus flow	Integrates anatomical and haemodynamic variables; predictive cut-offs improve risk stratification with advancing gestation	Does not account for LV functional impact; dependent on adequate four-chamber visualisation
SK score	Haemodynamic compromise and circular shunt physiology	CTR, right atrial area index (RAAI), pulmonary forward flow, TR,	Incorporates key haemodynamic markers and circular-shunt physiology;	Derived from a single-centre retrospective cohort; dependent on Doppler quality and

© 2026 by the author(s). Distributed under a Creative Commons CC BY license.

Preprints.org (www.preprints.org) | NOT PEER-REVIEWED | Posted: 15 June 2026 doi:10.20944/preprints202606.1179.v1

		PR, end-diastolic umbilical artery flow	useful for clinical triage and counselling	imaging conditions; does not include quantitative LV function
(TRIPP) Score	Functional haemodynamic assessment (RV/LV performance and flow)	TR peak velocity, LV myocardial performance index, antegrade pulmonary artery flow, ductal flow direction	Focuses on Doppler parameters reflecting core haemodynamics, including LV function	Doppler measurements may vary with technique; low TR velocity may paradoxically indicate severe RV dysfunction
(CVPS)	Global hemodynamic status (fetal heart failure)	Hydrops, cardiomegaly, ventricular function, arterial Doppler, venous Doppler	Provides dynamic assessment of systemic haemodynamic compromise; useful as an adjunct in surveillance	Not specific to Ebstein anomaly; limited value as a stand-alone model and requires further validation

aRV, atrialised right ventricle; CTR, cardiothoracic ratio; CVPS, cardiovascular profile score; EA, Ebstein anomaly; GOSE, Great Ormond Street Echocardiography score; LA, left atrium; LV, left ventricle; PA, pulmonary artery; PR, pulmonary regurgitation; RA, right atrium; RAAI, right atrial area index; RV, right ventricle; SAS, Simpson–Andrews–Sharland score; TR, tricuspid regurgitation; TRIPP, TRIcuspid Malformation Prognosis Prediction score; UA, umbilical artery.

Proposed Comprehensive Framework for Fetal Assessment of EA

Prognostication in fetal Ebstein anomaly requires a structured, multiparametric approach that integrates anatomical severity, haemodynamic consequences, Doppler physiology, and ventricular function within a longitudinal framework.

Initial assessment should focus on anatomical characterisation, including the degree of tricuspid valve displacement, leaflet morphology, and the extent of right ventricular atrialisation, supported by indices such as the Celermajer index. However, anatomical severity alone is insufficient to predict outcome and must be interpreted in the context of haemodynamic impact.

Haemodynamic assessment should evaluate the severity of tricuspid regurgitation, right atrial enlargement, cardiomegaly, and the degree of left ventricular compression or dysfunction, reflecting ventricular interdependence. These features provide insight into the physiological burden of the disease.

Doppler interrogation is central to risk stratification, particularly the assessment of pulmonary valve flow, ductus arteriosus flow direction, pulmonary regurgitation, and venous Doppler patterns. These parameters reflect the integrity of the fetal circulation and identify critical states, such as functional pulmonary atresia and circular shunt physiology.

Functional assessment further refines prognostication by evaluating ventricular performance using parameters such as myocardial performance index, tricuspid regurgitation dP/dt, and, where feasible, advanced techniques including strain imaging. These markers provide early indicators of myocardial dysfunction that may precede overt clinical deterioration [43,44].

Established scoring systems, including GOSE, SAS, SK, TRIPP, and CVPS, should be interpreted as complementary tools rather than standalone predictors, each capturing different aspects of disease severity. The integration of these systems allows for a more comprehensive evaluation of structural, haemodynamic, and functional compromise.

Fetal EA is a progressive condition in which echocardiographic indices obtained early in pregnancy may not reliably predict the physiological status later in pregnancy. Therefore, serial echocardiographic evaluations are essential for monitoring disease progression and reassessing prognosis accordingly. Serial imaging, typically every 4–6 weeks and more frequently in late gestation, is essential and enables identification of temporal changes such as new regurgitation or

© 2026 by the author(s). Distributed under a Creative Commons CC BY license.

Preprints.org (www.preprints.org) | NOT PEER-REVIEWED | Posted: 15 June 2026 doi:10.20944/preprints202606.1179.v1

abnormal venous Doppler patterns, which are more predictive of decompensation than isolated measurements [2,29].

Standardisation of imaging protocols, including consistent acquisition planes, sweep speeds, and frame rates, is necessary to reduce interobserver variability. Further improvements could be achieved through centralised analysis of advanced echocardiographic data and the development of shared gestational reference standards, facilitating more reliable assessment and multicentre collaboration [45,46]. When echocardiographic windows are suboptimal, placental and venous Doppler parameters offer promising adjuncts for risk stratification.

This integrated, longitudinal framework enables more accurate risk stratification and supports clinical decision-making, including surveillance intensity, timing, location of delivery, and perinatal management planning.

Conclusions

Fetal echocardiography is central to the diagnosis and risk stratification of EA, allowing the evaluation of both anatomical abnormalities and haemodynamic effects. While existing scoring systems aid prenatal counselling, prognostic accuracy remains limited by disease heterogeneity, measurement variability, and incomplete assessment of LV function and longitudinal changes. Multiparametric and serial evaluation may better capture disease progression and support more individualised surveillance. Prospective multicentre studies are needed to validate comprehensive prognostic models and assess their impact on outcomes.

Funding: This research received no external funding.

Institutional Review Board Statement: This is a narrative review of published literature. No patient data were collected, and no ethical approval was required.

Informed Consent Statement: Not applicable.

Data Availability Statement: No new data were generated or analysed. All data are from previously published sources cited herein.

Acknowledgments: The authors used artificial intelligence-assisted tools for language editing, grammatical refinement, and clarity enhancement. All scientific content, clinical interpretation, and conclusions were independently developed and verified by the authors.

Conflicts of Interest: The authors declare no conflicts of interest.

Abbreviations

The following abbreviations are used in this manuscript:

2D-STE	Two-Dimensional Speckle-Tracking Echocardiography
ALP	Alkaline Phosphatase
ALT	Alanine Aminotransferase
ARDS	Acute Respiratory Distress Syndrome
ASD	Atrial Septal Defect
AST	Aspartate Aminotransferase
BMI	Body Mass Index
CAID	Cirrhosis-Associated Immune Dysfunction
ccTGA	Congenitally Corrected Transposition of the Great Arteries
CHD	Congenital Heart Disease
CKD	Chronic Kidney Disease

© 2026 by the author(s). Distributed under a Creative Commons CC BY license.

Preprints.org (www.preprints.org) | NOT PEER-REVIEWED | Posted: 15 June 2026 doi:10.20944/preprints202606.1179.v1

CTP	Child-Turcotte-Pugh
CVPS	Cardiovascular Profile Score
DA	Ductus Arteriosus
DM	Diabetes Mellitus
EA	Ebstein Anomaly
GGT	Gamma-Glutamyl Transferase
GI	Gastrointestinal
GOSE	Great Ormond Street Echocardiographic Score
HCC	Hepatocellular Carcinoma
ICU	Intensive Care Unit
INR	International Normalized Ratio
KASCH-R	King Abdullah Specialist Children's Hospital Riyadh Critical Care Registry
LV	Left Ventricle / Left Ventricular
LVNC	Left Ventricular Non-Compaction
MELD	Model for End-Stage Liver Disease
MPI	Myocardial Performance Index
PA	Pulmonary Artery
PR	Pulmonary Regurgitation
RA	Right Atrium / Right Atrial
RT-PCR	Reverse Transcription Polymerase Chain Reaction
RV	Right Ventricle / Right Ventricular
SARS-CoV-2	Severe Acute Respiratory Syndrome Coronavirus 2
SAS	Simpson-Andrews-Sharland Score
SD	Standard Deviation
SK	Sick Kids (Toronto) Score
SPSS	Statistical Package for the Social Sciences
TAPSE	Tricuspid Annular Plane Motion Excursion
TR	Tricuspid Regurgitation
TRIPP	TRIcuspid Malformation Prognosis Prediction Score
TV	Tricuspid Valve
TVD	Tricuspid Valve Dysplasia
VSD	Ventricular Septal Defect

References

1. Zimmer, E.Z.; Blazer, S.; Lorber, A.; Solt, I.; Egenburg, S.; Bronshtein, M. Fetal Ebstein's anomaly: early and late appearance. *Prenat. Diagn.* **2012**, *32*, 228–233.
2. Wertaschnigg, D.; Manlhiot, C.; Jaeggi, M.; et al. Contemporary outcomes and factors associated with mortality after a fetal or neonatal diagnosis of Ebstein anomaly and tricuspid valve disease. *Can. J. Cardiol.* **2016**, *32*, 1500–1506.
3. Singh, D.P.; Hussain, K.; Horenstein, M.S.; et al. Ebstein anomaly and malformation. In *StatPearls*; StatPearls Publishing: Treasure Island, FL, USA, **2025**.
4. Rydzewska, K.; Sylwestrzak, O.; Krekora, M.; Słodki, M.; Respondek-Liberska, M. Ebstein's anomaly: epidemiological analysis and presentation of different prenatal management. *J. Matern. Fetal Neonatal Med.* **2022**, *35*, 3297–3304.

© 2026 by the author(s). Distributed under a Creative Commons CC BY license.

Preprints.org (www.preprints.org) | NOT PEER-REVIEWED | Posted: 15 June 2026 doi:10.20944/preprints202606.1179.v1

5. Eckersley, L.G.; Howley, L.W.; van der Velde, M.E.; et al. Quantitative assessment of left ventricular dysfunction in fetal Ebstein's anomaly and tricuspid valve dysplasia. *J. Am. Soc. Echocardiogr.* **2019**, *32*, 1598–1607.
6. Ramcharan, T.K.W.; Goff, D.A.; Greenleaf, C.E.; et al. Ebstein's anomaly: from fetus to adult—literature review and pathway for patient care. *Pediatr. Cardiol.* **2022**, *43*, 1409–1428.
7. Walter, A.; Plöger, R.; Recker, F.; et al. Hemodynamic considerations for prenatal treatment of severe Ebstein anomaly with circular shunt based on two cases and review of the literature. *Arch. Gynecol. Obstet.* **2025**, *312*, 25–35.
8. Konstantinov, I.E.; Chai, P.; Bacha, E.; et al. The American Association for Thoracic Surgery (AATS) 2024 expert consensus document: management of neonates and infants with Ebstein anomaly. *J. Thorac. Cardiovasc. Surg.* **2024**, *168*, 311–324.
9. Root, M.C.; Fisher, K.L. Prenatal sonographic detection of Ebstein's anomaly. *J. Diagn. Med. Sonogr.* **2017**, *33*, 225–230.
10. Truong, U.T.; Hintz, S.R.; Tacy, T.A. Ebstein anomaly in the fetus: preparing for the perfect storm. *NeoReviews* **2011**, *12**, e260–e269.
11. Lussier, E.C.; Yeh, S.J.; Chih, W.L.; et al. Reference ranges and Z-scores for fetal cardiac measurements from two-dimensional echocardiography in an Asian population. *PLoS One* **2020**, *15*, e0233179.
12. Attenhofer Jost, C.H.; Connolly, H.M.; Edwards, W.D.; et al. Ebstein's anomaly: review of a multifaceted congenital cardiac condition. *Swiss Med. Wkly.* **2005**, *135*, 269–281.
13. Coacci, S.; Alston, E.L.J.; Yamasaki, T.; et al. The connection between anatomical substrate and clinical severity in fetal Ebstein anomaly. *Pediatr. Dev. Pathol.* **2024**, *27*, 587–591.
14. Celermajer, D.S.; Cullen, S.; Sullivan, I.D.; et al. Outcome in neonates with Ebstein's anomaly. *J. Am. Coll. Cardiol.* **1992**, *19*, 1041–1046.
15. Dib, N.; Vidales, L.; Benseba, J.; et al. Clinical and imaging predictors of poor prognosis in Ebstein anomaly. *CJC Pediatr. Congenit. Heart Dis.* **2025**, *4*, 203–212.
16. Mao, Y.K.; Lou, H.Y.; Pan, M.; Zhao, BW. Z-score reference ranges for the offset of the tricuspid septal leaflet in normal fetuses. *Fetal Diagn. Ther.* **2019**, *46*, 58–66.
17. Malhotra, A.; Agrawal, V.; Patel, K.; et al. Ebstein's anomaly: the one and a half ventricle heart. *Braz. J. Cardiovasc. Surg.* **2018**, *33*, 353–361.
18. Torigoe, F.; Ishida, H.; Ishii, Y.; et al. Fetal echocardiographic prediction score for perinatal mortality in tricuspid valve dysplasia and Ebstein's anomaly. *Ultrasound Obstet. Gynecol.* **2020**, *55*, 226–232.
19. Ikegawa, T.; Kim, K.S.; Kawataki, M.; et al. Late-gestation prediction of outcome in tricuspid valve dysplasia and Ebstein's anomaly using fetal tricuspid regurgitation waveform analysis. *Ultrasound Obstet. Gynecol.* **2023**, *61*, 593–600.
20. Friedman, D.; Buyon, J.; Kim, M.; Glickstein, J.S. Fetal cardiac function assessed by Doppler myocardial performance index (Tei index). *Ultrasound Obstet. Gynecol.* **2003**, *21*, 33–36.
21. Oliveira, M.; Dias, J.P.; Guedes-Martins, L. Fetal cardiac function: myocardial performance index. *Curr. Cardiol. Rev.* **2022**, *18*, e271221199505.
22. Freud, L.R.; Escobar-Diaz, M.C.; Kalish, B.T.; et al. Outcomes and predictors of perinatal mortality in fetuses with Ebstein anomaly or tricuspid valve dysplasia in the current era: a multicenter study. *Circulation* **2015**, *132*, 481–489.
23. Bligard, K.H.; Doering, M.; Porat, S.; Rosenbloom, J.I. Reference ranges for left modified myocardial performance index: systematic review and meta-analysis. *Fetal Diagn. Ther.* **2024**, *51*, 159–167.
24. van den Wildenberg, S.; van Beynum, I.M.; Havermans, M.E.C.; et al. Fetal speckle tracking echocardiography measured global longitudinal strain and strain rate in congenital heart disease: a systematic review and meta-analysis. *Prenat. Diagn.* **2024**, *44*, 1479–1497.
25. Messing, B.; Gilboa, Y.; Lipschuetz, M.; et al. Fetal tricuspid annular plane systolic excursion (f-TAPSE): evaluation of fetal right heart systolic function. *Ultrasound Obstet. Gynecol.* **2013**, *42*, 182–188.
26. Selamet Tierney, E.S.; McElhinney, D.B.; Freud, L.R.; et al. Assessment of progressive pathophysiology after early prenatal diagnosis of Ebstein anomaly or tricuspid valve dysplasia. *Am. J. Cardiol.* **2017**, *119*, 106–111.

© 2026 by the author(s). Distributed under a Creative Commons CC BY license.

Preprints.org (www.preprints.org) | NOT PEER-REVIEWED | Posted: 15 June 2026 doi:10.20944/preprints202606.1179.v1

27. Berning, R.A.; Silverman, N.H.; Villegas, M.; et al. Reversed shunting across the ductus arteriosus or atrial septum in utero heralds severe congenital heart disease. *J. Am. Coll. Cardiol.* **1996**, *27*, 481–486.
28. Davey, B.; Szwast, A.; Rychik, J. Diagnosis and management of heart failure in the fetus. *Minerva Pediatr.* **2012**, *64*, 471–492.
29. Wang, S.; Freud, L.R.; Detterich, J.; et al. Extracardiac Doppler indices predict perinatal mortality in fetuses with Ebstein anomaly and tricuspid valve dysplasia. *Prenat. Diagn.* **2021**, *41*, 332–340.
30. Attenhofer Jost, C.H.; Connolly, H.M.; Dearani, J.A.; et al. Ebstein's anomaly. *Circulation* **2007**, *115*, 277–285.
31. Hornberger, L.K.; Sahn, D.J.; Kleinman, C.S.; et al. Tricuspid valve disease with significant tricuspid insufficiency in the fetus: diagnosis and outcome. *J. Am. Coll. Cardiol.* **1991**, *17*, 167–173.
32. Ammash, N.M.; Warnes, C.A.; Connolly, H.M.; et al. Mimics of Ebstein's anomaly. *Am. Heart J.* **1997**, *134*, 508–513.
33. Barre, E.; Durand, I.; Hazelzet, T.; David, N. Ebstein's anomaly and tricuspid valve dysplasia: prognosis after diagnosis in utero. *Pediatr. Cardiol.* **2012**, *33*, 1391–1396.
34. Bravo-Valenzuela, N.J.; Rizzo, G.; Mappa, I.; et al. Prenatal cardiac ultrasound markers of outcomes in Ebstein's anomaly. *Pediatr. Cardiol.* **2025**, *46*, 1171–1179.
35. Celermajer, D.S.; Bull, C.; Till, J.A.; et al. Ebstein's anomaly: presentation and outcome from fetus to adult. *J. Am. Coll. Cardiol.* **1994**, *23*, 170–176.
36. Andrews, R.E.; Tibby, S.M.; Sharland, G.K.; Simpson, J.M. Prediction of outcome of tricuspid valve malformations diagnosed during fetal life. *Am. J. Cardiol.* **2008**, *101*, 1046–1050.
37. Deng, M.X.; Kirsch, R.; Jaeggi, E.; Honjo, O. Management of a premature low birth weight neonate with Ebstein anomaly and persistent circular shunt. *JTCVS Tech.* **2021**, *7*, 208–211.
38. Huhta, J.C. Fetal congestive heart failure. *Semin. Fetal Neonatal Med.* **2005**, *10*, 542–552.
39. Wieczorek, A.; Hernandez-Robles, J.; Ewing, L.; et al. Prediction of outcome of fetal congenital heart disease using a cardiovascular profile score. *Ultrasound Obstet. Gynecol.* **2008**, *31*, 284–288.
40. Chen, Y.; Lv, G.; Li, B.; Wang, Z. Cerebral vascular resistance and left ventricular myocardial performance in fetuses with Ebstein's anomaly. *Am. J. Perinatol.* **2009**, *26*, 253–258.
41. Kühle, H.; Cho, S.K.S.; Barber, N.; et al. Advanced imaging of fetal cardiac function. *Front. Cardiovasc. Med.* **2023**, *10*, 1206138.
42. Sainathan, S.; da Fonseca da Silva, L.; da Silva, J.P. Ebstein's anomaly: contemporary management strategies. *J. Thorac. Dis.* **2020**, *12**, 1161–1173.
43. Freud, L.R.; McElhinney, D.B.; Kalish, B.T.; et al. Risk factors for mortality and circulatory outcome among neonates prenatally diagnosed with Ebstein anomaly or tricuspid valve dysplasia. *J. Am. Heart Assoc.* **2020**, *9*, e016684.
44. Barber, N.; Freud, L. Advances in fetal cardiac imaging and intervention. *CJC Pediatr. Congenit. Heart Dis.* **2023**, *3*, 33–42.
45. Moon-Grady, A.J.; Donofrio, M.T.; Gelehrter, S.; et al. Guidelines and recommendations for performance of the fetal echocardiogram. *J. Am. Soc. Echocardiogr.* **2023**, *36*, 679–723.
46. Patel, S.R.; Michelfelder, E. Prenatal diagnosis of congenital heart disease: the crucial role of perinatal and delivery planning. *J. Cardiovasc. Dev. Dis.* **2024**, *11*, 108.

Disclaimer/Publisher's Note: The statements, opinions and data contained in all publications are solely those of the individual author(s) and contributor(s) and not of MDPI and/or the editor(s). MDPI and/or the editor(s) disclaim responsibility for any injury to people or property resulting from any ideas, methods, instructions or products referred to in the content.

© 2026 by the author(s). Distributed under a Creative Commons CC BY license.