

Brief Report

Not peer-reviewed version

---

# Classic Method for Pathologically Liver Analyse

---

[Antonella Chesca](#)\*

Posted Date: 20 June 2025

doi: 10.20944/preprints202312.0919.v8

Keywords: liver; samples; methodology; diagnosis



Preprints.org is a free multidisciplinary platform providing preprint service that is dedicated to making early versions of research outputs permanently available and citable. Preprints posted at Preprints.org appear in Web of Science, Crossref, Google Scholar, Scilit, Europe PMC.

Copyright: This open access article is published under a Creative Commons CC BY 4.0 license, which permit the free download, distribution, and reuse, provided that the author and preprint are cited in any reuse.

## Brief Report

# Classic Method for Pathologically Liver Analyse

Antonella Chesca

Transilvania University of Brasov, Romania; anto.chesca@gmail.com

## Abstract

The purpose of this article is to identify the results of structural analyze from liver samples. In the study were used both normaly and pathologically liver samples. Also good to mention that in this study were used liver samples, collected during necropsy, from healthy patients and from patients diagnosed with cirrhosis. This previously mentioned, are known as routinely found methods, in medical practice, used for hepatitis C diagnosis, which conduct to hepatic cirrhosis. Following steps from the classic structural study, it is possible to analyse normal and alterate liver structure, on the colored preparates with classic specific stainings.

**Keywords:** liver; samples; methodology; diagnosis

## Introduction

Actually, HCV infection could be consider as one of bad results after percutaneous blood administration to ill patients. So, good to mention that HCV infection it is known as one of the most commonly through injection drug use. [1] The first and most important step in the care cascade is testing for HCV. Actually, is an enlarge number of expansion of populations eligible for testing for HCV prevention. [1–3]

It is know about care cascade, including multiple key points in diagnosis HCV infection. An HCV care cascade is consider as a model for identifying opportunities and barriers in order to improve laboratory tests, linkage to care, and proper treatment access. [4,5]

Relatively recently, there have been increases in HCV detection among women of childbearing age. [6,7] Reinfection with HCV after curative therapy in illness status in different patients, is an important key point for medical team. [8–10] The proper laboratory techniques include immunoglobulin (Ig) G antibody enzyme immunoassays (anti-HCV) and nucleic acid tests (NAT), as modern methods, in conection with blood tests. [11] In case that need to distinguish between two directions such as true or false positivity of the anti-HCV antibody result, previously mentined tests, may be done with a second FDA-approved HCV antibody assay that is different from previously used for testing [11,12]

Morphologically, HCV is an enveloped, positive-sense, single-stranded RNA virus of the Flaviviridae family. [13–15]

The great key point knowing as a start of the direct-acting antiviral (DAA) era was in 2011. The important role in this direction was the introduction of two NS3/4A protease inhibitors. Both previously mentioned were used in combination with interferon-based regimens for chronic HCV treatment to ill patients diagnosed. [16] Results of studies show that the HCV replication process is error prone. Finally results practically could be observe in variant viruses knowing as quasispecies. [17,18]

Nowadays there are 7 genotypes of HCV. So there are known 6 major genotypes and the recent addition of genotype 7. This last 7 genotip has been found only in a few cases diagnosed to HCV positive patients. [19] Hepatitis C virus (HCV) infection is a great cause of various liver diseases as cirrhosis and hepatocellular carcinoma. Following promising news, significant scientific discovering things remain in attention for reducing morbidity and mortality, associated to HCV. [20,21] Understanding the properties of hepatitis C virus (HCV) viral RNA and proteins facilitates

the development of diagnosis methods and also a proper treatment, including antivirals.[22–24] In addition we can mention that HCV genotyping assays approved for *in vitro* diagnostic use are commercially available[25,26] Cirrhosis, as a nowadays disease, is characterized by fibrosis and nodule formation of the liver. In the secondary plan, it is known as a chronic injury, which leads to alteration of the normal lobular organization of the liver. A complex of factors, such as life style, or environmentals, can injure the liver, and beside also including viral infections, toxins.

With each injury, the liver suffer alterations as fibrosis. Finally but after a long-standing injury, liver functionalalteration, develop in time cirrhosis as a complex diseases. Ethiology of the chronic liver diseases usually progress unfortunately in cirrhosis, following pathological mechanisms.[27] Scientific knowledges referring to the severity of liver cirrhosis, as a disease with a bad prognostic on the public health, is still not well characterized. [28] Liver diseases are without doubts, the most common in the world. [29] Researchers must be carefully to ideea refering to demonstration that drug injury is present in liver structure injury that conduct to pathology. [30]

Material and Methods

In order to assist medical staff in understanding the concerns outlined, a series of digital images have been prepared. The operative pieces are intended to bring in the pathological anatomy service for macroscopic examination for diagnostic purposes. This are examined by performing the optical microscopic analysis. Using an optical microscope, could be possible liver structure analyze. We can observe hepatocytes and interlobular spaces and septa.On a normal liver structure but using another specific stain known as *Argentinc impregnation Gomori*.

The functional unit of the liver is the lobule with hexagonal form. Kienann space is specific for liver strucutre, including a portal triad (portal vein, hepatic artery, bile duct) sits at each corner of the hexagon. Mitochondri as points observing with lens x40, using Goldner Szekely stain.

In liver cirrhosis, on samples could be observe tissue fibrosis and alterations in the normal liver architecture in abnormal structural nodules.

A similar coming image with specific structural changes in liver structure and with vascularized fibrotic septa in cirrhosis More than, we can mention in this disease, about portal hypertension. Prevention and treatment of liver cirrhosis are best done by an interdisciplinary medical team.

Animal models play a significant role in liver pathology diagnosis for example in rats with cirrhosis. Cirrhosis, as a nowadays disease, is characterized by fibrosis and neoformation noduls in the liver architecture. In addition, cirrhosis it is known as a chronic injury, which leads to alteration of the normal lobular organization of the liver. [29–31] A complex of factors, such as life style, or environmental factors, can affect the liver, for better or for worse. [32,33] In addition to optimal management of cirrhosis complications per the recent EASL guidelines, patients with advanced liver disease also require support and management for substance/alcohol abuse, nutrition and frailty. [34,35]

Cirrhosis Ethiology

Table I. Ethiology in cirrhosis.

Viral	Toxins	Vascular	Metabolic	Cholestatic	Autoimmune
hepatitis B, C, and D	alcohol, drugs	Budd-Chiari syndrome, sinusoidal obstruction syndrome, cardiac cirrhosis	hemochromatosis, NASH, Wilson disease, alpha-1 antitrypsin deficiency	primary biliary cholangitis, primary sclerosing cholangitis	autoimmune hepatitis

#### 4. Complications in Cirrhosis

Hepatic encephalopathy (HE) is an important major neuropsychiatric disorder in liver cirrhosis. There are known two types. So minimal hepatic encephalopathy (MHE), known as a cognitive deficit found in the earlier past time using specific psychological tests and Grade I HE. More than, also it is known about overt hepatic encephalopathy (OHE), with specific clinical symptoms.[36,37]

Ascites is known as a common complication in hepatic cirrhosis. Ascites is accompanied with portal hypertension. This previously mentioned complication in cirrhosis, it is known as a specific one, defined as an accumulation of a fluid quantity in the peritoneal cavity.[38]

Ascites infection is a possible accompanying event for ill persons diagnosed with cirrhosis. Infection in ascitis is often known as a bacterial peritonitis (SBP) sometimes with accompanying fungal infections.[39,40]

Variceal bleeding represent a relatively common accompanied complication to patients diagnosed with cirrhosis. [41] In liver damage as cirrhosis, esophageal and gastric variceal bleeding together with rectal variceal bleeding.[42]

Hepatorenal syndrome and kidney injury represent a common complication to patients diagnosed with hepatic cirrhosis. [43]

Infections are also relatively common in hepatic cirrhosis. In different parts of the body could be found after signs and symptoms, infections as tissue infections, bacteremia, pneumonia, urinary tract infections. [44,45] From years ago, till nowadays, infections caused by multidrug-resistant organisms (MDRO) play a significant role in liver damages such as those from hepatic cirrhosis.[46]

#### 5. Cellular and Molecular Key Points

Following embryogenesis stages, hepatic cells starting with progenitor cells namely hepatoblasts, during differentiation, become finally hepatocytes.

In the cellular and molecular mechanisms, signals play a great importance. So, hematopoietic cells, manage the hepatoblast proliferation process. In this direction, E-cadherin-mediated cell junction in hepatoblasts evolutionary mechanism. Also are known other contributors in finally hepatocytes evolution. It is useful to mention that the gradient of TGF- $\beta$  secreted from the portal vein mesenchyme play also a great role in previously mentioned direction with finally hepatocytes. Cellular and molecular mechanism referring to mechanistically, show a higher TGF- $\beta$  signaling in portal vein in hepatic cells that drives cholangiocyte physiologically direction. Research studies, show the decreasing expression of CCAAT/enhancer binding protein (C/EBP)  $\alpha$  and which promoting expression of Hnf6 (aka Oc1) and Hnf1 $\beta$ . More that, also results of studies, show the transcription profile. In this direction it is good to mention a bit about cholangiocyte-specific gene transcription process. More exactly, by HNF6 and HNF1 $\beta$ , are implications in suppressing hepatocyte genes by decreasing C/EBP $\alpha$  levels.[47]

In the developmentally mechanism, the hepatocytes, and the cholangiocytes, emerge from the specific region in the definitive endoderm. In the initiation signals referring to hepatic cells, include fibroblast growth factor (FGF), and also bone morphogenic proteins (BMPs). [47]

Studies also show as that non-alcoholic fatty liver disease (NAFLD) is a key point in liver diseases. In this direction, we can mention that the pathologically mechanisms, follow steps starting with steatosis having finally to cirrhosis. Also good to mention that liver enzymes play also a role. In this mechanism, it is known about ALT:AST ratio. [48,49]

Nowadays, the Model for End Stage Liver Disease (MELD Score) and the MELD-Na are important in liver illness prediction.[50,51]

Good to mention idea that the liver is a metabolic organ. Specific activity in the liver is metabolic activity with implications in normal endocrinological function of the body.[52]

More than we can mention a little bit about the importance of the level of glucose in the blood. This is important to know and to control for body protection and for avoiding from non normal deviations.

Key Points in Cirrhosis for Differential Diagnosis

Table II. Causes for differential diagnosis in cirrhosis (a,b,c,d).

Table II a

Acute fatty liver of pregnancy	Neonatal iron storage diseases	Galactosemia
--------------------------------	--------------------------------	--------------

Table II b

HELLP syndrome of pregnancy ( hemolysis, elevated liver enzymes, low platelets)	Bacillus cereus toxin	Acetaminophen poisoning
---	-----------------------	-------------------------

Table II c

Fructose intolerance	Tyrosinemia	Amanita phalloides mushroom poisoning
----------------------	-------------	---------------------------------------

Table II d

Hemorrhage viruses (Ebola virus)	Hemorrhage viruses (Lassa virus)	Hemorrhage viruses ( Marburg virus)
----------------------------------	----------------------------------	-------------------------------------

Idiopathic drug reaction is one of the great key point in cirrhosis, for differential diagnosis. Nowadays, the exactly prevalence of cirrhosis in the world, is without doubts still unknown.[54]

**Discussions:** Patient lifestyle changes, unfortunately cannot cure cirrhosis. Complications accompanying hepatic cirrhosis include,portal hypertension, edema in the abdomen and lower extremities, splenomegaly, infections, hepatic encephalopathy.

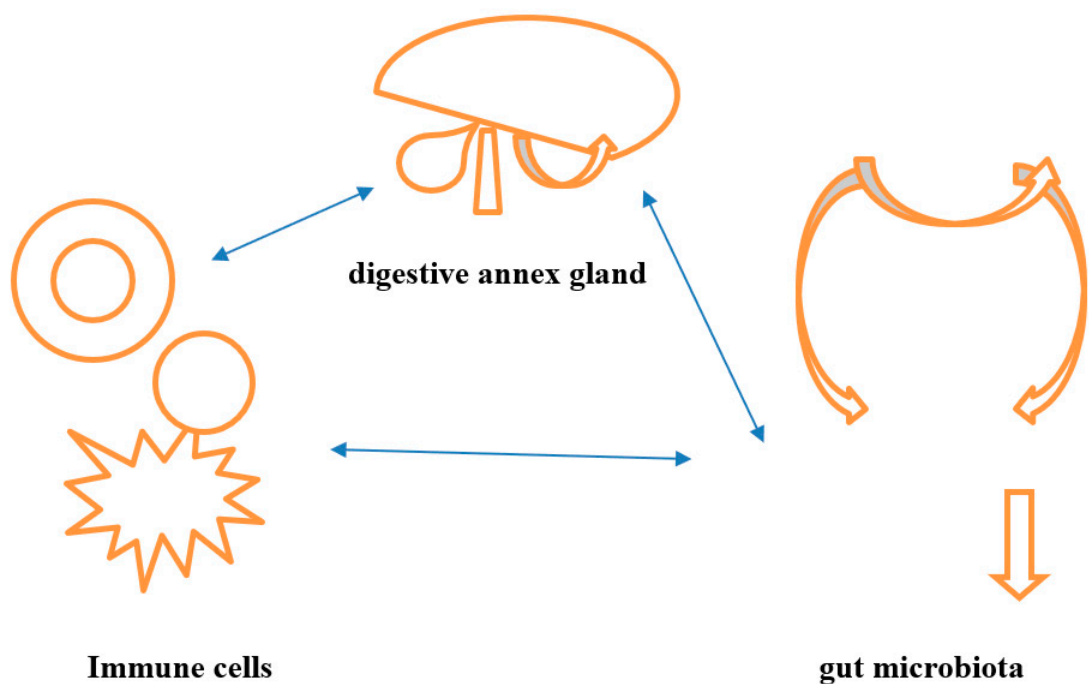
Behavioral modifications can prevent or at least delay disease progression and provide symptomatic relief.

Lifestyle changes, include factors, as eliminating ethanol consumption and dietary interventions as possible low-sodium diet, in order to reduce water retention. Regulate protein intake according to their doctor's directions and some medical recommandations, will be proper in the treatment of cirrhosis.

Cirrhosis secondary to HBV and HCV is one of the common risk factor for liver degeneration in cirrhosis.. Practically monitoring of cirrhotic patients is recommended, with at least six monthly screenings. Liver biopsy is the gold standard technique highly promising non-invasive methodology under development, that are used in diagnosis. Liver transplantation (LT) is also an effective therapeutic option for the management of cirrhosis end-stage. Relatively recently research investigations try to elucidate the signal transduction pathways that link hepatocytes alterations including cellular dysfunctionality. [Figure 1]

As mentioned in studies, the digestive annex gland is capable to store, synthesize, metabolize, and release glucose. There are more important functions for a proper life of each person. In this study direction, we can mention, that the liver is an important organ for digestive absorption and also for performs uptake, synthesis, and not only for secretion of biochemical compounds such us lipids and lipoproteins. Good to mention that the cholesterol can be absorbed from the intestine or could possible to be synthesized *de novo* in the liver.





**Figure 1.** Interaction each – other under phisiologically conditions.

**Conclusions**

Research studies predict about not so a good prognosis of patients diagnosed with cirrhosis, knowing laboratory results and clinical points. Nowadays diagnostic methods including a proper control of liver functions conduct to a proper diagnostic. In idea that hepatic cirrhosis is hard or impossible to cure, we are waiting from future research dirrections and plans.

**References**

1. AASLD-IDSA. HCV Guidance: Recommendations for Testing, Managing, and Treating Hepatitis C 2016. Available from: [http://hcvguidelines.org/sites/default/files/HCV-Guidance\\_October\\_2016\\_a.pdf](http://hcvguidelines.org/sites/default/files/HCV-Guidance_October_2016_a.pdf). Guidance produced by the American Association for the Study of Liver Disease and the Infectious Disease Society of America (AASLD-IDSA) covering recommendations for hepatitis C testing, clinical management and treatment.
2. Recommendations for prevention and control of hepatitis C virus (HCV) infection and HCV-related chronic disease. Centers for Disease Control and Prevention. *MMWR Recomm Rep*. 1998;47(Rr-19):1–39. Recommendations from the Centers for the Disease Control and Prevention definng populations for risk-based testing of hepatitis C.
3. Moyer VA. Screening for hepatitis C virus infection in adults: U.S. Preventive Services Task Force recommendation statement. *Ann Intern Med*. 2013;159(5):349–57. Hepatitis C testing recommendations for adults from the United States Preventive Services Task Force including risk-based testing and testing for adults born from 1945–1965.
4. Holmberg SD, Spradling PR, Moorman AC, Denniston MM. Hepatitis C in the United States. *N Engl J Med*. 2013;368(20):1859–61. Description of a care cascade integrating data from the Chronic Hepatitis Cohort Study and the National Health and Nutrition Examination Survey.
5. Viner K, Kuncio D, Newbern EC, Johnson CC. The continuum of hepatitis C testing and care. *Hepatology*. 2015;61(3):783–9. Description of an HCV continuum of care in a US urban center highlighting important areas where patients become lost at each stage.
6. Koneru A, Nelson N, Hariri S, Canary L, Sanders KJ, Maxwell JF, et al. Increased Hepatitis C Virus (HCV) Detection in Women of Childbearing Age and Potential Risk for Vertical Transmission - United States and

- Kentucky, 2011–2014. *MMWR Morb Mortal Wkly Rep.* 2016;65(28):705–10. Analysis finding that the proportion of infants born to HCV-infected mothers increased 68% nationally and 124% in Kentucky.
7. Kuncio DE, Newbern EC, Johnson CC, Viner KM. Failure to Test and Identify Perinatally Infected Children Born to Hepatitis C Virus-Infected Women. *Clin Infect Dis.* 2016;62(8):980–5. Analysis of surveillance data from the Philadelphia Department of Public Health finding a significant number of women giving birth in Philadelphia tested positive for HCV but that most of their children were not tested for HCV.
  8. Lambers FA, Prins M, Thomas X, Molenkamp R, Kwa D, Brinkman K, et al. Alarming incidence of hepatitis C virus re-infection after treatment of sexually acquired acute hepatitis C virus infection in HIV-infected MSM. *AIDS.* 2011;25(17):F21–7.
  9. Martin TC, Martin NK, Hickman M, Vickerman P, Page EE, Everett R, et al. Hepatitis C virus reinfection incidence and treatment outcome among HIV-positive MSM. *AIDS (London, England)* 2013;27(16):2551–7.
  10. Ingiliz P, Martin TC, Rodger A, Stellbrink HJ, Mauss S, Boesecke C, et al. HCV reinfection incidence and spontaneous clearance rates in HIV-positive men who have sex with men in Western Europe. *J Hepatol.* 2016.
  11. Testing for HCV infection: an update of guidance for clinicians and laboratorians. *MMWR Morb Mortal Wkly Rep.* 2013;62(18):362–5. Updated guidance for clinicians and laboratorians from the Centers for Disease Control and Prevention on diagnostic testing procedures for hepatitis C.
  12. Moyer VA. Screening for hepatitis C virus infection in adults: U.S. Preventive Services Task Force recommendation statement. *Ann Intern Med.* 2013;159(5):349–57. Hepatitis C testing recommendations for adults from the United States Preventive Services Task Force including risk-based testing and testing for adults born from 1945–1965.
  13. Thomas DL, Seeff LB. Natural history of hepatitis C. *Clin Liver Dis.* 2005;9(3):383–98. vi.
  14. Mack CL, Gonzalez-Peralta RP, Gupta N, Leung D, Narkewicz MR, Roberts EA, et al. NASPGHAN practice guidelines: Diagnosis and management of hepatitis C infection in infants, children, and adolescents. *J Pediatr Gastroenterol Nutr.* 2012;54(6):838–55.
  15. Thein HH, Yi Q, Dore GJ, Krahn MD. Estimation of stage-specific fibrosis progression rates in chronic hepatitis C virus infection: a meta-analysis and meta-regression. *Hepatology.* 2008;48(2):418–31.
  16. Conteduca V, Sansonno D, Russi S, Pavone F, Dammacco F. Therapy of chronic hepatitis C virus infection in the era of direct-acting and host-targeting antiviral agents. *J Infect.* 2014;68(1):1–20.
  17. Gomez J, Martell M, Quer J, Cabot B, Esteban JI. Hepatitis C viral quasispecies. *J Viral Hepat.* 1999;6(1):3–16.
  18. Duffy S, Shackelton LA, Holmes EC. Rates of evolutionary change in viruses: patterns and determinants. *Nat Rev Genet.* 2008;9(4):267–76.
  19. Bukh J. The history of hepatitis C virus (HCV): Basic research reveals unique features in phylogeny, evolution and the viral life cycle with new perspectives for epidemic control. *J Hepatol.* 2016;65(1 Suppl):S2–s21.
  20. Ly KN, Hughes EM, Jiles RB, Holmberg SD. Rising Mortality Associated With Hepatitis C Virus in the United States, 2003–2013. *Clin Infect Dis.* 2016;62(10):1287–8. Describes rising HCV-associated mortality in the United States from 2003–2013. During that time period, HCV-associated deaths surpassed 60 other nationally notifiable infectious conditions combined.
  21. Allison RD, Tong X, Moorman AC, Ly KN, Rupp L, Xu F, et al. Increased incidence of cancer and cancer-related mortality among persons with chronic hepatitis C infection, 2006–2010. *J Hepatol.* 2015;63(4):822–8. Analysis of a cohort of HCV-infected persons that found the the incidence of liver cancer and many types of non-liver cancers were higher, and age at diagnosis and death younger, in patients with chronic HCV infection compared to the general population.
  22. Alberti A, Chemello L, Benvegnù L. Natural history of hepatitis C. *J Hepatol.* 1999;31 Suppl 1:17–24.
  23. Hoofnagle JH. Course and outcome of hepatitis C. *Hepatology.* 2002;36:S21–S29.
  24. Chen SL, Morgan TR. The natural history of hepatitis C virus (HCV) infection. *Int J Med Sci.* 2006;3:47–52.
  25. Chevaliez S, Pawlotsky JM. Virology of hepatitis C virus infection. *Best Pract Res Clin Gastroenterol.* 2012;26:381–389.

26. Saludes V, González V, Planas R, Matas L, Ausina V, Martró E. Tools for the diagnosis of hepatitis C virus infection and hepatic fibrosis staging. *World J Gastroenterol*. 2014;20:3431–3442.
27. Naveau S, Perlemuter G, Balian A. [Epidemiology and natural history of cirrhosis]. *Rev Prat*. 2005 Sep 30;55(14):1527-32.
28. Kleinbloesem CH, van Harten J, Wilson JP, Danhof M, van Brummelen P, Breimer DD. Nifedipine: kinetics and hemodynamic effects in patients with liver cirrhosis after intravenous and oral administration. *Clin Pharmacol Ther*. 1986;40:21–8.
29. Bircher J, Benhamou JP, McIntyre N, Rizzetto M, Rodes J, editors. *Oxford Textbook of Clinical Hepatology*. 2nd Edition Oxford University Press; 1999.
30. Sherlock S, Dooley J, editors. *Diseases of the Liver and Biliary System*. 11th Edition Blackwell Science; Oxford, UK; Malden, MA: 2002.
31. Schiff ER, Sorrell MF, Maddrey EC, editors. *Schiff's Diseases of the Liver*. 9th Edition Lippincott, Williams & Wilkins; Philadelphia: 2003.
32. Desmet VJ, Roskams T. Cirrhosis reversal: a duel between dogma and myth. *J Hepatol*. 2004;40:860–7.
33. European Association for the Study of the Liver EASL Clinical Practice Guidelines for the management of patients with decompensated cirrhosis. *Hepatol*. 2018; 69: 406-460.
34. Wanless IR, Nakashima E, Sherman M. Regression of human cirrhosis. Morphologic features and the genesis of incomplete septal cirrhosis. *Arch Pathol Lab Med*. 2000;124:1599–607.
35. Macdonald S., Jepsen P., Alrubaiy L., Watson H., Vilstrup H., Jalan R., Quality of life measures predict mortality in patients with cirrhosis and severe ascites. *Aliment Pharmacol Ther*. 2019; 49: 321-330.
36. Häussinger D, Dhiman RK, Felipe V, Görg B, Jalan R, Kircheis G, Merli M, Montagnese S, Romero-Gomez M, Schnitzler A, Taylor-Robinson SD, Vilstrup H. Hepatic encephalopathy. *Nat Rev Dis Primers*. 2022;8:43.
37. Ridola L, Faccioli J, Nardelli S, Gioia S, Riggio O. Hepatic Encephalopathy: Diagnosis and Management. *J Transl Int Med*. 2020;8:210–219.
38. European Association for the Study of the Liver. EASL clinical practice guidelines on the management of ascites, spontaneous bacterial peritonitis, and hepatorenal syndrome in cirrhosis. *J Hepatol*. 2010;53:397–417.
39. Gravito-Soares M, Gravito-Soares E, Lopes S, Ribeiro G, Figueiredo P. Spontaneous fungal peritonitis: a rare but severe complication of liver cirrhosis. *Eur J Gastroenterol Hepatol*. 2017;29:1010–1016.
40. Fiore M, Chiodini P, Pota V, Sansone P, Passavanti MB, Leone S, Aurilio C, Pace MC. Risk of spontaneous fungal peritonitis in hospitalized cirrhotic patients with ascites: a systematic review of observational studies and meta-analysis. *Minerva Anesthesiol*. 2017;83:1309–1316.
41. Alqahtani SA, Jang S. Pathophysiology and Management of Variceal Bleeding. *Drugs*. 2021;81:647–667. Baiges
42. A, Hernández-Gea V. Management of Liver Decompensation in Advanced Chronic Liver Disease: Ascites, Hyponatremia, and Gastroesophageal Variceal Bleeding. *Clin Drug Investig*. 2022;42:25–31.
43. Molleston JP, Bennett WE Jr. Mortality, Risk Factors and Disparities Associated with Esophageal Variceal Bleeding in Children's Hospitals in the US. *J Pediatr*. 2021;232:176–182.
44. Van der Merwe S, Chokshi S, Bernsmeier C, Albillos A. The multifactorial mechanisms of bacterial infection in decompensated cirrhosis. *J Hepatol*. 2021;75 Suppl 1:S82–S100.
45. Choudry N, Sasso R, Rockey DC. Infection in Hospitalized Cirrhosis Patients: Changing Epidemiology and Clinical Features. *Am J Med Sci*. 2022;363:114–121.
46. Fernández J, Piano S, Bartoletti M, Wey EQ. Management of bacterial and fungal infections in cirrhosis: The MDRO challenge. *J Hepatol*. 2021;75 Suppl 1:S101–S117.
47. Trefts Elijah, GannonMaureen, Wasserman David H., The liver, *Published in final edited form as: Curr Biol*. 2017 Nov 6;27(21):R1147–R1151.
48. Su W, Mao Z, Liu Y, Zhang X, Zhang W, Gustafsson JA, Guan Y. Role of HSD17B13 in the liver physiology and pathophysiology. *Mol Cell Endocrinol*. 2019 Jun 01;489:119-125.
49. Adams LA, Angulo P, Lindor KD. Nonalcoholic fatty liver disease. *CMAJ*. 2005 Mar 29;172(7):899-905.



50. Malinchoc M., Kamath P.S., Gordon F.D., Peine C.J., Rank J., ter Borg P.C. A model to predict poor survival in patients undergoing transjugular intrahepatic portosystemic shunts. *Hepatology*. 2000;31:864–871.
51. Godfrey E.L., Kueht M.L., Rana A., Awad S. MELD-Na (the new MELD) and peri-operative outcomes in emergency surgery. *Am J Surg*. 2018;216:407–413.
52. Rui Liangyou, Energy Metabolism in the Liver, *Published in final edited form as: Compr Physiol*. 2014 Jan;4(1):177–197.
53. Wasserman H David, Four grams of glucose, *Am J Physiol Endocrinol Metab.*, . 2008 Oct 7;296(1):E11–E2.
54. Digestive diseases in the United States: Epidemiology and Impact. NIDDK; Bethesda, MD: 1994. NIH Publication No. 94-1447.

**Disclaimer/Publisher’s Note:** The statements, opinions and data contained in all publications are solely those of the individual author(s) and contributor(s) and not of MDPI and/or the editor(s). MDPI and/or the editor(s) disclaim responsibility for any injury to people or property resulting from any ideas, methods, instructions or products referred to in the content.