

Review

Platelet-Rich Fibrin Membrane for Pterygium Surgery: A Case Report, Literature Review and feasibility assessment

Carolina Camacho ^{1,*} and Jose E. Leon-Rojas ^{2,*}

¹ Universidad San Francisco de Quito, Quito, Ecuador; caro1933@msn.com

² Research Department, Medical School, Faculty of Health and Life Sciences, Universidad Internacional del Ecuador, Quito, Ecuador; joleonro@uide.edu.ec

* Correspondence: C.C. caro1933@msn.com; J.L-R: joleonro@uide.edu.ec

Abstract: Pterygium is a common ocular disease caused by abnormal cellular proliferation leading to abnormal fibrovascular growth of the conjunctiva. The main treatment is surgical removal; however, despite the improvement of surgical techniques and development of adjuvant therapies, post-operative recurrence, which can be as high as 89%, remains a challenge. Currently, pterygium excision with conjunctival autograft remains the preferred surgical technique to decrease recurrence, especially when combined with ciclosporin eye drops. Nevertheless, there is no gold standard surgical technique to prevent pterygium recurrence. Therefore, this review aims to assess the safety, effectiveness and, applicability of platelet-rich fibrin membrane for primary pterygium surgery and assess its possible benefits in resource-limited settings.

Keywords: Pterygium; Platelet-rich membrane; Surgery; Ocular; Repair

1. Introduction

Pterygium is an inflammatory, degenerative, and benign fibrovascular hyperplasia of the conjunctiva that extends across the limbus onto the cornea [1,2]. Nasal location is more common than temporal but, occasionally, can occur in both directions [1]. Even though its pathogenesis is not well understood, it is mainly associated with environmental factors, being ultraviolet radiation the major risk factor, which causes oxidative stress and hinders the normal cell proliferation cycle [1–3]. Genetic predisposition and viral infections (human papillomavirus and herpes simplex virus) have also been reported as causative factors [1,4]. Surgical removal is the only effective treatment, however, the risk of recurrence has been reported to be as high as 89%, depending on the technique used [1]. Recurrence is multifactorial depending on genetic, environmental, and surgical factors (surgical technique); hence, its incidence cannot be easily predicted[1,4].

Pterygium surgical treatment has evolved throughout the years, nowadays the “bare sclera technique”, that was the first adopted technique for pterygium removal, has been discontinued given its high rate of recurrence; thus, adjunct therapies have emerged to mitigate reappearance rates [3]. According to a recent meta-analysis, the best adjuvant treatment to reduce recurrence after pterygium excision is the association of a conjunctival autograft with ciclosporin 0.05% eye drops[3]. The rate of recurrence varies according to the technique used, but none have reported a lack of reappearance. As a result, there is a need to develop new therapeutic strategies that would decrease the proportion of repeat surgeries and therefore ameliorate the expense of such procedures to both patients and the health-care system.

One possible solution might lay within the patient itself, by using blood-derived products, rich in growth factors, to repair the surgical site after pterygium removal. This study aims to analyze the safety, effectiveness, and applicability of platelet-rich fibrin (PRF) membrane for primary pterygium surgery through a literary review and the report of a series of cases.

2. Search Methodology

The Database search for this review was performed on PubMed, Scopus, and Scielo, from inception to 01/02/2021, by using specific keywords including: 'pterygium', 'ocular surface regeneration', 'autologous biomaterials', 'fibrin membrane', 'blood-derived products', 'platelet-rich fibrin', 'plasma rich in growth factors membrane', 'platelet-rich fibrin membrane'. Search with these criteria yielded 62 studies from which only 2 were related to platelet-rich fibrin membrane for pterygium surgery, showcasing the lack of application and scientific assessment of a potentially useful procedure. All studies were assessed by two independent reviewers and any discrepancies were solved by discussion and mutual consensus.

3. Why not use what's already there? The benefit of Blood-Derived Products

Blood-derived products have been used in ophthalmology since 1946 [5]. Platelet preparations are an autologous source of growth factors, adhesion molecules, cytokines, and hemostatic factors; hence, platelets enhance cell adhesion and proliferation, aiding in the regeneration of the ocular surface epithelium [2,5,6]. They also have anti-inflammatory, antifibrotic, and antimicrobial potential [7]. Platelet-rich fibrin (PRF), described by Choukroun et al in 2001, is a second-generation platelet concentrate obtained from centrifugation of an autologous blood sample and from which we obtain a platelet-rich fibrin membrane, which consists of 3-D polymerized autologous fibrin matrix enriched with platelets and their biologically active agents that favors hemostasis, epithelial regeneration and wound healing at the injury site [1,2,5,8].

PRF application has been widely described in dentistry, orthopedics, plastic surgery, and otorhinolaryngology. However, its use in ophthalmology is relatively new, being mostly used in the management of corneal and ocular surface pathologies [2,7]. For example, a Randomized Controlled Trial that assessed the use of PRF membrane for the repair of palatal donor free gingival grafts and compared it with commercial collagen dressings (CollaCote®), reported no significant difference between the use of both procedures [9]. Furthermore, PRF membrane was easier to use and resulted in significantly less costs as compared with the commercial option [9]. Moreover, apart from its use in mucosal epithelium, PRF has also shown promise in nervous tissue and animal models of peripheral nerve injury [10].

However, the success of this technique entirely depends on the time gap between blood collection and its transfer to centrifuge because PRF polymerizes naturally and slowly during centrifugation. Therefore, centrifugation protocols must be standardized since this process has a significant impact on the biological properties of the fibrin matrix [8,11]

4. From blood to membrane: Building the Fibrin Scaffolding

PRF is a second-generation platelet concentrate described by Choukroun *et al* [2]. Platelets are natural reservoirs of growth factors such as epidermal growth factor, fibroblast growth factor, transforming growth factors, platelet-derived growth factors, vascular endothelial growth factors and insulin-like growth factor; cell adhesion molecules like

fibrin, fibronectin and vitronectin, and thrombospondin; and cytokines [2,5,12]. Cell adhesion molecules enhance growth factor activities[12]. During platelet activation, these factors are released at the site of injury facilitating wound healing[5,12].

PRF membrane is a three-dimensional, biocompatible, biodegradable biopolymer, which is obtained through a simple protocol and does not require any additives [6,8]. Its preparation requires the collection of a venous blood sample, without anticoagulant, in a sterile tube which is immediately centrifuged at 3000 rpm for 10 minutes [8,13]. Centrifugation concentrates fibrinogen in the middle and upper parts of the tube, the absence of anticoagulant allows platelet activation with the resulting transformation of fibrinogen into fibrin, which polymerizes to a three-dimensional fibrin mesh; platelets and leukocytes are trapped in this mesh [6,8]. A fibrin clot is formed in the middle of the tube, which is drained to obtain the PRF membrane that acts as a physiologic fibrin matrix scaffold, which interacts with patient's cellular matrix and sustainably releases epitheliotropic factors to support cell adhesion, proliferation, migration and differentiation of the ocular surface epithelium; hence, promoting healing [6–8,13]. A pictorial representation of this process can be found on **Figure 1**.

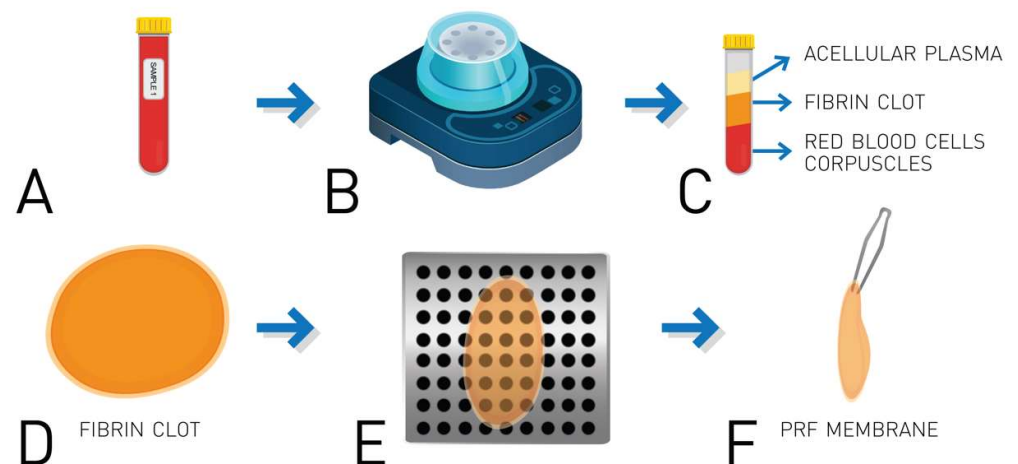


Figure 1. A, a venous blood sample is collected from the patient in a sterile, coagulant-free recollection tube; B, the tube is centrifugated at 3,000 rpm for 10 minutes; C, this results in the concentration of fibrinogen in the superior 2/3 of the tube and its polymerization in a fibrin clot (D); E, the clot is carefully drained to finally obtain the platelet-rich fibrin (PRF) membrane (F).

The PRF membrane can retain, for over a week, almost 30% of growth factors and its natural fibrin framework properties allow growth factors to keep their activity for a longer period [2,6,7,12]. As the fibrin matrix degrades, a progressive and controlled release of epitheliotropic factors occur at the site of injury, which enhances cell proliferation and adhesion; hence, the effect on wound healing is stronger and durable [2,6,7,12]. PRF constitutes a scaffold not only for growth factors but also for migrating endothelial cells; this combination of mechanical and chemotactic support highlights its potential for ocular surface reconstruction [2].

4. Bridging the gap: The application of PRF in Pterygium Surgery

The Treatment of pterygium is essentially surgical; however, high rates of postoperative recurrence remain a challenge. Recurrence is associated with pterygium type and size, age of the patient, environmental factors, and surgical technique, surgical trauma,

postoperative inflammation, and fibroblast proliferation [2,4]. It has been reported that 50% of recurrences occur within the first 4 months, while 97% appear within the first 12 months[1].

The “bare sclera technique alone” is no longer recommended due to its high recurrence rates, being as high as 89% [1]. Therefore, new adjunctive therapies have emerged; of these, a conjunctival autograft is the most commonly used technique due to its low recurrence risk of 5 to 10% and adequate safety margin [1,14,15]. A recent meta-analysis by Fonseca et al that compares the effectivity of 14 adjunct therapies for pterygium excision concluded that conjunctival autograft with ciclosporin 0.05% eye drops was most effective in preventing postoperative recurrence [3]. However, this meta-analysis didn't include the use of PRF membrane and included only studies assessing either conjunctival autograft or bare sclera technique, with and without adjuvant treatments [3]. Disadvantages of the use of adjuvant therapies such as ciclosporin, mitomycin C, beta therapy, 5- fluorouracil, and anti-vascular endothelial growth factor include potentially adverse effects and high costs; nowadays beta radiation is barely used due to its potentially devastating complications [4,14,16]

PRF membrane has exhibited favorable clinical results in the treatment of ocular surface pathologies, mainly corneal ulcers [7]. Nevertheless, there are few reported studies on the use of PRF membrane in pterygium surgery. To the best of our knowledge, there are only 2 studies related to the use of platelet-rich fibrin membrane for pterygium surgery. These compared the use of conjunctival autografts (CA) and PFF membrane. Cakmak *et al* evaluated 35 patient's surgical time, complications, conjunctival epithelization time, suture reaction, postoperative inflammation, and recurrence rates. In this study PRF membrane was superior to CA by a shorter surgical time (about 10 minutes) and milder postoperative inflammation; no suture reaction was observed with PRF membrane however difference was not statically significant [2]. On the other hand, Zhao et al evaluated 62 patient's surgical time, complications, and recurrence rates. Surgical time was shorter for PRF membrane, no significant differences were found between techniques in complications and recurrence rate[17]. These studies concluded that PRF membrane is a safe, effective, and promising method for pterygium surgery with low rates of recurrence and complications [2,17]. It's important to note that postoperative inflammation has been related to pterygium recurrence[2]. PRF membrane facilitates tissue regeneration after ocular surface surgery thus minimizing inflammation[7]; moreover, shorter surgical time reduces ocular surface manipulation reducing postoperative inflammation, hence reducing recurrence [2].

Nonetheless, these are preliminary studies with important limitations such as sample size and statistical power. Further studies are required to completely assess the benefits of this technique in the long-term and completely assess its economic benefit for both the patients and the healthcare system. **Table 1** summarizes the advantages and disadvantages of pterygium repair using PRF versus other techniques. In the next section, we report our experience with a small series of cases where PRF membrane was used.

Table 1. Comparison of pterygium surgical techniques

| Technique | Advantages | Disadvantages |
|---|---|-------------------------------------|
| Conjunctival autograft ⁴ | Easy to perform | Greater postoperative inflammation |
| | Low recurrence rates | Greater suture reaction |
| PRF membrane ^{2, 17} | | Possible graft loss |
| | | Longer surgical time |
| | | Possible pain and discomfort |
| | Easy to perform | |
| | Low recurrence rates | |
| PRF membrane + Conjunctival autograft ^{2,4,17} | Shorter surgical time (Decreased costs) | Possible graft loss |
| | Less postoperative inflammation | Possible pain and discomfort |
| | Less suture reaction | |
| | Easy to perform | Moderate postoperative inflammation |
| | Low recurrence rates | Greater suture reaction |
| | | Possible graft loss |
| | | Longer surgical time |

4. Case examples

CASE 1

40-year-old female patient with no past medical or ophthalmological history. Normal ophthalmic evaluation corrected visual acuity 20/20 in both eyes, slit-lamp examination revealed an inflamed nasal pterygium invading the cornea 2 mm on the right eye.

CASE 2

20-year-old male patient with no relevant past medical history. Normal ophthalmic evaluation corrected visual acuity 20/20 in both eyes, slit-lamp examination revealed an inflamed nasal pterygium invading the cornea 3 mm on the right eye.

CASE 3

40-year-old female patient with no past medical history. Normal ophthalmic evaluation corrected visual acuity 20/40 right eye and 20/20 left eye, slit-lamp examination revealed an inflamed nasal pterygium invading the cornea 2 mm on the right eye.

All cases underwent pterygium excision. Case 1 underwent pterygium excision followed by closure of the bare sclera with PRF membrane sutured with Vicryl 7-0. Cases 2 and 3 underwent pterygium excision followed by closure of bare sclera with PRF membrane and conjunctival autograft sutured with Vicryl 7-0. Mitomycin C 0.04% and triamcinolone 0.4cc were used intraoperatively as adjunct therapies in all cases.

PRF membrane was obtained in the operating room by taking a blood sample from the patient and immediately centrifugating it. The resulting fibrin clot was drained to obtain a membrane which was immediately placed on the bare sclera. Conjunctival autograft was obtained from superior bulbar conjunctiva and was placed on the fibrin membrane and sutured with Vicryl 7-0.

Postoperatively, corticosteroid eye drops, and lubricant eye drops were prescribed to all patients for 2 weeks and 4 weeks, respectively.

Follow-up examinations were carried out on days 2, 5, 1 month, 2 months, and 6 months after surgery. Visual acuity, ophthalmic evaluation, slit-lamp examination, and fluorescein staining were performed to assess graft epithelization, complications, and recurrence. In all cases, full epithelization was observed within the first 5 days. During the follow-up time, no complications or recurrence were evidenced. There was no significant difference observed between the patient who only had the PRF membrane and the patients who had the PRF membrane with conjunctival autograft.

Pterygium prevalence in our country, Ecuador, is not well documented; however, small cross-sectional studies have reported a prevalence ranging between 9% to 55.4% [18–20]. Considering that the basic monthly salary, determined by the Ecuadorian Ministry of Labor for 2021, is 400 USD and that pterygium surgery ranges from 600 – 2500 USD per eye; the need of cheaper alternatives with similar results is something warranted [21]. Certainly, a good proportion of underdeveloped countries face the same reality, which is why health equality, especially regarding illnesses that require surgical treatment, is a major concern in these areas of the world. Since the use of PRF membrane for pterygium surgery has shown comparable results and it has been associated with shorter surgical time, hence less cost, it is a promising method for resource-limited countries.

Limitations:

Our case series suffers from the common limitations of the small patient sample and lack of longer follow-up. Nonetheless, we believe that the use of PRF membrane shows promise and more studies should be performed in order to elucidate its long-term outcomes as well as assess its potential in resource limited settings, in terms of saving economic and hospital resources.

5. Conclusions

PRF membrane is a promising method with low rates of recurrence and complications. Previous studies have yield positive preliminary results and are the foundation for future investigations. A clear advantage of this method is the use of autologous material for surgery, it is timesaving and easy to prepare; therefore, PRF membrane is a safe, economic, effective, and feasible technique for pterygium surgery.

Author Contributions: Conceptualization, C.C. and J.L-R.; methodology, C.C. and J.L-R.; investigation, C.C. and J.L-R.; resources, C.C. and J.L-R.; data curation, C.C. and J.L-R.; writing—original draft preparation, C.C. and J.L-R.; writing—review and editing, C.C. and J.L-R.; visualization, C.C.; supervision, J-LR.; project administration, J.L-R. All authors have read and agreed to the published version of the manuscript.

Funding: This research received no external funding.

Institutional Review Board Statement: Not applicable.

Informed Consent Statement: Informed consent was obtained from all subjects involved in the study. However, written informed consent was not warranted as all the included cases in this short series don't allow for patient identification

Conflicts of Interest: The authors declare no conflict of interest.

References

1. Hovanesian, J.A.; Starr, C.E.; Vroman, D.T.; Mah, F.S.; Gomes, J.A.P.; Farid, M.; Shamie, N.; Davidson, R.S.; John, T.; Holland, E.J.; et al. Surgical techniques and adjuvants for the management of primary and recurrent pterygia. *J. Cataract Refract. Surg.* **2017**, *43*, 405–419, doi:10.1016/j.jcrs.2017.03.002.
2. Cakmak, H.B.; Dereli Can, G.; Can, M.E.; Cagil, N. A novel graft option after pterygium excision: Platelet-rich fibrin for conjunctivoplasty. *Eye* **2017**, *31*, 1606–1612, doi:10.1038/eye.2017.109.
3. Fonseca, E.C.; Rocha, E.M.; Arruda, G.V. Comparison among adjuvant treatments for primary pterygium: A network meta-analysis. *Br. J. Ophthalmol.* **2018**, *102*, 748–756, doi:10.1136/bjophthalmol-2017-310288.
4. Nuzzi, R.; Tridico, F. How to minimize pterygium recurrence rates: Clinical perspectives. *Clin. Ophthalmol.* **2018**, *12*, 2347–2362, doi:10.2147/OPTH.S186543.
5. Nugent, R.B.; Lee, G.A. Ophthalmic use of blood-derived products. *Surv. Ophthalmol.* **2015**, *60*, 406–434, doi:10.1016/j.survophthal.2015.03.003.
6. Kardos, D.; Hornyák, I.; Simon, M.; Hinsenkamp, A.; Marschall, B.; Várdai, R.; Kállay-Menyhárd, A.; Pinke, B.; Mészáros, L.; Kuten, O.; et al. Biological and mechanical properties of platelet-rich fibrin membranes after thermal manipulation and preparation in a single-syringe closed system. *Int. J. Mol. Sci.* **2018**, *19*, 576–579, doi:10.3390/ijms19113433.
7. Sanchez-Avila, R.M.; Merayo-Llodes, J.; Riestra, A.C.; Berisa, S.; Lisa, C.; Sánchez, J.A.; Muruzabal, F.; Orive, G.; Anitua, E. Plasma rich in growth factors membrane as coadjuvant treatment in the surgery of ocular surface disorders. *Med. (United States)* **2018**, *97*, doi:10.1097/MD.00000000000010242.
8. Dohan, D.M.; Choukroun, J.; Diss, A.; Dohan, S.L.; Dohan, A.J.J.; Mouhyi, J.; Gogly, B. Platelet-rich fibrin (PRF): A second-generation platelet concentrate. Part I: Technological concepts and evolution. *Oral Surgery, Oral Med. Oral Pathol. Oral Radiol. Endodontology* **2006**, *101*, doi:10.1016/j.tripleo.2005.07.008.
9. Sharma, V.; Kumar, A.; Puri, K.; Bansal, M.; Khatri, M. Application of platelet-rich fibrin membrane and collagen dressing as palatal bandage for wound healing: A randomized clinical control trial. *Indian J. Dent. Res. Off. Publ. Indian Soc. Dent. Res.* **2019**, *30*, 881–888, doi:10.4103/ijdr.IJDR_370_17.
10. Huang, M.-L.; Zhai, Z.; Chen, Z.-X.; Yang, X.-N.; Qi, Z.-L. Platelet-rich fibrin membrane nerve guidance conduit: a potentially promising method for peripheral nerve injuries. *Chin. Med. J. (Engl.)* **2020**, *133*, 999–1001, doi:10.1097/CM9.0000000000000726.
11. Dohan Ehrenfest, D.M.; Pinto, N.R.; Pereda, A.; Jiménez, P.; Corso, M. Del; Kang, B.S.; Nally, M.; Lanata, N.; Wang, H.L.; Quirynen, M. The impact of the centrifuge characteristics and centrifugation protocols on the cells, growth factors, and fibrin architecture of a leukocyte- and platelet-rich fibrin (L-PRF) clot and membrane. *Platelets* **2018**, *29*, 171–184, doi:10.1080/09537104.2017.1293812.
12. Alio, J.L.; Rodriguez, A.E.; Martinez, L.M.; Rio, A.L. Autologous fibrin membrane combined with solid platelet-rich plasma in the management of perforated corneal ulcers: A pilot study. *JAMA Ophthalmol.* **2013**, *131*, 745–751, doi:10.1001/jamaophthalmol.2013.2474.
13. Naik, B.; Karunakar, P.; Jayadev, M.; Rahul Marshal, V. Role of Platelet rich fibrin in wound healing: A critical review. *J. Conserv. Dent.* **2013**, *16*, 284–293, doi:10.4103/0972-0707.114344.
14. Young, A.L.; Kam, K.W. Pterygium: Surgical techniques and choices. *Asia-Pacific J. Ophthalmol.* **2019**, *8*, 422–423, doi:10.1097/APO.0000000000000269.
15. Kurian, A.; Reghunadhan, I.; Nair, K.G.R. Autologous blood versus fibrin glue for conjunctival autograft adherence in sutureless pterygium surgery: A randomised controlled trial. *Br. J. Ophthalmol.* **2015**, *99*, 464–470, doi:10.1136/bjophthalmol-2014-305028.
16. Chu, W.K.; Choi, H.L.; Bhat, A.K.; Jhanji, V. Pterygium: new insights. *Eye* **2020**, *34*, 1047–1050, doi:10.1038/s41433-020-0786-

-
- 3.
17. Qiu-Ya Zhao, Yi-Qiao Xing, Lei Du, S.-Y.Z. Application of platelet-rich fibrin grafts in pterygium excision. *Guoji Yanke Zazhi (Int Eye Sci)* **2020**, 3, 576–579.
18. Chamba Maza, M.F. "Pterigión y su relación con la actividad laboral en las edades comprendidas de 20 a 65 años atendidas en la Consulta de Oftalmología del Hospital Isidro Ayora de la ciudad de Loja, periodo Enero a Junio 2016." **2017**.
19. Luis, E.; Hernan, L. *Causas y Frecuencia del Pterigión en pacientes adultos atendidos en consulta externa de oftalmología del hospital del día-Azoguez periodo Julio-Noviembre 2017*; 2017; Vol. 4; ISBN 0604406835.
20. Eileen, O. Prevalencia de Pterigión y factores de riesgo asociados en pacientes atendidos en la consulta externa de oftalmología del Hospital Provincial General Docente de Riobamba 2017, 1–88.
21. "Ministerio de Trabajo" Salario Básico Unificado Ecuador 2021 Available online: <https://www.trabajo.gob.ec/el-salario-basico-unificado-sbu-para-el-2021-sera-de-usd-400/> (accessed on Mar 16, 2021).