

Review

Not peer-reviewed version

The Artery of Davidoff and Schechter: Navigating Its Anatomy and Neurosurgical Implications

[Oday Atallah](#)*, [Zeinab Hammoud](#), [Yasser F. Almealawy](#), Ahmed Muthana, [Mohammed A. Azab](#), Lambert Schless

Posted Date: 18 March 2026

doi: 10.20944/preprints202603.1452.v1

Keywords: artery of Davidoff and Schechter; posterior cerebral artery; dural arteriovenous fistula; tentorial; falcotentorial; hemangioblastoma



Preprints.org is a free multidisciplinary platform providing preprint service that is dedicated to making early versions of research outputs permanently available and citable. Preprints posted at Preprints.org appear in Web of Science, Crossref, Google Scholar, Scilit, Europe PMC.

Copyright: This open access article is published under a [Creative Commons CC BY 4.0 license](#), which permit the free download, distribution, and reuse, provided that the author and preprint are cited in any reuse.

Disclaimer/Publisher's Note: The statements, opinions, and data contained in all publications are solely those of the individual author(s) and contributor(s) and not of MDPI and/or the editor(s). MDPI and/or the editor(s) disclaim responsibility for any injury to people or property resulting from any ideas, methods, instructions, or products referred to in the content.

Review

The Artery of Davidoff and Schechter: Navigating Its Anatomy and Neurosurgical Implications

Oday Atallah ^{1,*}, Zeinab Hammoud ², Yasser F. Almealawy ³, Ahmed Muthana ⁴, Mohammed A. Azab ⁵ and Lambert Schless ⁶

¹ Department of Neurosurgery, Nordwest Hospital Sanderbusch, Carl Von Ossietzky University Oldenburg, Oldenburg, Germany

² Faculty of Medical Sciences, Lebanese University, Beirut, Lebanon

³ Faculty of medicine, University of Kufa, Kufa, Iraq

⁴ Faculty of Medicine, University of Baghdad, Baghdad, Iraq

⁵ Departemnt of Neurosurgery, Cairo University Hospital, Cairo, Egypt

⁶ Department of Neurosurgery, Nordwest Hospital Sanderbusch, Am Gut Sanderbusch 1, 26452 Sande, Germany

* Correspondence: oday.atallah@yahoo.de

Abstract

Introduction: The artery of Davidoff and Schechter (ADS) is a dural branch of the posterior cerebral artery that supplies the falcotentorial junction and posterior tentorium. It can be a major feeder in dural arteriovenous fistulas, tumors, and uncommon aneurysms in this area. This study examines documented human cases of the ADS to provide a comprehensive understanding of its anatomy, pathological correlations, and neurosurgical and therapeutic consequences. **Methods:** We conducted a systematic review of PubMed, Scopus, and ScienceDirect from inception to December 2025, focusing on human, English-language studies with eponymous ADS terms and combinations of posterior cerebral artery dural/meningeal branches, tentorial or falcotentorial pathology, and dAVFs/meningiomas. **Results:** Twenty-three studies met the inclusion criteria, including 54 patients with ADS-related vascular lesions published between 1974 and 2025. The average age was 51.1 years (range 13-79), and 46.3% of patients were male. Headache was the most commonly reported symptom (44.4%), followed by altered awareness (11.1%), tinnitus (9.3%), visual/ocular symptoms (9.3%), and ataxia (9.3%). All lesions were dural shunts or related vascular diseases in the falcotentorial-tentorial-falcine/posterior fossa region, with falcotentorial dAVF (19/54; 35.2%) and tentorial dAVF (16/54; 29.6%) predominating. ADS laterality was 35.2% left, 29.6% right, and 11.1% bilateral. Transarterial embolization was the most common treatment (75.9%), with surgery and transvenous embolization being used less frequently. Major consequences were primarily in ischemia infarction (7.4%). Favorable outcomes were achieved in most patients, complete recovery in 44.4% and clinical improvement in 20.4%. **Conclusions:** This systematic study will provide clinicians with a consolidated reference on ADS architecture, disease involvement, and procedural risks, allowing them to plan neurosurgical and neurointerventional procedures more effectively. :

Keywords: artery of Davidoff and Schechter; posterior cerebral artery; dural arteriovenous fistula; tentorial; falcotentorial; hemangioblastoma

Introduction

The Davidoff and Schechter artery (ADS) is a meningeal branch of the posterior cerebral artery (PCA). Paul B. and Gertraud Wollschlaeger originally described it in 1965 with postmortem barium angiography (Roman et al., 2022). ADS is the primary dural branch of the PCA, supplying the falcotentorial junction and surrounding posterior tentorium. Because of its tiny caliber and slow flow, it is commonly overlooked during regular angiography. Pathological expansion occurs when

it becomes a primary feeder for falcotentorial or tentorial dural arteriovenous fistulas (dAVFs), meningiomas, or hemangioblastomas. Enlargement is also seen in aneurysms and arteriovenous malformations in the posterior fossa and falcine region (Bhatia et al., 2020; Indo et al., 2025).

The ADS provides circulatory area in the posterior medial tentorium and falcotentorial junction. This region is near the deep venous system and the brainstem (Roman et al., 2022). Lesions of the ADS, as well as unintentional catheterization and embolization of this vessel, can have serious clinical repercussions such as hemorrhage, venous congestion, and ischemia injury to the midbrain and thalamus (Lucas et al., 2023; Roman et al., 2022). For neurosurgeons, precisely identifying the ADS from adjacent pial branches is critical for planning endovascular therapy or microsurgical disconnection of complex dAVFs (Golub et al., 2024).

Although case reports and series have detailed ADS morphology, anatomical variances and their involvement in providing tentorial and falcotentorial lesions are rarely discussed. Moreover, currently available literature has been fragmented and majority are descriptive. A comprehensive literature review and analysis of ADS-related clinical cases with demographic characteristics, clinical presentation, angiographic features, pathologies, management strategies, complications, and outcomes, will be able to help clinicians in decision making process. Through this study, our aim was to provide a strong reference document for ADS anatomy and its neurosurgical and endovascular implications.

Methods

This study was conducted after a thorough evaluation of all articles related to the ADS. The electronic databases, including PubMed, Scopus, and ScienceDirect, were searched until December 2025. A structured literature search was attempted to find papers that described the Davidoff and Schechter artery (ADS), its architecture, imaging properties, and neurosurgical/endovascular implications. The searches were limited to human studies and English-language publications (Figure 1).

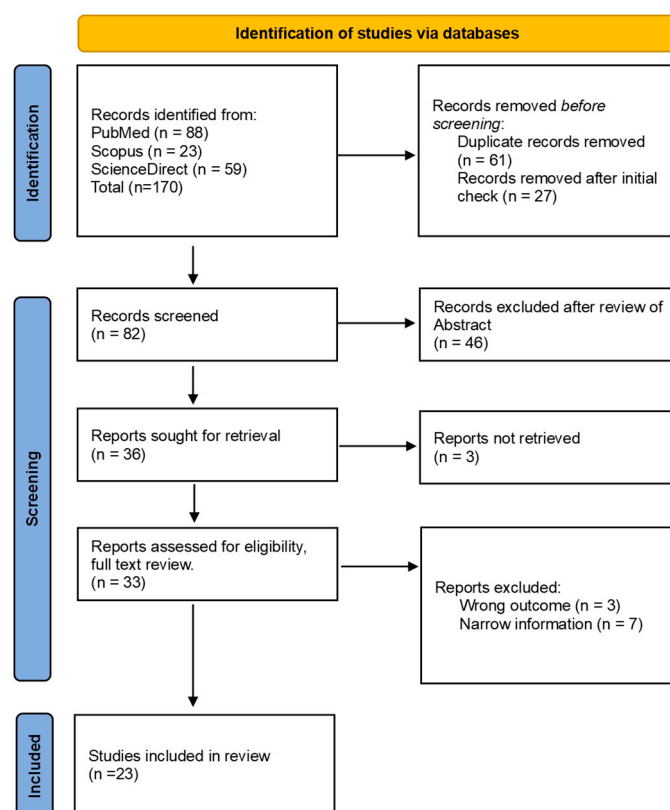


Figure 1. PRISMA flow diagram for identification of the studies.

In PubMed, the following query was used and yielded 88 records: (“Davidoff”[Title/Abstract] AND “Schechter”[Title/Abstract]) OR “artery of Davidoff and Schechter”[Title/Abstract] OR (“posterior cerebral artery”[Title/Abstract] AND (“dural branch”[Title/Abstract] OR “meningeal branch”[Title/Abstract]) AND (tentorial[Title/Abstract] OR falcotentorial[Title/Abstract])) OR Wollschlaeger[Author] OR (“arteriovenous fistula”[Title/Abstract] OR “dural arteriovenous fistula”[Title/Abstract] OR dAVF[Title/Abstract]) AND (tentorial[Title/Abstract] OR falcotentorial[Title/Abstract]) AND “posterior cerebral artery”[Title/Abstract]) OR (meningioma[Title/Abstract] AND (falcotentorial[Title/Abstract] OR “falx cerebri”[Title/Abstract] OR tentorial[Title/Abstract]) AND “posterior cerebral artery”[Title/Abstract]).

In Scopus, the search strategy TITLE-ABS-KEY(“artery of Davidoff and Schechter” OR (“Davidoff” AND “Schechter”) OR (“posterior cerebral artery” AND (“dural branch” OR “meningeal branch”) AND (tentorial OR falcotentorial)) OR (“dural arteriovenous fistula” OR “arteriovenous fistula” OR DAVF OR dAVF) AND (tentorial OR falcotentorial) AND “posterior cerebral artery” OR (meningioma AND (falcotentorial OR “falx cerebri” OR tentorial) AND “posterior cerebral artery”)) yielded 23 records. In ScienceDirect, the database was searched using “artery of Davidoff and Schechter” OR (Davidoff AND Schechter), limited to English-language research articles, case reports, and conference papers, yielding 59 records.

Before screening, records from all databases were exported, consolidated into a single library, and de-duplicated. Titles were then reviewed for relevance to the Davidoff and Schechter artery (ADS). Abstracts then reviewed to determine which studies matched. Then we went for full text review of the screened articles, including anatomy, angiographic identification, and clinical/neurosurgical/endovascular significance. Two reviewers independently evaluated the records to determine which studies matched the predetermined eligibility criteria.

Results

Demographic Characteristics

From 1974 to 2025, 54 patients with ADS-related dural AVF/dAVM were found throughout 23 studies. Age was reported in 38/54 (70.4%), with a mean of 51.1 ± 15.9 years, median 53, and range 13-79 years. The majority of patents (46.3%) were male, with 13 females (24.1%) and 16 patients (29.6%) did not report their gender (**Table 1**).

Clinical Presentation

The clinical presentation was varied, with various symptoms coexisting in the same instance. Headache was the most common complaint, affecting 24/54 patients (44.4%) and frequently co-occurring with additional symptoms such as ataxia, tinnitus, or visual problems. Altered consciousness (loss of consciousness, confusion, lethargy, or decreased consciousness) was observed in 6/54 (11.1%), whereas visual/ocular manifestations (visual disturbance, alexia, ocular congestion, exophthalmus) occurred in 5/54 (9.3%). Tinnitus was reported in 5 out of 54 (9.3%), as was ataxia or balance problems. A hemorrhagic presentation (SAH or intraparenchymal hematoma) was observed in 3/54 individuals (5.6%), seizures in 2/54 (3.7%), and cognitive symptoms (dementia or cognitive impairment) in 2/54 (3.7%).

Table 1. A synopsis of the selected articles within the ADS.

Author	Year	Pts	Age (y) /sex	Presentation	Diagnostic modalities	Diagnostic modality of ADS	Origin Site/segment	Associated pathology	Feeding arteries/ Draining vein	Management	Complications	Mx of complications	Outcome
(Weinstein et al., 1974)	1974	3	26/M	hemiparesis	Isotope brain scan-increased uptake in midline parietal region	Angiogram	Lt/-	Falcine meningioma	-	Surgery- PR	-	-	-
			13m / M	Pulsatile occipital scalp mass	X-ray-prominent meningeal vascular markings with bone defect	Angiogram	Rt/-	Falcotentorial dAVM	-	-	-	-	-
			15y/ F	LOC	Ventriculogram-mass inside the posterior part of septum pellicidum, partially obstructing the Foramen of Monro	Angiogram	Lt/-	-	-	-	-	-	-
(Puri, 2010)	2010	1	40/F	Pressure sensation in the occipital region	MRI/MRA-posterior pericallosal and quadrigeminal plate cistern flow voids	DSA	Bilateral	Splenic dAVF	MHT, OA, ADS, artery of falx cerebelli/VOG	Conservative and follow up	-	-	-
(Zhang et al., 2010)	2010	1	41/M	-	-	DSA	Lt/ P2	Tentorial dAVF	ADS/aneurysmal vein	TA embolization ADS with Onyx	Left cerebellar infarction	Conservative	Blepharoptosis and ataxia recovered. Additional infarction

									(SCA territory)			of Lt. superior colliculus and Lt. cerebellar peduncle in 3 months F/U MRI	
(Hart et al., 2011)	2011	1	57/M	Left LL weakness, dimness of vision	MRI-Falcine meningioma with SSS infiltration	DSA	Lt/ -	Falcine meningioma	ADS, MMA, OA, STA(Feeding arteries)/-	TA embolization with Glubran, followed by GTR of tumor	None	None	Improved neurological status with no recurrence at 18 months F/U
(Byrne & Garcia, 2013)	2013	4	45/M	HA, LOC	CT/CTA-posterior fossa hemorrhage, HCP	DSA		Falx cerebelli dAVF	MHT, ADS, SCA/ Posterior fossa veins	TA embolization with Onyx, n-BCA (2 feeders embolized)	Edema with brainstem compression	-	Died at 14 th POD
			64/F	HA, AMS, dysphasia	CT/CTV-engorged leptomeningeal veins	DSA		Torcular dAVF	OA, MMA, ADS, SCA/ Tentorial veins	TA embolization with Onyx (1 feeder embolized)	None	None	Complete neurological recovery
			66/M	Visual disturbance	MRI-multiple congested intracranial veins	DSA		Torcular dAVF	OA, PMA, MHT, ADS, SCA/ Tentorial veins	TA embolization with Onyx (2 feeders embolized)	None	None	Improved
			64/M	LOC, vomiting, aphasia	CT-posterior fossa SAH with VE	DSA		Falx cerebelli dAVF Incomplete Onyx embolization in another centre-4 years back	OA, MMA, PMA, PICA, ADS/ Posterior fossa veins	TA embolization with n-BCA to flow aneurysm (1 feeder embolized)	None	None	Residual symptom (treatment ongoing)
(Griesse nauer et al., 2013)	2013	2	62/M	HA, photophobia, tinnitus	-	DSA	Rt/ P2	Falcotentorial dAVF	ADS/-	Endovascular embolization	None	None	HA & photophobia improved but tinnitus persisted at 6 years F/U

			50/M	Tinnitus	-	DSA	Rt/ P2	Galenic tentorial dAVF	ADS/ VOG	Endovascular embolization with platinum coils	None	None	Complete angiographic obliteration at 3 years F/U
(Choudhri & Marks, 2014)	2014	1	65/F	HA, balance difficulty	MRI-ASL suggestive of AV shunting	DSA	Lt/ P1	Galenic tentorial dAVF	ADS, MHT, posterior choroidal branches/ VOG	TA embolization through left ADS with onyx	None	None	Complete neurological recovery at 3 months F/U and no recurrence at 6 months F/U angiogram
(Puri, 2015)	2015	1	40/F	Pressure sensation in the occipital region	MRI/MRA-flow voids along the posterior pericallosal and quadrigeminal cistern	DSA	Lt/ -	Tentorial dAVF	MHT, OA, ADS/ VOG	Not treated	-	-	-
(Gioppo et al., 2017)	2017	1	60/F	Tinnitus, hearing loss	MRI-abnormal tangle of vessel with prominent cerebellar vein	DSA	-	Tentorial dAVF	MHT, MMA, OA, ADS/ PCV into VOG	TA embolization MMA with liquid polymer glue (Squid-18)	None	None	Tinnitus resolve with improved hearing status at 6 months F/U
(Bhatia et al., 2020)	2020	6	30/M	HA	-	DSA	-	Falcotentorial dAVF	ADS, MHT, RMA/ VOG	TA embolization through RMA with onyx	Residual flow through ADS	TV Reverse pressure-cooker to vein of Galen with Onyx+coils	Pre-procedure mRS:1 Post-procedure mRS:1
			44/ F	HA	-	DSA	-	Falcotentorial dAVF	ADS, MMA, OA, PMA / SS	TA embolization Pressure-cooker to MMA; combined coils and Onyx to ADS	None	None	Pre-procedure mRS:1 Post-procedure mRS:0
			34/ F	LOC, Pulsatile tinnitus	-	DSA	-	SSS, Middle third dAVF	ADS, MMA, OA, PMA, STA/ SSS (middle	TA embolization through MMA and PMA with Onyx	Residual supply through ADS	TA STA with Onyx	Pre-procedure mRS:1 Post-procedure mRS:0

third)													
		53/ M	HA	-	DSA	-	Parasagittal dAVF	ADS, MMA, AMA/ cortical vein	TA embolization through MMA with onyx	None	None	Pre-procedure mRS:1 Post-procedure mRS:0	
		65/ M	Balance difficulty	-	DSA	-	Falcotentorial dAVF	ADS, MMA, OA/ cortical vein	TA embolization through MMA n-BCA glue to MMA and balloon occlusion of OA to reduce flow	Residual supply through ADS	TA embolization MMA and posterior meningeal with Onyx	Pre-procedure mRS:2 Post-procedure mRS:1	
		53/ F	SAH	-	DSA	-	Falcotentorial dAVF	ADS, MMA, OA/ cortical vein	TA embolization through MMA with Onyx	None	None	Pre-procedure mRS:1 Post-procedure mRS:0	
(Ghorbani et al., 2021)	2021	1	47/M	Ataxia, HA H/O gamma knife for AVM-15 years back H/O VP shunt-2 years back	CT-Infratentorial mass	DSA	Rt	Tentorial dAVF	ADS, MMA, OA, Tentorial Artery/ VOG	TA embolization through right MMA with onyx, followed by TA embolization through left MMA, left OA, right PCA (ADS) with onyx after 2 months	HCP after 2 months, development of venous varix with intra-variceal hemeatoma after 6 months of VP shunt	Left sided VP shunt done. After 6 months, microsurgical excision of venous varix done through supracerebellar-infratentorial route	Clinically improved and discharged at 5 th POD following venous varix surgery
(Rezen de et al., 2021)	2021	6	63/F	Asymptomatic	-	DSA	Lt	Tentorial dAVF	ADS, OA/-	TA embolization through left OA with onyx	None	None	Complete angiographic occlusion achieved and no recurrence in F/U angiogram 6 months
		52/M	HA, ataxia	-	DSA	Lt	Tentorial dAVF	MMA, OA, ADS/-	TA embolization through left OA with onyx and coils	None	None	Complete angiographic occlusion achieved	

												and no recurrence in F/U angiogram 6 months
	73/M	Asymptomatic	-	DSA	Rt	Tentorial dAVF	ADS, OA/-	TA embolization through right OA with onyx	None	None	Complete angiographic occlusion achieved and no recurrence in F/U angiogram 6 months	
	32/M	HA	-	DSA	Bilateral	Tentorial dAVF	MMA, OA, ADS, MTA/-	TV embolization with onyx and coils	None	None	Complete angiographic occlusion achieved and no recurrence in F/U angiogram 6 months	
	43/M	HA, cognitive impairment	-	DSA	Rt	Tentorial dAVF	MMA, OA, ADS, MTA, PMA/-	TV embolization with coils in first setting followed by TV embolization with glue and coils in second setting	None	None	Complete angiographic occlusion achieved and no recurrence in F/U angiogram 6 months	
	50/M	HA	-	DSA	Rt	Tentorial dAVF	MMA, OA, MTA, PMA, ADS/-	TA embolization through right MMA and left OA with onyx (double lumen balloon assisted)	None	None	Complete angiographic occlusion achieved and no recurrence in F/U angiogram 6 months	
(Carnevale et al., 2022)	2022 1	60/F	Alexia	CT-Left temporo-occipital intraparenchymal hematoma	DSA	Lt	Tentorial dAVF	OA, ADS/-	TA embolization through left MMA and left OA with onyx			
(Islak et al., 2022)	2022 10	-	Dementia, tonsillar herniation, HCP	-	DSA	Lt	Falcotentorial dAVF	ADS, MHT, MMA, OA/ICV, PCV	TA embolization through left ADS with glue	None	None	Complete angiographic occlusion achieved and no recurrence in

								F/U angiogram (6-12 months)	
		DSA	Rt	Falcotental dAVF	ADS, PMA, all dural branches from ECA/SS, VOG, BVR, IOV, LAMVs, APMV	TA embolization through left MMA with onyx	None	None	Complete angiographic occlusion achieved and no recurrence in F/U angiogram (6-12 months)
Lt sided paresthesia, Rt thalamic hematoma		DSA	Lt	Falcotental dAVF	ADS, AWW, all dural branches of both ECAs, PMA, AMA/SS, VOG, BVR, LAMV	TA embolization through bilateral MMA with onyx	None	None	Complete angiographic occlusion achieved and no recurrence in F/U angiogram (6-12 months)
		DSA	Bilateral	Falcotental dAVF	ADSs, MHT, MMA, OA, PMA/VOG, SS, BVR, LAMV, APMV	TA embolization through right ADS with onyx	None	None	Complete angiographic occlusion achieved and no recurrence in F/U angiogram (6-12 months)
Dysphagia, dysphonia, ataxia		DSA	Lt	Falcotental dAVF (previously underwent surgery for temporal tumor)	ADS, MHT, PMA, AMA, all dural branches of both ECAs/SS, VOG, BVR	TA embolization through right PMA with onyx	None	None	Complete angiographic occlusion achieved and no recurrence in F/U angiogram (6-12 months)

	DSA	Rt	Falcotentorial dAVF	ADS, MHT, all dural branches of both ECAs, PMA/VOG, SS, BVR, IOV	TA embolization through right MMA with onyx	None	None	Complete angiographic occlusion achieved
	DSA	Rt	Falcotentorial dAVF	ADS, MHT/SVV, SS	TA embolization through right ADS, left MHT with PHIL microvention	None	None	Complete angiographic occlusion achieved
	DSA	Rt	Falcotentorial dAVF	ADS, MHT, MMA, PMA/VOG, IOV, BVR, LAMV, APMV	TA embolization through right OA with PHIL microvention	None	None	Complete angiographic occlusion achieved and no recurrence in F/U angiogram (6-12 months)
Seizure	DSA	Bilateral	Falcotentorial dAVF	ADSs, MHT, AMA, all dural branches of both ECAs/VOG, SS, BVR, IOV, numerous infratentorial veins	TA embolization through left MMA, left PMA with onyx	None	None	Partial angiographic occlusion achieved
HA, exophthalmus, hearing loss, tonsillar herniation, HCP	DSA	Lt	Falcotentorial dAVF	ADS, all dural branches of both ECAs, MHT, PMA, PMCA/VOG, SS,	TA embolization through right PMCA, left ADS with onyx	Parinaud syndrome, tectal compression	Bithalamic infarction	Complete angiographic occlusion achieved and no recurrence in F/U angiogram (6-12 months)

BVR, IOV

(Fry et al., 2022)	1	57/F	HA, SAH	CT/CTA-perimesencephalic SAH with complex vascular malformation	DSA	Rt/ P1	Tentorial dAVF, ADS aneurysm	MMA, OA/VOG, ADS had fistulous connection with SS	TA balloon assisted embolization MMA, OA with onyx for dAVF and coiling of the aneurysm with ADS sacrifice in two setting, 1 week interval	None	None	Complete neurological recovery at 2 months F/U
(Roman et al., 2022)	7	61.9 (mean age)	HA	CT/CTA-negative	DSA	Rt	Tentorial dAVF	ADS/ Dural and cortical veins	TA embolization ADS with onyx	Left UL tremor/ hemiparesis due to delayed midbrain infarction	Conservative	Complete angiographic occlusion achieved and mRS 3 at 52 months F/U
	-		Tinnitus, hearing loss	MRI-prominent cortical veins in the posterior fossa	DSA	Lt	Posterior fossa dAVF	ADS, MMA, RMA from OpthA/ Left SCCV	TA embolization ADS with onyx followed by suboccipital craniectomy and obliteration of fistula	None	None	Complete angiographic occlusion achieved. Residual tinnitus mRS 1 at 29 months F/U
	-		HA, lethargy	CT- SAH with VE	DSA	Bilateral	dAVF	ADS/ SVV, VOG, SS	TV embolization venous varix with micro-coil embolization, followed by cyber knife stereotactic radiotherapy (3,300cGy in 3 fractions)	Persistent shunting	None	mRS 0 at 36 months F/U
	-		Confusion, lethargy	MRI-bilateral hyperintense	DSA	Rt	Tentorial dAVF	ADS, APA, PMA/ VOG,	TA embolization ADS with onyx	Delayed hemiparesis	Conservative	mRS 2 at 22 months F/U

					signal change in thalamus with restricted diffusion			SS	followed by TA embolization APA with poly vinyl alcohol particle in 18 days apart. PMA feeder addressed surgically	and dysarthria due to midbrain infarction			
				Referred case to confirm thalamic lesion	MRI-FLAIR hyperintense signal change in both thalamus (left>right) MRA-abnormal venous flow in tentorium	DSA	Lt	Tentorial dAVF	ADS, PMA, APA/SVV, VOG	Microsurgical clipping	CN VI palsy due to post-operative tension pneumocephalus, right hand numbness	Conservative	Complete angiographic obliteration achieved. mRS 1 at 20 months F/U
					CT- post traumatic SAH	DSA	Rt	Tentorial dAVF	ADS, PCA/SVV, VOG	-	-	-	-
				Syncope, dysarthria	CTA-prominent vessels in the posterior fossa	DSA	Rt	Posterior fossa dAVF	ADS, OA/SVV, VOG	Conservative	None	None	Discharged home in stable condition
(Shi et al., 2022)	2022	1	32/M	Ocular swelling and congestion (Lt)	MRI-enlargement of Lt. SOV	DSA	Lt	Falcotentorial dAVF	ADS, MMA/anonymous variant vein, CS	TA embolization MMA by onyx	None	None	Complete angiographic occlusion achieved and no recurrence at 9 months F/U
(Sugiyama et al., 2022)	2022	1	74/M	Incidental	MRI-dilatation of the cortical veins in right occipital lobe	DSA	Lt/ P1	Falcine dAVF	MMA, OA, ADS, PMA/ cortical veins	TA embolization MMA by n-BCA, OA by platinum coils, TA embolization ADS by onyx 3 months later	None	None	Complete angiographic occlusion achieved
(Woo et al., 2022)	2022	1	63/M	HA	MRA-suggestive of Falcotentorial dAVF	DSA	Lt/ P1- PCom A	Falcotentorial dAVF	ADS, OA/ VOG	TA embolization ADS with onyx	None	None	HA subsided and no recurrence on MRA at 12 months F/U

junction													
(Su et al., 2024)	2024	1	42/M	HA	-	DSA	-	Falcine dAVF	MMA, ADS/cortical veins, SSS	TA embolization MMA with onyx	None	None	-
(Yanai et al., 2024)	2024	1	79/M	Decreased consciousness	CT-Posterior fossa SAH	DSA	Bilateral/ P2	Falcotentorial dAVF with right ADS aneurysm	ADS, MMA, STA, OA/SVV, SCCV	TA embolization Right ADS with nBCA to occlude aneurysm followed by TA embolization left ADS & MMA with nBCA to obliterate fistula, 1 month interval	None	None	Referred to rehabilitation centre with mRS 4
(Day & Dacey, 2026)	2025	1	54/F	HA	CT-SAH with left sided cerebellar subfoliar hemorrhage	DSA		dAVF	MHT, ADS/SPV	Surgery-coagulation & disconnection of fistula			
(Indo et al., 2025)	2025	1	72/M	Seizure	CT-multiple calcified lesion throughout the left cerebral hemisphere MRI-multiple dilated veins along the similar area in CT	DSA	Lt/ P4	dAVF	MMA, OA, ADS/Cortical veins	TA embolization ADS	None	None	Referred to rehabilitation centre

Pathology and ADS Anatomy

All the lesions were dural shunts or vascular lesions in the falcotentorial-tentorial-falcine/posterior fossa area. The most common diseases were falcotentorial dAVF in 19/54 (35.2%) and tentorial dAVF in 16/54 (29.6%), which accounted for 35/54 (64.8%). Less common categories included falcine dAVF (4; 7.4%), dAVF (unspecified location) (3; 5.6%), parasagittal/SSS dAVF (2; 3.7%), torcular dAVF (2; 3.7%), falx cerebelli dAVF (2; 3.7%), posterior fossa dAVF (2; 3.7%), Galenic tentorial dAVF (2; 3.7%), splenial dAVF (1; 1.9%), and one case without specified site (**Figure 2**).

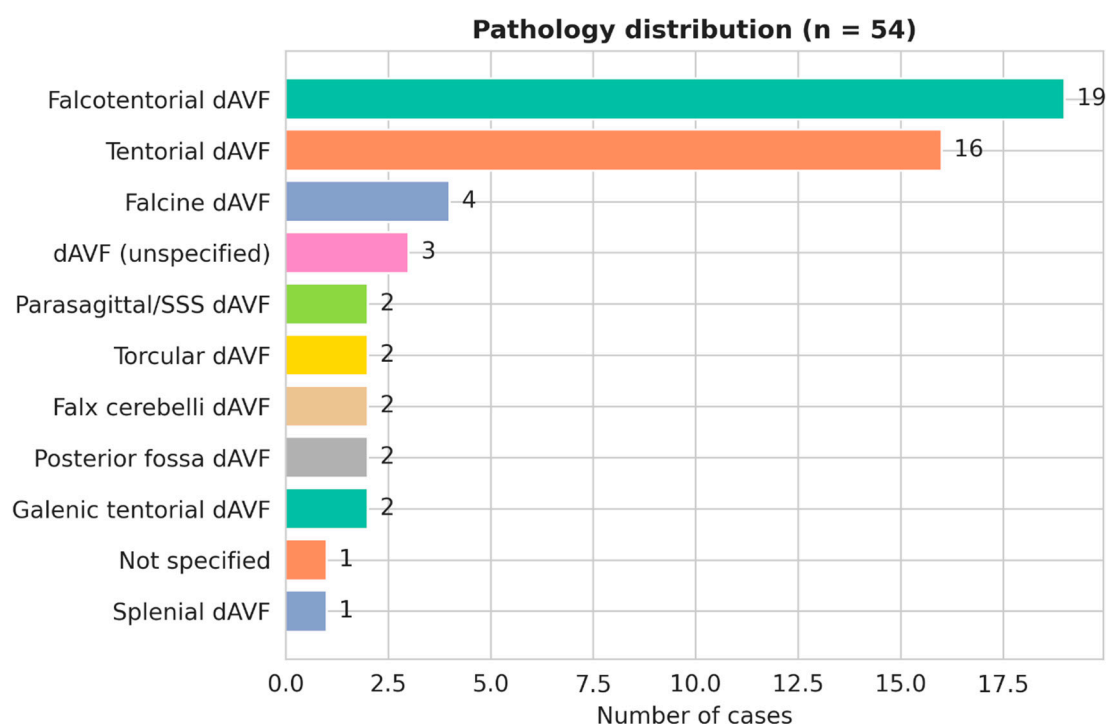


Figure 2. Distribution of ADS-associated pathologies (n = 54).

ADS laterality was left-sided in 19/54 (35.2%), right-sided in 16/54 (29.6%), and bilateral in 6/54 (11.1%), while 13/54 (24.1%) did not have laterality explicitly specified. When the PCA segment was reported (9/54; 16.7%), ADS arose most often from P2 (4 cases) or P1 (3 cases), with single cases from P1-PCoM and P4 segments.

Management Strategies

Transarterial embolization was the most common treatment, used in 41 of 54 patients (75.9%). Surgery alone was reported in 3/54 (5.6%), transvenous embolization in 3/54 (5.6%), and solely conservative management (observation/medical) in 3/54 (5.6%), with no management reported in 3/54 (5.6%) and one "other/combined" strategy. The most commonly used materials were liquid embolics (Onyx/PHIL or n-BCA/glue) administered through MMA, OA, or ADS. Coils were also used in some transvenous or combination techniques (**Figure 3**).

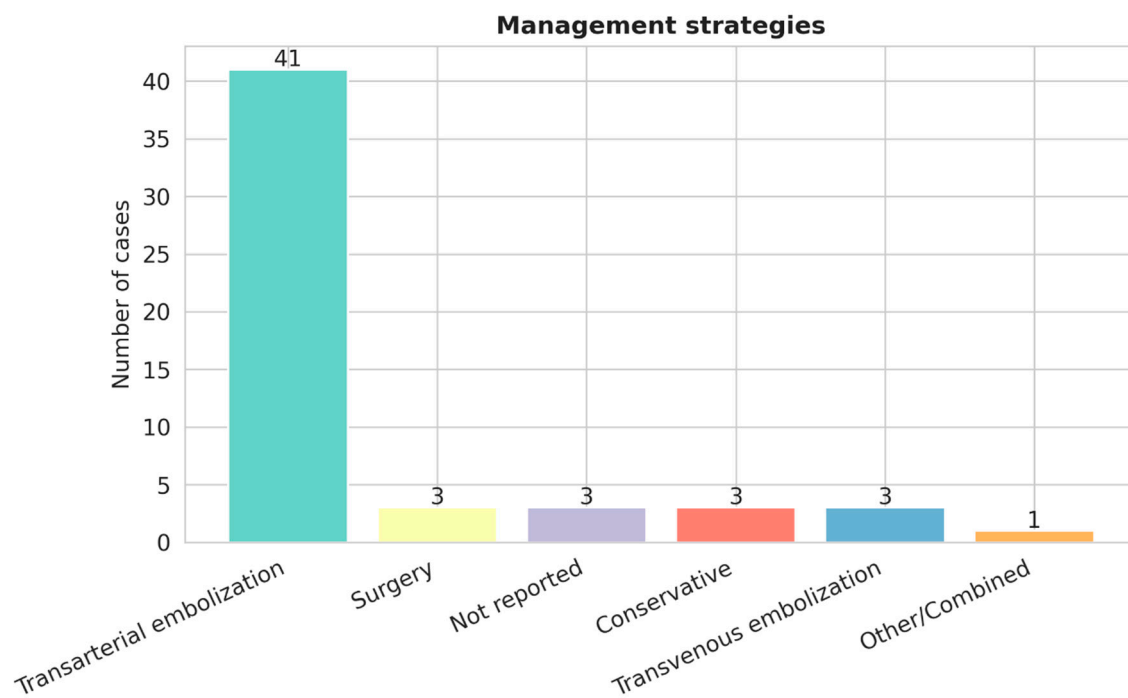


Figure 3. Management strategies used in ADS lesions (n = 54).

Complications

There were no complications reported in 43/54 subjects (79.6%). Major problems occurred in 8/54 (14.8%) cases, with infarction accounting for 4/54 (7.4%), including cerebellar or midbrain/thalamic events, as well as single occurrences of edema/brainstem compression, hydrocephalus/venous varix development, prolonged shunting, and other postoperative neurological impairments.

Outcomes

Positive outcomes were prevalent, with complete recovery/angiographic obliteration in 24/54 (44.4%) and clinical improvement in 11/54 (20.4%), resulting in favorable outcomes in 35/54 (64.8%). Residual neurological deficit was present in 4/54 (7.4%), residual symptoms in 1/54 (1.9%), and one patient (1.9%) died as a result of edema and brainstem compression following embolization. In the remaining cases, the outcomes were classified as "other," "stable," "rehabilitation," or "not reported" (2/54, 1/54, 1/54, and 9/54). Residual flow without apparent clinical worsening was observed in 3/54 (5.6%) (**Figure 4**).

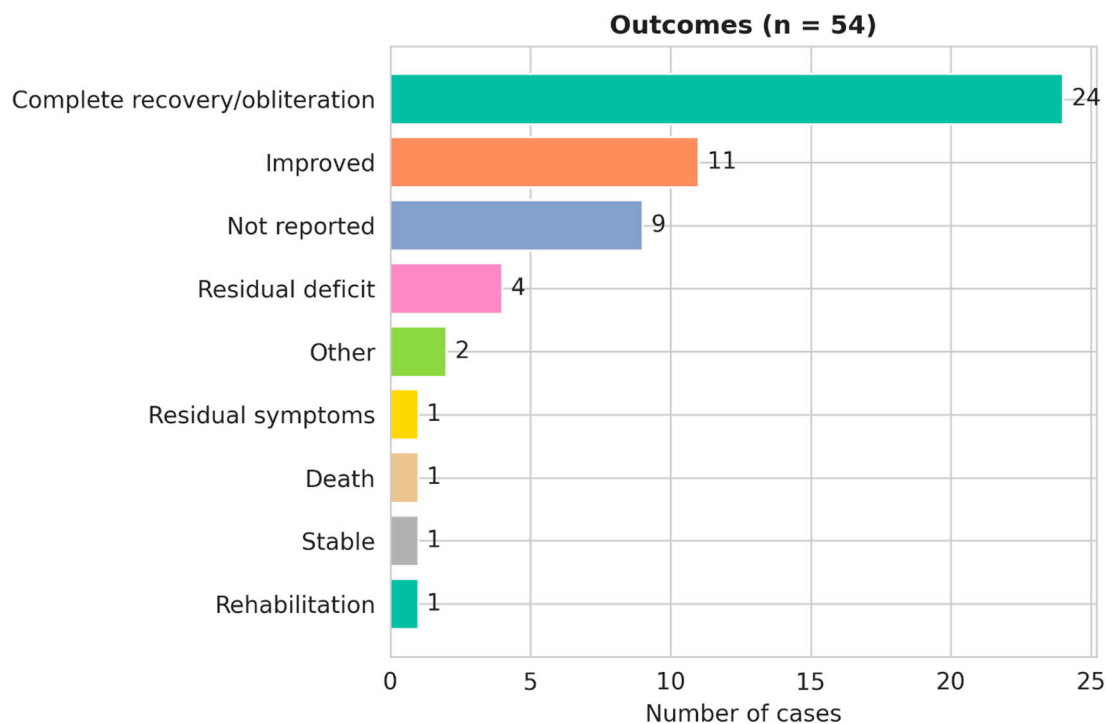


Figure 4. Clinical outcomes following management of ADS lesions (n = 54).

Discussion

In this systematic review of ADS, we compiled 54 reported clinical patients in various articles published between 1974 to 2025 and summarized presentation, lesion spectrum, management, complications, and outcomes. The most common ADS involvement occurs in tentorial/falcotentorial dural shunts, treatment is predominantly transarterial embolization, and clinically meaningful ischemic complications are common.

Anatomy and Variants

The ADS typically arises from the P2 segment, with P1 variants reported, courses through the ambient cistern near the SCA and trochlear nerve and then reaches the tentorium/falcotentorial junction (Bhagal et al., 2015; Byrne & Garcia, 2013; Griessenauer et al., 2013) (**Figure 5**). In our extracted clinical cases, laterality was left at 35.2%, right at 29.6%, and bilateral at 11.1%, with laterality not specified in 24.1%. Segment-level reporting was limited 16.7%, but when specified, P2 and P1 predominated, which matters because proximal origin and pial–dural connections can increase the consequence of reflux during liquid embolization. The previous literatures also highlights a related tentorial dural branch arising from the SCA and ongoing debate about whether it represents an ADS variant or a distinct artery (Atallah et al., 2024; Day & Dacey, 2026; Krafft et al., 2018). Practically, careful angiographic confirmation is necessary because “posterior circulation dural supply” in the tentorial region may be heterogeneous, and misidentification can affect both strategy and risk.

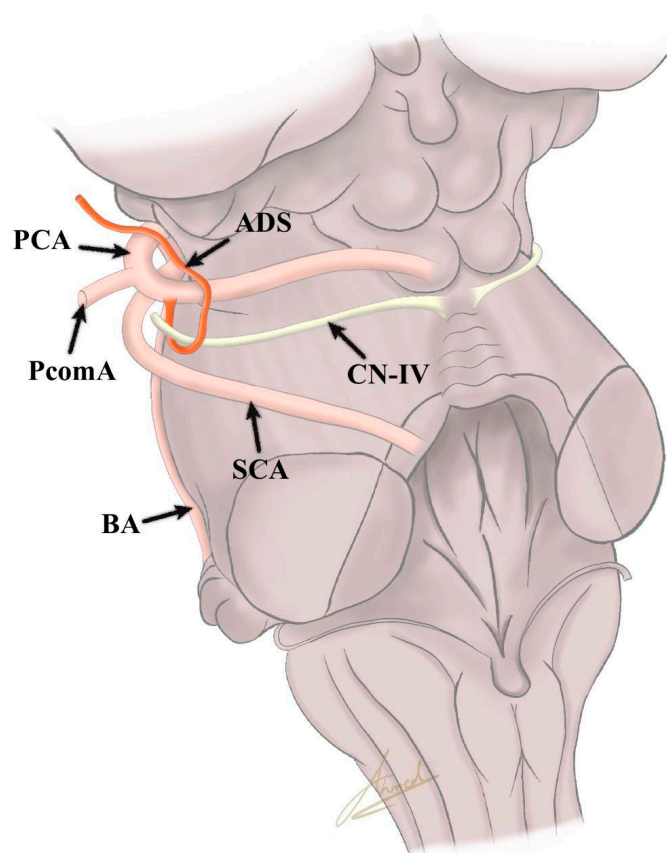


Figure 5. An artistic depiction showing the artery of Davidoff and Schechter (ADS). PcomA: posterior communicating artery; BA: basilar artery; PCA: posterior cerebral artery; SCA: superior cerebellar artery; CV-IV: trochlear nerve.

Clinical Presentation and Lesion

Clinical presentation was nonspecific and heterogeneous. These support the need for suspicion based on lesion location and venous drainage, not only symptoms. Headache was the most frequent symptom (44.4%), followed by altered consciousness (11.1%). Hemorrhagic presentation was documented in 5.6% and seizures in 3.7%, which is consistent with prior observations that tentorial/falcotentorial dAVFs may present with venous congestion or hemorrhage (Gioppo et al., 2017; Puri, 2010; Serulle et al., 2016). The pathology distribution of case clustered strongly in the tentorial–falcotentorial region. Falcotentorial dAVF (35.2%) and tentorial dAVF (29.6%) are major, with smaller contributions from falcine, parasagittal/SSS, torcular, posterior fossa, and Galenic tentorial entities. This statistic aligns with the ADS vascular territory at the falcotentorial junction and posterior tentorium. Which is commonly involved in high-grade tentorial fistulas recognized to have increased bleeding propensity compared with non-tentorial dAVFs (HIRAMATSU et al., 2014; Roman et al., 2022).

Angiographic Detection and Imaging

ADS may only become apparent when enlarged by pathological shunting or tumor recruitment, making DSA central for confirmation and treatment planning (Bhatia et al., 2020). Prior

research emphasized the high-quality angiography (including 3D rotational angiography and careful evaluation of pial–dural connections) to distinguish ADS supply from nearby pial branches and to avoid inadvertent embolization of eloquent posterior circulation (Bhatia et al., 2020; Day & Dacey, 2026). This is important when a meningeal supply arises from the PCA P1 region (e.g., collicular artery variants) because misclassification can increase ischemic/hemorrhagic risk during endovascular therapy (Day & Dacey, 2026).

Treatment Patterns, Risks and Outcomes

In our study, trans-arterial embolization was the most common treatment (75.9%), surgery, transvenous embolization and conservative management were each reported in 5.6%. Overall outcomes were favorable in majority cases, with complete recovery/angiographic obliteration in 44.4% and clinical improvement in 20.4%, yielding good outcomes in 64.8%. However, major complications (14.8%), and ischemic infarction (7.4%), indicate ADS-access routes can be effective but are not benign. These complications are consistent with the concern regarding reflux of liquid embolic material or unintended passage into intradural posterior circulation through pial–dural connections. This can produce brainstem/thalamic/cerebellar ischemia (Roman et al., 2022; Sugiyama et al., 2022). Several authors recommend strategies to reduce reflux risk, including preferential embolization from non-ADS feeders when feasible, the use of reflux-control techniques such as the pressure-cooker technique, and avoidance of ADS embolization when adequate distal purchase cannot be achieved (Bhatia et al., 2020; Woo et al., 2022). For falcine/tentorial targets, meticulous microcatheter navigation and superselective angiography are repeatedly emphasized to confirm separation from eloquent parenchymal branches and to support safe parent-branch sacrifice when required (Fry et al., 2022; Sugiyama et al., 2022). Beyond dAVFs, ADS recognition can alter management of hypervascular tumors and rare aneurysms in the region. Preoperative embolization of an enlarged ADS feeder has been reported as an adjunct in falcine meningioma resection (Hart et al., 2011), and ADS aneurysms often described with coexisting tentorial dAVF. This may require parent vessel sacrifice after confirming that eloquent branches are not involved (Fry et al., 2022; Yanai et al., 2024).

Limitations and Future Directions

Our study, which used case reports and small series, may have publication bias. The study does have findings regarding optimal strategy or predictors of complications. Many of our target variables were regularly absent. The study limits comparisons based on anatomy, technique, or lesion subtype. Future research would benefit from our reporting of ADS origin/segment, laterality, dural connections, venous drainage pattern, and embolic agent approach (including reflux-control). Our findings will also assist clinicians in improving comparability and better defining risk.

Conclusions

The ADS is a major feeder in tentorial and falcotentorial dural arteriovenous fistulas, with less involvement in other posterior falcine/tentorial vascular diseases. Transarterial embolization was the most common therapeutic technique; overall results were positive, although clinically significant problems were recorded. Thus, therapy via posterior circulation dural branches necessitates enhanced technique and risk awareness. When using liquid embolic agents, accurate angiographic identification is important for safe endovascular or microsurgical planning and reducing reflux-related harm.

Ethics approval: Ethics approval is not applicable.

Consent to Participate: No original data from new patients were collected, consent to participate is not applicable.

Consent for Publication: Consent for publication is not applicable.

Acknowledgments: Not Applicable.

Funding: The authors declare that no funds, grants, or other support were received during the preparation of this manuscript.

Conflicts of Interests: The authors have no relevant financial or non-financial interests to disclose.

Availability of Data and Material: Not Applicable.

References

1. Atallah, O., Wawi, O., Ergen, A., & Chaurasia, B. (2024). The artery of Wollschlaeger and Wollschlaeger. *Journal of Clinical Neuroscience*, 119, 151–154. <https://doi.org/10.1016/j.jocn.2023.11.030>
2. Bhatia, K. D., Kortman, H., Wälchli, T., Radovanovic, I., Pereira, V. M., & Krings, T. (2020). Artery of Davidoff and Schechter Supply in Dural Arteriovenous Fistulas. *American Journal of Neuroradiology*, 41(2), 300–304. <https://doi.org/10.3174/ajnr.A6380>
3. Bhogal, P., Makalanda, H. L., Brouwer, P. A., Gontu, V., Rodesch, G., Mercier, P., & Söderman, M. (2015). Normal pio-dural arterial connections. *Interventional Neuroradiology*, 21(6), 750–758. <https://doi.org/10.1177/1591019915609137>
4. Byrne, J. V., & Garcia, M. (2013). Tentorial Dural Fistulas: Endovascular Management and Description of the Medial Dural-Tentorial Branch of the Superior Cerebellar Artery. *American Journal of Neuroradiology*, 34(9), 1798–1804. <https://doi.org/10.3174/ajnr.A3519>
5. Carnevale, J. A., Goldberg, J., & Knopman, J. (2022). Lateral Variant of Davidoff and Schechter Dural Arteriovenous Fistula. *World Neurosurgery*, 157, 166–169. <https://doi.org/10.1016/j.wneu.2021.09.135>
6. Choudhri, O., & Marks, M. P. (2014). Endovascular treatment of a tentorial dural arteriovenous fistula. *Neurosurgical Focus*, 37(v1supplement), 1. <https://doi.org/10.3171/2014.V2.FOCUS14184>
7. Day, A. L., & Dacey, R. G. (2026). Perimesencephalic hemorrhage: a proposed explanation of its cause and clinical manifestations. *Journal of Neurosurgery*, 144(3), 740–746. <https://doi.org/10.3171/2025.7.JNS251343>
8. Fry, L., De Stefano, F. A., Chatley, K. S., Lei, C., Peterson, J., & Ebersole, K. (2022). Ruptured aneurysm of the artery of Davidoff and Schechter: illustrative case. *Journal of Neurosurgery: Case Lessons*, 4(17). <https://doi.org/10.3171/CASE22361>
9. Ghorbani, M., Rahbarian, F., & Lafta, G. A. (2021). The microsurgical management of a brainstem compression resulted from an embolized cerebral tentorial dural arteriovenous fistula. *Interdisciplinary Neurosurgery*, 23, 100998. <https://doi.org/10.1016/j.inat.2020.100998>
10. Gioppo, A., Faragò, G., Caldiera, V., Caputi, L., Cusin, A., & Ciceri, E. (2017). Medial Tentorial Dural Arteriovenous Fistula Embolization: Single Experience with Embolic Liquid Polymer SQUID and Review of the Literature. *World Neurosurgery*, 107, 1050.e1-1050.e7. <https://doi.org/10.1016/j.wneu.2017.08.050>
11. Golub, D., Lynch, D. G., Mehta, S. H., Donaldson, H., Shah, K. A., White, T. G., Quach, E. T., Papadimitriou, K., Kuffer, A. F., Woo, H. H., Link, T. W., Patsalides, A., & Dehdashti, A. R. (2024). The role of surgical disconnection for posterior fossa pial arteriovenous fistulas and dural fistulas with pial supply: an illustrative case series. *Neurosurgical Review*, 47(1), 189. <https://doi.org/10.1007/s10143-024-02407-y>
12. Griessenauer, C. J., Loukas, M., Scott, J. A., Tubbs, R. S., & Cohen-Gadol, A. A. (2013). The artery of Davidoff and Schechter: an anatomical study with neurosurgical case correlates. *British Journal of Neurosurgery*, 27(6), 815–818. <https://doi.org/10.3109/02688697.2013.798856>

13. Hart, J. L., Davagnanam, I., Chandrashekar, H. S., & Brew, S. (2011). Angiography and selective microcatheter embolization of a falxine meningioma supplied by the artery of Davidoff and Schechter. *Journal of Neurosurgery*, 114(3), 710–713. <https://doi.org/10.3171/2010.4.JNS10218>
14. HIRAMATSU, M., SUGIU, K., HISHIKAWA, T., HARUMA, J., TOKUNAGA, K., DATE, I., KUWAYAMA, N., & SAKAI, N. (2014). Epidemiology of Dural Arteriovenous Fistula in Japan: Analysis of Japanese Registry of Neuroendovascular Therapy (JR-NET2). *Neurologia Medico-Chirurgica*, 54(1), 63–71. <https://doi.org/10.2176/nmc.st.2013-0172>
15. Indo, M., Oya, S., Kakuda, N., Tanaka, M., & Nemoto, S. (2025). Anomalous Origin of the Artery of Davidoff and Schechter Confirmed in a Case of Dural Arteriovenous Fistula of the Superior Sagittal Sinus. *Cureus*. <https://doi.org/10.7759/cureus.82262>
16. Islak, C., Bagcilar, O., Nacar Dogan, S., Korkmazer, B., Arslan, S., Kizilkilic, O., & Kocer, N. (2022). Endovascular management of anterior falcotentorial dural arteriovenous fistulas: importance of functionality of deep venous system and existence of accompanying choroidal arteriovenous malformation. *Journal of NeuroInterventional Surgery*, 14(6), 599–604. <https://doi.org/10.1136/neurintsurg-2021-017730>
17. Krafft, P. R., Liu, S. S., Agarwalla, P. K., & Van Loveren, H. R. (2018). The meningeal branch of the superior cerebellar artery. *British Journal of Neurosurgery*, 32(3), 273–275. <https://doi.org/10.1080/02688697.2017.1416066>
18. Lucas, S. J., Bready, E., Banks, C. A., Gaillard, W. F., Beck, A. W., & Spangler, E. (2023). Accidental central venous catheter cannulation into aberrant arterial anatomy requiring endovascular intervention. *Journal of Vascular Surgery Cases, Innovations and Techniques*, 9(3), 101164. <https://doi.org/10.1016/j.jvscit.2023.101164>
19. Puri, A. S. (2010). Dural arteriovenous fistula supplied by the artery of Davidoff and Schechter. *Radiology Case Reports*, 5(2), 375. <https://doi.org/10.2484/rcr.v5i2.375>
20. Puri, A. S. (2015). Dural arteriovenous fistula supplied by the artery of Davidoff and Schechter. *Radiology Case Reports*, 5(2). <https://doi.org/10.2484/rcr.v5i2.375>
21. Rezende, M. T. S., Trivelato, F. P., de Castro-Afonso, L. H., Nakiri, G. S., Silva, C. C. M., Abud, T. G., Colli, B. O., Ulh a, A. C., & Abud, D. G. (2021). Endovascular Treatment of Tentorial Dural Arteriovenous Fistulas Using the Transarterial Approach as a First-Line Strategy. *Operative Neurosurgery (Hagerstown, Md.)*, 20(5), 484–492. <https://doi.org/10.1093/ons/opaa477>
22. Roman, N. I. S., Rodriguez, P., Nasser, H., Cox, M., Ramchand, P., Choudhri, O., Satti, S. R., Kung, D., Pukenas, B., & Hurst, R. W. (2022). Artery of Davidoff and Schechter: A Large Angiographic Case Series of Dural AV Fistulas. *The Neurohospitalist*, 12(1), 155–161. <https://doi.org/10.1177/19418744211022217>
23. Serulle, Y., Miller, T. R., & Gandhi, D. (2016). Dural Arteriovenous Fistulae. *Neuroimaging Clinics of North America*, 26(2), 247–258. <https://doi.org/10.1016/j.nic.2015.12.003>
24. Shi, Y., Liu, P., Liu, Y., Quan, K., Tian, Y., & Zhu, W. (2022). A falcotentorial dural arteriovenous fistula presented as carotid cavernous fistula clinically treated by transarterial embolization: case report. *Chinese Neurosurgical Journal*, 8(1), 41. <https://doi.org/10.1186/s41016-022-00309-w>
25. Su, X., Shang, Z., Li, X., Song, Z., Ye, M., Sun, L., Hong, T., Ma, Y., Zhang, H., & Zhang, P. (2024). Dural arteriovenous fistulas in the falx cerebri: case series and literature review. *Neurosurgical Review*, 47(1), 303. <https://doi.org/10.1007/s10143-024-02544-4>
26. Sugiyama, T., Tajima, Y., Yoshida, Y., Ishikura, T., & Iwadata, Y. (2022). Transarterial embolization for falx dural arteriovenous fistula through the artery of Davidoff and Schechter: A case report. *Radiology Case Reports*, 17(3), 700–705. <https://doi.org/10.1016/j.radcr.2021.12.013>
27. Weinstein, M., Stein, R., Pollock, J., Stucker, T. B., & Newton, T. H. (1974). Meningeal branch of the posterior cerebral artery. *Neuroradiology*, 7(3), 129–131. <https://doi.org/10.1007/BF00344317>
28. Woo, S.-B., Kim, J.-H., Kwon, M.-Y., & Lee, C.-Y. (2022). Anatomical safety and precaution of transarterial embolization of a falcotentorial dural arteriovenous fistula fed by the artery of Davidoff and Schechter: Case report and review of the literature. *Journal of Cerebrovascular and Endovascular Neurosurgery*, 24(3), 281–290. <https://doi.org/10.7461/jcen.2022.E2021.09.004>

29. Yanai, K., Fujii, G., Kawamura, S., Matsubishi, A., Naemura, K., Koizumi, S., & Yoshikawa, G. (2024). Transarterial embolization with n-butyl-2-cyanoacrylate for a ruptured aneurysm at the artery of Davidoff and Schechter. *Radiology Case Reports*, 19(6), 2268–2271. <https://doi.org/10.1016/j.radcr.2024.02.063>
30. Zhang, J., Lv, X., Jiang, C., Li, Y., & Wu, Z. (2010). Superior cerebellar artery infarction in endovascular treatment for tentorial dural arteriovenous fistulas. *European Journal of Radiology*, 74(3), e33–e37. <https://doi.org/10.1016/j.ejrad.2009.03.048>

Disclaimer/Publisher's Note: The statements, opinions and data contained in all publications are solely those of the individual author(s) and contributor(s) and not of MDPI and/or the editor(s). MDPI and/or the editor(s) disclaim responsibility for any injury to people or property resulting from any ideas, methods, instructions or products referred to in the content.