

Article

Protective effects of icariin on nicotine-induced reproductive toxicity in male mouse

Guochao Ni¹, Xuhui Zhang², Seth Yaw Afedo¹ and Rong Rui^{1*}

¹ Department of Clinical Veterinary Medicine, College of Veterinary Medicine, Nanjing Agricultural University, Jiangsu, P.R. China

² Co-Innovation Center for Sustainable Forestry in Southern China, College of Forestry, Nanjing Forestry University, Nanjing, P. R. China

* Correspondence: rrui@njau.edu.cn

Abstract: Nicotine is a pharmacologically active component of tobacco which adversely affects the male reproductive system and fertility and Icariin (ICA) is the main active ingredient of Epimedium herba which has been used to treat several male reproductive problems. This study was aimed at investigating the protective or ameliorative effect of ICA against reproductive toxicity induced by intraperitoneal injection of nicotine in mice. Forty male mice were randomly divided into 4 groups: control, nicotine (0.75 mg/kg intraperitoneally), icariin (ICA, 75 mg/kg), and icariin plus nicotine (ICA + nicotine) group. After 35 days of treatment, the mice were weighed, sacrificed, and their reproductive organs were collected and examined for further studies. In the nicotine-treated group, epididymal sperm density and serum testosterone concentrations significantly decreased relative to the control group. Nicotine also caused oxidative damage as shown by significant reduction in the activities of antioxidant enzymes and an elevation in Malondialdehyde (MDA) levels. Icariin on the other hand, improved the reduction in sperm characteristics, hormone levels, and activities of antioxidant enzymes alterations observed in the nicotine treated mice. These findings indicate that the nicotine-induced reproductive toxicity and oxidative damages on male reproductive tissues can be effectively attenuated by icariin.

Keywords: Icariin, nicotine, sperm density, testosterone, antioxidant enzyme, male mice.

1. Introduction

Tobacco contains numerous compounds and nicotine is the most toxic component. For users of tobacco, nicotine plays a significant role in the development of cardiovascular disorders, pulmonary diseases, lung cancer, and many other diseases [1,2]. Nicotine has also been known to cause oxidative stress by inducing the generation of reactive oxygen species (ROS) in tissues [3]. In addition, it adversely affects the male reproductive system and fertility. Several reports have showed that nicotine adversely affects spermatogenesis, epididymal sperm count, motility, and the fertilizing potential of sperms [4]. Nicotine causes disturbances in the functions of Leydig cells, thus diminishing the production of testosterone [5].

Medicinal plants and their active ingredients have received greater attention as potential anti-peroxidative agents. Icariin, ($C_{33}H_{40}O_{15}$; molecular weight: 676.67) the main active flavonoid glucoside from *Epimedium herba* is associated with a wide range of pharmacological and biological activities, including anti-inflammatory, antidepressant, anti-tumor activity, antioxidant effect, estrogenic activity, cardiovascular protection, enhancement of bone healing and neuroprotection, immunoregulation, and improved sexual function [6-9]. Experiments on animals have shown that icariin improves erectile function when administered to aged male rats and icariin supplementation could elevate exercise endurance and possess protective effects on exercise-induced oxidative stress [10,11]. The testes contain an elaborate array of antioxidant enzymes and free radical scavengers to ensure that the twin spermatogenic and steroidogenic functions of this organ are not impacted by oxidative stress [12]. In addition, icariin has testosterone mimetic properties, testosterone assumes the lead role in both morphological development and reproductive function [13]. There are several separate reports on nicotine (as a cause of fertility problems in males) and icariin which has a role in enhancing male reproduction and fertility, but no studies on the effects of icariin on nicotine-induced reproductive toxicity have yet been reported. Therefore, this present study was designed to evaluate the possible protective effect of icariin against nicotine-mediated reproductive toxicity and on

oxidative stress in mice through assessment of reproductive function and activities of the main antioxidant enzymes. These results may also serve as a basis to investigate or examine the possible mechanisms through which icariin acts to exert protective or ameliorative effect on nicotine-mediated reproductive toxicity.

2. Results

2.1. Effect of icariin on body growth, testicular and epididymal weights

The body, testicular, and epididymal weights of all groups are provided in Table 1. Prior to the experiment, body weights of the mice were not significantly different among the groups (control, icariin, nicotine, and icariin plus nicotine). At the end of the treatment period, differences in body weight of the control group compared with the treatment groups were still not significant ($P>0.05$). However, the absolute weights of testis in icariin treated groups were significantly higher compared with the control group ($P<0.05$). Meanwhile, the absolute weights of the testis from the nicotine treated groups were lower compared with the control group, but was not statistically significant ($P>0.05$). The testicular index in icariin treated groups were significantly higher compared with the other groups ($P<0.05$), and the absolute and relative weights of epididymis in all groups were not statistically significant ($P>0.05$).

Table 1. Effects of icariin on body and reproductive organ weights and sperm density in the experimental mice

Groups	Initial Body Weight(g)	Final Body Weight(g)	Testicular weight(g)	Testicular index (mg/g)	Epididymal weight(g)	Epididymal index (mg/g)
Control	45.15±2.20 ^a	52.04±4.67 ^a	0.280±0.023 ^a	5.39±0.30 ^a	0.106±0.008 ^a	2.05±0.11 ^a
Nicotine	46.03±2.27 ^a	53.49±4.10 ^a	0.279±0.019 ^a	5.22±0.15 ^a	0.107±0.011 ^a	2.00±0.14 ^a
ICA	44.60±3.35 ^a	50.68±3.76 ^a	0.302±0.023 ^b	5.97±0.39 ^b	0.104±0.007 ^a	2.05±0.13 ^a
ICA+Nicotine	44.13±2.56 ^a	52.09±5.01 ^a	0.288±0.021 ^{ab}	5.56±0.45 ^{ab}	0.105±0.008 ^a	2.02±0.11 ^a

Values are expressed as means ± S.D. Values not sharing a common superscript differ significantly at $P<0.05$.

2.2. Effects of icariin on testicle morphology

Figure 1 shows representative photomicrographs of the testes from the different groups. The seminiferous tubule basement membrane was continuous and complete, and the germ cells had normal morphology and regular arrangement. More primary spermatocytes were observed in the nicotine treated group whereas early spermatid were more observed in icariin treated group than the other groups.

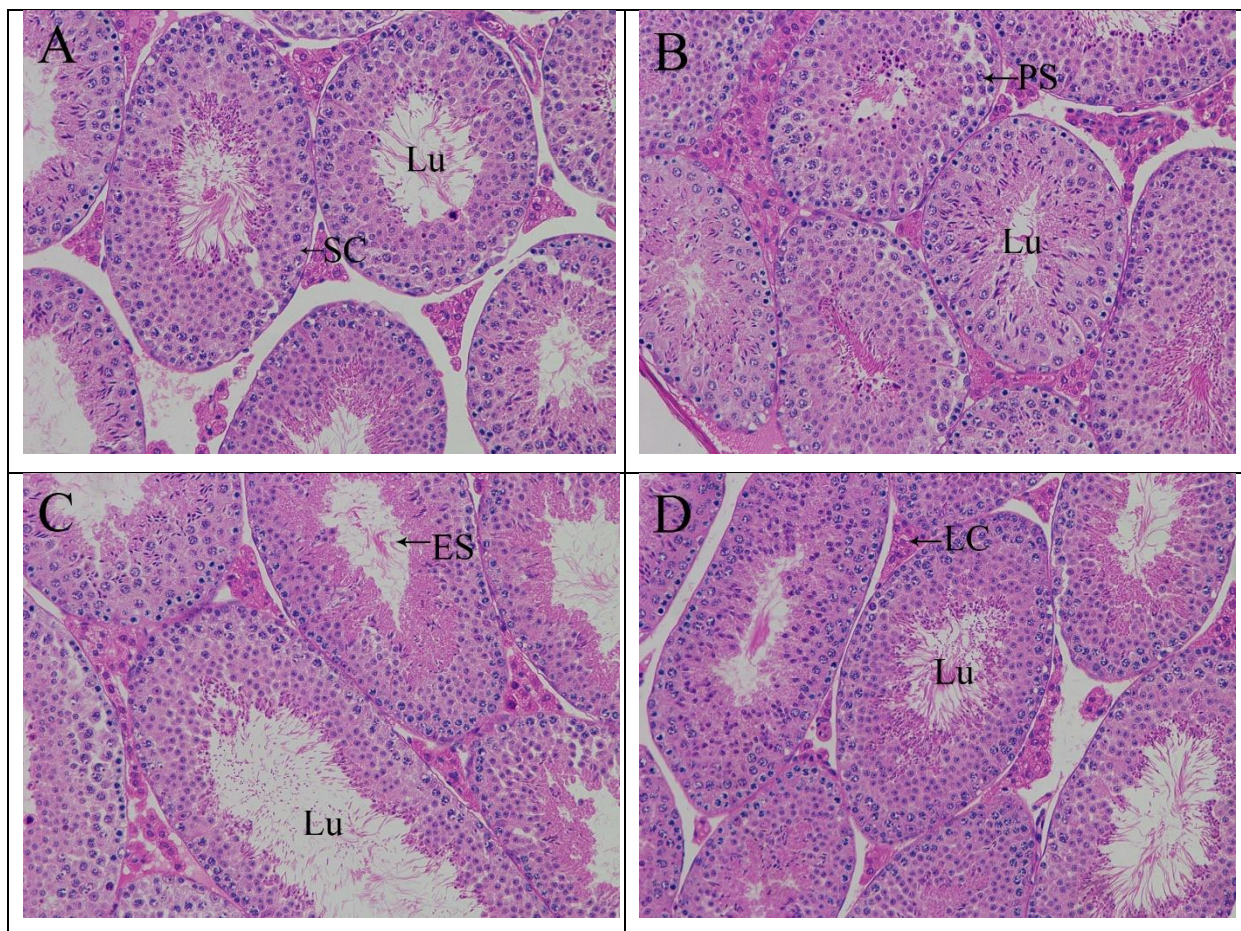


Figure 1. Haematoxylin and eosin stained sections of testes in different treatment group ($\times 200$). (A)

Control, (B) 0.75 mg/kg Nicotine, (C) 75 mg/kg Icariin, (D) 0.75 mg/kg Nicotine plus 75 mg/kg Icariin.

Lu, lumen; Sc, Sertoli cells; Lc, Leydig cells; PS, primary spermatocyte; ES, early spermatid.

2.3. Effects of icariin on epididymal sperm density

In the nicotine treated group, sperm density in the epididymis was significantly lower than in the control group ($P < 0.05$) as shown in Figure 2. However, icariin and icariin plus nicotine treatments

caused significant increase in sperm count, and epididymal sperm density compared with the control group ($P<0.05$).

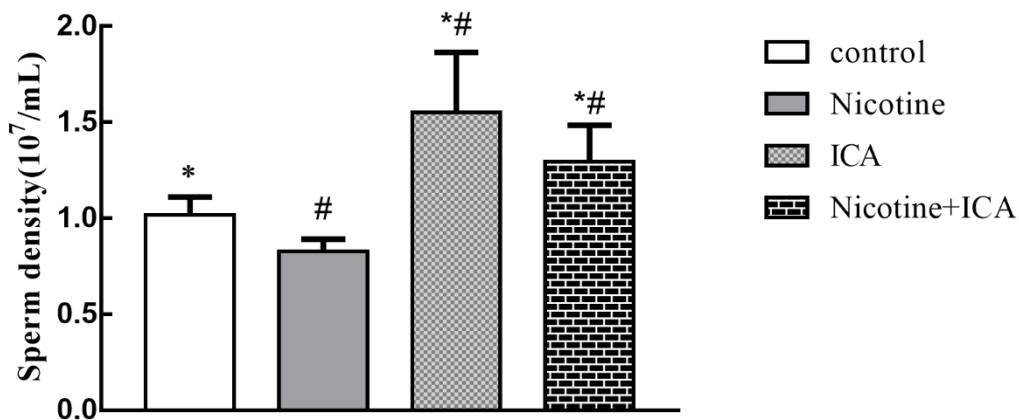


Figure 2. Effects of nicotine and ICA on epididymal sperm density in the control and treatment groups.

#: $P < 0.05$ vs. control mice; *: $P < 0.05$ vs. nicotine treated rats.

2.4. Effects of icariin on serum testosterone concentration

In the present study, serum testosterone concentration in the nicotine group were significantly lower than in the control group ($P<0.05$). As shown in Table 2, icariin treated group and icariin plus nicotine-treated group had significantly higher serum testosterone compared with the control group ($P<0.05$).

Table 2. Testicular tissue SOD, GPx activities and MDA level, and serum testosterone levels

Groups	SOD (U/mg protein)	GPx (U/mg protein)	MDA (nmol/g protein)	Testosterone (ng/ml)
Control	159.35±8.15 ^a	23.26±2.72 ^a	3.97±0.45 ^a	0.341±0.057 ^a
Nicotine	147.34±7.38 ^b	22.83±1.46 ^{ac}	4.63±0.67 ^b	0.273±0.035 ^b
ICA	175.79±9.03 ^c	26.74±1.95 ^b	3.23±0.61 ^c	0.675±0.105 ^c
ICA+ Nicotine	169.55±4.19 ^c	24.13±3.12 ^{ab}	3.82±0.57 ^a	0.494±0.065 ^d

SOD: superoxide dismutase; GPx: glutathione peroxidase; MDA: malondialdehyde. All data was expressed in mean ± SD; Values not sharing a common superscript differ significantly at $P<0.05$.

2.5. Effects of icariin on MDA levels, activities of SOD, and GPx in mice testis

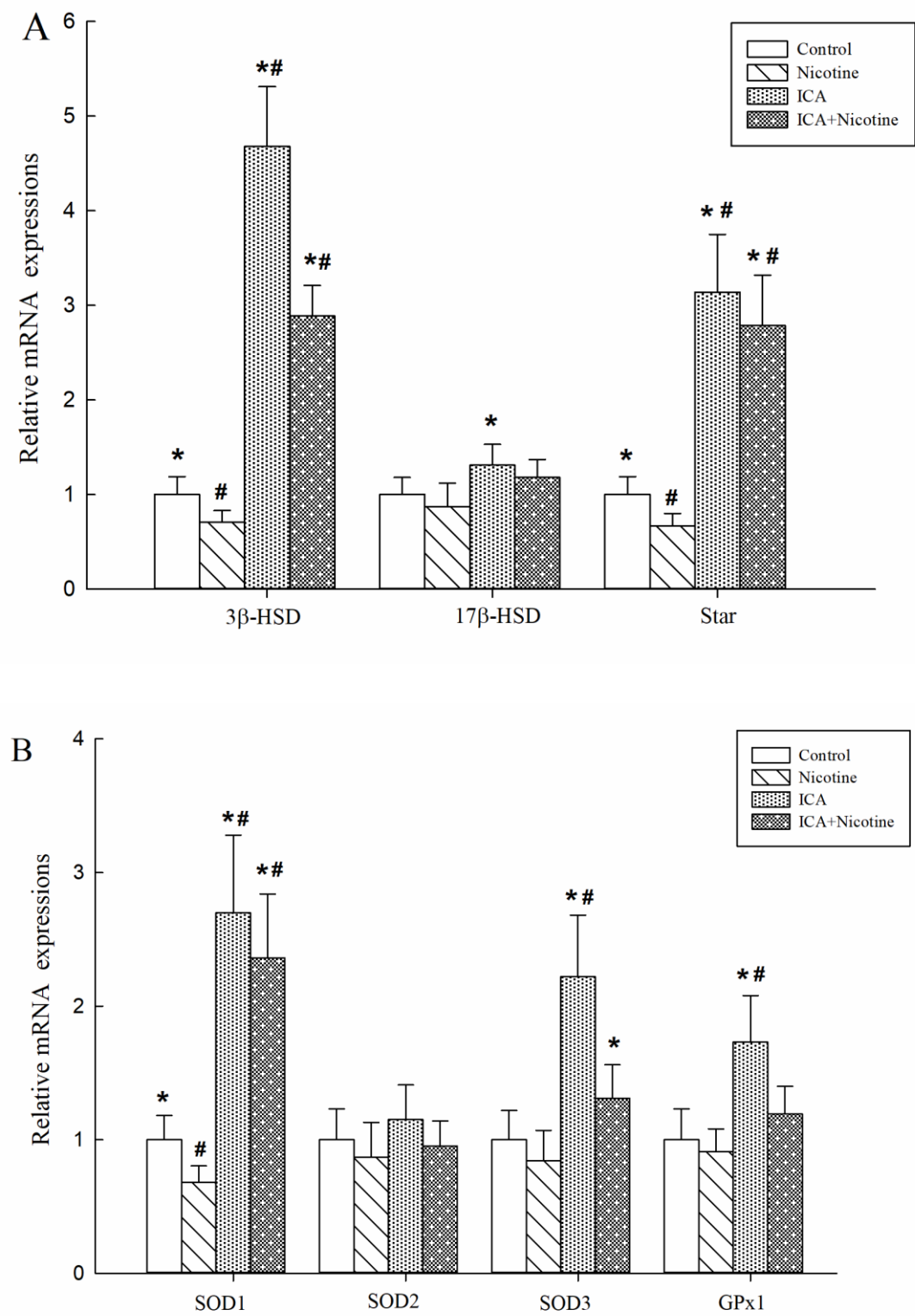
The activities of Superoxide dismutase (SOD) in the nicotine group were significantly lower than in the control group ($P<0.05$). The activities of SOD in icariin group and icariin plus nicotine-treated group were significantly higher than that of the control group ($P<0.05$). Also, the activities of glutathione peroxidase (GPx) in the icariin group were significantly higher than that of the control group and nicotine treated groups ($P<0.05$). However, the activities of GPx in the nicotine group were lower than in the control group but was not statistically significant ($P>0.05$). The concentration of MDA in nicotine group were significantly higher than in the control group ($P>0.05$). Furthermore, the concentration of MDA in icariin group were significantly lower than that of the control group ($P>0.05$; Table 2).

2.6. Effects of icariin on mRNA expression levels of steroidogenic genes and antioxidant genes in mice testis

The mRNA expressions of 3β -HSD, StAR in testicular tissue in the nicotine-treated group significantly decreased compare to the control group. However, the mRNA expressions of 3β -HSD, StAR in the ICA-treated group and ICA plus nicotine group increased significantly compare with the control group and nicotine-treated group. Also, expression of 17β -HSD mRNA significantly increased in the ICA group when compared with the nicotine-treated group ($P<0.05$) (Figure 3A).

The mRNA expressions of SOD1 gene (which provides instructions for making superoxide dismutase) in testicular tissues significantly decreased in the nicotine-treated group compared with the control group, whereas the mRNA expressions of SOD1 and SOD3 in ICA-treated group and ICA plus nicotine-treated group increased significantly compared with the control group and the nicotine-treated group. Furthermore, the mRNA expressions of GPx1 in ICA-treated group increased significantly when compared with the control and nicotine-treated group ($P<0.05$) (Figure 3B).

Figure 3. Expressions of 3 β -HSD, 17 β -HSD, StAR, SOD1, SOD2, SOD3 and GPx1 mRNA in the testes of mice treated with different doses of icariin. The mRNA levels were normalized using β -actin mRNA as internal control. The mRNA levels of the control group were set as 1. #P<0.05 compared to the control group, *P<0.05 compared to the Nicotine-treated group.



3. Discussion

This study was conducted to evaluate the protective effects of ICA on reproductive toxicity induced by intraperitoneal injection of nicotine in male mice. The markedly decreased serum testosterone concentrations and epididymal sperm density observed in the nicotine treated mice in this study agrees with previous studies [18-20]. However, administration of nicotine and ICA together reversed these trends.

In the present study, intraperitoneal administration of nicotine at a dose of 0.75 mg/kg body weight/day for 35 days was carried out. The results of this study showed that nicotine administration had no significant effect on body weight, absolute, and relative testicular weight. This finding is different from that of the study conducted by Hasanzadeh et. al., who reported that exposures to nicotine significantly decreased body weight in mice [5], the differences in weight results could probably be due to the different doses of nicotine administered, the different duration of experiment, and the differences in age of experimental animals. In this study, serum testosterone concentrations and epididymal sperm density decreased markedly in nicotine treated mice. These effects agree with those previously reported [20-22]. ICA plus nicotine-treatment together caused a significant increase in serum testosterone level, and epididymal sperm density compared with the nicotine alone and the control group. Testosterone is essential for sexual differentiation, maintenance of spermatogenesis, and expression of male secondary sex characteristics [23]. Holdcraft reported that testosterone plays a leading role in both morphological development and reproductive function of the testis [13]; hence, the ability of ICA to increase serum testosterone level suggests a possible protective mechanism of ICA against nicotine-mediated reproductive toxicity.

Testicular 3β -HSD and 17β -HSD play a pivotal role in the biosynthesis of testosterone, which is a prerequisite for sperm production and maturation [24]. StAR transport of cholesterol across the mitochondrial membrane is generally considered the rate-limiting step in steroidogenesis [25]. So the production of testosterone might be affected when the mRNA expression levels of 3β -HSD, 17β -HSD

and StAR are up and down-regulated. The mRNA expression levels of 3β -HSD and StAR decreased following nicotine exposure, but the down-regulation tendencies of the 3β -HSD and StAR were reversed due to the co-treatment with ICA. This study suggests a possible mechanism of ICA in improving testosterone production through the evaluation of mRNA expression of steroidogenic genes.

There exist an elaborate array of antioxidant enzymes and free radical scavengers in the testes, and they ensure that the twin spermatogenic and steroidogenic functions of this organ is not impacted by oxidative stress [26]. These results are in agreement with previous studies [23,24]. In cells, the SOD enzyme rapidly converts superoxide anion ($O_2^{\bullet-}$) to less dangerous hydrogen peroxide (H_2O_2) so that GPx can decompose H_2O_2 to water [27,28]. The MDA is frequently used as key indicative index of tissue oxidative stress, which results from the free radical damage to membrane components of cells [29]. In our study, administration of nicotine caused testicular oxidative stress as evidenced by increased MDA levels and decreased activities of SOD enzymes in the testes. However, co-treatment with ICA significantly inhibited the elevated MDA level and SOD enzymes activity depletion in the testis as a result of the nicotine exposure. The results of this study demonstrate that ICA possessed antioxidative properties against nicotine induced oxidative damage.

It's well known that SOD serves as an important antioxidant defense against oxidative stress. Three forms of SOD; namely, SOD1, SOD2 and SOD3 are present in mammals. Furthermore, GPx1 is the most abundant selenoperoxidase and is a key antioxidant enzyme in various cell types [25,26]. In order to further explore the antioxidant effects of ICA, the activities of SOD and GPx were studied and changes in their activity levels in testicular tissues were analysed while, mRNA expressions of antioxidant genes such as SOD1, SOD2, SOD3, and GPx1 mRNA levels were detected through qRT-PCR experiments. The mRNA expressions of SOD1 in testicular tissue markedly decreased in nicotine treated group compared with the control, when co-treated with ICA, these down-regulation tendencies of SOD1 were efficiently reversed.

Materials and methods

4.1. Drugs and chemicals

Nicotine ditartrate was purchased from Adooq Bioscience Co., Ltd. (American) and Icariin from Ze Lang Co., Ltd. (Nanjing, China). The SYBR® PrimeScript® RT-PCR Kit (Perfect Real Time) was purchased from TaKaRa Biotech (Liaoning, China). SOD, GPx, and MDA assay kits were obtained from Jiancheng Bioengineering Institute (Nanjing, China), and testosterone (T) ELISA Kit from Abcam (England).

4.2. Animals and experimental design

All procedures and protocols involving animals were in accordance with the Animal Ethics Procedure and Guidelines of the People's Republic of China and the Guide for the Care and Use of Laboratory Animals. All animal procedures were also approved by the Institutional Animal Care and Use Committee (IACUC) of Nanjing Agricultural University with Permit No. 2018CB114306. Forty healthy male Kunming mice (8-week-old) were purchased from Beijing Vital River Laboratory Animal Technology Co., Ltd. with Permit No. SCXK-Jing 2016-0011 and used in this experiment. The mice were purchased 1 week prior to the study, and for the purposes of acclimatization, all mice were routinely raised in a clean area with normal room temperature and fed with standard mouse feed and ordinary water ad libitum.

The mice were randomly assigned to 4 groups; 10 mice per group. Group I served as the control group, mice assigned to this group received 0.35 mL physiological saline administered via gastric gavage. Group II mice were injected intraperitoneally with nicotine tartrate (dissolved in 0.9% physiological saline) at 0.75 mg/kg/day. Mice assigned to group III received icariin at 75 mg/kg/day administered through gastric gavage, and finally mice assigned to group IV were administered icariin at 75 mg/kg/day via gastric gavage, and then injected intraperitoneally with nicotine tartrate (dissolved in 0.9% physiological saline) at 0.75 mg/kg/day.

All the mice were administrated once a day for 35 consecutive days. The doses of nicotine corresponded to the daily nicotine intake in people who smoke 10-20 cigarette sticks per day [14]. The mice were weighed weekly to adjust the gavage or injection volume.

4.3. Collection of testes and epididymides

At the end of the treatment period, the mice were sacrificed by cervical dislocation. The testes and epididymides were quickly collected and weighed. The testes used for histopathological examination were kept in Bouin's fixatives to preserve normal morphology and facilitate further processing into paraffin blocks. Testes samples collected for assays of biochemical analysis and real-time PCR were snap-frozen in liquid nitrogen and stored at -80°C until further processing. The epididymides were used for sperm density analysis.

4.4. Epididymal sperm density

The left epididymis was used for sperm counting experiment. The epididymides were cut into small pieces after which epididymal spermatozoa were collected and immersed in 4 mL of human tubal fluid (HTF) in a Petri dish [15,16]. This was incubated in 5% CO_2 in air for 15 min at 37°C , and homogenization-resistant sperms were counted using a haemocytometer. The number of cells in at least 2 of the large corner squares (1 mm^2) were counted [17].

4.5. Histopathological examination

The right testis was fixed in Bouin's solution for 24 h and processed by standard histological procedures. Briefly, specimens were dehydrated in xylene and embedded in paraffin wax, 5 μm thick slices were cut from each sample onto a glass slide, and stained with haematoxylin-eosin (H&E) routinely. Changes in testicular morphology and structure were observed under the microscope.

4.6. Detection of serum testosterone

When treatment ended, blood samples were obtained by decapitation 8 h after fasting. The collected blood samples were centrifuged at $2,000 \times g$ for 10 min to separate the serum. The serum was

stored at -20°C for further analysis. The serum concentrations of testosterone were measured using a Radioimmunoassay (RIA) kits. All operations followed the protocols that came with the RIA kits.

4.7. Determination of SOD, GPx activity and MDA level

The testicular tissues stored at -80°C were homogenized at 4°C after adding pre-cooled 0.9% saline in the ratio of 1:9. When testicular tissues were disrupted, the homogenate was centrifuged at $3,000 \times g$ for 10 min at 4°C . The supernatant was used for assay involving SOD, GPx, and MDA according to the manufacturer's instructions.

4.8. Quantitative real-time PCR analysis

The expression levels of 3β -Hydroxysteroid dehydrogenase (3β -HSD), 17β -Hydroxysteroid dehydrogenase (17β -HSD), steroidogenic acute regulatory protein (StAR), cytoplasmic superoxide dismutase (SOD1), mitochondrial superoxide dismutase (SOD2), extracellular superoxide dismutase (SOD3) and Glutathione peroxidase 1 (GPx1) mRNA in testicular tissues were assessed by qRT-PCR. Primers (Table 3.) were produced at Shanghai Invitrogen Biotech Co. Ltd. Total RNA was extracted from the testicular tissues using Trizol reagent (from Invitrogen), and according to manufacturer's instructions. The quality and quantity of the RNA preps were determined by gel electrophoresis and the Nanodrop ND-1000 spectrophotometer (Nanodrop Technologies Inc., DE, USA). Each real-time PCR reaction was carried out in triplicate in a 20- μL reaction mixture (2 μL cDNA, 6.8 μL H_2O , 10 μL SYBR® Premix Ex Taq™, and 0.6 μL of each 10 μM forward and reverse primers). The PCR program was 30 s at 95°C followed by 40 cycles of 5 s at 95°C , 31 s at 60°C . A melting curve was generated at the end of every run to ensure product uniformity (95°C for 15 s, 60°C for 15s, 95°C for 15s). The relative expression of target genes was calculated using $2^{-\Delta\Delta\text{Ct}}$. PCR with β -actin as an internal control was carried out in the same tubes as the genes.

Table 3. Primer sequences used in real-time PCR

Genes	Forward primer	Reverse primer	Lengths of amplicons (bp)
β-actin	TACTGAGCTGCGTTTACACC	TCCTGAGTCAAAAGCGCCAA	177
3β-HSD	AGATAATCCTGAATGGCAACGA	TTTGCCCGTACAACCGAGA	245
17β-HSD	TGGGTGCTGTGTTGGATGTG	TGGCACAGTACACTTCGTGG	153
StAR	TGCGCTTAAATCTCCTAGCTC	TGGCTATCCTTCTGTGTAGACC	195
SOD1	AAGCGGTGAACCAGTTGTGT	CCGGGCCACCATGTTTCTTA	152
SOD2	AGGAGAGTTGCTGGAGGCTA	TAGTAAGCGTGCTCCCACAC	228
SOD3	GAGAAGATAGGCGACACGCA	GAGAACCAAGCCGGTGATCT	156
GPx1	ACAGTCCACCGTGTATGCC	CGTTCATCTCGGTGTAGTCCC	146

4.9. Statistical analysis

The results were expressed as the mean ± standard deviation (SD) of the mean and statistically analyzed by One-way analysis of variance (ANOVA) using SPSS Statistics Package 25 and differences between experimental groups were considered significant at $P<0.05$.

5. Conclusion

In conclusion, our results show adverse effects of nicotine on serum testosterone concentrations and epididymal sperm density. Nicotine-mediated reproductive toxicity in male mouse could be successfully treated with ICA, with characteristic actions such as increase secretion of androgen, antioxidant effects, and the suppression of oxidative stress. ICA prevented testicular oxidative stress, and decreased MDA levels in testis. These results and previous reports suggest that ICA with testosterone mimetic and antioxidant properties might be used as a therapeutic agent in cases of decreased sperm production and oxidative stress mediated by cigarette smoking.

Author Contributions: Conceptualization, N.G. and R.R.; methodology, N.G.; validation, R.R.; formal analysis, R.R.; investigation, N.G., Z.X., and A.S.Y.; resources, R.R.; data curation, N.G., Z.X and A.S.Y.;

writing—original draft preparation, N.G. and Z.X.; writing—review and editing, N.G. and A.S.Y.; visualization, N.G.; supervision, R.R.; project administration, R.R.; funding acquisition, R.R.

Funding: This work was supported by Natural Science Research of Jiangsu Higher Education Institutions of China (CN), China (17KJB230002) and the College of Science and Technology Plan of Jiangsu Polytechnic College of Agriculture and Forestry, China (2018kj16).

Declaration of interest: The authors declare no conflict of interest.

References

1. Mishra, A.; Chaturvedi, P.; Datta, S.; Sinukumar, S.; Joshi, P.; Garg, A., Harmful effects of nicotine. *Indian journal of medical and paediatric oncology : official journal of Indian Society of Medical & Paediatric Oncology* **2015**, 36, (1), 24-31.
2. Seema, P.; Swathy, S. S.; Indira, M., Protective effect of selenium on nicotine-induced testicular toxicity in rats. *Biological Trace Element Research* **2007**, 120, (1-3), 212-218.
3. Kalpana, C.; Sudheer, A. R.; Rajasekharan, K. N.; Menon, V. P., Comparative effects of curcumin and its synthetic analogue on tissue lipid peroxidation and antioxidant status during nicotine-induced toxicity. *Singapore Med J* **2007**, 48, (2), 124-130.
4. Oyeyipo, I. P.; Raji, Y.; Emikpe, B. O.; Bolarinwa, A. F., Effects of nicotine on sperm characteristics and fertility profile in adult male rats: a possible role of cessation. *Journal of reproduction & infertility* **2011**, 12, (3), 201-7.
5. Hasanzadeh, K. A.; Hasanzadeh, S.; Shalizar, J. A., Ameliorative effects of Achillea millefolium inflorescences alcoholic extract on nicotine-induced reproductive toxicity in male rat: Apoptotic and biochemical evidences. *Veterinary Research Forum* **2017**, 8, (2), 97-104.
6. Pozharitskaya, O. N.; Karlina, M. V.; Shikov, A. N.; Kosman, V. M.; Makarova, M. N.; Makarov, V. G., Determination of icariin in rat plasma by reverse-phase high-performance liquid chromatography after oral administration of a lipid-based suspension of Epimedium koreanum extract. *Biomedical Chromatography* **2008**, 22, (6), 625-629.
7. Pan, Y.; Kong, L.-D.; Li, Y.-C.; Xia, X.; Kung, H.-F.; Jiang, F.-X., Icariin from Epimedium brevicornum attenuates chronic mild stress-induced behavioral and neuroendocrinological alterations in male Wistar rats. *Pharmacology Biochemistry and Behavior* **2007**, 87, (1), 130-140.
8. Xin, H.; Zhou, F.; Liu, T.; Li, G.-Y.; Liu, J.; Gao, Z.-Z.; Bai, G.-Y.; Lu, H.; Xin, Z.-C., Icariin Ameliorates Streptozotocin-Induced Diabetic Retinopathy in Vitro and in Vivo. *International journal of molecular sciences* **2012**, 13, (1), 866-878.
9. Huang, Z.-S.; Xiao, H.-J.; Qi, T.; Hu, Z.-M.; Li, H.; Chen, D.-L.; Xu, Y.-L.; Chen, J., Antioxidative protective effect of icariin on the FeSO₄/H₂O₂-damaged human sperm based on confocal raman micro-spectroscopy. *Journal of Huazhong University of Science and Technology. Medical sciences = Hua zhong ke ji da xue xue bao. Yi xue Ying De wen ban = Huazhong keji daxue xuebao. Yixue Yingdewen ban* **2014**, 34, (5), 755-60.
10. QiaoPing, C.; Ping, W., Icariin Supplementation Protects Mice from Exercise-induced Oxidant Stress in Liver. *Food Science and Biotechnology* **2013**, 22, (5), 1409-1413.
11. Liu, T.; Xin, H.; Li, W.-R.; Zhou, F.; Li, G.-Y.; Gong, Y.-Q.; Gao, Z.-Z.; Qin, X.-C.; Cui, W.-S.; Shindel, A. W.; Xin, Z.-C., Effects of Icariin on Improving Erectile Function in Streptozotocin-Induced Diabetic Rats. *Journal of Sexual Medicine* **2011**, 8, (10), 2761-2772.
12. Aitken, R. J.; Roman, S. D., Antioxidant Systems and Oxidative Stress in the Testes. *Molecular Mechanisms in Spermatogenesis* **2008**, 636, 154-171.
13. Holdcraft, R. W.; Braun, R. E., Hormonal regulation of spermatogenesis. *International journal of andrology* **2004**, 27, (6), 335-342.

14. Paunovi, M. G.; Ognjanovi, B. I.; Mati, M. M.; tajn, A.; Sai?i, Z. S., Protective effects of quercetin and vitamin C against nicotine-induced toxicity in the blood of Wistar rats. *Arh Hig Rada Toksikol* **2016**, 67, (4), 304-310.
15. Yan, F. H.; Chen, Y. F.; Zuo, Z. H.; Chen, Y. X.; Yang, Z. M.; Wang, C. G., Effects of tributyltin on epididymal function and sperm maturation in mice. *Environ Toxicol Phar* **2009**, 28, (1), 19-24.
16. Goodson, S. G.; Qiu, Y. P.; Sutton, K. A.; Xie, G. X.; Jia, W.; O'Brien, D. A., Metabolic Substrates Exhibit Differential Effects on Functional Parameters of Mouse Sperm Capacitation. *Biology of Reproduction* **2012**, 87, (3).
17. Oliveira, H.; Spano, M.; Santos, C.; Pereira, M. D., Lead chloride affects sperm motility and acrosome reaction in mice. *Cell Biol Toxicol* **2009**, 25, (4), 341-353.
18. Salahipour, M. H.; Hasanzadeh, S.; Malekinejad, H., Ameliorative effects of Achillea millefolium inflorescences alcoholic extract against nicotine-induced reproductive failure in rat. *Experimental and toxicologic pathology : official journal of the Gesellschaft fur Toxikologische Pathologie* **2017**, 69, (7), 504-516.
19. Bisong, S. A.; Ukoh, I. E.; Nna, V. U.; Ebong, P. E., Vitamin E attenuates nicotine- and noise-induced reproductive impairment in male albino Wistar rats. *Andrologia* **2018**, e13050.
20. Mosbah, R.; Yousef, M. I.; Mantovani, A., Nicotine-induced reproductive toxicity, oxidative damage, histological changes and haematotoxicity in male rats: the protective effects of green tea extract. *Experimental and toxicologic pathology : official journal of the Gesellschaft fur Toxikologische Pathologie* **2015**, 67, (3), 253-9.
21. Oyeyipo, I. P.; Raji, Y.; Bolarinwa, A. F., Nicotine alters male reproductive hormones in male albino rats: The role of cessation. *Journal of human reproductive sciences* **2013**, 6, (1), 40-4.
22. Abd El-Aziz, G. S.; El-Fark, M. O.; Hamdy, R. M., Protective effect of Eruca sativa seed oil against oral nicotine induced testicular damage in rats. *Tissue & cell* **2016**, 48, (4), 340-8.
23. Payne, A. H.; Youngblood, G. L., Regulation of Expression of Steroidogenic Enzymes in Leydig-Cells. *Biology of Reproduction* **1995**, 52, (2), 217-225.
24. Priya, P. H.; Reddy, P. S., Effect of restraint stress on lead-induced male reproductive toxicity in rats. *Journal of experimental zoology. Part A, Ecological genetics and physiology* **2012**, 317, (7), 455-65.
25. Das, J.; Ghosh, J.; Manna, P.; Sil, P. C., Taurine protects rat testes against doxorubicin-induced oxidative stress as well as p53, Fas and caspase 12-mediated apoptosis. *Amino Acids* **2012**, 42, (5), 1839-1855.
26. Sujatha, R.; Chitra, K. C.; Latchoumycandane, C.; Mathur, P. P., Effect of lindane on testicular antioxidant system and steroidogenic enzymes in adult rats. *Asian Journal of Andrology* **2001**, 3, (2), 135-138.
27. Das, S.; Gautam, N.; Dey, S. K.; Maiti, T.; Roy, S., Oxidative stress in the brain of nicotine-induced toxicity: protective role of Andrographis paniculata Nees and vitamin E. *Applied Physiology Nutrition & Metabolism* **2009**, 34, (2), 124-135.
28. Oyeyipo, I. P.; Raji, Y.; Bolarinwa, A. F., Antioxidant profile changes in reproductive tissues of rats treated with nicotine. *Journal of human reproductive sciences* **2014**, 7, (1), 41-6.
29. Hong, Z.; Hailing, L.; Hui, M.; Guijie, Z.; Leyan, Y.; Dubing, Y., Effect of vitamin E supplement in diet on antioxidant ability of testis in Boer goat. *Anim Reprod Sci* **2010**, 117, (1-2), 90-4.