Preprints.org | NOT PEER-REVIEWED | Posted: 24 November 2026 https://doi.org/10.20944/preprints202611.2421.v1

Disclaimer/Publisher's Note: The statements, opinions, and data contained in all publications are solely those of the individual author(s) and contributor(s) and not of MDPI and/or the editor(s). MDPI and/or the editor(s) disclaim responsibility for any injury to people or property resulting from any ideas, methods, instructions, or products referred to in the content.

Concept Paper

From Phenotype to Endotype in Neuro-EDS: A Framework for Mechanistic Investigation and Precision Care—How Can Neuro-EDS Be Biologically Characterized, Mechanistically Understood, Objectively Evaluated, and More Precisely Treated?

Allison R. Bloom [1,*], Petra M. Klinge [2], Ilene S. Ruhoy [1], Fraser C. Henderson Sr. [3], John D. Heiss [4], Wouter I. Schievink [5], Ferdinand K. Hui [6], Kyle M. Fargen [7], Richard C. Hsu [8], Elizabeth Brooke Spencer [9], Jonathan Sisti [1], Peter C. Rowe [10], Anne Maitland [11], Zachary Spiritos [12], Linda Bluestein [13], Dacre Knight [14], Antonio Bulbena [15], Marco Ritelli [16], Marina Colombi [16], Nicola Chiarelli [16], Kimberly Agosto [1], Alba M. Azola [17], Christoph Bettag [18], John B. Biggins [1], Andrea Bulbena-Cabré [19], Travis Caton [1], Philippa Cheetham [20], Pradeep Chopra [21], Maritsa E. Christoforou [10], Craig Coleby [22], Hugo D. Critchley [23], Randall A. Dass [1], Jessica A. Eccles [24], Mansoor Foroughi [25], Joshi George [26], Vicenç Gilete [27], Stephanie L. Grach [28], Gerald A. Grant [29], Jeffrey P. Greenfield [30], Svetlana Blitshteyn [31], Edward Hepworth [32], Jaclyn Hunter [1], Valerie Rogers Iovine [33], Prajoy Kadkade [34], David Kaufman [35], Gad Klein [36], Myles Koby [37], Linda Leithe Gray [38], Frank Loth [39], Yelena Markovskaya [40], Alon Mogilner [41], Kevin Muldowney [42], Lauren Natbony [43], Misao Nishikawa [44], Phil Papadimas [1], Athos Patsalides [45], David Putrino [33], Prashanth Rao [46], Evan Ren [1], Veit Rohde [18], David Saperstein [47], Konstantina Svokos [2], Alexander M. Tucker [48], Justin Virojanapa [49], George Xipoleas [34], Tanvir Choudhri [50] and Paolo A. Bolognese [1,*]

[1] The Center for Neuro-EDS, Division of Neurosurgery, Mount Sinai South Nassau, Oceanside, NY, and Department of Neurosurgery, Icahn School of Medicine at Mount Sinai, New York, NY, USA
[2] Departments of Neurosurgery and Neuropathology, Rhode Island Hospital, The Warren Alpert Medical School of Brown University, Providence, RI, USA
[3] Department of Neurosurgery, University of Maryland School of Medicine - Director, The Metropolitan Neurosurgery Group, LLC, MD, USA
[4] Surgical Neurology Branch, National Institute of Neurological Disorders and Stroke, National Institutes of Health, Bethesda, MD 20892, USA
[5] Department of Neurosurgery, Cedars-Sinai, Los Angeles, CA, USA
[6] Neuroscience Institute, Queen's Medical Center, Honolulu, HI, USA
[7] Department of Neurological Surgery, Atrium Health Wake Forest Baptist, Winston-Salem NC, USA
[8] Stamford Health Medical Group Vascular Surgery, Stamford, CT, USA
[9] Minimally Invasive Procedure Specialists, Highlands Ranch, CO, USA
[10] Department of Pediatrics, Johns Hopkins School of Medicine, Baltimore, MD, USA
[11] Department of Medicine, Division of Rheumatology, Medical University of South Carolina, Charleston, SC, USA
[12] EverBetter Medicine, Raleigh, NC, USA
[13] Hypermobility MD, Littleton, CO, USA
[14] EDS and Hypermobility Disorders Center, UVA Health, Charlottesville, VA, USA
[15] Department of Psychiatry, Universitat Autònoma de Barcelona, Barcelona, Spain
[16] Department of Molecular and Translational Medicine, Universita' degli Studi di Brescia, Brescia, Italy
[17] Department of Physical Medicine and Rehabilitation, Johns Hopkins School of Medicine, Baltimore, MD
[18] Neurochirurgische Klinik, University of Göttingen, Göttingen, Germany
[19] Department of Psychiatry, Icahn School of Medicine at Mount Sinai, New York, NY, USA
[20] Department of Urology, Icahn School of Medicine at Mount Sinai, New York, NY, USA

© 2026 by the author(s). Distributed under a Creative Commons CC BY license.

Preprints.org | NOT PEER-REVIEWED | Posted: 24 November 2026 https://doi.org/10.20944/preprints202611.2421.v1

[21] The Center for Complex Conditions, Pain Medicine, Brown Medical School, Providence, RI. USA
[22] Granger Medical Clinic, Riverton, UT, USA
[23] Department of Psychiatry, Brighton and Sussex Medical School, Brighton, UK
[24] Department of Neuroscience, Brighton and Sussex Medical School, Brighton, UK
[25] Department of Neurosurgery, Nuffield Health, Brighton, UK
[26] Department of Neurosurgery, Centre for Clinical Neurosciences at Salford Royal NHS Foundation Trust, Manchester, UK
[27] International Center of Excellence for EDS & CCI, Hospital Teknon, Barcelona, Spain
[28] Division of General Internal Medicine, Mayo Clinic, Rochester, MN, USA
[29] Department of Neurosurgery, Duke University, Durham, NC, USA
[30] Department of Neurosurgery, Cornell University, New York, NY, USA
[31] Department of Neurology, University at Buffalo Jacobs School of Medicine and Biomedical Sciences, Buffalo, NY, USA
[32] Western Sinus and Skull Base Consultants, Denver, CO, USA
[33] Department of Rehabilitation and Human Performance, Icahn School of Medicine at Mount Sinai, New York, NY, USA
[34] Department of Surgery, Mount Sinai South Nassau, Oceanside, NY, USA
[35] Center for Complex Diseases, Seattle, WA, USA
[36] Department of Neurology, NYU Langone, East Meadow, NY, USA
[37] Radiology, Luminis Health Doctors Community Medical Center, Lanham, MD, USA
[38] Department of Radiology, Duke University, Durham, NC, USA
[39] Departments of Mechanical and Industrial Engineering & Bioengineering, Northeastern University, Boston, MA, USA
[40] Department of Medicine, Mount Sinai South Nassau, Oceanside, NY
[41] Department of Neurosurgery, NYU, New York, NY, USA
[42] Muldowney Physical Therapy, North Smithfield, RI, USA
[43] Department of Neurology, Icahn School of Medicine at Mount Sinai, New York, NY, USA
[44] Department of Neurosurgery, Moriguchi-Ikuno Memorial Hospital, Osaka Metropolitan University, Osaka, Japan
[45] Department of Neurosurgery, North Shore University Hospital, Northwell Health, Manhasset, NY, USA
[46] Macquarie University Hospital, Macquarie University, Sydney, NSW, Australia
[47] Center for Complex Neurology, EDS & POTS, Phoenix, AZ, USA
[48] Department of Neurosurgery, Children Hospital of Philadelphia, Philadelphia, PA, USA
[49] Department of Neurosurgery, University of Cincinnati, Cincinnati, OH, USA
[50] Department of Neurosurgery, Icahn School of Medicine at Mount Sinai, New York, NY, USA
* Correspondence: allison.bloom@mountsinai.org (A.R.B.); paolo.bolognese@mountsinai.org (P.A.B.)

Abstract

A subset of patients with hypermobile Ehlers–Danlos syndrome (hEDS), hypermobility spectrum disorders (HSD), and related heritable connective tissue disorders (HCTDs) develop complex neurological manifestations. A companion position paper proposed Neuro-EDS as a recognizable neuro-predominant phenotype within this population, providing a foundation for standardized clinical characterization, patient stratification, and future mechanistic research. However, phenotypic characterization alone does not establish the biological mechanisms underlying disease expression. To address this gap, we introduce a phenotype-to-endotype framework for Neuro-EDS, reflecting a broader shift in medicine toward biologically informed classification of complex diseases. Central to this framework is the recognition that altered connective-tissue and extracellular-matrix (ECM) biology may provide a shared substrate through which distinct or interacting mechanisms contribute to seemingly disparate clinical manifestations. Organized around the principal clinical manifestations of Neuro-EDS, the framework integrates candidate biological mechanisms, potential modifiers of disease expression, and mechanism-linked verifiers—objective structural, physiological,

© 2026 by the author(s). Distributed under a Creative Commons CC BY license.

Preprints.org | NOT PEER-REVIEWED | Posted: 24 November 2026 https://doi.org/10.20944/preprints202611.2421.v1

functional, imaging, tissue-based, or molecular measures used to evaluate the presence and relevance of proposed mechanisms. This approach is intended to guide systematic mechanistic investigation and advance understanding of the biological basis of disease heterogeneity. Application of this framework may ultimately enable the identification and validation of biologically defined endotypes, facilitating earlier and more accurate diagnosis, improved patient stratification, and the development of precision therapies targeting underlying disease mechanisms. By providing a structured approach to objective mechanistic evaluation, the framework may also guide research priorities, improve comparability across studies, and support assessment of whether therapeutic interventions modify their intended biological targets.

Keywords: connective tissue disorder (CTD); hypermobility spectrum disorders; Ehlers–Danlos Syndrome (EDS); craniocervical instability; Chiari I malformation; cerebral venous outflow disorder; tethered cord; mast cell activation syndrome (MCAS)

Introduction

Heritable connective tissue disorders (HCTDs) comprise a clinically heterogeneous group of conditions affecting a substantial population worldwide, although their true prevalence remains uncertain in part because of incomplete recognition, evolving diagnostic criteria, and considerable phenotypic variability. Delayed recognition and multisystem involvement frequently result in prolonged diagnostic trajectories and care distributed across multiple specialties [1–3].

A recent companion position paper proposed Neuro-EDS as a recognizable neuro-predominant phenotype within hEDS/HSD and related HCTDs, defining its principal clinical manifestation domains and summarizing the evidence supporting its recognition[4]. “Neuro-EDS” is intended as a working construct for clinical characterization and scientific investigation, rather than a distinct diagnostic entity. The substantial overlap in multisystem and extra-articular manifestations between hEDS and HSD suggests that these diagnostic categories encompass closely related clinical populations [5,6]. As the classification of hEDS/HSD continues to evolve, the manifestations described by this construct remain clinically relevant and warrant investigation irrespective of how these conditions are ultimately classified.

Although recognition of a shared clinical phenotype provides a foundation for systematic investigation, it does not establish a common biological mechanism. Similar or overlapping neurological manifestations may arise through distinct or interacting processes, with implications for patient stratification, therapeutic response, prognosis, and disease classification [7,8].

Building on the clinical foundation established in the companion paper, we therefore ask: what mechanisms may underlie the Neuro-EDS phenotype, and how can they be systematically investigated and objectively evaluated?

To address these questions, we propose a phenotype-to-endotype framework integrating clinical manifestations, candidate biological mechanisms, and mechanism-linked verifiers–objective measures used to evaluate the presence and relevance of proposed mechanisms. This structured approach is intended to guide mechanistic research and ultimately support the identification and validation of biologically defined endotypes.

The Phenotype–Endotype Concept and Investigative Framework

Cross-Disciplinary Adoption of the Endotype Paradigm

The endotype paradigm arose from the recognition that phenotypic classification alone is often insufficient to capture the biological heterogeneity underlying complex disease [9]. It has since been adopted across multiple medical disciplines, enabling the development of pathway-targeted therapies and more precise selection of patients likely to benefit [7,8,10]. Phenotypes organize patients by shared clinical expression but do not necessarily reflect the mechanisms driving disease.

© 2026 by the author(s). Distributed under a Creative Commons CC BY license.

Preprints.org | NOT PEER-REVIEWED | Posted: 24 November 2026 https://doi.org/10.20944/preprints202611.2421.v1

In neurology, endotype-based approaches have been applied, for example, to disorders of consciousness and traumatic brain injury. In disorders of consciousness, a tiered, multidimensional framework integrates clinical phenotypes with structural imaging, neurophysiology, and mechanistic data to better characterize biological heterogeneity, refine prognostic stratification, and identify therapeutic targets [11]. In traumatic brain injury, identification of biologically coherent endotypes has been advanced as a strategy to improve prognostication, enrich clinical trials, and enable more precise therapeutic development and intervention [12].

Collectively, these efforts underscore that endotyping, linking clinical expression to underlying mechanisms, represents a rational and increasingly necessary evolution beyond phenotype-based classification for complex, heterogeneous, and multisystem disorders [7,8,11,12].

We propose that this paradigm may be particularly relevant to HCTDs, in which the widespread distribution of connective tissue and extracellular matrix provides a biological substrate through which abnormalities may influence disease expression across multiple physiological systems and contribute to heterogeneity within a shared clinical phenotype.

Within this framework, a phenotype refers to the observable pattern of clinical manifestations and measurable characteristics shared among patients, whereas a diagnosis refers to a recognized clinical entity defined by established criteria. A candidate mechanism is a biological process proposed to contribute to disease expression or heterogeneity. An endotype refers to a biologically defined subgroup characterized by shared pathobiological mechanisms that may influence disease expression, prognosis, or therapeutic response [7,8,13].

We introduce mechanism-linked verifiers as objective structural, physiological, functional, imaging, tissue-based, or molecular measures used to evaluate the presence and relevance of a proposed mechanism. These vary in mechanistic specificity and validation, ranging from findings consistent with a proposed mechanism to more direct evidence from dynamic testing or targeted interventions. The strength of mechanistic inference depends on verifier specificity, reproducibility, validation, and study design. Symptomatic responses to interventions are particularly susceptible to expectancy effects and natural symptom fluctuation; concordant objective changes and controlled or comparative designs can strengthen interpretation. No single verifier independently establishes causality, but integrating complementary measures may support the identification of biologically defined endotypes.

Together, these concepts distinguish what is observed clinically (**phenotype)**, what condition is recognized (**diagnosis**), what biological processes may contribute to clinical heterogeneity **(candidate mechanisms**), and how those proposed mechanisms can be objectively evaluated **(mechanism-linked verifiers**). Integration of these elements may ultimately support the identification and validation of biologically defined subgroups (**endotypes**). Key concepts and their roles in the framework are summarized in Table 1.

© 2026 by the author(s). Distributed under a Creative Commons CC BY license.

Preprints.org | NOT PEER-REVIEWED | Posted: 24 November 2026 https://doi.org/10.20944/preprints202611.2421.v1

Table 1. Key concepts and their roles in the Neuro-EDS phenotype-to-endotype framework.

Concept	Definition	Role in Framework
Phenotype	Observable pattern of clinical manifestations and measurable characteristics shared among patients	Defines what is observed clinically
Diagnosis	Recognized clinical entity defined by established criteria	Identifies the recognized clinical condition
Candidate Mechanism	Biological process proposed to contribute to disease expression or heterogeneity	Provides a testable biological explanation for phenotype heterogeneity
Mechanism-Linked Verifier	Objective structural, physiological, functional, imaging, tissue-based, or molecular measure used to evaluate the presence and relevance of a proposed mechanism	Provides objective evidence to evaluate a proposed mechanism and strengthen mechanistic inference
Endotype	Biologically defined subgroup characterized by shared pathobiological mechanisms that may influence disease expression, prognosis, or therapeutic response	Represents the biological subgroup that may ultimately emerge after mechanistic investigation
Modifier	Precipitating or amplifying factor that may unmask latent disease, disrupt physiological compensation, or alter expression/activity of underlying mechanisms	Modifies disease expression without itself constituting an endotype

The Neuro-EDS Phenotype–Endotype Framework

Within the proposed Neuro-EDS phenotype, disorders such as craniocervical instability (CCI), Chiari-spectrum pathology, tethered cord syndrome (TCS), CSF-pressure disorders, and Eagle syndrome may occur concurrently and may differ in their pathogenesis, clinical expression, diagnostic features, and therapeutic response when they arise in the context of a connective tissue disorder (CTD) [14–17]. The frequent co-occurrence of multiple neurological and neurosurgical diagnoses in CTD populations [18] raises the possibility of shared or interacting biological vulnerabilities rather than entirely independent susceptibility to each disorder. The observed clinical heterogeneity of the Neuro-EDS phenotype remains a challenge and is incompletely understood. In the current paper we therefore further propose that heterogeneity within the phenotype may reflect varying combinations of interacting mechanisms across structural, biomechanical, autonomic, vascular, CSF, neurophysiologic, neuroimmune, and cellular domains, whose relative contributions may differ among patients. This premise also underscores the need to evaluate the applicability of prevailing disease models, diagnostic standards, and reference values developed largely outside CTD populations.

Endotypes are therefore conceptualized as overlapping, mechanistically defined biological subgroups that may account for heterogeneity within the shared Neuro-EDS phenotype. They are not presumed a priori or intended as individual diagnoses, mutually exclusive disease categories, or a definitive taxonomy, but may ultimately be identified through systematic investigation of candidate mechanisms and mechanism-linked verifiers. Identification of Neuro-EDS endotypes will require integration of multidimensional clinical and biological data to identify reproducible mechanistic patterns, followed by independent validation and evaluation of their relationship to disease expression and therapeutic response. This proposed phenotype-to-endotype framework is illustrated in Figure 1.

© 2026 by the author(s). Distributed under a Creative Commons CC BY license.

Preprints.org | NOT PEER-REVIEWED | Posted: 24 November 2026 https://doi.org/10.20944/preprints202611.2421.v1

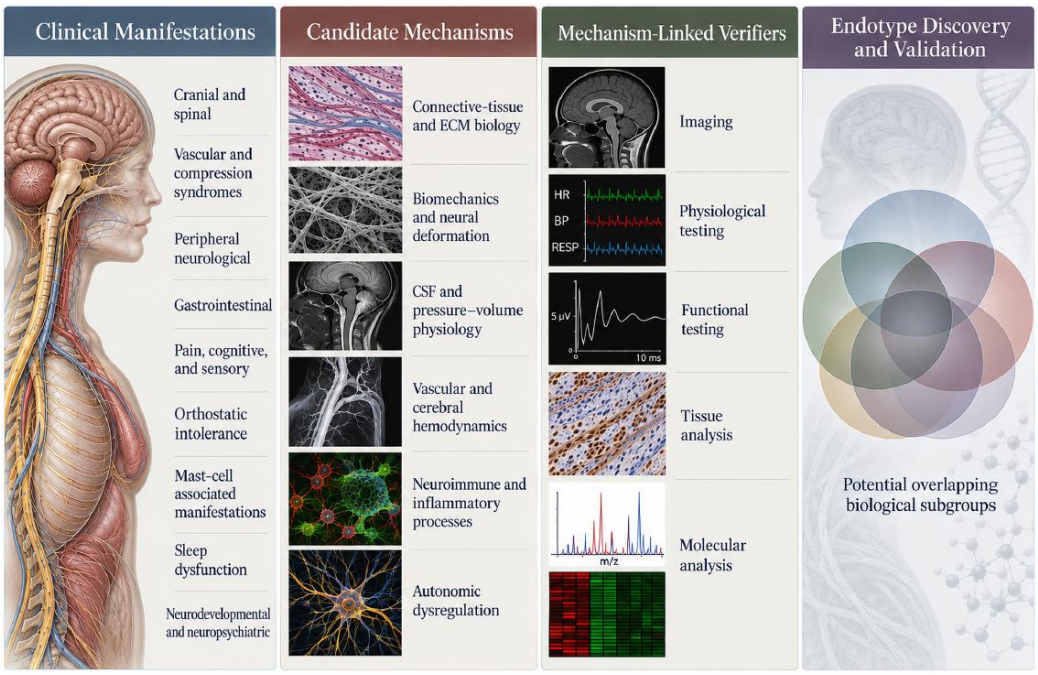

Figure 1. Proposed phenotype-to-endotype framework for Neuro-EDS. Clinical manifestations guide investigation of candidate mechanisms using complementary imaging, physiological, functional, tissue-based, and molecular verifiers. Integrated findings may support discovery and validation of overlapping biological subgroups; Neuro-EDS endotypes remain proposed. Images and traces are illustrative. ECM, extracellular matrix; CSF, cerebrospinal fluid; HR, heart rate; BP, blood pressure; RESP, respiration; m/z, mass-to-charge ratio.

The principal clinical manifestations are organized into two domains: the cranial and spinal domain and the neuro-autonomic-inflammatory domain (Figure 2). These domains are organizational rather than mutually exclusive, reflecting the overlap and interaction of biological mechanisms across clinical manifestations. Representative candidate mechanisms and mechanism-linked verifiers across these manifestations are summarized in Table 2.

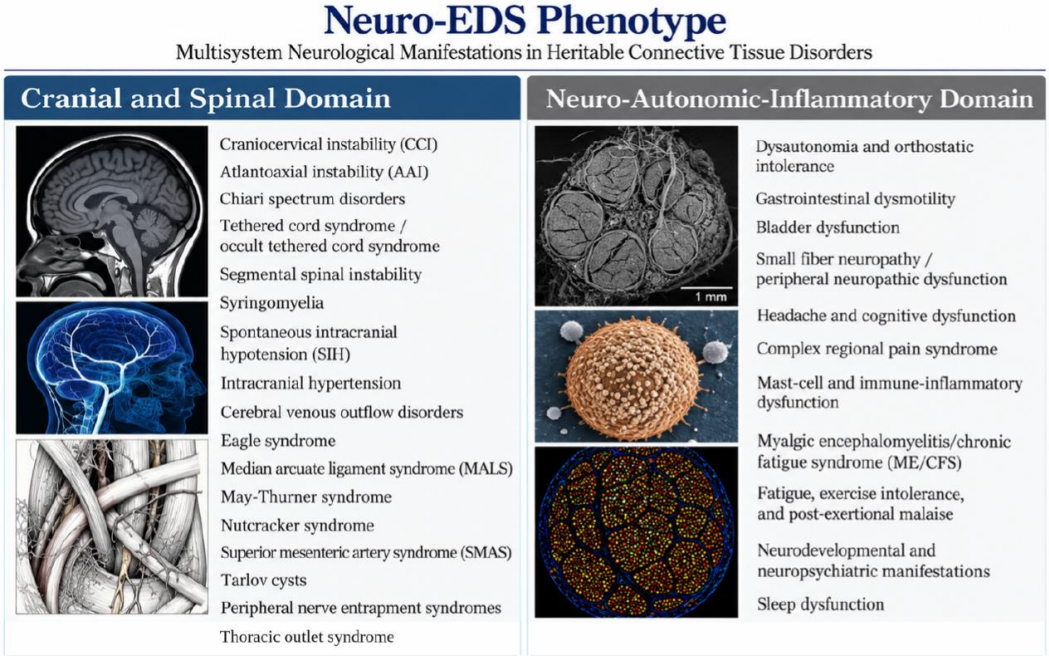

Figure 2. Principal clinical manifestation domains of Neuro-EDS. Manifestations are organized into cranial and spinal and neuro-autonomic-inflammatory domains. These overlapping domains describe the proposed

© 2026 by the author(s). Distributed under a Creative Commons CC BY license.

Preprints.org | NOT PEER-REVIEWED | Posted: 24 November 2026 https://doi.org/10.20944/preprints202611.2421.v1

clinical phenotype and do not imply a shared established mechanism. Images are illustrative. CCI, craniocervical instability; AAI, atlantoaxial instability; SIH, spontaneous intracranial hypotension; MALS, median arcuate ligament syndrome; SMAS, superior mesenteric artery syndrome; ME/CFS, myalgic encephalomyelitis/chronic fatigue syndrome.

Table 2. Representative candidate mechanisms and mechanism-linked verifiers across Neuro-EDS manifestations.

Clinical manifestation	**Representative candidate mechanisms**	**Representative mechanism-linked verifiers**
CRANIAL AND SPINAL DOMAIN		
Craniocervical / atlantoaxial instability	Impaired ligamentous restraint; pathological motion; neural deformation	Dynamic imaging and craniocervical morphometrics; ICT with concordant clinical and morphometric responses
Occult tethered cord syndrome	Altered filum biomechanics; abnormal cord tension and motion	Neurological/urological findings; adjunctive dynamic imaging; filum histopathology and biomechanics
Chiari-spectrum disorders / syringomyelia	Hindbrain overcrowding; CSF-flow obstruction; altered compliance and hindbrain motion	Posterior fossa morphometrics; cine CSF-flow MRI; DENSE MRI; syrinx morphology; compliance assessment
Spontaneous intracranial hypotension / spinal CSF leaks	Dural and meningeal vulnerability; focal dural defects; leaking diverticula; CSF–venous shunting	Brain/spine MRI; dynamic CT myelography; DSM; leak/fistula localization
Tarlov cysts	Meningeal/perineural connective-tissue vulnerability; CSF pulsatility and ball-valve mechanisms; nerve-root compression	MRI characterization of cyst–nerve-root relationships; concordant neurological findings and cyst-related compression
Cerebral venous outflow disorders / intracranial hypertension	Fixed or dynamic venous obstruction; venous congestion/hypertension; altered CSF pressure–volume regulation	MRV/CTV; dynamic venography/manometry or Doppler; ICP monitoring and waveforms

© 2026 by the author(s). Distributed under a Creative Commons CC BY license.

Preprints.org | NOT PEER-REVIEWED | Posted: 24 November 2026 https://doi.org/10.20944/preprints202611.2421.v1

Clinical manifestation	Representative candidate mechanisms	Representative mechanism-linked verifiers
Eagle syndrome	Glossopharyngeal nerve traction/compression; styloidogenic jugular venous compression	Concordant provocation; glossopharyngeal nerve block; dynamic vascular/hemodynamic assessment
Median arcuate ligament syndrome	Dynamic celiac-axis compression; altered splanchnic perfusion; celiac plexus irritation	Respiratory duplex ultrasonography; CTA/MRA; celiac plexus block
May–Thurner syndrome / non-thrombotic iliac vein lesions	Iliac venous obstruction; venous hypertension; impaired venous return	CT/MR venography; Doppler assessment; catheter venography /IVUS; collateral assessment
Nutcracker syndrome	Left renal vein compression; renal venous hypertension	Doppler ultrasonography; CT/MR vascular imaging; venography with pressure-gradient assessment
Superior mesenteric artery syndrome	Mechanical duodenal compression; possible altered visceral support in hEDS/HSD, currently unproven	CT/CTA; upper-GI contrast studies; dynamic/positional ultrasonography
Thoracic outlet syndrome	Fixed or dynamic neurovascular compression; possible ligamentous laxity, scapular instability, and brachial plexus traction	Electrodiagnostic testing; dynamic duplex ultrasonography or positional CTA/CTV; scalene/pectoralis minor blocks as supportive localization tests
Peripheral nerve entrapment syndromes	Excessive nerve excursion; reduced ligamentous/fascial restraint; traction, compression, or friction	Dynamic ultrasound; electrodiagnostic testing; targeted imaging/provocation
NEURO-AUTONOMIC-INFLAMMATORY DOMAIN		
Dysautonomia / orthostatic intolerance	Excessive venous pooling; reduced preload; impaired vasoconstriction/baroreflex regulation; cerebral hypoperfusion or hypocapnia; autonomic small-fiber dysfunction	Stand/tilt with continuous HR/BP; cerebral hemodynamics and end-tidal CO_2; autonomic/sudomotor testing

© 2026 by the author(s). Distributed under a Creative Commons CC BY license.

Preprints.org | NOT PEER-REVIEWED | Posted: 24 November 2026 https://doi.org/10.20944/preprints202611.2421.v1

Clinical manifestation	Representative candidate mechanisms	Representative mechanism-linked verifiers
Small-fiber neuropathy	Possible neural microenvironment, vascular, immune, metabolic, or hereditary contributors*	Skin biopsy with IENFD; QST; sudomotor and cardiovascular autonomic testing
Mast-cell / immune-inflammatory dysfunction	Mast-cell mediator release; effects on vascular tone/permeability and neural signaling; proposed bidirectional mast-cell–ECM interactions	Event-related versus baseline tryptase; paired urinary mediators†
GI dysmotility / disorders of gut–brain interaction	Autonomic or neuropathic dysfunction; visceral hypersensitivity; altered gut–brain processing; altered visceral/pelvic-floor mechanics	Gastric-emptying studies; esophageal/anorectal manometry; pH-impedance; balloon expulsion/defecography
Headache / cognitive dysfunction / altered central processing	Cerebral hypoperfusion or hypocapnia; trigeminovascular/migraine-network dysfunction; central sensitization	Orthostatic cerebral hemodynamics and end-tidal CO_2; QST; secondary-headache investigations
Fatigue / exercise intolerance / PEM-like phenotype	Hemodynamic dysfunction; biomechanical inefficiency; possible microvascular/metabolic/immune contributors*	CPET; autonomic/cerebral-hemodynamic testing‡
Sleep dysfunction	Upper-airway vulnerability and sleep-disordered breathing; pain–sleep interactions; possible autonomic contributions; circadian dysregulation	Polysomnography; actigraphy; targeted sleep assessment
Neurodevelopmental / neuropsychiatric manifestations	Proposed familial/neurodevelopmental susceptibility; autonomic and interoceptive dysregulation; altered sensory processing	Autonomic testing; research markers linked to clinical patterns; no established mechanism-specific verifier§

Note. Entries are representative; evidence, specificity, and validation vary. Findings may support mechanistic inference without establishing causality. Therapeutic response alone is not definitive confirmation. Domains overlap. *CTD-specific contributions remain unestablished. † Mediator tests assess mast-cell activation, not broader ECM–immune interactions. ‡ Two-day CPET has been studied in ME/CFS; its role in hEDS/HSD remains unestablished. § NEQ provides complementary clinical characterization and requires further validation. **Abbreviations:** BP, blood pressure; CO_2, carbon dioxide; CPET, cardiopulmonary exercise testing; CSF, cerebrospinal fluid; CT, computed tomography; CTA/CTV, CT angiography/venography; DENSE, displacement encoding with stimulated echoes; DSM, digital subtraction myelography; ECM, extracellular matrix; GI, gastrointestinal; hEDS, hypermobile Ehlers–Danlos syndrome; HR, heart rate; HSD, hypermobility spectrum disorder; ICP, intracranial pressure; ICT, intraoperative cervical traction; IENFD, intraepidermal nerve-fiber density; IVUS, intravascular ultrasound; ME/CFS, myalgic encephalomyelitis/chronic fatigue syndrome; MR/MRI, magnetic resonance/magnetic resonance imaging; MRA/MRV, MR angiography/venography; NEQ, Neuroconnective Endophenotype Questionnaire; PEM, postexertional malaise; QST, quantitative sensory testing; SFN, small-fiber neuropathy.

© 2026 by the author(s). Distributed under a Creative Commons CC BY license.

Preprints.org | NOT PEER-REVIEWED | Posted: 24 November 2026 https://doi.org/10.20944/preprints202611.2421.v1

Cranial and Spinal Domain

1. Craniocervical Instability/AAI/Segmental Instability

Clinical Phenotype and Connective-Tissue Context

Craniocervical instability (CCI) involves pathological motion between the cranium and upper cervical spine, whereas atlantoaxial instability (AAI) involves abnormal translational and/or rotational motion between C1 and C2. These disorders may coexist, producing overlapping neurological manifestations and symptoms of the cervicomedullary syndrome (CMS, also known as "craniocervical syndrome"; ICD-10-CM Diagnosis Code M53.0), attributable to pathological stresses to the lower brainstem, lower cranial nerves, upper spinal cord and vertebral arteries [19–22].

AAI is characterized by the CMS symptoms of occipital neuralgia, neck pain, fatigue, vertigo, nausea, episodes of visual loss, blurring or diplopia, syncope or presyncope, intermittent dysesthesias of the upper extremities and trunk, and dysautonomia [23]. CCI adds to this symptom panoply weakness, imbalance, lower cranial nerve symptoms including dysphagia, choking, hoarseness, sleep disorders and increasing autonomic dysfunction. Neurological findings of CCI and AAI include hyperreflexia, decreased gag reflex, Dejerine pattern of facial sensory loss and hypoesthesia to pinprick, mild weakness , Romberg sign, dysdiadochokinesia, and long-tract signs [21,24–26].

Segmental spinal instability has also been described in EDS, where pathological intervertebral motion may contribute to mechanical pain, neural deformation, radiculopathy, and myelopathy [20,27]. Although population prevalence remains undefined, CTD-associated CCI is likely underrecognized; recognition may require a paradigm shift from acute traumatic models to a chronic, dynamic model accounting for underlying connective-tissue vulnerability and diverse CMS manifestations.

Candidate Mechanisms

The stability of the craniocervical junction (CCJ) depends on ligamentous restraint and neuromuscular stabilization. In HCTDs, ligamentous laxity may compromise passive stability, while altered proprioception, postural alignment, and impaired neuromuscular control may further influence craniocervical loading, although their contributions to pathological instability remain incompletely characterized [20,22,28].

Under physiological loading and repetitive strain, impaired passive restraint may contribute to pathological translation, rotation, angulation, or cranial settling, altering force transmission across the CCJ and deforming adjacent neural structures [19,29–35]. Torsion and strain of the ventral medulla and lower cranial nerves may contribute to bulbar symptoms, while deformation of cervicomedullary pathways may affect autonomic, respiratory, and arousal regulation [23,25,36,37]. Mechanical irritation of the vagus nerve near the jugular foramen has also been proposed as a potential contributor to autonomic dysfunction in cervical instability, although direct mechanistic evidence remains limited[38].

The upper cervical spine exhibits complex coupled three-dimensional motion influenced by muscular stabilization and physiological loading [39–41]. Dynamic imaging may reveal altered craniocervical relationships not apparent on neutral static studies[15,21,35,42]. Neurological dysfunction may therefore result from dynamic deformation rather than fixed compression alone [19,33,43]. Von Mises stress is a scalar measure derived from the local stress state and is used in finite-element modeling. Models of the craniocervical junction suggest that abnormal translation, kyphotic clivo-axial angulation, and ventral brainstem compression may increase predicted tissue stress [33,34,44].

Neural deformation may impair axonal integrity, signal transmission, and nociceptive pathways [45–47]. Experimental stretch alters ion-channel activity and calcium homeostasis, mitochondrial function, NMDA-related signaling, and apoptotic pathways and can produce myelin disruption and axonal retraction bulbs, while reducing neural firing rate and amplitude (30-33, 48-62).

© 2026 by the author(s). Distributed under a Creative Commons CC BY license.

Preprints.org | NOT PEER-REVIEWED | Posted: 24 November 2026 https://doi.org/10.20944/preprints202611.2421.v1

Vascular mechanisms may provide an additional pathway. Head rotation in AAI results in forward, downward movement of the atlas , kinking the contralateral vertebral artery, and obstructing arterial flow [22,23,63,64]. Alternatively, ischemia may result from obstruction of venous outflow through the intracranial venous sinuses or the jugular vein [65–67].

Mechanical stretch of dural/ligamentous attachments in the atlantooccipital membrane may affect pain and, indirectly, CSF flow [68]. The myodural bridge connects the suboccipital musculature to the upper cervical dura, facilitating force transmission during head and neck movement. Ultrastructural studies suggest linkage between abnormal force transmission and altered myodural architecture [69–71].

Modifiers

Clinical onset or deterioration of CTD-associated CCI may follow loss of previously effective biomechanical compensation. Physical trauma, craniovertebral surgery, and other systemic inflammatory stressors may disrupt structural, biomechanical, physiological, and neuroimmune homeostasis, precipitating or amplifying disease expression in susceptible individuals [26,72,73].

Mechanism-Linked Verifiers

Instability can be assessed by morphometric evaluation or by concordant clinical and morphometric responses to controlled biomechanical intervention. Morphometric assessment includes the clivo-axial angle (CXA) [15,35,74–78]; pathological translation on dynamic flexion-extension of the cervical spine as measured by change in the basion-axial interval (BAI) [15,35,42,75,79–83]; the Grabb-Oakes measurement (pB-C2) [84]; C1–C2 angular displacement [15,20,23,35,85–88]; and standard measures of basilar invagination [77,89]. Widening of the atlanto-condylar joints may provide supportive evidence [90]. Dynamic and weight-bearing imaging may reveal abnormalities not apparent on supine imaging, although diagnostic thresholds remain unvalidated in CTDs [15]

Concordant clinical and morphometric responses to controlled biomechanical intervention provide complementary mechanism-linked evidence. The Bloom et al. intraoperative cervical traction (ICT) protocol combines controlled traction with clinical assessment, dynamic imaging, and objective morphometric measurements; improvement in cervicomedullary symptoms accompanying correction of craniocervical alignment supports a mechanically mediated component of disease expression [91]. Similarly, Bohra et al. (2025) reported improvements in cervicomedullary symptoms accompanying correction of craniocervical morphometrics during halo traction, providing additional evidence of a mechanically mediated component of disease expression.

Numerous studies have demonstrated a strong association between clinical improvement and the elimination of deformative stress through stabilization [21,26,29,34,44,76,78, 89,92–95]. Whether clinically significant craniocervical dysfunction may occur despite normal conventional and dynamic imaging measurements remains an important question requiring prospective investigation.

2. Tethered Cord

Clinical Phenotype and Connective-Tissue Context

Tethered cord syndrome (TCS) arises from pathological anchoring of the spinal cord within the spinal canal, resulting in abnormal transmission of tensile forces and mechanical strain to the spinal cord and cauda equina during physiological movement [96,97]. It typically presents with a triad of lower-extremity weakness and neurologic findings, urologic dysfunction, and low-back pain; children may also have scoliosis or leg deformities.

While classic TCS is typically associated with a low-lying conus medullaris and congenital dysraphic abnormalities, Warder and Oakes first described TCS in patients with a normally positioned conus [98]. In patients with hEDS, this phenomenon has been described as occult tethered

© 2026 by the author(s). Distributed under a Creative Commons CC BY license.

Preprints.org | NOT PEER-REVIEWED | Posted: 24 November 2026 https://doi.org/10.20944/preprints202611.2421.v1

cord syndrome (OTCS), in which clinically significant neurological dysfunction occurs despite the absence of conventional radiographic evidence of tethering [20,99].

Candidate Mechanisms

In hEDS, histopathologic, ultrastructural, and biomechanical studies of the filum terminale provide evidence for a CTD-associated biological substrate of occult tethering. Altered collagen architecture and impaired biomechanical properties of the filum may reduce its ability to dampen movement-related tensile forces, thereby increasing transmission of strain to the distal spinal cord despite a normally positioned conus medullaris [99]. This behaviour is similar to the strain-stiffening behaviour seen in tendon biomechanics [100].

This biomechanical derangement may be amplified in the hypermobile spine, where pathological anchoring may limit the spinal cord's ability to accommodate increased spinal motion, thereby increasing mechanical strain across the tethered neuraxis [99].

The concept of spinal cord tethering has traditionally centered on caudal fixation by an inelastic filum terminale [96,97]. Breig's biomechanical investigations extended this perspective by examining how spinal movement influences neural excursion, deformation, and tension throughout the neuraxis [101]. This provides a foundation for considering *spinal cord motion disorder* as a proposed disturbance of coordinated cord and meningeal movement without a discrete anatomical tether. The resulting disturbance may involve the entire neuraxis, potentially affecting upper motor neuron pathways and manifesting as subtle, often asymmetric spasticity and other upper motor neuron signs [100,102,103].

The concept of spinal cord motion disorder in hEDS is further supported by studies of the myodural bridges, connective tissue structures linking the suboccipital muscles to the craniocervical dura and supporting dural compliance. Histological studies identified collagen alterations similar to those observed in the filum terminale, potentially affecting dural and spinal cord motion [69]

Excessive vertebral motion, altered meningeal compliance, or arachnoid adhesions may also impair neural accommodation and concentrate strain during movement. Hirayama disease illustrates how flexion-dependent dural displacement can produce cord injury without a discrete tether, although its mechanism is distinct [104].

In hEDS/HSD, spinal cord motion disorder remains a hypothesis-generating candidate mechanism that may overlap clinically with CCI, caudal tethering, and CSF-pressure disorders [20,99,105] . Breig's work provides a biomechanical rationale but does not establish diagnostic criteria or treatment indications.

Modifiers

Similar to CCI, clinical onset or deterioration of CTD-associated TCS may follow loss of previously effective biomechanical compensation. Physical trauma, craniovertebral surgery, and other systemic inflammatory stressors may disrupt structural, biomechanical, physiological, and neuroimmune homeostasis, precipitating or amplifying disease expression in susceptible individuals [26,72,73].

Histological studies have shown increased mast-cell and leukocyte density, along with filum terminale calcification, more prominent in hEDS. These findings may reflect secondary inflammatory tissue injury and could act as disease modifiers [99,106].

Mechanism-Linked Verifiers

Because OTCS lacks conventional radiographic evidence of tethering, mechanism-linked verification depends on convergence of clinical, neurological, urological, imaging, and tissue-based findings rather than any single measure. Supportive clinical features include the characteristic triad described above [99,102,107,108].

© 2026 by the author(s). Distributed under a Creative Commons CC BY license.

Preprints.org | NOT PEER-REVIEWED | Posted: 24 November 2026 https://doi.org/10.20944/preprints202611.2421.v1

Conventional imaging remains important for excluding alternative structural pathology, while positional or dynamic imaging may provide adjunctive evidence of restricted cord or filum mobility [109–111]. Craniocervical ultrasonography has also provided preliminary evidence of altered upper cervical spinal cord motion associated with cardiac and respiratory cycles in patients with hEDS compared with individuals without EDS [69].

Histopathologic and biomechanical abnormalities of the filum terminale provide tissue-based evidence supporting the proposed connective tissue–biomechanical mechanism in hEDS [99]. Clinical improvement following filum terminale sectioning in carefully selected patients may provide additional supportive mechanistic evidence but should not be considered independently diagnostic [99,107,112,113]. For the proposed spinal cord motion disorder, future investigation should evaluate the reproducibility of abnormal cord dynamics, distinguish these findings from competing mechanisms, and determine their relationship to neurological manifestations and treatment outcomes.

3. Chiari Spectrum Disorders and Syringomyelia

Clinical Phenotype and Connective-Tissue Context

Chiari I malformation (CM-I) is radiographically characterized by caudal displacement of the cerebellar tonsils below the foramen magnum and may be associated with brainstem dysfunction, altered cerebrospinal fluid (CSF) dynamics, and syringomyelia. Because the hindbrain and cervicomedullary junction integrate autonomic, respiratory, vestibular, cerebellar, lower cranial nerve, and sensorimotor functions, abnormalities in this region may produce diverse neurological manifestations [114].

HCTDs may define a clinically and radiographically distinct CM-I subgroup. Compared with CM-I in patients without HCTDs, HCTD-associated CM-I may demonstrate greater lower brainstem involvement and craniovertebral abnormalities, including occipitoatlantoaxial hypermobility and cranial settling [44,115]. Familial CM-I studies also demonstrate enrichment of connective tissue disorders, particularly EDS, supporting a heritable relationship between these conditions [116].

Syringomyelia, a fluid-filled cavity within the spinal cord, is a well-recognized consequence of disturbed CSF dynamics and commonly occurs in association with CM-I. Among patients with CM-I, joint hypermobility has been associated with a higher observed prevalence of syringomyelia, suggesting that connective tissue phenotype may modify disease expression [117].

A subset of patients exhibits complex Chiari-spectrum pathology, characterized by hindbrain abnormalities that coexist with ventral brainstem compression, craniocervical instability, abnormal craniocervical angulation, basilar invagination, cranial settling, or other craniovertebral junction abnormalities requiring treatment beyond posterior fossa decompression [118,119].

Candidate Mechanisms

Proposed mechanisms include posterior cranial fossa underdevelopment and hindbrain overcrowding, obstruction of CSF flow at the foramen magnum, altered craniospinal compliance, and abnormal pulsatile hindbrain motion [120–123]. Spinal CSF leakage, including CSF–venous fistulas, may cause acquired tonsillar descent mimicking Chiari I malformation, underscoring the need to distinguish primary from secondary mechanisms [105,124].

Obstruction of normal CSF oscillatory displacement across the foramen magnum during the cardiac cycle may increase pulsatile tonsillar and hindbrain motion, generating abnormal spinal subarachnoid pressure waves that contribute to syrinx formation and progression. Contemporary models also incorporate altered subarachnoid compliance and pressure-driven fluid movement through perivascular and interstitial pathways [122,125,126]. These perivascular pathways overlap with the proposed glymphatic system of CSF–interstitial fluid exchange and solute clearance, although the effects of altered craniospinal dynamics on glymphatic transport in Chiari malformation remain unestablished [127,128].

© 2026 by the author(s). Distributed under a Creative Commons CC BY license.

Preprints.org | NOT PEER-REVIEWED | Posted: 24 November 2026 https://doi.org/10.20944/preprints202611.2421.v1

In CTDs, these mechanisms may interact with abnormalities in craniospinal support, ligamentous and dural mechanics, cranial settling, and CCI. Coexisting CCI may be present initially or become clinically apparent after posterior fossa decompression (PFD), with EDS and hypermobility reported among patients developing symptomatic postoperative CCI [44,78].

Modifiers

Clinical expression may be modified by coexisting TCS, altered craniospinal compliance, trauma, progressive CCI, and prior PFD, each of which may further alter craniospinal biomechanics or CSF physiology [44,78,114].

Mechanism-Linked Verifiers

Posterior fossa morphometrics, cine CSF-flow imaging, displacement encoding with stimulated echoes (DENSE) MRI quantification of cerebellar and brainstem motion and strain, syrinx morphology, and measures of craniospinal compliance may provide complementary evidence of hindbrain overcrowding, CSF-flow obstruction, abnormal tissue biomechanics, and altered compliance [120,121,123,129]. Additional quantitative MRI investigations have examined relationships between cardiac-induced brainstem and cerebellar motion or mechanical strain, clinical symptoms, and physiological changes following posterior fossa decompression, supporting further evaluation of these measurements as candidate mechanism-linked verifiers [130–133]. In complex Chiari, dynamic craniovertebral assessment may also identify coexisting instability or deformity relevant to disease mechanism and treatment selection [78,119].

Restoration of CSF flow across the foramen magnum, accompanied by normalization of abnormal CSF dynamics or a reduction in syrinx size, may provide mechanism-linked evidence that CSF-flow obstruction contributes to disease expression [125,134,135]. Prospective longitudinal assessment of clinical outcomes and posterior fossa morphometric changes following decompression provides additional evidence for investigating relationships between anatomical correction and clinical improvement [136].

4. Disorders of CSF Pressure Regulation and Cerebral Venous Outflow

1.1. Spontaneous Intracranial Hypotension

Clinical Phenotype and Connective-Tissue Context

Spontaneous intracranial hypotension (SIH) most commonly results from spontaneous spinal CSF leakage through dural tears, leaking meningeal diverticula, or CSF–venous fistulas [124,137]. Although orthostatic headache is characteristic, SIH may produce neck pain, nausea, vestibulo-auditory symptoms, visual disturbances, cognitive dysfunction, and cranial nerve manifestations [124,137,138].

SIH remains underrecognized because of phenotypic overlap with other neurological disorders and the inconsistent presence of low CSF opening pressure or characteristic intracranial MRI findings, contributing to diagnostic delay and misdiagnosis [124,139–141]. Heritable and broader connective-tissue abnormalities are associated with spontaneous spinal CSF leaks, although recognized monogenic HCTDs account for only a minority of cases [16,17].

Candidate Mechanisms

Dural and meningeal connective-tissue vulnerability may represent a foundational mechanism underlying spontaneous CSF leakage in HCTDs, predisposing to meningeal diverticula, focal dural defects, dural ectasia, and CSF–venous fistulas through distinct mechanisms that disrupt craniospinal CSF volume and pressure regulation [105,124]. Recent genetic and functional evidence directly links extracellular-matrix abnormalities to impaired dural integrity: rare functional FBN2 variants are

© 2026 by the author(s). Distributed under a Creative Commons CC BY license.

Preprints.org | NOT PEER-REVIEWED | Posted: 24 November 2026 https://doi.org/10.20944/preprints202611.2421.v1

enriched in patients with spontaneous spinal CSF leaks, impair fibrillin-2–dural fibroblast interactions, and increase susceptibility to dural rupture in experimental models [142].

Mechanisms differ by leak location. Dural defects ventral to the spinal cord are strongly associated with a causative calcific lesion, e.g., osteophyte, calcified disc herniation, or calcified ligament [143]. Among patients with spontaneous lateral spinal CSF leaks, causative calcific lesions are uncommon, while rare functional variants in the fibrillin-2 gene (FBN2) were identified in 21% (9/42) of patients with type 1b leaks [142].

CSF–venous fistulas represent a distinct mechanism involving direct CSF egress into the paraspinal venous system, typically without a spinal longitudinal extradural CSF collection [105,144,145]. Their recognition has expanded the mechanistic spectrum of SIH beyond conventional extradural CSF leakage, although their prevalence among patients with connective-tissue disorders remains incompletely defined.

Emerging models of CSF pressure disorders recognize intracranial hypertension and SIH as complementary manifestations of disturbed craniospinal pressure homeostasis rather than mutually exclusive disease states [146–148].

Modifiers

Mechanical stress, minor trauma, or abrupt pressure changes may precipitate leakage in individuals with underlying dural susceptibility, supporting an interaction between connective-tissue integrity and environmental loading [142,149,150].

Mechanism-Linked Verifiers

Mechanism-linked verifiers include imaging capable of directly demonstrating CSF leakage or CSF–venous shunting. The SEEPS mnemonic (Subdural fluid collections, Enhancement of the pachymeninges, Engorgement of venous structures, Pituitary enlargement, and Sagging of the brain) summarizes characteristic intracranial MRI findings of SIH; however, these findings and a spinal longitudinal extradural CSF collection may be absent despite spinal CSF leakage [124,149].

When conventional imaging is unrevealing, dynamic computed tomography (CT) myelography and digital subtraction myelography (DSM) may provide direct mechanism-linked evidence by localizing occult CSF leaks or CSF–venous fistulas. Fistulas may remain occult on conventional myelography, often requiring lateral decubitus CT myelography or DSM for localization, while intrathecal contrast-enhanced MR myelography may provide additional localization in selected cases [124,151,152]. Among patients with orthostatic headaches but normal brain and spine MRI, CSF-venous fistulas can be identified in about 10% of patients, and the yield increases in the presence of meningeal diverticula and with a decreased optic nerve sheath diameter [105,153]. These findings support targeted advanced imaging in appropriately selected patients despite negative conventional studies.

Clinical improvement following intrathecal saline administration provides physiologic evidence that restoration of CSF volume and pressure can reverse neurological manifestations of SIH, supporting a pressure–volume mechanism of disease expression [154–156]. Rebound intracranial hypertension following successful treatment of spontaneous CSF leaks provides complementary evidence of dynamic shifts in craniospinal pressure–volume regulation, supporting physiological interactions between low- and high-pressure states rather than entirely independent processes [147,148].

4.2. Tarlov Cysts

Tarlov cysts are classically described as CSF-containing perineural cysts involving the nerve-root sheath that may reflect meningeal or perineural connective tissue vulnerability. However, contemporary use of the term may encompass anatomically distinct cystic meningeal abnormalities, including dural diverticula, highlighting the importance of distinguishing these entities when

© 2026 by the author(s). Distributed under a Creative Commons CC BY license.

Preprints.org | NOT PEER-REVIEWED | Posted: 24 November 2026 https://doi.org/10.20944/preprints202611.2421.v1

evaluating their clinical and mechanistic significance. Although frequently incidental, symptomatic perineural cysts may produce radicular pain, sensory disturbances, and bowel, bladder, or sexual dysfunction through nerve-root compression or deformation [157,158]. Proposed mechanisms of cyst enlargement include hydrostatic and pulsatile CSF forces and a ball-valve mechanism that permits CSF influx while restricting outflow [158,159]. Tarlov cysts have been associated with HCTDs, including EDS, although the strength and biological basis of this association remain uncertain [20,158].

1.3. Cerebral Venous Outflow Disorders

Clinical Phenotype and Connective-Tissue Context

Cerebral venous outflow disorders (CVD) comprise a spectrum of conditions in which impaired venous outflow results in cerebral venous congestion and/or intracranial hypertension, with idiopathic intracranial hypertension (IIH) representing a well-recognized clinical presentation. Core symptoms include pressure headache, barometric pressure sensitivity, cognitive dysfunction, pulsatile and non-pulsatile tinnitus, visual disturbances, dizziness, and postural exacerbation; less common manifestations include facial pain, non-epileptic seizures or convulsions, and stroke-like episodes [160,161]. Elevated intracranial pressure (ICP) may additionally produce papilledema and diplopia [162].

Candidate Mechanisms

ICP is regulated within an integrated pressure–volume system in which cerebral blood volume, CSF volume and flow, venous drainage, and craniospinal compliance are dynamically coupled [163,164]. In CTDs, altered connective-tissue properties may affect multiple components of this system; greater susceptibility to venous compression and more pronounced vessel angulation may predispose to outflow compromise, potentially contributing to pressure dysregulation and reduced compensatory reserve. Coexisting CSF leakage may further modify intracranial pressure regulation by providing an alternative pathway for CSF egress, potentially masking underlying pressure elevation. Intracranial hypertension may become apparent following leak closure, suggesting that CSF leakage can alter the clinical expression of pressure dysregulation in selected patients [165,166].

Similar clinical presentations may arise from impaired venous outflow due to stenoses of major draining veins in the head, neck, or chest [162]. Cerebral venous outflow obstruction may involve multiple sites, including concurrent intracranial and extracranial stenoses [167]. Impaired venous drainage may produce upstream venous hypertension, which may manifest as elevated ICP, as CSF is reabsorbed into the cerebral venous system, at least partially, through pressure-dependent mechanisms. Neurological symptoms may arise through interacting effects of cerebral venous congestion on tissue and neurons and elevated ICP on pain-sensitive structures and intracranial or intraspinal veins [162].

The transverse sinus (TS) stenosis that develops in patients with intracranial hypertension is thought to be dynamic in many patients, involving a positive-feedback loop: elevated ICP causes compression of the TS, leading to venous congestion and hypertension, thereby resulting in higher ICP and further compression of the sinus. A similar CSF pressure effect on cortical and deep veins has been hypothesized, potentially further exacerbating venous congestion [162].

Extracranial venous obstruction may further contribute to impaired cerebral venous outflow. The internal jugular veins (IJV) are highly compliant, with caliber varying according to posture and transmural pressure [168], while surrounding anatomical structures may cause fixed or dynamic compression [169]. Focal compression most commonly occurs at the rostral IJV within the styloid–C1 corridor, where the styloid process, C1 transverse process, or their anatomical relationship may compress the vein [169,170]. A high prevalence of styloidogenic jugular stenosis has been reported in a selected CTD cohort [171].

© 2026 by the author(s). Distributed under a Creative Commons CC BY license.

Preprints.org | NOT PEER-REVIEWED | Posted: 24 November 2026 https://doi.org/10.20944/preprints202611.2421.v1

Mechanism-Linked Verifiers

Structural and vascular imaging may support intracranial pressure dysregulation or impaired venous outflow through findings such as empty sella, optic nerve sheath distension or tortuosity, posterior globe flattening, transverse sinus stenosis, IJV compression, and collateral drainage [169,172]. Magnetic resonance venography and computed tomography venography characterize venous anatomy, while catheter venography with manometry quantifies pressure gradients and assesses for collateral venous pathways [169,171].

Dynamic venography with manometry or Doppler ultrasonography during head rotation or flexion may identify positional IJV obstruction [171,173]. Head rotation and cervical flexion may further alter IJV caliber and trans-stenotic pressure gradients, with corresponding changes in intracranial venous and CSF pressures, providing physiologic evidence linking positional venous obstruction to intracranial pressure regulation [174]. Clinical improvement following targeted decompression may support the physiologic significance of an identified obstruction [161,175–177].

ICP monitoring may reveal abnormalities missed by a single opening-pressure measurement, while positional or Valsalva responses and waveform analysis may characterize pressure regulation and compensatory reserve [178–180]. Phase-contrast MRI may assess CSF flow and pulsatility [181]. Symptom improvement following CSF removal may further support a pressure-responsive phenotype [171].

5. Neurovascular and Visceral Compression Syndromes

1.1. Eagle Syndrome

Clinical Phenotype and Connective-Tissue Context

Eagle syndrome (ES) is symptomatic styloidogenic neurovascular compression caused by styloid hypertrophy (SH) or stylohyoid ligament ossification. Two principal phenotypes are traditionally recognized: Classic ES, presenting predominantly with cervicopharyngeal pain and glossopharyngeal symptoms, and Vascular ES, involving carotid compression or irritation with neurovascular manifestations [182]. More recently, styloidogenic internal jugular vein compression has been described, variably termed the jugular variant of ES [183,184] In patients with HCTDs, ES may present with a distinct neuro-autonomic phenotype characterized by overlapping auditory, otalgic, bulbar, dysautonomic, and systemic manifestations [14].

In a cohort of 2,003 neurologically symptomatic patients with HCTDs, predominantly hEDS, SH was present in 16.2%, within contemporary CT-based general-population estimates [185,186]. In contrast, 7.5% of the cohort met criteria for Definite or Probable ES, substantially exceeding the reported general-population prevalence of 0.1–0.4% [14,187]. This discrepancy suggests that HCTDs may increase susceptibility to symptomatic styloidogenic pathology rather than to the underlying anatomical abnormality itself and that ES may be an underrecognized contributor to neurological symptom burden in this population, although referral to a tertiary center cannot be excluded as a contributor.

Candidate Mechanisms

In patients with HCTDs, altered connective-tissue mechanics, ligamentous laxity, and altered craniocervical biomechanics may modify relationships between the styloid–stylohyoid complex and adjacent neural and vascular structures [44,69,188].

Glossopharyngeal stretch neuropathy represents one candidate mechanism underlying the neuro-autonomic phenotype. Intermittent traction or compression of cranial nerve IX (CN IX) and adjacent neurovascular structures may produce broader glossopharyngeal dysfunction than the classic pain-predominant phenotype, supported by the predominance of glossopharyngeal symptoms and their functional verification by nerve block. Enrichment of dysautonomic and systemic features, including blood-pressure lability, cardiac rhythm disturbances, nausea, and

© 2026 by the author(s). Distributed under a Creative Commons CC BY license.

Preprints.org | NOT PEER-REVIEWED | Posted: 24 November 2026 https://doi.org/10.20944/preprints202611.2421.v1

dyspnea, suggests secondary engagement of vagal and central autonomic pathways in a population with pre-existing autonomic vulnerability, possibly including carotid sinus baroreceptor afferents (CN IX) [14]. Fibrosis or scar tissue involving the stylohyoid complex may also contribute to local cranial nerve irritation, particularly following pharyngeal trauma or surgery [189,190].

Styloidogenic jugular compression within the styloid–C1 corridor may represent a parallel mechanism. It may impair cerebral venous outflow and alter intracranial pressure physiology [66,176], and is increasingly recognized in CTD-enriched populations with cerebral venous outflow disorders [171].

Modifiers

Local trauma and prior oropharyngeal or craniocervical procedures may modify ES expression by altering local anatomical and mechanical relationships. Altered ECM organization and remodeling in HCTDs may further modify tissue responses to injury or surgery [73,191,192]. In a CTD cohort, head or neck trauma and prior craniocervical fusion were significantly enriched with increasing ES diagnostic likelihood [14].

Mechanism-Linked Verifiers

Because SH is frequently incidental, verification requires evidence linking anatomy to clinical phenotype. Thin-slice CT with 3D reconstruction characterizes styloid–stylohyoid length, angulation, and mineralization. Reproduction of characteristic symptoms with palpation or other targeted provocation of the styloid region/tonsillar fossa region may provide functional evidence linking symptoms to the styloid–stylohyoid complex, although examiner-dependent [182].

For suspected neural involvement, targeted glossopharyngeal nerve block transiently interrupts CN IX afferent signaling; concordant symptom improvement implicates the glossopharyngeal nerve in symptom generation [14,193]. For suspected vascular involvement, CT/MR angiography or venography with dynamic, position-dependent imaging and hemodynamic assessment may demonstrate carotid or jugular compression and its physiological consequences [184]. Concordant improvement in venous outflow and clinical manifestations following targeted decompression may provide additional mechanism-linked evidence, although therapeutic response alone does not establish causality [184,194].

1.2. Median Arcuate Ligament Syndrome

Clinical Phenotype and Connective-Tissue Context

Median arcuate ligament syndrome (MALS), also known as Dunbar syndrome, is a chronic pain syndrome characterized by symptomatic compression of the celiac axis and surrounding celiac neural plexus by the median arcuate ligament. Typical manifestations include postprandial epigastric pain, nausea, early satiety, food avoidance, and weight loss [195].

MALS may be enriched in hEDS/HSD, where recognition is complicated by overlapping gastrointestinal dysmotility, dysautonomia, abdominal pain, and nutritional impairment. Earlier clinical experience described MALS and SMAS in patients with hEDS/HSD, highlighting the potential contribution of abdominal compression syndromes to gastrointestinal symptoms [196]. An hEDS-specific cohort identified 45 patients with MALS, with frequent postprandial pain, postural symptom modulation, and co-occurring vascular compression syndromes; a recent systematic review similarly supports a possible association between EDS/HSD and abdominopelvic vascular compression syndromes, while emphasizing that evidence specific to EDS/HSD remains limited [197,198].

Candidate Mechanisms

MALS may involve both vascular compression (dynamic or fixed) and celiac plexus irritation. Respiratory- and position-dependent relationships among the diaphragm, median arcuate ligament, celiac axis, and surrounding tissues may alter arterial compression and splanchnic perfusion, while

© 2026 by the author(s). Distributed under a Creative Commons CC BY license.

Preprints.org | NOT PEER-REVIEWED | Posted: 24 November 2026 https://doi.org/10.20944/preprints202611.2421.v1

celiac plexus irritation may contribute to symptoms independent of arterial stenosis [195,199]. In hEDS/HSD, altered ligamentous and fascial properties may increase susceptibility to developing a low lying median arcuate ligament that is the anatomic basis for MALS, although a mechanism specific to hEDS/HSD remains unproven [197,198].

Modifiers

Low BMI has been associated with MALS, while postprandial symptoms and food avoidance may drive further weight loss, potentially reinforcing disease expression [198,200].

Mechanism-Linked Verifiers

Verification should demonstrate concordance between symptoms and dynamic celiac-axis or celiac-plexus dysfunction, rather than arterial narrowing alone. Duplex ultrasonography can demonstrate respiratory variation in celiac artery velocity and morphology, while CTA/MRA can characterize proximal celiac artery compression, poststenotic changes, and collateralization [195,201].

Celiac plexus block may provide clinical evidence of a predominantly neurogenic mechanism when temporary interruption of plexus signaling produces concordant symptom improvement [202]. Response to celiac plexus block has also been associated with favorable outcomes following median arcuate ligament release, providing potential prognostic as well as mechanistic information [202,203]. Although response to celiac plexus block is used to support diagnosis and guide surgical selection, its predictive accuracy remains uncertain in the absence of adequately controlled validation studies.

1.3. May-Thurner Syndrome/Non-Thrombotic Iliac Vein Lesion

Clinical Phenotype and Connective-Tissue Context

Non-thrombotic iliac vein lesion (NIVL), or May-Thurner syndrome, occurs when the left common iliac vein (LCIV) is compressed between the right common iliac artery and the lumbar spine. While historically associated with unilateral left leg pain or swelling, deep vein thrombosis, wounds, varicose veins and venous claudication, recent literature suggests a wider range of clinical expressions including chronic pelvic pain, low back pain, bladder and bowel dysfunction, postural orthostatic tachycardia syndrome/orthostatic intolerance (POTS/OI), headaches, myalgic encephalomyelitis/chronic fatigue syndrome (ME/CFS), brain fog, post-exertional malaise and possibly non-epileptiform seizure activity [204].

An association with hEDS/HSD is emerging. Significant (>50%) LCIV compression was identified on CT in 68% of patients with hEDS and 65.6% with HSD compared with 35% of controls (Ogunlade et al., 2026). Recent systematic review similarly supports a possible association between EDS/HSD and abdominopelvic vascular compression syndromes while emphasizing that evidence specific to EDS/HSD remains limited [197].

Candidate Mechanisms

NIVL causes impaired venous return and elevated venous pressures within the pelvis, leading to collateralization through the presacral, paralumbar, and epidural venous plexuses [205]. While the exact mechanisms are not clearly elucidated in the literature, elevated pressures within spinal venous plexuses have been proposed as a potential contributor to intracranial pressure dysregulation, while impaired pelvic venous return may reduce cardiac preload [206]. Reduced venous return and preload may provide a potential link between iliac venous obstruction and dysautonomia. Iliac obstruction may compound dependent venous pooling and thereby increase orthostatic stress; observational studies report improvement in orthostatic symptoms following iliac vein stenting, supporting further investigation of this mechanism [204,207,208].

Altered connective-tissue support, vascular compliance, and pelvic biomechanics may increase susceptibility to clinically significant compression in hEDS/HSD, although the underlying mechanism remains unproven [197,209].

© 2026 by the author(s). Distributed under a Creative Commons CC BY license.

Preprints.org | NOT PEER-REVIEWED | Posted: 24 November 2026 https://doi.org/10.20944/preprints202611.2421.v1

Mechanism-Linked Verifiers

Verification should establish hemodynamically and clinically significant venous obstruction rather than anatomical compression alone. CT/MR venography and Doppler imaging may demonstrate iliac compression and collateral venous pathways, while catheter venography with intravascular ultrasound (IVUS) is considered the gold standard and can provide more direct anatomical and hemodynamic assessment. Recent POTS/OI data demonstrated that compared with venography and IVUS, significant iliac vein compression was missed 50% of the time on CT, 46% of the time on ultrasound, and 13% of the time on MRI, suggesting that these are reasonable screening exams but in levels of high clinical suspicion venography and intravascular ultrasound may still be warranted [204]. Concordant improvement in venous outflow and orthostatic symptoms following targeted intervention may provide additional mechanism-linked evidence, although therapeutic response alone does not establish causality [204].

1.4. Nutcracker Syndrome

Clinical Phenotype and Connective-Tissue Context

Nutcracker syndrome (NCS) results from clinically significant compression of the left renal vein, most commonly between the superior mesenteric artery and aorta, producing renal venous hypertension and collateral drainage through gonadal, lumbar, and pelvic veins. Manifestations include hematuria, flank or abdominal pain, orthostatic proteinuria, pelvic venous congestion, pelvic pain, dyspareunia, and varicocele [210].

NCS has been reported in patients with EDS/hypermobility, but the strength and prevalence of this association remain poorly defined [197,211]. Recent case reports and series have also described persistent headaches associated with nutcracker physiology in hypermobile patients, accompanied by retrograde lumbar venous flow and spinal epidural venous congestion, suggesting a potential neurovascular manifestation [212–214].

Candidate Mechanisms

The primary mechanism is mechanical left renal vein (LRV) compression resulting in renal venous hypertension and development of collateral venous pathways. In patients with HCTDs, altered connective tissue support, vascular compliance, and positional relationships among the mesenteric vessels and surrounding structures may plausibly modify susceptibility to compression. Retrograde drainage through lumbar veins may also produce spinal epidural venous congestion, potentially altering craniospinal venous and CSF dynamics and contributing to neurological manifestations, including persistent headache [213,214].

Modifiers

Low body mass and reduced retroperitoneal fat may narrow the aortomesenteric angle and are recognized modifiers of anterior NCS [215].

Mechanism-Linked Verifiers

Verification should establish clinically and hemodynamically significant LRV compression rather than anatomical narrowing alone. Doppler ultrasonography may demonstrate altered LRV diameter and flow velocity, while CT or MR angiography can characterize compression, aortomesenteric anatomy, and collateral venous pathways. Catheter venography with renocaval pressure-gradient measurement and intravascular ultrasound may provide additional anatomical and hemodynamic evidence, although collateral decompression can normalize pressure gradients despite clinically significant obstruction [210,215,216]. In selected patients, demonstration of retrograde lumbar venous flow and spinal epidural venous congestion, with symptomatic

© 2026 by the author(s). Distributed under a Creative Commons CC BY license.

Preprints.org | NOT PEER-REVIEWED | Posted: 24 November 2026 https://doi.org/10.20944/preprints202611.2421.v1

improvement following embolization, provides preliminary intervention-linked evidence for this proposed mechanism [213].

1.5. Superior Mesenteric Artery Syndrome (SMAS)

Clinical Phenotype and Connective-Tissue Context

Superior mesenteric artery syndrome (SMAS) results from compression of the third portion of the duodenum between the superior mesenteric artery (SMA) and aorta, typically associated with reduced aortomesenteric angle and distance. Manifestations include postprandial abdominal pain, early satiety, nausea, vomiting, distension, reduced intake, and weight loss, with positional variation in some patients [217].

SMAS has been reported in hEDS/HSD, including patients with coexisting MALS, Nutcracker syndrome, and other compression syndromes, raising the possibility of a broader connective-tissue-related susceptibility to visceral and vascular compression, although prevalence and causality remain uncertain [196,197,218]. Recognition may be particularly difficult in hEDS/HSD populations because dysmotility, dysautonomia, nausea, early satiety, restricted oral intake, and weight loss may produce an overlapping phenotype.

Candidate Mechanisms

The established mechanism is mechanical duodenal compression from narrowing of the aortomesenteric space, commonly influenced by loss of mesenteric/retroperitoneal fat and other anatomical factors [217,219].

In hEDS/HSD, altered connective-tissue support and visceral mobility represent plausible additional modifiers, but a CTD-specific mechanism has not been established. Abnormal fascial or ligamentous material properties could theoretically modify relationships among the mesenteric root, duodenum, vessels, and surrounding tissues, potentially altering susceptibility to dynamic compression [220,221]. At present, this should be regarded as a mechanistic hypothesis rather than established disease biology.

Modifiers

Body habitus, rapid weight loss, nutritional status, lumbar lordosis, body position, and prior abdominal or spinal surgery may modify clinical expression [217,219,222].

Mechanism-Linked Verifiers

Verification should demonstrate concordance between symptoms, abnormal aortomesenteric anatomy, and objective duodenal compression rather than reduced angle or distance alone. CT/CTA, upper-GI contrast studies, and direct endoscopic visualization may provide complementary anatomical, functional, and positional evidence of obstruction or duodenal compression [217,219,223].

1.6. Thoracic Outlet Syndrome

Clinical Phenotype and Connective-Tissue Context

Thoracic outlet syndrome (TOS) encompasses neurogenic (nTOS), venous (vTOS), and arterial (aTOS) compression of the brachial plexus or subclavian vessels within the interscalene triangle, costoclavicular space, or subpectoral region. Neurogenic TOS accounts for most cases and may present with upper-extremity pain, paresthesias, heaviness, fatigue, and weakness, often exacerbated by arm elevation or dependency [224]. True neurogenic TOS, characterized by objective electrodiagnostic abnormalities, should be distinguished from the more common clinically defined form, for which diagnostic specificity remains debated [225].

© 2026 by the author(s). Distributed under a Creative Commons CC BY license.

Preprints.org | NOT PEER-REVIEWED | Posted: 24 November 2026 https://doi.org/10.20944/preprints202611.2421.v1

TOS may be particularly relevant in hypermobility disorders. In a selected cohort of athletes undergoing surgical decompression, 62% had significant joint hypermobility [226]. A retrospective series of 28 patients with hEDS and TOS identified nTOS in 26, frequently accompanied by cervical pathology and prior upper-extremity procedures [227].

Candidate Mechanisms

TOS results from fixed or dynamic neurovascular compression involving cervical ribs, fibrous bands, scalene hypertrophy or fibrosis, or narrowing of the costoclavicular or subpectoral spaces [224,228].

In HCTDs, ligamentous laxity and impaired scapular stabilization may permit excessive clavicular descent, scapular protraction, or first-rib motion, dynamically narrowing the thoracic outlet. Increased tissue extensibility may also expose the brachial plexus to repetitive traction during arm and neck movement. Compensatory scalene activation associated with cervical instability may further contribute to compression, although these CTD-specific mechanisms remain hypothetical. Possible interactions with autonomic or cerebral hemodynamic dysfunction warrant investigation [229].

Modifiers

Neck or shoulder trauma, repetitive overhead activity, and prior upper-extremity or cervical surgery may precipitate or exacerbate TOS symptoms [227,230]. Coexisting cervical or craniocervical instability, scapular dyskinesis, peripheral nerve entrapment, and central sensitization may further influence symptom expression and complicate identification of the underlying mechanisms.

Mechanism-Linked Verifiers

Verification should establish concordance between symptoms and objective evidence of neurovascular compression. Conventional provocative maneuvers have limited specificity, with high false-positive rates [231]. The Society for Vascular Surgery criteria for nTOS incorporate characteristic symptoms, signs of nerve compression, exclusion of alternative diagnoses, and response to scalene muscle injection [224]. Electrodiagnostic studies may demonstrate lower-trunk brachial plexopathy in true nTOS but are frequently normal in clinically defined nTOS [225].

Dynamic ultrasonography and positional CT angiography or venography may demonstrate vascular compression, while catheter venography with positional maneuvers can characterize vTOS [232]. Diagnostic scalene blocks may provide supportive localization evidence, although symptomatic responses alone do not establish causality [233].

1.7. Peripheral Nerve Entrapment Syndromes

Clinical Phenotype and Connective-Tissue Context

Peripheral nerve entrapment may present with focal pain, paresthesias, numbness, weakness, or other sensory and motor deficits in the distribution of the affected nerve. In HCTDs, altered ligamentous and fascial properties may increase susceptibility to abnormal nerve excursion, traction, or compression during movement, potentially producing intermittent or position-dependent neurological symptoms. Ulnar nerve instability at the elbow is particularly well documented, whereas the prevalence and clinical significance of carpal tunnel and other entrapment neuropathies remain less well established [234,235].

Candidate Mechanisms

Peripheral nerves normally accommodate movement through controlled excursion and deformation. Excessive joint motion or reduced ligamentous and fascial restraint may increase nerve displacement, traction, compression, or friction, potentially impairing intraneural perfusion or axonal

© 2026 by the author(s). Distributed under a Creative Commons CC BY license.

Preprints.org | NOT PEER-REVIEWED | Posted: 24 November 2026 https://doi.org/10.20944/preprints202611.2421.v1

function and increasing mechanosensitivity [235]. Proximal tibiofibular joint instability provides another example: excessive fibular head motion may subject the common peroneal nerve to repetitive traction or compression [236,237], although its prevalence and clinical significance in HCTDs remain uncertain.

Modifiers

Repetitive movement, sustained joint positioning, trauma, and prior surgery may precipitate or exacerbate peripheral nerve entrapment. In HCTDs, coexisting joint instability or subluxation may further increase mechanical stress on peripheral nerves.

Mechanism-Linked Verifiers

Dynamic ultrasonography can directly demonstrate abnormal nerve excursion, subluxation/luxation, or position-dependent compression during provocative movement. Electrodiagnostic studies may identify associated large-fiber dysfunction, while targeted imaging and provocative testing can help localize specific entrapment sites [235,238].

Neuro-Autonomic-Inflammatory Domain

1. Dysautonomia And Orthostatic Intolerance

Clinical Phenotype and Connective-Tissue Context

Dysautonomia is prominent in hEDS/HSD and may involve cardiovascular, vasomotor, sudomotor, gastrointestinal, genitourinary, and temperature dysregulation. Orthostatic intolerance (OI) is particularly common and encompasses a heterogeneous spectrum that includes POTS, orthostatic hypotension, neurally mediated hypotension, and symptomatic cerebral hypoperfusion without conventional heart-rate or blood-pressure abnormalities. Manifestations include lightheadedness, presyncope, syncope, fatigue, headache, cognitive dysfunction, palpitations, tremulousness, dyspnea, chest pain, diaphoresis, exercise intolerance, nausea, and visual disturbance during upright posture [239–244].

Recent data reinforce this heterogeneity. Among 270 patients with hEDS referred for specialized autonomic evaluation, mild autonomic failure abnormalities were identified in 90%, including POTS, hypocapnic cerebral hypoperfusion, orthostatic cerebral hypoperfusion syndrome, and neurogenic orthostatic hypotension [240]. Orthostatic cerebral blood-flow velocity was reduced in 79%, an abnormality not captured by standard heart-rate and blood-pressure analysis [240]. Similarly, among patients with ME/CFS, orthostatic cerebral blood-flow reduction was greater in those with joint hypermobility than in those without (32% vs 23%) [245].

Candidate Mechanisms

OI in hEDS/HSD is likely mechanistically heterogeneous. Altered vascular and connective-tissue properties may promote excessive venous capacitance and dependent pooling, reducing venous return. Reduced preload during upright posture may increase compensatory sympathetic activation and catecholamine release. Hypovolemia, excessive vasodilation, and impaired vasoconstriction may further amplify this phenotype [242,243,246]. Abnormal cardiovascular, orthostatic, and baroreflex regulation has also been reported, suggesting mechanisms beyond passive vascular pooling [239,241]. Cerebral hemodynamic dysregulation, including orthostatic cerebral hypoperfusion and hypocapnia, may contribute to orthostatic symptoms [240,244].

The central autonomic network (CAN), comprising interconnected brainstem and supratentorial regions, integrates visceral, baroreceptor, nociceptive, somatosensory, and respiratory inputs to coordinate autonomic regulation, with substantial overlap with networks involved in interoception and emotional processing [247,248]. Although altered central autonomic regulation represents a plausible candidate mechanism in hEDS/HSD, direct evidence of CAN dysfunction in this population

© 2026 by the author(s). Distributed under a Creative Commons CC BY license.

Preprints.org | NOT PEER-REVIEWED | Posted: 24 November 2026 https://doi.org/10.20944/preprints202611.2421.v1

remains limited. Autonomic manifestations may arise through central, peripheral, vascular, or interacting mechanisms, and the relative contributions of these processes have not been established [249–252]. Hyperadrenergic presentations and orthostatic hypertensive responses further highlight the heterogeneity of autonomic phenotypes without establishing a specific underlying mechanism [253]. Additional contributors in selected patients may include regional venous obstruction, mast-cell mediator effects on vascular tone and permeability, and neural compression from craniospinal pathology [204,207,208,254].

Peripheral autonomic small-fiber dysfunction may further impair vasomotor, sudomotor, thermoregulatory, and visceral regulation and is considered separately below [240,255–257].

Modifiers

Modifiers may include volume depletion, heat, prolonged upright posture, exertion, infection, hormonal changes, medications, alcohol, allergic or mast-cell activation, and other physiological stressors that alter circulatory or autonomic compensation [243,246].

Mechanism-Linked Verifiers

Mechanism-linked assessment should characterize underlying physiology rather than orthostatic diagnosis alone. Continuous heart-rate and beat-to-beat blood-pressure monitoring during active stand or head-up tilt can characterize systemic hemodynamic and baroreflex responses, while extracranial Doppler–derived cerebral blood flow, transcranial Doppler cerebral blood-flow velocity, and end-tidal CO_2 monitoring may identify cerebral hypoperfusion or hypocapnia not captured by conventional measurements. Autonomic reflex and sudomotor testing can further characterize cardiovagal, adrenergic, and postganglionic dysfunction, with skin biopsy providing complementary structural evidence when autonomic small-fiber neuropathy (SFN) is suspected [240,243,258]. The presence of SFN does not by itself establish the mechanism responsible for orthostatic symptoms.

2. Small-Fiber Neuropathy And Peripheral Neuropathic Dysfunction

Clinical Phenotype and Connective-Tissue Context

SFN is increasingly recognized in hEDS/HSD and may contribute to sensory and autonomic manifestations through dysfunction of small myelinated Aδ and unmyelinated C fibers, which mediate nociceptive, thermal, and postganglionic autonomic function. Manifestations may include neuropathic pain, paresthesias, allodynia, altered temperature sensation, and sudomotor, vasomotor, or visceral autonomic dysfunction [259]. Objective small-fiber abnormalities have been demonstrated across multiple hEDS/HSD cohorts using structural and functional measures [240,255–257].

Emerging evidence suggests that small-fiber involvement in hEDS may differ from conventional length-dependent neuropathy. Igharo et al. demonstrated proximal as well as distal small-fiber loss, supporting a generalized pattern of involvement, while Novak et al. identified SFN in 64% by structural criteria and 82% using combined structural and functional criteria in a large hEDS cohort [240,257]. More recently, direct comparison of hEDS-associated and idiopathic SFN demonstrated earlier onset, more generalized symptoms, greater autonomic symptom burden, and greater autonomic fiber loss despite similar intraepidermal sensory-fiber loss, suggesting a potentially distinctive pattern with disproportionate autonomic involvement in hEDS [260].

Candidate Mechanisms

The mechanisms underlying SFN in hEDS/HSD remain unknown. Altered connective-tissue and ECM properties may modify the mechanical or trophic microenvironment of peripheral nerves, potentially increasing susceptibility to stretch, compression, or impaired neural homeostasis. However, the generalized distribution of fiber loss and disproportionate autonomic involvement suggest that local mechanical injury alone is insufficient to explain the phenotype [257,260].

© 2026 by the author(s). Distributed under a Creative Commons CC BY license.

Preprints.org | NOT PEER-REVIEWED | Posted: 24 November 2026 https://doi.org/10.20944/preprints202611.2421.v1

Small-fiber–vascular interactions may represent an additional candidate mechanism. In a small hEDS family study, all participants demonstrated Aδ-fiber loss, while those with dysautonomia also exhibited C-fiber impairment and vascular hyperelasticity, suggesting a possible relationship among small-fiber dysfunction, vascular properties, and autonomic dysregulation [261].

Immune-mediated, metabolic, nutritional, infectious, hereditary, and ion-channel mechanisms are recognized causes of SFN more broadly and may contribute to mechanistic heterogeneity in hEDS/HSD; however, their specific contributions in this population remain unestablished [262]. Emerging serum proteomic findings in hEDS/HSD identify alterations in proteins associated with neuronal survival, oxidative-stress responses, and myelin and Schwann-cell biology, suggesting potential molecular correlates of peripheral neural dysfunction [263]. However, these findings have not been directly linked to small-fiber neuropathy and require phenotype-specific validation.

Mechanism-Linked Verifiers

Verification should integrate structural and functional assessment of both sensory and autonomic small fibers. Skin biopsy with intraepidermal nerve-fiber density provides structural evidence of sensory fiber loss, while quantitative sensory testing assesses sensory function; sudomotor and cardiovascular autonomic testing can characterize autonomic small-fiber dysfunction. Specialized skin-biopsy analysis of cutaneous autonomic innervation, including nerve fibers surrounding arteriovenous anastomoses, may provide additional structural evidence of autonomic fiber involvement, particularly given the greater autonomic fiber loss reported in hEDS-associated SFN compared with idiopathic SFN [260]. Conventional nerve-conduction studies remain useful for identifying concomitant large-fiber neuropathy. Corneal confocal microscopy is an emerging noninvasive structural measure, although its role in hEDS/HSD remains unestablished [264].

3. Mast-Cell And Immune-Inflammatory Dysfunction

Clinical Phenotype and Connective-Tissue Context

Mast-cell activation can produce multisystem manifestations through release of histamine, tryptase, prostaglandins, leukotrienes, cytokines, and other mediators. The clinical phenotype may include episodic flushing, pruritus, urticaria, gastrointestinal symptoms, tachycardia, presyncope, and anaphylaxis-like episodes. Headache, cognitive difficulties, and sensory hypersensitivity may also occur, although these manifestations are nonspecific and overlap with dysautonomia and other neurological conditions [265].

Mast-cell-related symptoms and mast cell activation syndrome (MCAS) are frequently reported in association with hEDS/HSD, dysautonomia, and gastrointestinal manifestations, although the magnitude and biological significance of these associations remain uncertain [266–268]. In a 2025 POTS cohort, estimated MCAS prevalence ranged from 2% using strict consensus criteria to 37% with broader laboratory-supported criteria and 87% using clinical criteria, illustrating the profound effect of diagnostic definition [269].

Immune abnormalities in hEDS/HSD may extend beyond mast-cell activation, including reported immunoglobulin deficiency and altered proteins associated with innate and adaptive immune signaling [263,266]. Complement-related differences have also been reported in hEDS, including reduced serum concentrations of C1qA, C3, C8α, and C8β (Griggs et al, 2025). Whether these findings reflect shared connective-tissue biology, altered complement regulation, secondary disease processes, or coincidental comorbidity remains unresolved.

Hereditary alpha-tryptasemia (HαT), associated with increased TPSAB1 copy number, has been investigated in individuals with hypermobility-related disorders. Although HαT prevalence was not increased in these populations, it was associated with differences in clinical presentation, suggesting a genetically identifiable modifier of phenotype rather than an established cause of hEDS/HSD or Neuro-EDS [270,271].

© 2026 by the author(s). Distributed under a Creative Commons CC BY license.

Preprints.org | NOT PEER-REVIEWED | Posted: 24 November 2026 https://doi.org/10.20944/preprints202611.2421.v1

Candidate Mechanisms

Mast cells reside within connective-tissue microenvironments, interacting with fibroblasts, extracellular matrix (ECM), peripheral nerves, and vasculature [268]. Their mediators influence vascular permeability, nociception, neuroimmune signaling, and tissue remodeling, potentially contributing to multisystem Neuro-EDS manifestations [265,268]. Tissue injury and sensory neuropeptide signaling, including substance P–mediated mast-cell activation, may provide a potential interface between peripheral nerves, connective tissue, and neuroimmune signaling [272,273].

Mechanical stress can induce mast-cell degranulation, while mast-cell mediators influence fibroblast activity and ECM remodeling, suggesting bidirectional interactions between tissue biomechanics and immune signaling [274–277].

Klinge et al. (2022) identified connective-tissue and biomechanical abnormalities alongside inflammatory-cell infiltration in the filum terminale of patients with hEDS-associated occult tethered cord, including CD117-positive mast cells in 5 of 19 specimens (26%). These findings provide tissue-level evidence of local immune-cell involvement in a subset of patients, although increased mast-cell density relative to controls and a causal relationship with mast-cell activation remain unestablished. Supporting broader ECM–immune interactions, hEDS/HSD fibroblast studies identified ECM-degrading and proinflammatory transcriptional signatures and candidate miRNA–mRNA regulatory networks [73,278].

Modifiers

Potential modifiers include atopy and allergic disease, infection or inflammation, medications, hormonal and environmental exposures.

Mechanism-Linked Verifiers

Current literature does not support separate diagnostic criteria for CTD-associated MCAS; consensus criteria require episodic multisystem symptoms, objective evidence of mast-cell mediator release, response to mediator-targeted therapy and ruling out conditions that mimic MCAS [265,279,280]. Broader diagnostic frameworks, including Consensus-2, have also been proposed, incorporating additional mediator measurements and clinical response patterns, although their specificity and validation remain debated [281]. Event-related serum tryptase remains the best-established biochemical marker, with a significant increase defined relative to the individual baseline using the baseline × 1.2 + 2 ng/mL criterion. Its sensitivity and diagnostic role remain debated, particularly because of sampling challenges [279,282].

Urinary N-methylhistamine, leukotriene E_4, and 2,3-dinor-11β-prostaglandin $F_2\alpha$ may provide complementary evidence, particularly when paired symptomatic and baseline samples are available, although their specificity, optimal timing, and diagnostic thresholds remain less well validated than serum tryptase [279,283,284].

Research-level approaches may include assessment of tissue mast-cell distribution, density, activation-associated markers, and spatial relationships with peripheral nerves and ECM, alongside circulating complement activation products or tissue complement deposition. Histological studies in hereditary alpha-tryptasemia and MCAS provide methodological precedents for examining tissue mast-cell phenotypes [285]. However, these tissue- and complement-based measures remain investigational and have not been validated as biomarkers of distinct Neuro-EDS endotypes.

4. Gastrointestinal Dysmotility and Disorders of Gut–Brain Interaction (DGBI)

Clinical Phenotype and Connective-Tissue Context

Gastrointestinal manifestations are highly prevalent in hEDS/HSD. A recent meta-analysis of 17,455 patients with hEDS/HSD found chronic GI symptoms in approximately 65%, with over fourfold higher odds than controls, and DGBI in approximately 44% [286]. Common manifestations

© 2026 by the author(s). Distributed under a Creative Commons CC BY license.

Preprints.org | NOT PEER-REVIEWED | Posted: 24 November 2026 https://doi.org/10.20944/preprints202611.2421.v1

include dysphagia, reflux, nausea, postprandial fullness, bloating and distension, abdominal pain, diarrhea, constipation, impaired evacuation, and fecal incontinence [221,287]. The GI phenotype frequently coexists with autonomic and pelvic-floor dysfunction, while overlapping mast-cell–mediated symptoms or disorders are also reported [286,287].

Candidate Mechanisms

Gastrointestinal manifestations in hEDS/HSD are likely mechanistically heterogeneous, with overlapping autonomic, neuropathic, sensory-processing, and connective-tissue contributions.

Autonomic dysfunction may contribute to altered motility, secretion, visceral sensation, and gastrointestinal regulation. POTS was independently associated with objectively documented gastrointestinal dysmotility in one hEDS cohort, supporting an autonomic contribution in at least a subset of patients, although causality has not been established [288]. Autonomic small-fiber dysfunction represents an additional potential contributor, although direct evidence linking SFN to gastrointestinal dysmotility in hEDS/HSD remains limited [289].

Small-intestinal microbial dysbiosis may represent a secondary amplifying mechanism in patients with impaired gastrointestinal motility, which can reduce normal small-bowel clearance and permit microbial overgrowth [290]. Recent data in patients with hypermobility disorders support this relationship, with microbial dysbiosis associated with delayed gastric emptying and dyssynergic defecation, although its contribution to gastrointestinal symptom expression remains incompletely defined [291].

Altered visceral afferent signaling and gut–brain processing may contribute to symptoms not explained by measurable dysmotility. Visceral hypersensitivity and altered mechanosensory processing may involve altered afferent signaling, connective-tissue–related differences in mechanosensation, and central sensitization, although these mechanisms remain incompletely characterized in hEDS/HSD [221,287].

Connective-tissue abnormalities may additionally contribute through altered structural support, tissue compliance, and visceral or pelvic-floor mechanics. Pelvic-floor dysfunction may impair evacuation through both functional and structural mechanisms. Abnormal rectoanal coordination, including reduced anal relaxation and elevated residual anal pressures during defecation, has been demonstrated in hEDS/HSD, while rectocele, rectal prolapse, and other morphological abnormalities may further impair evacuation [292–294].

Modifiers

Established IBS triggers, including prior gastrointestinal infection, psychological stress, poor sleep, hormonal fluctuations, and diet, may unmask or worsen symptoms [295–297]. Mast-cell patients report cold, friction, and fatigue as triggers [298] Alpha-gal syndrome, a tick-acquired condition overlapping with mast-cell disorders, may provoke GI symptoms [299,300].

Mechanism-Linked Verifiers

Mechanism-linked verification should be directed by the suspected gastrointestinal physiology rather than symptom pattern alone. Gastric emptying scintigraphy and, where available, assessment of gastric accommodation may characterize upper-GI motor dysfunction, particularly in patients with hEDS/HSD and comorbid POTS [287]. High-resolution esophageal manometry and 24-hour pH-impedance monitoring can distinguish esophageal motor disorders, pathological reflux, reflux hypersensitivity, and functional esophageal phenotypes [292,301]. In patients with impaired evacuation or pelvic-floor symptoms, anorectal manometry, balloon-expulsion testing, and defecography may identify defecatory dysfunction or rectal sensory abnormalities [287,294].

5. Headache, Cognitive Dysfunction, and Altered Central Processing

Clinical Phenotype and Connective-Tissue Context

© 2026 by the author(s). Distributed under a Creative Commons CC BY license.

Preprints.org | NOT PEER-REVIEWED | Posted: 24 November 2026 https://doi.org/10.20944/preprints202611.2421.v1

Headache and cognitive dysfunction are prominent neurological manifestations of hEDS/HSD, but neither represents a mechanistically uniform phenotype. Migraine is markedly enriched, while subjective cognitive dysfunction or "brain fog" is frequently reported; both may arise within a clinical context that includes autonomic dysfunction, altered cerebral hemodynamics, chronic nociceptive input, and craniospinal or CSF disorders [302,303]. Headache may therefore reflect primary migraine, secondary craniospinal or pressure-related mechanisms, or combinations of these processes within the same patient [302].

Emerging objective data are beginning to clarify potential contributors to cognitive dysfunction in hEDS/HSD. Greater orthostatic symptom burden has been associated with greater cognitive complaints at the population level, while neuropsychological testing demonstrates objective cognitive abnormalities that may vary with autonomic symptoms, pain, and body position [303,304].

Candidate Mechanisms

Cerebrovascular dysfunction may contribute to orthostatic neurological symptoms through reduced cerebral perfusion and hypocapnia. Orthostatic cerebral blood-flow velocity is frequently reduced in hEDS and is associated with lightheadedness and dizziness; together with frequent hypocapnia, these findings provide a physiological basis for investigating cerebral hemodynamic dysfunction as one potential contributor to cognitive symptoms [240].

Primary migraine and altered central sensory processing represent a distinct but potentially overlapping pathway. Migraine involves dysfunction across trigeminovascular and distributed thalamic, cortical, brainstem, and hypothalamic networks; in hEDS/HSD, this biology may coexist with autonomic dysfunction, cervical nociceptive input, sleep disturbance, and chronic pain, potentially amplifying headache burden and sensory hypersensitivity [302,305].

Central sensitization may contribute to headache, widespread pain, sensory hypersensitivity, and altered central processing. Pain in hEDS/HSD may involve overlapping nociceptive mechanisms associated with musculoskeletal injury or instability, neuropathic mechanisms associated with nerve dysfunction, and nociplastic mechanisms involving altered nociceptive processing without sufficient evidence of tissue damage or somatosensory system disease to explain the pain [306,307]. Experimental studies in adolescents with HSD/hEDS demonstrate generalized hyperalgesia and altered exercise-induced hypoalgesia, while a recent adult cohort identified central-sensitization features associated with multisystem symptom burden [308,309].

Modifiers

Headache and cognitive symptoms may be modified by posture, exertion, sleep disruption, pain, medications, hormonal changes, and psychological stress. Coexisting dysautonomia, migraine, cervical pain, and craniospinal or CSF-pressure disorders may further modify symptom expression and should be considered when interpreting headache or cognitive complaints.

Mechanism-Linked Verifiers

In patients with orthostatic symptoms, continuous heart-rate and blood-pressure monitoring combined with cerebral blood-flow assessment and end-tidal CO_2 during orthostatic challenge may identify cerebral hypoperfusion or hypocapnia and permit correlation with concurrent headache or cognitive symptoms. For migraine and altered sensory processing, standardized headache phenotyping and validated migraine measures can characterize the clinical phenotype, while quantitative sensory testing, including temporal summation and conditioned pain modulation, may characterize altered nociceptive processing and endogenous pain modulation [310,311]. When secondary headache is suspected, mechanism-specific evaluation for CSF-pressure disorders, cerebral venous outflow impairment, or craniospinal pathology should be guided by the corresponding structural and physiological verifiers described above.

6. Fatigue, Exercise Intolerance, Post-Exertional Malaise, and ME/CFS-Like Phenotypes

© 2026 by the author(s). Distributed under a Creative Commons CC BY license.

Preprints.org | NOT PEER-REVIEWED | Posted: 24 November 2026 https://doi.org/10.20944/preprints202611.2421.v1

Clinical Phenotype and Connective-Tissue Context

Fatigue is common in hEDS/HSD but should be distinguished from exercise intolerance and post-exertional malaise (PEM) [246]. Chronic fatigue occurs in approximately 49% of patients with hEDS/HSD [286]. Exercise intolerance may include disproportionate pain and fatigability during activity, while PEM is characterized by disproportionate symptom worsening following exertion, which may be delayed and followed by prolonged recovery [312,313]. Joint hypermobility is enriched in ME/CFS populations, supporting clinical overlap without establishing a shared mechanism [314]. Joint hypermobility has been identified as a potential mediator of the association between chronic fatigue and neurodivergence, including neurodevelopmental conditions such as autism spectrum disorder (ASD) and attention-deficit/hyperactivity disorder (ADHD) [315].

Candidate Mechanisms

Autonomic and hemodynamic dysfunction may contribute to fatigue and exercise intolerance. Autonomic symptom burden is associated with greater fatigue and pain, and dysautonomia with exercise intolerance and reduced activity; objective autonomic and cerebral-perfusion abnormalities provide plausible physiological mechanisms for exertional limitation [239,240,316].

Neuromuscular and biomechanical inefficiency may further contribute to physical fatigability. hEDS/HSD studies demonstrate increased metabolic cost of walking, reduced tendon stiffness and ankle power, and altered muscle activation and co-contraction [317–319].

ME/CFS-like post-exertional physiology may be relevant in patients with reproducible PEM. Microvascular, metabolic, mitochondrial/redox, and immune-inflammatory abnormalities have been implicated in ME/CFS and post-COVID PEM, but whether these mechanisms contribute to fatigue and PEM in hEDS/HSD remains uncertain [320,321]. Nonetheless, serum proteomic signatures of oxidative stress, one-carbon metabolism, and immune activation have recently been reported in hEDS/HSD [263], providing a rationale for investigating their relationship with fatigue and PEM. Infection may precipitate or amplify PEM, although whether hEDS/HSD modifies susceptibility to post-infectious syndromes remains unknown [322]. Notably, observational studies have identified an association between generalized joint hypermobility and increased odds of incomplete recovery following COVID-19 infection or subsequent Long COVID [323,324]. These findings support further investigation into whether connective-tissue phenotypes influence susceptibility to persistent post-infectious illness.

Modifiers

Infection, sleep disruption, pain, heat, and orthostatic or physical stress may precipitate or amplify fatigue and PEM.

Mechanism-Linked Verifiers

Mechanism-linked assessment may include validated fatigue/PEM measures, cardiopulmonary exercise testing (CPET), and autonomic/cerebral-hemodynamic testing. Two-day CPET can characterize impaired post-exertional recovery in ME/CFS, although its role in hEDS/HSD remains unestablished [325,326].

7. Sleep Dysfunction

Clinical Phenotype and Connective-Tissue Context

Sleep disturbance is a common, underrecognized feature across hypermobility-related and HCTDs. Manifestations include obstructive sleep apnea (OSA) and other sleep-disordered breathing, nonrestorative sleep, insomnia, nocturnal awakenings, daytime sleepiness, and periodic limb movements [327–329]. In one HSD/hEDS cohort, 93% reported bothersome insomnia [330].

© 2026 by the author(s). Distributed under a Creative Commons CC BY license.

Preprints.org | NOT PEER-REVIEWED | Posted: 24 November 2026 https://doi.org/10.20944/preprints202611.2421.v1

OSA is the best-characterized sleep disorder. A meta-analysis (7 EDS, 6 Marfan studies) found pooled OSA prevalence of 48.9% across both populations, with approximately sixfold higher odds of OSA than the general population (OR 6.28) [331]. In a matched adult EDS cohort, OSA was present in 32% versus 6% of controls (OR 5.3), and all 34 EDS patients in a selected cohort had sleep-disordered breathing [328,332]. Pediatric EDS shows OSA in ~42% versus 13%, with a 4.43-fold increased risk in a 10,104-patient database [333,334]. Notably, once apnea is present, severity (apnea–hypopnea index [AHI], nadir SpO_2) is not worse than BMI-matched controls [335].

Candidate Mechanisms

Sleep disruption in hEDS/HSD is likely multifactorial. Chronic nocturnal pain may contribute to a bidirectional pain–sleep cycle via impaired endogenous pain inhibition while autonomic dysregulation could contribute to nonrestorative sleep and morning fatigue [329,332,335–337]. Craniofacial, upper-airway, and connective-tissue abnormalities may promote airway collapse and susceptibility to sleep-disordered breathing in selected patients [332,335,338]. Circadian dysregulation, restless legs, medication effects, and coexisting anxiety and depression can further modify sleep quality and timing [327,329,339].

Mechanism-Linked Verifiers

Verification should be guided by the suspected sleep mechanism. Sleep diaries, validated questionnaires, and actigraphy can characterize sleep timing and continuity; however, questionnaires may miss OSA in some CTD populations, including children with Marfan syndrome, supporting a low threshold for polysomnography [340]. Polysomnography can identify sleep-disordered breathing, periodic limb movements, and other abnormalities of sleep architecture. Targeted evaluation for restless legs, circadian rhythm disorders, medication effects, and hypersomnolence may further define contributing mechanisms.

8. Neurodevelopmental and Neuropsychiatric Manifestations

Clinical Phenotype and Connective-Tissue Context

The neuropsychiatric burden associated with EDS, particularly hEDS, is substantial and multidimensional, encompassing psychiatric comorbidity, neurodevelopmental differences, altered sensory and interoceptive processing, and autonomic dysfunction [341–345]. Associations between joint hypermobility and functional somatic syndromes have also been reported [346].

Anxiety and depression are among the most consistently reported psychiatric associations [342,347]. Population-based data have demonstrated increased rates of ASD, ADHD, depression, bipolar disorder, and suicide attempts in individuals with EDS [348]. Additional studies have identified associations between joint hypermobility and neurodevelopmental conditions, particularly ASD and ADHD [343,349], while emerging literature has explored the overlap with bipolar disorder and neurodivergence [341]. Increased ADHD and depression among siblings without an EDS diagnosis suggest that shared familial or developmental susceptibility may contribute to these associations [348]. The longstanding association between joint hypermobility and anxiety-spectrum symptoms is also well documented [342,350]. Differences in executive function, memory, interoception, sensory processing, and pain perception have been described, although their specific biological relationship to hEDS/HSD remains incompletely defined [351].

Candidate Mechanisms

Potential mechanisms include shared familial and neurodevelopmental susceptibility [348,352], autonomic and interoceptive dysregulation, and altered central processing of physiological and emotional signals. Neuroimaging and experimental assessments of interoception have identified associations among joint hypermobility, anxiety, and differences in the structure or function of brain

© 2026 by the author(s). Distributed under a Creative Commons CC BY license.

Preprints.org | NOT PEER-REVIEWED | Posted: 24 November 2026 https://doi.org/10.20944/preprints202611.2421.v1

regions involved in emotional and bodily-state processing, particularly the insula and amygdala [353,354].

Autonomic dysfunction, including POTS and orthostatic intolerance, may interact with altered interoceptive processing, potentially influencing physiological arousal and the perception and interpretation of bodily signals. Within predictive-processing models, unexpected physiological sensations, such as episodes of tachycardia, may generate interoceptive prediction errors that contribute to anxiety-spectrum symptoms [350,351].

Modifiers

The EDS–neuropsychiatric relationship may be modified by chronic pain, fatigue, sleep dysfunction, functional impairment, pain catastrophizing, and coping responses. Depressive symptoms in hEDS/HSD have been associated with fatigue and pain catastrophizing [355]. Diagnostic delay and experiences of symptom invalidation may further amplify psychological distress.

Mechanism-Linked Verifiers

At present, validated objective biomarkers linking neurodevelopmental and neuropsychiatric manifestations in hEDS/HSD to specific underlying biological mechanisms are lacking. Candidate mechanism-linked verifiers may include standardized experimental assessments of interoceptive processing [158,356], quantitative sensory testing [357], and experimental paradigms integrating autonomic physiology with subjective perception of bodily signals. Simultaneous measurement of physiological responses, interoceptive performance, and symptom perception during standardized autonomic challenges may help characterize the relative contributions of autonomic abnormalities and altered central processing of physiological signals. However, these approaches remain investigational as mechanism-linked verifiers in hEDS/HSD and require prospective validation.

The Neuroconnective Endophenotype Questionnaire (NEQ) is a multidimensional instrument integrating sensory sensitivity, somatic manifestations, behavioral patterns, and psychological and psychopathological features. Initial validation demonstrated acceptable reliability and discrimination between anxiety cases and controls, supporting its potential to identify clinically coherent patterns across domains [358]. Its biological rationale is supported by evidence involving autonomic dysfunction, altered interoception, somatosensory processing, familial susceptibility, and emotion-processing mechanisms [342,350,351]. The NEQ may facilitate integration of clinical phenotyping with objective autonomic, neurological, neuroimaging, genetic, immune, and extracellular-matrix measures, including emerging circulating molecular signatures identified in hEDS/HSD [263,359]. As a clinical phenotyping instrument rather than a mechanism-linked verifier, its contribution to endotype discovery will depend on demonstrating that NEQ-defined patterns correspond to reproducible biological findings in independent cohorts.

From Candidate Mechanisms to Endotype Discovery

Despite the clinical and multisystem heterogeneity of Neuro-EDS, recurring candidate mechanisms emerge across its manifestations. These include altered connective-tissue and extracellular-matrix biology; abnormal biomechanics, mechanotransduction, and neural deformation; altered CSF and pressure–volume physiology; vascular, venous, and cerebral hemodynamic dysfunction; autonomic dysregulation; and neuroimmune and inflammatory processes.

Connectivetissue and Cellular Biology as a Shared Substrate

Relevant connective-tissue biology spans tissue-level organization and biomechanics, ECM–cell interactions, and cellular signaling. Connective tissue is distributed throughout the body, forming fascia, ligaments, tendons, bone, cartilage, the stromal framework of organs, and supporting matrices

© 2026 by the author(s). Distributed under a Creative Commons CC BY license.

Preprints.org | NOT PEER-REVIEWED | Posted: 24 November 2026 https://doi.org/10.20944/preprints202611.2421.v1

of neural and vascular structures. Despite their structural and functional diversity, connective tissues share a dynamic interplay among ECM, resident cells, and mechanical forces. The ECM undergoes continuous synthesis, remodeling, and degradation, while providing structural, biochemical, and mechanical cues to resident cells. Through mechanotransduction, cells translate these cues into intracellular signals that regulate cellular behavior and, in turn, remodel the surrounding matrix. Disruption of this reciprocal relationship may alter both tissue biomechanics and cellular function [360].

Within this system, fascia represents a particularly relevant body-wide connective-tissue network, continuous across anatomical regions and intimately associated with muscles, joints, nerves, blood vessels, lymphatics, and viscera. Beyond structural support, fascia participates in force transmission, tissue gliding, mechanosensation and proprioception, and provides an interface through which mechanical, neural, vascular, and immune processes may interact [361,362]. In hEDS/HSD, imaging and biomechanical studies demonstrate altered fascial thickness and architecture, reduced stiffness, and impaired interfascial gliding, providing tissue-level evidence of altered connective-tissue mechanics [362–364].

At the cellular and molecular level, studies of hEDS/HSD fibroblasts demonstrate disorganized ECM, altered cell–matrix interactions and integrin signaling, myofibroblast-like differentiation, and altered expression of genes and proteins involved in ECM organization and remodeling, cytoskeletal organization, cell adhesion, proteostasis, cellular metabolism, and inflammatory signaling [73,191,365,366]. More recently, shared fibronectin and type-I-collagen fragmentation patterns, overlapping fibroblast miRNA profiles, and circulating protein signatures have provided emerging molecular evidence supporting the hypothesis that hEDS and HSD may represent a biological continuum [263,278,359]. Notably, pharmacological inhibition of matrix metalloproteinases with doxycycline restored ECM organization and partly reverted the myofibroblast-like phenotype of hEDS fibroblasts in vitro [191], illustrating how a cellular verifier may also be used to assess whether an intervention engages its intended biological target.

Clinical expression may be further shaped by precipitating or amplifying events, including physical trauma [142], infection [367], surgery [78], and hormonal transitions [368]. Such events may unmask latent vulnerability, disrupt physiological compensation, or alter disease severity or trajectory.

These same biological processes are central to tissue repair and may therefore influence wound healing in Neuro-EDS, an important but incompletely characterized aspect of clinical and surgical care [192]. Understanding this shared biological substrate is important for elucidating Neuro-EDS pathophysiology and developing biologically informed approaches to patient stratification and treatment. These interconnected aspects of connective-tissue biology are illustrated in Figure 3.

© 2026 by the author(s). Distributed under a Creative Commons CC BY license.

Preprints.org | NOT PEER-REVIEWED | Posted: 24 November 2026 https://doi.org/10.20944/preprints202611.2421.v1

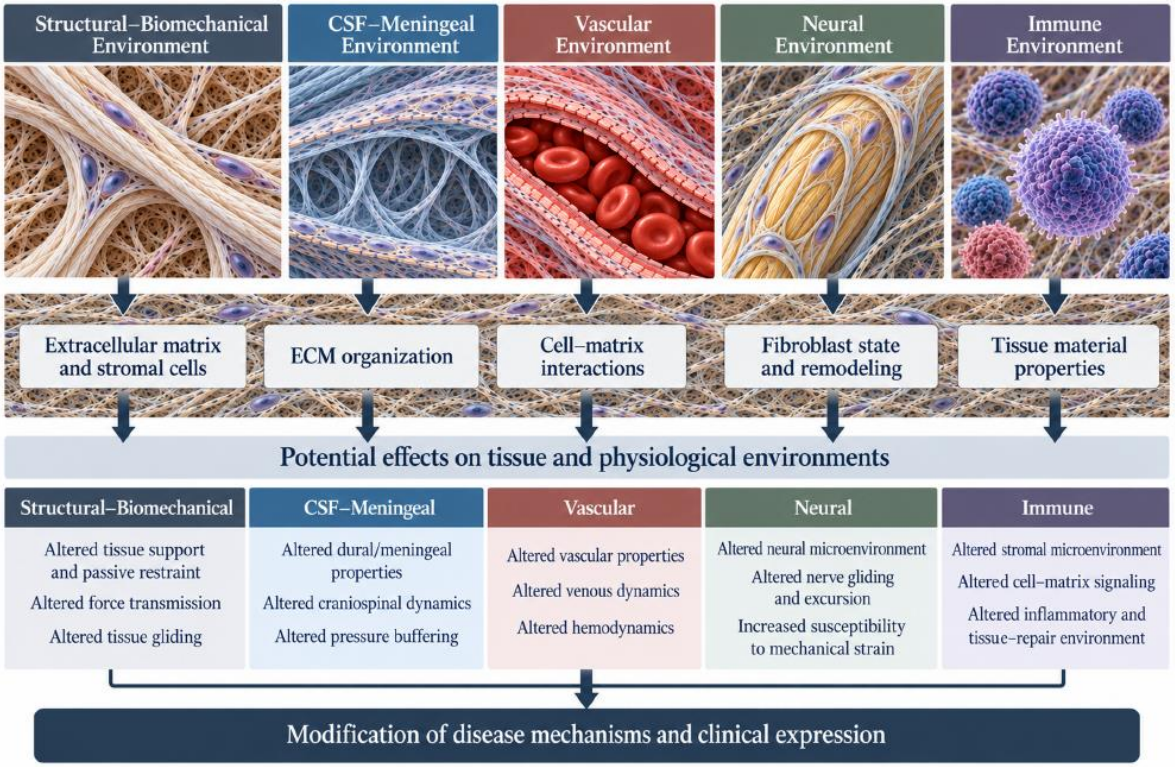

Figure 3. Connective-tissue biology as a shared substrate for Neuro-EDS. Extracellular matrix organization, stromal cells, cell–matrix interactions, remodeling, and tissue properties may influence structural–biomechanical, CSF–meningeal, vascular, neural, and immune environments. Their interactions may modify disease mechanisms and clinical expression. The schematic depicts candidate relationships, with illustrative tissue and cellular images. ECM, extracellular matrix; CSF, cerebrospinal fluid.

A central next step is to determine whether integrated analysis of clinical phenotype, candidate mechanisms, and mechanism-linked verifiers can identify reproducible patient subgroups characterized by shared pathobiology. Multi-omic profiling of accessible tissues and biofluids, including dermal fibroblast transcriptomes and miRNomes, circulating proteomic signatures, and plasma ECM-fragmentation patterns, may help elucidate candidate mechanisms and identify molecular measures for potential validation as mechanism-linked verifiers. Such integrated analyses may reveal subgroups reflecting dominant or interacting biological processes, or patterns not anticipated a priori. Machine-learning analysis of serum proteomic data has already identified a protein panel discriminating hEDS/HSD from controls [263].

Whether these molecular signatures correlate with specific Neuro-EDS manifestations, rather than existing hEDS/HSD diagnostic categories alone, remains to be determined [73,278,359,365]. Prospective longitudinal investigation will be necessary to determine whether the resulting subgroups differ in disease expression, progression, or therapeutic response and can ultimately be validated as Neuro-EDS endotypes.

Limitations and Knowledge Gaps

The phenotype–endotype framework is a conceptual model intended to guide future investigation rather than a definitive biological classification. The candidate mechanisms described herein are supported to varying degrees but remain incompletely characterized, and many of the proposed mechanism-linked verifiers require further validation.

Considerable knowledge gaps remain regarding the natural history of Neuro-EDS; the influence of underlying connective-tissue biology on disease expression and therapeutic response; the roles of genetic susceptibility and modifiers such as trauma, infection, surgery, and hormonal transitions; and the development of validated biomarkers, diagnostic thresholds, and mechanism-appropriate

© 2026 by the author(s). Distributed under a Creative Commons CC BY license.

Preprints.org | NOT PEER-REVIEWED | Posted: 24 November 2026 https://doi.org/10.20944/preprints202611.2421.v1

imaging and physiological assessments. Much of the available evidence derives from selected tertiary referral populations, limiting generalizability and potentially overestimating the prevalence and clinical significance of specific manifestations within the broader hEDS/HSD population; studies incorporating less-selected comparison cohorts will be important for determining generalizability.

Building on the clinical phenotype defined in Paper I and the mechanistic framework proposed here, planned next steps include a Delphi process to establish consensus on the manifestations comprising the Neuro-EDS phenotype, followed by the development of evidence-based guidance for diagnosis, patient selection, and treatment. The planned Delphi process will also seek expert consensus on the classification, interpretation, and evidentiary standards for mechanism-linked verifiers, including their validation requirements and the strength of mechanistic inference they support. The proposed relationship among consensus development, translational research, and precision care is illustrated in Figure 4.

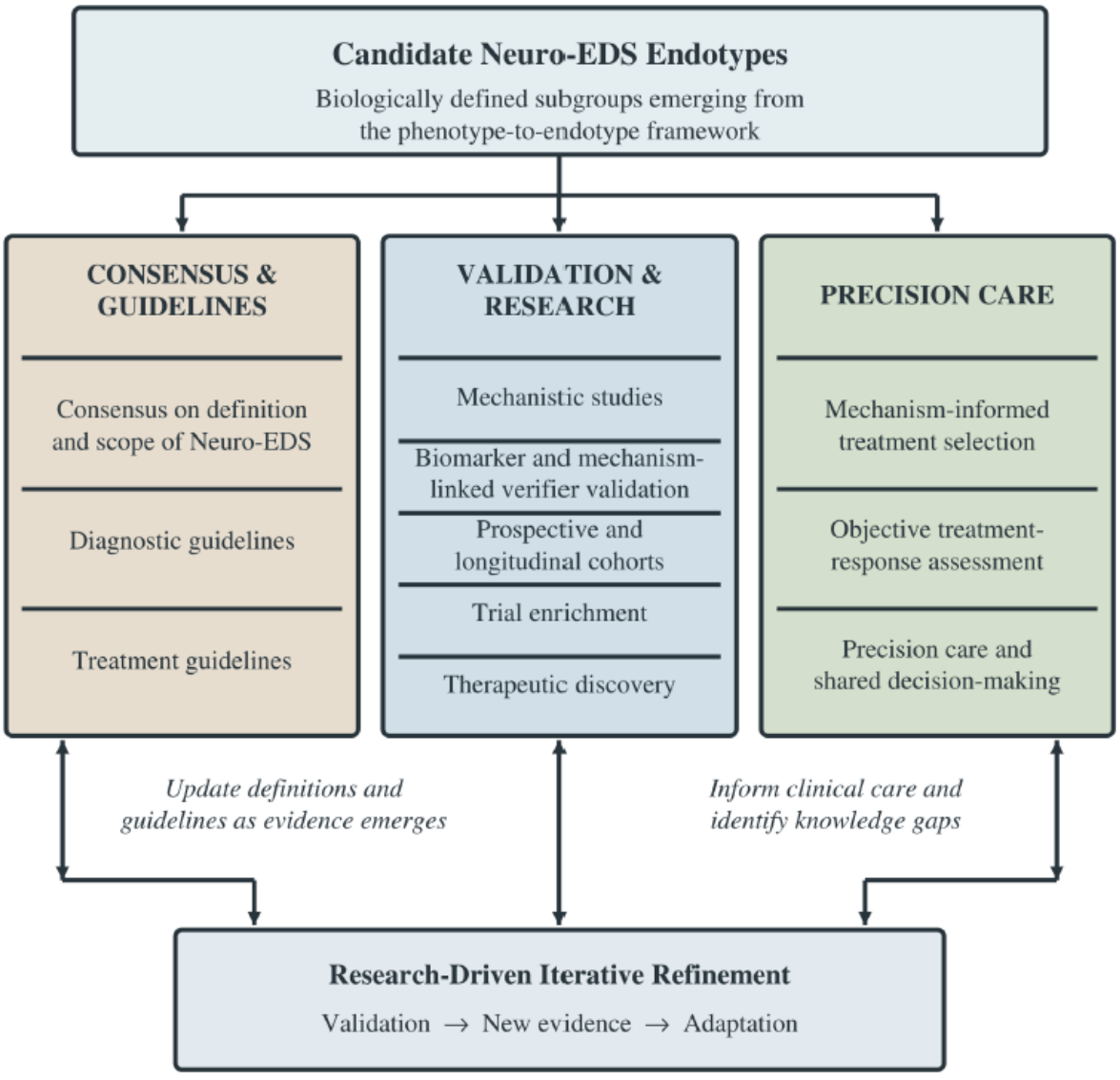

Figure 4. Proposed translation from endotype investigation to precision care. Consensus development, mechanistic research, verifier validation, and clinical care form an iterative pathway toward biologically informed patient stratification and treatment. Emerging evidence informs definitions, guidelines, therapeutic discovery, and objective treatment-response assessment, while clinical experience identifies further research needs. The pathway is proposed rather than an established guideline process.

Conclusion: Toward Biologically Informed of Complex Disease

© 2026 by the author(s). Distributed under a Creative Commons CC BY license.

Preprints.org | NOT PEER-REVIEWED | Posted: 24 November 2026 https://doi.org/10.20944/preprints202611.2421.v1

This approach provides a path beyond descriptive clinical recognition of Neuro-EDS toward biologically informed classification and precision care. Manifestations that appear disparate when viewed within individual specialties may reflect interconnected biological processes that become apparent only when considered within an integrated model.

Conventional testing may not adequately capture the biological abnormalities underlying Neuro-EDS manifestations when these are dynamic, physiological, cellular, or molecular, or when classic diagnostic findings are absent. When routine testing is unrevealing, patients with substantial multisystem disability may experience diagnostic uncertainty and delayed recognition, remain assigned nonspecific diagnoses, and have symptoms attributed to psychiatric or psychosocial causes.

Mechanism-linked verification may provide greater objectivity by linking clinical manifestations to their proposed biological basis. Such measures may strengthen diagnostic confidence, guide treatment selection and provide evidence that an intervention modifies its intended target, beyond symptomatic or functional improvement alone. This evidence may also inform how healthcare systems and insurers evaluate diagnostic testing and treatment.

Importantly, similar clinical phenotypes may arise from different biological processes, while multiple processes may coexist and interact within an individual. As these are better characterized, treatment may increasingly target the biology contributing to disease rather than diagnostic labels alone.

Ultimately, the goal is not to replace phenotype with another static classification system, but to develop a model that evolves with biological evidence. By integrating clinical phenotype, candidate mechanisms, and mechanism-linked verifiers, this framework provides a translational path toward biologically informed patient stratification and increasingly precise care.

References

1. Halverson CME, Cao S, Perkins SM, Francomano CA. Comorbidity, Misdiagnoses, and the Diagnostic Odyssey in Patients with Hypermobile Ehlers-Danlos Syndrome. *Genet Med Open* (2023) 1(1):100812. Epub 20230428. doi: 10.1016/j.gimo.2023.100812.
2. National Academies of Sciences E, Medicine, Health, Medicine D, Board on Health Care S, Committee on Selected Heritable Disorders of Connective T, et al. In: Wedge RA, Cartaxo T, Spicer CM, Volberding PA, editors. *Selected Heritable Disorders of Connective Tissue and Disability*. Washington (DC): National Academies Press (US)
3. Copyright 2022 by the National Academy of Sciences. All rights reserved. (2022).
4. Scicluna K, Formosa MM, Farrugia R, Borg I. Hypermobile Ehlers-Danlos Syndrome: A Review and a Critical Appraisal of Published Genetic Research to Date. *Clin Genet* (2022) 101(1):20–31. Epub 20210714. doi: 10.1111/cge.14026.
5. Bloom AB, Ruhoy IS, Dass RA, Bolognese PA, Klinge PM. Defining Neuro-Eds: A Neuro-Predominant Phenotype in Heds/Hsd and Related Heritable Connective Tissue Disorders. *Frontiers in Neurology* (2026).
6. Aubry-Rozier B, Schwitzguebel A, Valerio F, Tanniger J, Paquier C, Berna C, et al. Are Patients with Hypermobile Ehlers-Danlos Syndrome or Hypermobility Spectrum Disorder So Different? *Rheumatol Int* (2021) 41(10):1785–94. Epub 20210816. doi: 10.1007/s00296-021-04968-3.
7. Ritelli M, Chiarelli N, Cinquina V, Vezzoli M, Venturini M, Colombi M. Looking Back and Beyond the 2017 Diagnostic Criteria for Hypermobile Ehlers-Danlos Syndrome: A Retrospective Cross-Sectional Study from an Italian Reference Center. *Am J Med Genet A* (2024) 194(2):174–94. Epub 20230929. doi: 10.1002/ajmg.a.63426.
8. Agache I, Akdis CA. Precision Medicine and Phenotypes, Endotypes, Genotypes, Regiotypes, and Theratypes of Allergic Diseases. *J Clin Invest* (2019) 129(4):1493–503. Epub 20190311. doi: 10.1172/jci124611.
9. Battaglia M, Ahmed S, Anderson MS, Atkinson MA, Becker D, Bingley PJ, et al. Introducing the Endotype Concept to Address the Challenge of Disease Heterogeneity in Type 1 Diabetes. *Diabetes Care* (2020) 43(1):5–12. Epub 20191121. doi: 10.2337/dc19-0880.
10. Anderson GP. Endotyping Asthma: New Insights into Key Pathogenic Mechanisms in a Complex, Heterogeneous Disease. *Lancet* (2008) 372(9643):1107–19. doi: 10.1016/s0140-6736(08)61452-x.

© 2026 by the author(s). Distributed under a Creative Commons CC BY license.

Preprints.org | NOT PEER-REVIEWED | Posted: 24 November 2026 https://doi.org/10.20944/preprints202611.2421.v1

11. den Hollander NHM, Roep BO. From Disease and Patient Heterogeneity to Precision Medicine in Type 1 Diabetes. *Front Med (Lausanne)* (2022) 9:932086. Epub 20220712. doi: 10.3389/fmed.2022.932086.
12. Kondziella D, Menon DK, Helbok R, Naccache L, Othman MH, Rass V, et al. A Precision Medicine Framework for Classifying Patients with Disorders of Consciousness: Advanced Classification of Consciousness Endotypes (Access). *Neurocrit Care* (2021) 35(Suppl 1):27–36. Epub 20210708. doi: 10.1007/s12028-021-01246-9.
13. Azad TD, Shah PP, Kim HB, Stevens RD. Endotypes and the Path to Precision in Moderate and Severe Traumatic Brain Injury. *Neurocrit Care* (2022) 37(Suppl 2):259–66. Epub 20220321. doi: 10.1007/s12028-022-01475-6.
14. Gordon AC, Alipanah-Lechner N, Bos LD, Dianti J, Diaz JV, Finfer S, et al. From Icu Syndromes to Icu Subphenotypes: Consensus Report and Recommendations for Developing Precision Medicine in the Icu. *Am J Respir Crit Care Med* (2024) 210(2):155–66. doi: 10.1164/rccm.202311-2086SO.
15. Bloom AB, Biggins JB, Brodbelt A, Nishikawa M, Foroughi M, Ruhoy IS, et al. Eagle Syndrome in Heritable Connective Tissue Disorders: Cohort Prevalence and a Distinct Neuroautonomic Stretch-Neuropathy Phenotype. . *J Neurosurg Spine* (2026).
16. Lohkamp LN, Marathe N, Fehlings MG. Craniocervical Instability in Ehlers-Danlos Syndrome-a Systematic Review of Diagnostic and Surgical Treatment Criteria. *Global Spine J* (2022) 12(8):1862–71. Epub 20220223. doi: 10.1177/21925682211068520.
17. Reinstein E, Pariani M, Bannykh S, Rimoin DL, Schievink WI. Connective Tissue Spectrum Abnormalities Associated with Spontaneous Cerebrospinal Fluid Leaks: A Prospective Study. *Eur J Hum Genet* (2013) 21(4):386–90. Epub 20120829. doi: 10.1038/ejhg.2012.191.
18. Schievink WI, Gordon OK, Tourje J. Connective Tissue Disorders with Spontaneous Spinal Cerebrospinal Fluid Leaks and Intracranial Hypotension: A Prospective Study. *Neurosurgery* (2004) 54(1):65–70; discussion –1. doi: 10.1227/01.neu.0000097200.18478.7b.
19. Ruhoy IS, Bolognese PA, Rosenblum JS, Dass RA, Nayyer NS, Wood JD, et al. Comorbidities and Neurosurgical Interventions in a Cohort with Connective Tissue Disorders. *Front Neurol* (2024) 15:1484504. Epub 20250122. doi: 10.3389/fneur.2024.1484504.
20. Goel A. Goel's Classification of Atlantoaxial "Facetal" Dislocation. *J Craniovertebr Junction Spine* (2014) 5(1):3–8. doi: 10.4103/0974-8237.135206.
21. Henderson FC, Sr., Austin C, Benzel E, Bolognese P, Ellenbogen R, Francomano CA, et al. Neurological and Spinal Manifestations of the Ehlers-Danlos Syndromes. *Am J Med Genet C Semin Med Genet* (2017) 175(1):195–211. Epub 20170221. doi: 10.1002/ajmg.c.31549.
22. Henderson FC, Sr., Francomano CA, Koby M, Tuchman K, Adcock J, Patel S. Cervical Medullary Syndrome Secondary to Craniocervical Instability and Ventral Brainstem Compression in Hereditary Hypermobility Connective Tissue Disorders: 5-Year Follow-up after Craniocervical Reduction, Fusion, and Stabilization. *Neurosurg Rev* (2019) 42(4):915–36. Epub 20190109. doi: 10.1007/s10143-018-01070-4.
23. Menezes AH, Traynelis VC. Anatomy and Biomechanics of Normal Craniovertebral Junction (a) and Biomechanics of Stabilization (B). *Childs Nerv Syst* (2008) 24(10):1091–100. Epub 20080404. doi: 10.1007/s00381-008-0606-8.
24. Henderson FC, Sr., Rowe PC, Narayanan M, Rosenbaum R, Koby M, Tuchmann K, et al. Refractory Syncope and Presyncope Associated with Atlantoaxial Instability: Preliminary Evidence of Improvement Following Surgical Stabilization. *World Neurosurg* (2021) 149:e854–e65. Epub 20210201. doi: 10.1016/j.wneu.2021.01.084.
25. Caetano de Barros M, Farias W, Ataíde L, Lins S. Basilar Impression and Arnold-Chiari Malformation. A Study of 66 Cases. *J Neurol Neurosurg Psychiatry* (1968) 31(6):596–605. doi: 10.1136/jnnp.31.6.596.
26. da Silva JA, Brito JC, da Nóbrega PV. [Autonomic Nervous System Disorders in 230 Cases of Basilar Impression and Arnold-Chiari Deformity]. *Neurochirurgia (Stuttg)* (1992) 35(6):183–8.
27. Henderson FC, Sr., Schubart JR, Narayanan MV, Tuchman K, Mills SE, Poppe DJ, et al. Craniocervical Instability in Patients with Ehlers-Danlos Syndromes: Outcomes Analysis Following Occipito-Cervical Fusion. *Neurosurg Rev* (2024) 47(1):27. Epub 20240102. doi: 10.1007/s10143-023-02249-0.

© 2026 by the author(s). Distributed under a Creative Commons CC BY license.

Preprints.org | NOT PEER-REVIEWED | Posted: 24 November 2026 https://doi.org/10.20944/preprints202611.2421.v1

28. Gensemer C, Daylor V, Nix J, Norris RA, Patel S. Co-Occurrence of Tethered Cord Syndrome and Cervical Spine Instability in Hypermobile Ehlers-Danlos Syndrome. *Front Neurol* (2024) 15:1441866. Epub 20240717. doi: 10.3389/fneur.2024.1441866.
29. Chalela S, Russek LN. Presentation and Physical Therapy Management Using a Neuroplasticity Approach for Patients with Hypermobility-Related Upper Cervical Instability: A Brief Report. *Front Neurol* (2024) 15:1459115. Epub 20241108. doi: 10.3389/fneur.2024.1459115.
30. CreveCoeur TS, Yahanda AT, Maher CO, Johnson GW, Ackerman LL, Adelson PD, et al. Occipital-Cervical Fusion and Ventral Decompression in the Surgical Management of Chiari-1 Malformation and Syringomyelia: Analysis of Data from the Park-Reeves Syringomyelia Research Consortium. *Neurosurgery* (2021) 88(2):332–41. doi: 10.1093/neuros/nyaa460.
31. Geddes JF, Whitwell HL, Graham DI. Traumatic Axonal Injury: Practical Issues for Diagnosis in Medicolegal Cases. *Neuropathol Appl Neurobiol* (2000) 26(2):105–16. doi: 10.1046/j.1365-2990.2000.026002105.x.
32. Geddes JF, Hackshaw AK, Vowles GH, Nickols CD, Whitwell HL. Neuropathology of Inflicted Head Injury in Children. I. Patterns of Brain Damage. *Brain* (2001) 124(Pt 7):1290–8. doi: 10.1093/brain/124.7.1290.
33. Henderson FC, Geddes JF, Crockard HA. Neuropathology of the Brainstem and Spinal Cord in End Stage Rheumatoid Arthritis: Implications for Treatment. *Ann Rheum Dis* (1993) 52(9):629–37. doi: 10.1136/ard.52.9.629.
34. Henderson FC, Geddes JF, Vaccaro AR, Woodard E, Berry KJ, Benzel EC. Stretch-Associated Injury in Cervical Spondylotic Myelopathy: New Concept and Review. *Neurosurgery* (2005) 56(5):1101–13; discussion –13.
35. Henderson FC, Wilson WA, Mott S, Mark A, Schmidt K, Berry JK, et al. Deformative Stress Associated with an Abnormal Clivo-Axial Angle: A Finite Element Analysis. *Surg Neurol Int* (2010) 1. Epub 20100716. doi: 10.4103/2152-7806.66461.
36. Marathe N, Lohkamp LN, Fehlings MG. Spinal Manifestations of Ehlers-Danlos Syndrome: A Scoping Review. *J Neurosurg Spine* (2022) 37(6):783–93. Epub 20220819. doi: 10.3171/2022.6.Spine211011.
37. Benarroch EE. Brainstem Integration of Arousal, Sleep, Cardiovascular, and Respiratory Control. *Neurology* (2018) 91(21):958–66. Epub 20181024. doi: 10.1212/wnl.0000000000006537.
38. Krohn F, Novello M, van der Giessen RS, De Zeeuw CI, Pel JJM, Bosman LWJ. The Integrated Brain Network That Controls Respiration. *Elife* (2023) 12. Epub 20230308. doi: 10.7554/eLife.83654.
39. Hauser RA, Matias D, Rawlings BR. Cervicovagopathy: Ligamentous Cervical Instability and Dysstructure as a Potential Etiology for Vagus Nerve Dysfunction in the Cause of Human Symptoms and Diseases. *Front Neurol* (2025) 16:1572863. Epub 20250702. doi: 10.3389/fneur.2025.1572863.
40. Cook C, Hegedus E, Showalter C, Sizer PS, Jr. Coupling Behavior of the Cervical Spine: A Systematic Review of the Literature. *J Manipulative Physiol Ther* (2006) 29(7):570–5. doi: 10.1016/j.jmpt.2006.06.020.
41. Ishii T, Mukai Y, Hosono N, Sakaura H, Nakajima Y, Sato Y, et al. Kinematics of the Upper Cervical Spine in Rotation: In Vivo Three-Dimensional Analysis. *Spine (Phila Pa 1976)* (2004) 29(7):E139–44. doi: 10.1097/01.brs.0000116998.55056.3c.
42. Kettler A, Hartwig E, Schultheiss M, Claes L, Wilke HJ. Mechanically Simulated Muscle Forces Strongly Stabilize Intact and Injured Upper Cervical Spine Specimens. *J Biomech* (2002) 35(3):339–46. doi: 10.1016/s0021-9290(01)00206-8.
43. Nicholson LL, Rao PJ, Lee M, Wong TM, Cheng RHY, Chan C. Reference Values of Four Measures of Craniocervical Stability Using Upright Dynamic Magnetic Resonance Imaging. *Radiol Med* (2023) 128(3):330–9. Epub 20230130. doi: 10.1007/s11547-023-01588-8.
44. Steinmetz MP, Mroz TE, Benzel EC. Craniovertebral Junction: Biomechanical Considerations. *Neurosurgery* (2010) 66(3 Suppl):7–12. doi: 10.1227/01.Neu.0000366109.85796.42.
45. Milhorat TH, Bolognese PA, Nishikawa M, McDonnell NB, Francomano CA. Syndrome of Occipitoatlantoaxial Hypermobility, Cranial Settling, and Chiari Malformation Type I in Patients with Hereditary Disorders of Connective Tissue. *J Neurosurg Spine* (2007) 7(6):601–9. doi: 10.3171/spi-07/12/601.
46. Dubin AE, Patapoutian A. Nociceptors: The Sensors of the Pain Pathway. *J Clin Invest* (2010) 120(11):3760–72. Epub 20101101. doi: 10.1172/jci42843.

© 2026 by the author(s). Distributed under a Creative Commons CC BY license.

Preprints.org | NOT PEER-REVIEWED | Posted: 24 November 2026 https://doi.org/10.20944/preprints202611.2421.v1

47. Kwan MK, Wall EJ, Massie J, Garfin SR. Strain, Stress and Stretch of Peripheral Nerve. Rabbit Experiments in Vitro and in Vivo. *Acta Orthop Scand* (1992) 63(3):267–72. doi: 10.3109/17453679209154780.
48. Singh A, Lu Y, Chen C, Kallakuri S, Cavanaugh JM. A New Model of Traumatic Axonal Injury to Determine the Effects of Strain and Displacement Rates. *Stapp Car Crash J* (2006) 50:601–23. doi: 10.4271/2006-22-0023.
49. Arundine M, Aarts M, Lau A, Tymianski M. Vulnerability of Central Neurons to Secondary Insults after in Vitro Mechanical Stretch. *J Neurosci* (2004) 24(37):8106–23. doi: 10.1523/jneurosci.1362-04.2004.
50. Bunge RP, Puckett WR, Becerra JL, Marcillo A, Quencer RM. Observations on the Pathology of Human Spinal Cord Injury. A Review and Classification of 22 New Cases with Details from a Case of Chronic Cord Compression with Extensive Focal Demyelination. *Adv Neurol* (1993) 59:75–89.
51. Chung RS, Staal JA, McCormack GH, Dickson TC, Cozens MA, Chuckowree JA, et al. Mild Axonal Stretch Injury in Vitro Induces a Progressive Series of Neurofilament Alterations Ultimately Leading to Delayed Axotomy. *J Neurotrauma* (2005) 22(10):1081–91. doi: 10.1089/neu.2005.22.1081.
52. Gennarelli TA. The Pathobiology of Traumatic Brain Injury. *The Neuroscientist* (1997) 3(1):73–81. doi: 10.1177/107385849700300117.
53. Jafari SS, Maxwell WL, Neilson M, Graham DI. Axonal Cytoskeletal Changes after Non-Disruptive Axonal Injury. *J Neurocytol* (1997) 26(4):207–21. doi: 10.1023/a:1018588114648.
54. Li GL, Brodin G, Farooque M, Funa K, Holtz A, Wang WL, et al. Apoptosis and Expression of Bcl-2 after Compression Trauma to Rat Spinal Cord. *J Neuropathol Exp Neurol* (1996) 55(3):280–9. doi: 10.1097/00005072-199603000-00003.
55. Liu XZ, Xu XM, Hu R, Du C, Zhang SX, McDonald JW, et al. Neuronal and Glial Apoptosis after Traumatic Spinal Cord Injury. *J Neurosci* (1997) 17(14):5395–406. doi: 10.1523/jneurosci.17-14-05395.1997.
56. Maxwell WL, Islam MN, Graham DI, Gennarelli TA. A Qualitative and Quantitative Analysis of the Response of the Retinal Ganglion Cell Soma after Stretch Injury to the Adult Guinea-Pig Optic Nerve. *J Neurocytol* (1994) 23(6):379–92. doi: 10.1007/bf01666527.
57. Maxwell WL, Kosanlavit R, McCreath BJ, Reid O, Graham DI. Freeze-Fracture and Cytochemical Evidence for Structural and Functional Alteration in the Axolemma and Myelin Sheath of Adult Guinea Pig Optic Nerve Fibers after Stretch Injury. *J Neurotrauma* (1999) 16(4):273–84. doi: 10.1089/neu.1999.16.273.
58. Maxwell WL, Domleo A, McColl G, Jafari SS, Graham DI. Post-Acute Alterations in the Axonal Cytoskeleton after Traumatic Axonal Injury. *J Neurotrauma* (2003) 20(2):151–68. doi: 10.1089/08977150360547071.
59. Maxwell WL, Pennington K, MacKinnon MA, Smith DH, McIntosh TK, Wilson JT, et al. Differential Responses in Three Thalamic Nuclei in Moderately Disabled, Severely Disabled and Vegetative Patients after Blunt Head Injury. *Brain* (2004) 127(Pt 11):2470–8. Epub 20040929. doi: 10.1093/brain/awh294.
60. Povlishock JT. Traumatically Induced Axonal Injury: Pathogenesis and Pathobiological Implications. *Brain Pathol* (1992) 2(1):1–12.
61. Saatman KE, Abai B, Grosvenor A, Vorwerk CK, Smith DH, Meaney DF. Traumatic Axonal Injury Results in Biphasic Calpain Activation and Retrograde Transport Impairment in Mice. *J Cereb Blood Flow Metab* (2003) 23(1):34–42. doi: 10.1097/01.Wcb.0000035040.10031.B0.
62. Shi R, Whitebone J. Conduction Deficits and Membrane Disruption of Spinal Cord Axons as a Function of Magnitude and Rate of Strain. *J Neurophysiol* (2006) 95(6):3384–90. Epub 20060301. doi: 10.1152/jn.00350.2005.
63. Wolf JA, Stys PK, Lusardi T, Meaney D, Smith DH. Traumatic Axonal Injury Induces Calcium Influx Modulated by Tetrodotoxin-Sensitive Sodium Channels. *J Neurosci* (2001) 21(6):1923–30. doi: 10.1523/jneurosci.21-06-01923.2001.
64. Choi KD, Choi JH, Kim JS, Kim HJ, Kim MJ, Lee TH, et al. Rotational Vertebral Artery Occlusion: Mechanisms and Long-Term Outcome. *Stroke* (2013) 44(7):1817–24. Epub 20130521. doi: 10.1161/strokeaha.113.001219.
65. Dvorak J, Panjabi M, Gerber M, Wichmann W. Ct-Functional Diagnostics of the Rotatory Instability of Upper Cervical Spine. 1. An Experimental Study on Cadavers. *Spine (Phila Pa 1976)* (1987) 12(3):197–205. doi: 10.1097/00007632-198704000-00001.

© 2026 by the author(s). Distributed under a Creative Commons CC BY license.

Preprints.org | NOT PEER-REVIEWED | Posted: 24 November 2026 https://doi.org/10.20944/preprints202611.2421.v1

66. Fargen KM. A Unifying Theory Explaining Venous Sinus Stenosis and Recurrent Stenosis Following Venous Sinus Stenting in Patients with Idiopathic Intracranial Hypertension. *J Neurointerv Surg* (2021) 13(7):587–92. Epub 20210212. doi: 10.1136/neurintsurg-2020-017208.
67. Fargen KM, Midtlien JP, Margraf CR, Hui FK. Idiopathic Intracranial Hypertension Pathogenesis: The Jugular Hypothesis. *Interv Neuroradiol* (2026) 32(5):2198–207. Epub 20240808. doi: 10.1177/15910199241270660.
68. Jayaraman MV, Boxerman JL, Davis LM, Haas RA, Rogg JM. Incidence of Extrinsic Compression of the Internal Jugular Vein in Unselected Patients Undergoing Ct Angiography. *AJNR Am J Neuroradiol* (2012) 33(7):1247–50. Epub 20120209. doi: 10.3174/ajnr.A2953.
69. Zhang L, Song X, Chen C, Ma W, Zhang JF, Zheng N, et al. The Myodural Bridge Complex: A Comprehensive Review of Morphology, Physiology, Developmental Biology and Pathology. *Front Med (Lausanne)* (2026) 13:1790220. Epub 20260417. doi: 10.3389/fmed.2026.1790220.
70. Klinge PM, McElroy A, Donahue JE, Brinker T, Gokaslan ZL, Beland MD. Abnormal Spinal Cord Motion at the Craniocervical Junction in Hypermobile Ehlers-Danlos Patients. *J Neurosurg Spine* (2021) 35(1):18–24. Epub 20210521. doi: 10.3171/2020.10.Spine201765.
71. McElroy A, Rashmir A, Manfredi J, Sledge D, Carr E, Stopa E, et al. Evaluation of the Structure of Myodural Bridges in an Equine Model of Ehlers-Danlos Syndromes. *Sci Rep* (2019) 9(1):9978. Epub 20190710. doi: 10.1038/s41598-019-46444-w.
72. Panjabi MM. The Stabilizing System of the Spine. Part Ii. Neutral Zone and Instability Hypothesis. *J Spinal Disord* (1992) 5(4):390–6; discussion 7. doi: 10.1097/00002517-199212000-00002.
73. Griggs M, Daylor V, Petrucci T, Weintraub A, Huff M, Willey S, et al. Proteomic Discoveries in Hypermobile Ehlers-Danlos Syndrome Reveal Insights into Disease Pathophysiology. *Immunohorizons* (2025) 9(10). doi: 10.1093/immhor/vlaf044.
74. Ritelli M, Chiarelli N, Cinquina V, Zoppi N, Bertini V, Venturini M, et al. Rna-Seq of Dermal Fibroblasts from Patients with Hypermobile Ehlers-Danlos Syndrome and Hypermobility Spectrum Disorders Supports Their Categorization as a Single Entity with Involvement of Extracellular Matrix Degrading and Proinflammatory Pathomechanisms. *Cells* (2022) 11(24). Epub 20221214. doi: 10.3390/cells11244040.
75. Bollo RJ, Riva-Cambrin J, Brockmeyer MM, Brockmeyer DL. Complex Chiari Malformations in Children: An Analysis of Preoperative Risk Factors for Occipitocervical Fusion. *J Neurosurg Pediatr* (2012) 10(2):134–41. Epub 20120622. doi: 10.3171/2012.3.Peds11340.
76. Henderson FC, Sr., Henderson FC, Jr., Wilson WAt, Mark AS, Koby M. Utility of the Clivo-Axial Angle in Assessing Brainstem Deformity: Pilot Study and Literature Review. *Neurosurg Rev* (2018) 41(1):149–63. Epub 20170303. doi: 10.1007/s10143-017-0830-3.
77. Kim LJ, Rekate HL, Klopfenstein JD, Sonntag VK. Treatment of Basilar Invagination Associated with Chiari I Malformations in the Pediatric Population: Cervical Reduction and Posterior Occipitocervical Fusion. *J Neurosurg* (2004) 101(2 Suppl):189–95. doi: 10.3171/ped.2004.101.2.0189.
78. VanGilder JC, Menezes AH, H. A, Dolan KD. *The Craniovertebral Junction and Its Abnormalities*: Futura Publishing Company (1987).
79. Zhao DY, Rock MB, Sandhu FA. Craniocervical Stabilization after Failed Chiari Decompression: A Case Series of a Population with High Prevalence of Ehlers-Danlos Syndrome. *World Neurosurg* (2022) 161:e546–e52. Epub 20220219. doi: 10.1016/j.wneu.2022.02.068.
80. Batzdorf U, Benzel E, Bolognese P, Francomano C, Grahame R, Henderson FC, et al. *Proceedings of Csf Colloquium 2013: Basilar Impression & Hypermobility at the Craniocervical Junction*(2014). 150 p.
81. Harris JH, Jr., Carson GC, Wagner LK. Radiologic Diagnosis of Traumatic Occipitovertebral Dissociation: 1. Normal Occipitovertebral Relationships on Lateral Radiographs of Supine Subjects. *AJR Am J Roentgenol* (1994) 162(4):881–6. doi: 10.2214/ajr.162.4.8141012.
82. Panjabi M, Dvorak J, Crisco JJ, 3rd, Oda T, Wang P, Grob D. Effects of Alar Ligament Transection on Upper Cervical Spine Rotation. *J Orthop Res* (1991) 9(4):584–93. doi: 10.1002/jor.1100090415.
83. Werne S. Studies in Spontaneous Atlas Dislocation. *Acta Orthop Scand Suppl* (1957) 23:1–150.
84. Wiesel SW, Rothman RH. Occipitoatlantal Hypermobility. *Spine (Phila Pa 1976)* (1979) 4(3):187–91. doi: 10.1097/00007632-197905000-00001.

© 2026 by the author(s). Distributed under a Creative Commons CC BY license.

Preprints.org | NOT PEER-REVIEWED | Posted: 24 November 2026 https://doi.org/10.20944/preprints202611.2421.v1

85. Grabb PA, Mapstone TB, Oakes WJ. Ventral Brain Stem Compression in Pediatric and Young Adult Patients with Chiari I Malformations. *Neurosurgery* (1999) 44(3):520–7; discussion 7–8. doi: 10.1097/00006123-199903000-00050.
86. Fielding JW. Cineroentgenography of the Normal Cervical Spine. *J Bone Joint Surg Am* (1957) 39-a(6):1280–8.
87. Grahame R, Malik I, Hakim A, Koby M, Henderson F, Sr. Comment on "Quantitative Measures of Tissue Mechanics to Detect Hypermobile Ehlers-Danlos Syndrome and Hypermobility Syndrome Disorders: A Systematic Review". *Clin Rheumatol* (2020) 39(8):2481–2. Epub 20200605. doi: 10.1007/s10067-020-05158-5.
88. Joaquim AF, Ghizoni E, Tedeschi H, Appenzeller S, Riew KD. Radiological Evaluation of Cervical Spine Involvement in Rheumatoid Arthritis. *Neurosurg Focus* (2015) 38(4):E4. doi: 10.3171/2015.1.Focus14664.
89. Riascos R, Bonfante E, Cotes C, Guirguis M, Hakimelahi R, West C. Imaging of Atlanto-Occipital and Atlantoaxial Traumatic Injuries: What the Radiologist Needs to Know. *Radiographics* (2015) 35(7):2121–34. doi: 10.1148/rg.2015150035.
90. Menezes AH. Craniovertebral Junction Abnormalities with Hindbrain Herniation and Syringomyelia: Regression of Syringomyelia after Removal of Ventral Craniovertebral Junction Compression. *J Neurosurg* (2012) 116(2):301–9. Epub 20111118. doi: 10.3171/2011.9.Jns11386.
91. Joaquim AF, Schnake KJ, Bransford RJ, Chabbra HS, Bigdon SF, El-Sharkawi M, et al. Craniocervical Traumatic Ligamentous Injuries - Ao Spine Type B Injuries - Anatomy, Biomechanics and Clinical Perspectives. *J Clin Orthop Trauma* (2025) 71:103223. Epub 20251004. doi: 10.1016/j.jcot.2025.103223.
92. Bloom AR, Biggins JB, Brodbelt A, Nishikawa M, Foroughi M, Ruhoy IS, et al. Surgical Screening Protocol for Craniocervical Instability Secondary to Ehlers-Danlos Syndrome and Other Connective Tissue Disorders: Analysis of a 347 Patient Case Series. *Neurosurg Rev* (2026) 49(1). Epub 20260312. doi: 10.1007/s10143-026-04195-z.
93. Izeki M, Neo M, Takemoto M, Fujibayashi S, Ito H, Nagai K, et al. The O-C2 Angle Established at Occipito-Cervical Fusion Dictates the Patient's Destiny in Terms of Postoperative Dyspnea and/or Dysphagia. *Eur Spine J* (2014) 23(2):328–36. Epub 20130825. doi: 10.1007/s00586-013-2963-6.
94. Marianayagam NJ, Chae JK, Hussain I, Cruz A, Baaj AA, Härtl R, et al. Increase in Clivo-Axial Angle Is Associated with Clinical Improvement in Children Undergoing Occipitocervical Fusion for Complex Chiari Malformation: Patient Series. *J Neurosurg Case Lessons* (2021) 2(23):Case21433. Epub 20211206. doi: 10.3171/case21433.
95. Menezes AH, VanGilder JC, Clark CR, el-Khoury G. Odontoid Upward Migration in Rheumatoid Arthritis. An Analysis of 45 Patients with "Cranial Settling". *J Neurosurg* (1985) 63(4):500–9. doi: 10.3171/jns.1985.63.4.0500.
96. Sawin PD, Menezes AH. Basilar Invagination in Osteogenesis Imperfecta and Related Osteochondrodysplasias: Medical and Surgical Management. *J Neurosurg* (1997) 86(6):950–60. doi: 10.3171/jns.1997.86.6.0950.
97. Hertzler DA, 2nd, DePowell JJ, Stevenson CB, Mangano FT. Tethered Cord Syndrome: A Review of the Literature from Embryology to Adult Presentation. *Neurosurg Focus* (2010) 29(1):E1. doi: 10.3171/2010.3.Focus1079.
98. Yamada S, Won DJ, Yamada SM. Pathophysiology of Tethered Cord Syndrome: Correlation with Symptomatology. *Neurosurg Focus* (2004) 16(2):E6. Epub 20040215. doi: 10.3171/foc.2004.16.2.7.
99. Warder DE, Oakes WJ. Tethered Cord Syndrome and the Conus in a Normal Position. *Neurosurgery* (1993) 33(3):374–8. doi: 10.1227/00006123-199309000-00004.
100. Klinge PM, Srivastava V, McElroy A, Leary OP, Ahmed Z, Donahue JE, et al. Diseased Filum Terminale as a Cause of Tethered Cord Syndrome in Ehlers-Danlos Syndrome: Histopathology, Biomechanics, Clinical Presentation, and Outcome of Filum Excision. *World Neurosurg* (2022) 162:e492–e502. Epub 20220317. doi: 10.1016/j.wneu.2022.03.038.
101. Wang JH, Guo Q, Li B. Tendon Biomechanics and Mechanobiology--a Minireview of Basic Concepts and Recent Advancements. *J Hand Ther* (2012) 25(2):133–40; quiz 41. Epub 20110917. doi: 10.1016/j.jht.2011.07.004.

© 2026 by the author(s). Distributed under a Creative Commons CC BY license.

Preprints.org | NOT PEER-REVIEWED | Posted: 24 November 2026 https://doi.org/10.20944/preprints202611.2421.v1

102. Breig A. *Adverse Mechanical Tension in the Central Nervous System : An Analysis of Cause and Effect : Relief by Functional Neurosurgery*: Stockholm : Almqvist & Wiksell International ; New York : Wiley
103. 1978 (1978).
104. Klinge PM, Leary OP, Allen PA, Svokos K, Sullivan P, Brinker T, et al. Clinical Criteria for Filum Terminale Resection in Occult Tethered Cord Syndrome. *J Neurosurg Spine* (2024) 40(6):758–66. Epub 20240315. doi: 10.3171/2024.1.Spine231191.
105. McCullough DC, Levy LM, DiChiro G, Johnson DL. Toward the Prediction of Neurological Injury from Tethered Spinal Cord: Investigation of Cord Motion with Magnetic Resonance. *Pediatr Neurosurg* (1990) 16(1):3–7; discussion doi: 10.1159/000120494.
106. Wang H, Tian Y, Wu J, Luo S, Zheng C, Sun C, et al. Update on the Pathogenesis, Clinical Diagnosis, and Treatment of Hirayama Disease. *Front Neurol* (2021) 12:811943. Epub 20220201. doi: 10.3389/fneur.2021.811943.
107. Schievink WI, Maya M, Prasad RS, Wadhwa VS, Cruz RB, Moser FG, et al. Spontaneous Spinal Cerebrospinal Fluid-Venous Fistulas in Patients with Orthostatic Headaches and Normal Conventional Brain and Spine Imaging. *Headache* (2021) 61(2):387–91. Epub 20210123. doi: 10.1111/head.14048.
108. Abdulrazeq H, Leary OP, Tang OY, Karimi H, McElroy A, Gokaslan Z, et al. The Surgical Histopathology of the Filum Terminale: Findings from a Large Series of Patients with Tethered Cord Syndrome. *J Clin Med* (2023) 13(1). Epub 20231219. doi: 10.3390/jcm13010006.
109. Metcalfe PD, Luerssen TG, King SJ, Kaefer M, Meldrum KK, Cain MP, et al. Treatment of the Occult Tethered Spinal Cord for Neuropathic Bladder: Results of Sectioning the Filum Terminale. *J Urol* (2006) 176(4 Pt 2):1826–9; discussion 30. doi: 10.1016/j.juro.2006.04.090.
110. Wehby MC, O'Hollaren PS, Abtin K, Hume JL, Richards BJ. Occult Tight Filum Terminale Syndrome: Results of Surgical Untethering. *Pediatr Neurosurg* (2004) 40(2):51–7; discussion 8. doi: 10.1159/000078908.
111. Aoun SG, El Ahmadieh TY, Vance AZ, Neeley O, Morrill KC. The Use of Prone Magnetic Resonance Imaging to Rule out Tethered Cord in Patients with Structural Spine Anomalies: A Diagnostic Technical Note for Surgical Decision-Making. *Cureus* (2019) 11(3):e4221. Epub 20190311. doi: 10.7759/cureus.4221.
112. Nakanishi K, Tanaka N, Kamei N, Nakamae T, Izumi B, Ohta R, et al. Use of Prone Position Magnetic Resonance Imaging for Detecting the Terminal Filum in Patients with Occult Tethered Cord Syndrome. *J Neurosurg Spine* (2013) 18(1):76–84. Epub 20121109. doi: 10.3171/2012.10.Spine12321.
113. Stamates MM, Frim DM, Yang CW, Katzman GL, Ali S. Magnetic Resonance Imaging in the Prone Position and the Diagnosis of Tethered Spinal Cord. *J Neurosurg Pediatr* (2018) 21(1):4–10. Epub 20171027. doi: 10.3171/2017.3.Peds16596.
114. Steinbok P, MacNeily AE. Section of the Terminal Filum for Occult Tethered Cord Syndrome: Toward a Scientific Answer. *Neurosurg Focus* (2007) 23(2):E5. doi: 10.3171/foc-07/08/e5.
115. Zingman A, Tuchman K, Henderson F, Sr., Francomano CA. Patient-Reported Outcomes Following Sectioning of the Filum Terminale for Treatment of Tethered Cord Syndrome Associated with Ehlers-Danlos Syndrome. *Cureus* (2022) 14(5):e24679. Epub 20220502. doi: 10.7759/cureus.24679.
116. Milhorat TH, Chou MW, Trinidad EM, Kula RW, Mandell M, Wolpert C, et al. Chiari I Malformation Redefined: Clinical and Radiographic Findings for 364 Symptomatic Patients. *Neurosurgery* (1999) 44(5):1005–17. doi: 10.1097/00006123-199905000-00042.
117. Ellington M, Francomano CA. Chiari I Malformations and the Heritable Disorders of Connective Tissue. *Neurosurg Clin N Am* (2023) 34(1):61–5. doi: 10.1016/j.nec.2022.09.001.
118. Heukwa-Tefoung A, Bui A, Gilmer H. Familial Chiari Malformation: Prevalence of Connective Tissue Disorders and Other Comorbidities. *Neurosurgery* (2026). Epub 20260722. doi: 10.1227/neu.0000000000004172.
119. Sadler B, Kuensting T, Strahle J, Park TS, Smyth M, Limbrick DD, et al. Prevalence and Impact of Underlying Diagnosis and Comorbidities on Chiari 1 Malformation. *Pediatr Neurol* (2020) 106:32–7. Epub 20200121. doi: 10.1016/j.pediatrneurol.2019.12.005.
120. Brockmeyer DL. The Complex Chiari: Issues and Management Strategies. *Neurol Sci* (2011) 32 Suppl 3:S345–7. doi: 10.1007/s10072-011-0690-5.

© 2026 by the author(s). Distributed under a Creative Commons CC BY license.

Preprints.org | NOT PEER-REVIEWED | Posted: 24 November 2026 https://doi.org/10.20944/preprints202611.2421.v1

121. Ravindra VM, Brockmeyer DL. Complex Chiari Malformations: Diagnosis, Evaluation, and Treatment. *Neurosurg Clin N Am* (2023) 34(1):143–50. Epub 20221103. doi: 10.1016/j.nec.2022.08.009.
122. Alperin N, Sivaramakrishnan A, Lichtor T. Magnetic Resonance Imaging-Based Measurements of Cerebrospinal Fluid and Blood Flow as Indicators of Intracranial Compliance in Patients with Chiari Malformation. *J Neurosurg* (2005) 103(1):46–52. doi: 10.3171/jns.2005.103.1.0046.
123. Bhadelia RA, Chang YM, Oshinski JN, Loth F. Cerebrospinal Fluid Flow and Brain Motion in Chiari I Malformation: Past, Present, and Future. *J Magn Reson Imaging* (2023) 58(2):360–78. Epub 20230403. doi: 10.1002/jmri.28717.
124. Heiss JD. Cerebrospinal Fluid Hydrodynamics in Chiari I Malformation and Syringomyelia: Modeling Pathophysiology. *Neurosurg Clin N Am* (2023) 34(1):81–90. Epub 20221103. doi: 10.1016/j.nec.2022.08.007.
125. Nishikawa M, Sakamoto H, Hakuba A, Nakanishi N, Inoue Y. Pathogenesis of Chiari Malformation: A Morphometric Study of the Posterior Cranial Fossa. *J Neurosurg* (1997) 86(1):40–7. doi: 10.3171/jns.1997.86.1.0040.
126. Cheema S, Anderson J, Angus-Leppan H, Armstrong P, Butteriss D, Carlton Jones L, et al. Multidisciplinary Consensus Guideline for the Diagnosis and Management of Spontaneous Intracranial Hypotension. *J Neurol Neurosurg Psychiatry* (2023) 94(10):835–43. Epub 20230505. doi: 10.1136/jnnp-2023-331166.
127. Heiss JD, Patronas N, DeVroom HL, Shawker T, Ennis R, Kammerer W, et al. Elucidating the Pathophysiology of Syringomyelia. *J Neurosurg* (1999) 91(4):553–62. doi: 10.3171/jns.1999.91.4.0553.
128. Oldfield EH, Muraszko K, Shawker TH, Patronas NJ. Pathophysiology of Syringomyelia Associated with Chiari I Malformation of the Cerebellar Tonsils. Implications for Diagnosis and Treatment. *J Neurosurg* (1994) 80(1):3–15. doi: 10.3171/jns.1994.80.1.0003.
129. Iliff JJ, Wang M, Liao Y, Plogg BA, Peng W, Gundersen GA, et al. A Paravascular Pathway Facilitates Csf Flow through the Brain Parenchyma and the Clearance of Interstitial Solutes, Including Amyloid β. *Sci Transl Med* (2012) 4(147):147ra11. doi: 10.1126/scitranslmed.3003748.
130. Hablitz LM, Nedergaard M. The Glymphatic System: A Novel Component of Fundamental Neurobiology. *J Neurosci* (2021) 41(37):7698–711. doi: 10.1523/jneurosci.0619-21.2021.
131. Nwotchouang BST, Eppelheimer MS, Pahlavian SH, Barrow JW, Barrow DL, Qiu D, et al. Regional Brain Tissue Displacement and Strain Is Elevated in Subjects with Chiari Malformation Type I Compared to Healthy Controls: A Study Using Dense Mri. *Ann Biomed Eng* (2021) 49(6):1462–76. Epub 20210104. doi: 10.1007/s10439-020-02695-7.
132. Eppelheimer MS, Nwotchouang BST, Heidari Pahlavian S, Barrow JW, Barrow DL, Amini R, et al. Cerebellar and Brainstem Displacement Measured with Dense Mri in Chiari Malformation Following Posterior Fossa Decompression Surgery. *Radiology* (2021) 301(1):187–94. Epub 20210727. doi: 10.1148/radiol.2021203036.
133. Al Samman MMF, Ibrahimy A, Nwotchouang BST, Oshinski JN, Barrow DL, Allen PA, et al. The Relationship between Imbalance Symptom and Cardiac Pulsation Induced Mechanical Strain in the Brainstem and Cerebellum for Chiari Malformation Type I. *J Biomech Eng* (2023) 145(8). doi: 10.1115/1.4062723.
134. McIlvain G, Williams B, Al Samman MM, Mohsenian S, Barrow DL, Loth F, et al. Measurement of Csf Flow and Brain Motion in Chiari Malformation Type I Subjects Undergoing Posterior Fossa Decompression Surgery. *J Neurosurg* (2025) 143(1):13–23. Epub 20250307. doi: 10.3171/2024.11.Jns241509.
135. Karamzadeh M, Al Samman MM, Maclellan C, Bhadelia RA, Oshinski J, Amini R, et al. Cardiac-Induced Brain Tissue Motion in Chiari Malformation Type 1 Subjects and Its Relationship to Symptomatology, Morphometrics, and Surgical Outcomes. *Magn Reson Imaging* (2025) 124:110530. Epub 20250920. doi: 10.1016/j.mri.2025.110530.
136. Dolar MT, Haughton VM, Iskandar BJ, Quigley M. Effect of Craniocervical Decompression on Peak Csf Velocities in Symptomatic Patients with Chiari I Malformation. *AJNR Am J Neuroradiol* (2004) 25(1):142–5.
137. Wetjen NM, Heiss JD, Oldfield EH. Time Course of Syringomyelia Resolution Following Decompression of Chiari Malformation Type I. *J Neurosurg Pediatr* (2008) 1(2):118–23. doi: 10.3171/ped/2008/1/2/118.
138. Ibrahimy A, Wu T, Mack J, Scott GC, Cortes MX, Cantor FK, et al. Prospective, Longitudinal Study of Clinical Outcome and Morphometric Posterior Fossa Changes after Craniocervical Decompression for

© 2026 by the author(s). Distributed under a Creative Commons CC BY license.

Preprints.org | NOT PEER-REVIEWED | Posted: 24 November 2026 https://doi.org/10.20944/preprints202611.2421.v1

Symptomatic Chiari I Malformation. *AJNR Am J Neuroradiol* (2023) 44(10):1150–6. Epub 20230914. doi: 10.3174/ajnr.A7993.

139. Schievink WI. Spontaneous Intracranial Hypotension. *N Engl J Med* (2021) 385(23):2173–8. doi: 10.1056/NEJMra2101561.
140. D'Antona L, Jaime Merchan MA, Vassiliou A, Watkins LD, Davagnanam I, Toma AK, et al. Clinical Presentation, Investigation Findings, and Treatment Outcomes of Spontaneous Intracranial Hypotension Syndrome: A Systematic Review and Meta-Analysis. *JAMA Neurol* (2021) 78(3):329–37. doi: 10.1001/jamaneurol.2020.4799.
141. Cheema S, Joy C, Pople J, Snape-Burns J, Trevarthen T, Matharu M. Patient Experience of Diagnosis and Management of Spontaneous Intracranial Hypotension: A Cross-Sectional Online Survey. *BMJ Open* (2022) 12(1):e057438. Epub 20220120. doi: 10.1136/bmjopen-2021-057438.
142. McRae-Posani B, Strauss S, Robbins MS, Salama G. Csf Pressures in Spontaneous Intracranial Hypotension Due to Csf-Venous Fistula: A Retrospective Analysis. *Clin Neurol Neurosurg* (2025) 258:109169. Epub 20250922. doi: 10.1016/j.clineuro.2025.109169.
143. Schievink WI, Maya MM, Riedinger M. Recurrent Spontaneous Spinal Cerebrospinal Fluid Leaks and Intracranial Hypotension: A Prospective Study. *J Neurosurg* (2003) 99(5):840–2. doi: 10.3171/jns.2003.99.5.0840.
144. Parks CA, Singh M, Wohler E, Martin R, Peeters S, Juzwiak EE, et al. Spontaneous Spinal Csf Leaks: A Rare Variant Exome Sequencing Study and Functional Analysis. *Lancet Neurol* (2026) 25(7):664–72. doi: 10.1016/s1474-4422(26)00140-7.
145. Nasiri D, Häni L, Goldberg J, Petutschnigg T, Dobrocky T, Schär RT, et al. Prevalence and Characteristics of Microspurs in Patients with Spontaneous Intracranial Hypotension Compared with the General Population. *AJNR Am J Neuroradiol* (2025) 46(7):1486–92. Epub 20250701. doi: 10.3174/ajnr.A8644.
146. Orru E, Patel NV, Pace J, Krings T. Spontaneous Intracranial Hypotension and Csf-Venous Fistulae: From Diagnostic Imaging to Interventional Management. *Clin Neuroradiol* (2026) 36(1):3–17. Epub 20251007. doi: 10.1007/s00062-025-01573-w.
147. Schievink WI, Maya MM, Jean-Pierre S, Nuño M, Prasad RS, Moser FG. A Classification System of Spontaneous Spinal Csf Leaks. *Neurology* (2016) 87(7):673–9. Epub 20160720. doi: 10.1212/wnl.0000000000002986.
148. Goldberg J, Häni L, Jesse CM, Zubak I, Piechowiak EI, Gralla J, et al. Spontaneous Intracranial Hypotension without Csf Leakage-Concept of a Pathological Cranial to Spinal Fluid Shift. *Front Neurol* (2021) 12:760081. Epub 20211101. doi: 10.3389/fneur.2021.760081.
149. Parikh SK. Rebound Intracranial Hypertension. *Curr Pain Headache Rep* (2024) 28(5):395–401. Epub 20240302. doi: 10.1007/s11916-024-01231-9.
150. Schievink WI, Maya MM, Jean-Pierre S, Moser FG, Nuño M, Pressman BD. Rebound High-Pressure Headache after Treatment of Spontaneous Intracranial Hypotension: Mrv Study. *Neurol Clin Pract* (2019) 9(2):93–100. doi: 10.1212/cpj.0000000000000550.
151. Schievink WI. Spontaneous Spinal Cerebrospinal Fluid Leaks and Intracranial Hypotension. *Jama* (2006) 295(19):2286–96. doi: 10.1001/jama.295.19.2286.
152. Vukovic-Cvetkovic V, Schytz HW. Airplane Flights Triggering Spontaneous Intracranial Hypotension: Observations from the Danish Headache Centre. *Acta Neurol Scand* (2022) 146(1):92–8. Epub 20220502. doi: 10.1111/ane.13626.
153. Farb RI, Nicholson PJ, Peng PW, Massicotte EM, Lay C, Krings T, et al. Spontaneous Intracranial Hypotension: A Systematic Imaging Approach for Csf Leak Localization and Management Based on Mri and Digital Subtraction Myelography. *AJNR Am J Neuroradiol* (2019) 40(4):745–53. Epub 20190328. doi: 10.3174/ajnr.A6016.
154. Dobrocky T, Nicholson P, Häni L, Mordasini P, Krings T, Brinjikji W, et al. Spontaneous Intracranial Hypotension: Searching for the Csf Leak. *Lancet Neurol* (2022) 21(4):369–80. Epub 20220225. doi: 10.1016/s1474-4422(21)00423-3.

© 2026 by the author(s). Distributed under a Creative Commons CC BY license.

Preprints.org | NOT PEER-REVIEWED | Posted: 24 November 2026 https://doi.org/10.20944/preprints202611.2421.v1

155. Murphy K, Nasralla M, Pron G, Almohaimede K, Schievink W. Management of Tarlov Cysts: An Uncommon but Potentially Serious Spinal Column Disease-Review of the Literature and Experience with over 1000 Referrals. *Neuroradiology* (2024) 66(1):1–30. Epub 20231013. doi: 10.1007/s00234-023-03226-6.
156. Binder DK, Dillon WP, Fishman RA, Schmidt MH. Intrathecal Saline Infusion in the Treatment of Obtundation Associated with Spontaneous Intracranial Hypotension: Technical Case Report. *Neurosurgery* (2002) 51(3):830–6; discussion 6–7.
157. Chiu PF, Lin YH, Lu HS, Hsiao IH, Lin HL. Continuous Intrathecal Saline Infusion for Treating Refractory Spontaneous Intracranial Hypotension: A Case Report. *Biomedicine (Taipei)* (2023) 13(4):51–6. Epub 20231201. doi: 10.37796/2211-8039.1417.
158. Ghavanini AA, Scott CA, Chan DK, Tang-Wai DF. Management of Patients with Spontaneous Intracranial Hypotension Causing Altered Level of Consciousness: Report of Two Cases and Review of Literature. *Cephalalgia* (2013) 33(1):43–51. Epub 20121109. doi: 10.1177/0333102412466963.
159. Murphy K, Oaklander AL, Elias G, Kathuria S, Long DM. Treatment of 213 Patients with Symptomatic Tarlov Cysts by Ct-Guided Percutaneous Injection of Fibrin Sealant. *AJNR Am J Neuroradiol* (2016) 37(2):373–9. Epub 20150924. doi: 10.3174/ajnr.A4517.
160. Murphy J. Interoception: Where Do We Go from Here? *Q J Exp Psychol (Hove)* (2024) 77(2):223–9. Epub 20230509. doi: 10.1177/17470218231172725.
161. Yang AI, Rinehart CD, McShane BJ, Hitti FL, Welch WC. Growth of Lumbosacral Perineural (Tarlov) Cysts: A Natural History Analysis. *Neurosurgery* (2020) 86(1):88–92. doi: 10.1093/neuros/nyy586.
162. Fargen KM, Stout C, Vargas J, Ashraf O, Siddiqui A, Hui FK. Cerebral Venous Outflow Revisited: Contemporary Insights to Simplify a Complex Disease. *Interv Neuroradiol* (2025):15910199251380374. Epub 20251028. doi: 10.1177/15910199251380374.
163. Margraf CR, Midtlien JP, Hui FK, Ehrig MR, Kittel CA, Siddiqui AH, et al. Clinical Symptoms of Jugular Venous Outflow Obstruction and Their Modification after Targeted Surgical Treatment. *Neurosurg Pract* (2026) 7(3):e000238. Epub 20260507. doi: 10.1227/neuprac.0000000000000238.
164. Arun A, Amans MR, Higgins N, Brinjikji W, Sattur M, Satti SR, et al. A Proposed Framework for Cerebral Venous Congestion. *Neuroradiol J* (2022) 35(1):94–111. Epub 20210705. doi: 10.1177/19714009211029261.
165. Benson JC, Madhavan AA, Cutsforth-Gregory JK, Johnson DR, Carr CM. The Monro-Kellie Doctrine: A Review and Call for Revision. *AJNR Am J Neuroradiol* (2023) 44(1):2–6. Epub 20221201. doi: 10.3174/ajnr.A7721.
166. Wilson MH. Monro-Kellie 2.0: The Dynamic Vascular and Venous Pathophysiological Components of Intracranial Pressure. *J Cereb Blood Flow Metab* (2016) 36(8):1338–50. Epub 20160512. doi: 10.1177/0271678x16648711.
167. Aaron G, Doyle J, Vaphiades MS, Riley KO, Woodworth BA. Increased Intracranial Pressure in Spontaneous Csf Leak Patients Is Not Associated with Papilledema. *Otolaryngol Head Neck Surg* (2014) 151(6):1061–6. Epub 20140923. doi: 10.1177/0194599814551122.
168. Carper MG, Guillot FH, Gasquet NC, Carey AR, Henderson AD. Clinical Features of High Intracranial Pressure and Prevalence of Idiopathic Intracranial Hypertension among Patients Presenting with Spontaneous Csf Leaks. *Neurosurg Focus* (2026) 60(1):E9. doi: 10.3171/2025.10.Focus25815.
169. Li H, Guan X, Liu L, Lu C, Zhang W, Zhou Y, et al. Cerebral Venous Outflow Insufficiency: A Study on Symptoms and Venous Stenosis Classification. *MedComm (2020)* (2026) 7(3):e70609. Epub 20260226. doi: 10.1002/mco2.70609.
170. Gisolf J, van Lieshout JJ, van Heusden K, Pott F, Stok WJ, Karemaker JM. Human Cerebral Venous Outflow Pathway Depends on Posture and Central Venous Pressure. *J Physiol* (2004) 560(Pt 1):317–27. Epub 20040729. doi: 10.1113/jphysiol.2004.070409.
171. Pang S, Kolarich AR, Brinjikji W, Nakaji P, Hepworth E, Hui F. Interventional and Surgical Management of Internal Jugular Venous Stenosis: A Narrative Review. *J Neurointerv Surg* (2022) 14(5). Epub 20210824. doi: 10.1136/neurintsurg-2021-017937.
172. Ding JY, Zhou D, Pan LQ, Ya JY, Liu C, Yan F, et al. Cervical Spondylotic Internal Jugular Venous Compression Syndrome. *CNS Neurosci Ther* (2020) 26(1):47–54. Epub 20190522. doi: 10.1111/cns.13148.

© 2026 by the author(s). Distributed under a Creative Commons CC BY license.

Preprints.org | NOT PEER-REVIEWED | Posted: 24 November 2026 https://doi.org/10.20944/preprints202611.2421.v1

173. Midtlien JP, Curry BP, Chang E, Kiritsis NR, Aldridge JB, Fargen KM. Characterizing a New Clinical Phenotype: The Co-Existence of Cerebral Venous Outflow and Connective Tissue Disorders. *Front Neurol* (2023) 14:1305972. Epub 20240110. doi: 10.3389/fneur.2023.1305972.
174. Prabhat N, Chandel S, Takkar DA, Ahuja C, Singh R, Kathirvel S, et al. Sensitivity and Specificity of Neuroimaging Signs in Patients with Idiopathic Intracranial Hypertension. *Neuroradiol J* (2021) 34(5):421–7. Epub 20210308. doi: 10.1177/19714009211000623.
175. Cha YH, Gharib M, Chan K, Karam J. Sternocleidomastoid Omohyoid Entrapment of the Internal Jugular Vein Causing Vertigo and Headaches. *Clin Otolaryngol* (2025) 50(5):918–23. Epub 20250424. doi: 10.1111/coa.14325.
176. Fargen KM, Midtlien JP, Margraf CR, Wiater AH, Marcet PA, Siddiqui AH, et al. Cerebral Venous Pressures, Sinus Trans-Stenosis Gradients, and Intracranial Pressures Are Dramatically Augmented by Head Position. *J Neurointerv Surg* (2025) 17(10):1120–6. Epub 20250912. doi: 10.1136/jnis-2024-022167.
177. Abeysinghe N, Parker G, Allan R, Rao PJ, Elliott MS. Surgical Outcomes of Styloidectomy, Internal Jugular Vein Fasciotomy, and C1 Transverse Process Resection for Venopathic Intracranial Hypertension. *Neurosurg Focus* (2026) 60(1):E18. doi: 10.3171/2025.10.Focus25849.
178. Midtlien JP, Ashraf O, Yager B, Margraf CR, Wiater AH, Chang E, et al. Styloidectomy for Jugular Decompression in Venous Outflow Disorders. *World Neurosurg* (2026) 205:124717. Epub 20251212. doi: 10.1016/j.wneu.2025.124717.
179. Petersingham G, Shrestha N, Elliott M, Allan RS, Parker G, Camp LV, et al. Invasive Surgical Management of Cervical Internal Jugular Venous Compression: A Literature Review. *J Clin Neurosci* (2025) 137:111304. Epub 20250509. doi: 10.1016/j.jocn.2025.111304.
180. Eide PK. Abnormal Intracranial Pulse Pressure Amplitude Despite Normalized Static Intracranial Pressure in Idiopathic Intracranial Hypertension Refractory to Conservative Medical Therapy. *Life (Basel)* (2021) 11(6). Epub 20210609. doi: 10.3390/life11060537.
181. Mitchell JL, Buckham R, Lyons H, Walker JK, Yiangou A, Sassani M, et al. Evaluation of Diurnal and Postural Intracranial Pressure Employing Telemetric Monitoring in Idiopathic Intracranial Hypertension. *Fluids Barriers CNS* (2022) 19(1):85. Epub 20221101. doi: 10.1186/s12987-022-00384-2.
182. Yiangou A, Weaver SRC, Thaller M, Mitchell JL, Lyons HS, Tsermoulas G, et al. The Impact of Valsalva Manoeuvres and Exercise on Intracranial Pressure and Cerebrovascular Dynamics in Idiopathic Intracranial Hypertension. *Neuroophthalmology* (2024) 48(2):122–33. Epub 20231122. doi: 10.1080/01658107.2023.2281433.
183. Battal B, Kocaoglu M, Bulakbasi N, Husmen G, Tuba Sanal H, Tayfun C. Cerebrospinal Fluid Flow Imaging by Using Phase-Contrast Mr Technique. *Br J Radiol* (2011) 84(1004):758–65. Epub 20110517. doi: 10.1259/bjr/66206791.
184. Piagkou M, Anagnostopoulou S, Kouladouros K, Piagkos G. Eagle's Syndrome: A Review of the Literature. *Clin Anat* (2009) 22(5):545–58. doi: 10.1002/ca.20804.
185. Higgins JN, Garnett MR, Pickard JD, Axon PR. An Evaluation of Styloidectomy as an Adjunct or Alternative to Jugular Stenting in Idiopathic Intracranial Hypertension and Disturbances of Cranial Venous Outflow. *J Neurol Surg B Skull Base* (2017) 78(2):158–63. Epub 20161123. doi: 10.1055/s-0036-1594238.
186. Zhao X, Cavallo C, Hlubek RJ, Mooney MA, Belykh E, Gandhi S, et al. Styloidogenic Jugular Venous Compression Syndrome: Clinical Features and Case Series. *Oper Neurosurg* (2019) 17(6):554–61. doi: 10.1093/ons/opz012.
187. Balcioglu HA, Kilic C, Akyol M, Ozan H, Kokten G. Length of the Styloid Process and Anatomical Implications for Eagle's Syndrome. *Folia Morphol (Warsz)* (2009) 68(4):265–70.
188. Yaşar S, Erdim İ, Bilir AB. Is There a Relationship between Styloid Process Morphology and Symptoms Associated with Eagle Syndrome? *Ann Otol Rhinol Laryngol* (2025) 134(11):848–53. Epub 20250620. doi: 10.1177/00034894251349387.
189. Badhey A, Jategaonkar A, Anglin Kovacs AJ, Kadakia S, De Deyn PP, Ducic Y, et al. Eagle Syndrome: A Comprehensive Review. *Clin Neurol Neurosurg* (2017) 159:34–8. Epub 20170506. doi: 10.1016/j.clineuro.2017.04.021.

© 2026 by the author(s). Distributed under a Creative Commons CC BY license.

Preprints.org | NOT PEER-REVIEWED | Posted: 24 November 2026 https://doi.org/10.20944/preprints202611.2421.v1

190. Malfait F, Castori M, Francomano CA, Giunta C, Kosho T, Byers PH. The Ehlers-Danlos Syndromes. *Nat Rev Dis Primers* (2020) 6(1):64. Epub 20200730. doi: 10.1038/s41572-020-0194-9.
191. Bănică DA, Zamfirescu VI, Rusu MC, Brezean I. Compression Syndromes of the Stylohyoid Complex: Neural, Arterial, and Venous Phenotypes in a Dynamic Neurovascular Corridor. *Tomography* (2026) 12(9). Epub 20260907. doi: 10.3390/tomography12090127.
192. Zeckler SR, Betancur AG, Yaniv G. The Eagle Is Landing: Eagle Syndrome--an Important Differential Diagnosis. *Br J Gen Pract* (2012) 62(602):501–2. doi: 10.3399/bjgp12X654777.
193. Chiarelli N, Zoppi N, Venturini M, Capitanio D, Gelfi C, Ritelli M, et al. Matrix Metalloproteinases Inhibition by Doxycycline Rescues Extracellular Matrix Organization and Partly Reverts Myofibroblast Differentiation in Hypermobile Ehlers-Danlos Syndrome Dermal Fibroblasts: A Potential Therapeutic Target? *Cells* (2021) 10(11). Epub 20211119. doi: 10.3390/cells10113236.
194. Younesi FS, Miller AE, Barker TH, Rossi FMV, Hinz B. Fibroblast and Myofibroblast Activation in Normal Tissue Repair and Fibrosis. *Nat Rev Mol Cell Biol* (2024) 25(8):617–38. Epub 20240408. doi: 10.1038/s41580-024-00716-0.
195. Shin JH, Herrera SR, Eboli P, Aydin S, Eskandar EH, Slavin KV. Entrapment of the Glossopharyngeal Nerve in Patients with Eagle Syndrome: Surgical Technique and Outcomes in a Series of 5 Patients. *J Neurosurg* (2009) 111(6):1226–30. doi: 10.3171/2009.1.Jns08485.
196. Dashti SR, Nakaji P, Hu YC, Frei DF, Abla AA, Yao T, et al. Styloidogenic Jugular Venous Compression Syndrome: Diagnosis and Treatment: Case Report. *Neurosurgery* (2012) 70(3):E795–9. doi: 10.1227/NEU.0b013e3182333859.
197. Giakoustidis A, Moschonas S, Christodoulidis G, Chourmouzi D, Diamantidou A, Masoura S, et al. Median Arcuate Ligament Syndrome Often Poses a Diagnostic Challenge: A Literature Review with a Scope of Our Own Experience. *World J Gastrointest Surg* (2023) 15(6):1048–55. doi: 10.4240/wjgs.v15.i6.1048.
198. Sandmann W, Scholbach T, Verginis K. Surgical Treatment of Abdominal Compression Syndromes: The Significance of Hypermobility-Related Disorders. *Am J Med Genet C Semin Med Genet* (2021) 187(4):570–8. Epub 20211107. doi: 10.1002/ajmg.c.31949.
199. Bruessel P, Govender M, Frahm-Jensen G. The Investigation and Management of the Abdominopelvic Vascular Compression Syndromes in Patients with Ehlers-Danlos Syndrome and Hypermobility Spectrum Disorder. *Vasc Health Risk Manag* (2026) 22:592420. Epub 20260327. doi: 10.2147/vhrm.S592420.
200. Milunsky A, Milunsky JM, Hsu R. Abdominal Compression Syndromes in the Hypermobile Ehlers-Danlos Syndrome. *Am J Med Genet A* (2025) 197(12):e64182. Epub 20250713. doi: 10.1002/ajmg.a.64182.
201. Lu LY, Eastment JG, Sivakumaran Y. Median Arcuate Ligament Syndrome (Mals) in Hepato-Pancreato-Biliary Surgery: A Narrative Review and Proposed Management Algorithm. *J Clin Med* (2024) 13(9). Epub 20240428. doi: 10.3390/jcm13092598.
202. Terlouw LG, Moelker A, Abrahamsen J, Acosta S, Bakker OJ, Baumgartner I, et al. European Guidelines on Chronic Mesenteric Ischaemia - Joint United European Gastroenterology, European Association for Gastroenterology, Endoscopy and Nutrition, European Society of Gastrointestinal and Abdominal Radiology, Netherlands Association of Hepatogastroenterologists, Hellenic Society of Gastroenterology, Cardiovascular and Interventional Radiological Society of Europe, and Dutch Mesenteric Ischemia Study Group Clinical Guidelines on the Diagnosis and Treatment of Patients with Chronic Mesenteric Ischaemia. *United European Gastroenterol J* (2020) 8(4):371–95. Epub 20200416. doi: 10.1177/2050640620916681.
203. Haruta H, Higashida M, Hoshina K, Takayama T, Ueno T, Chiba S, et al. Consensus Statement on Precision Anatomy and Treatment Strategies for Median Arcuate Ligament Syndrome: Aob Consensus Meeting. *Asian J Endosc Surg* (2026) 19(1):e70208. doi: 10.1111/ases.70208.
204. Bower KS, McCarthy CC, Vyasa P, Nagarsheth K, Desai MJ. Celiac Plexus Block: A Diagnostic Tool for Neurogenic Median Arcuate Ligament Syndrome. *Pain Pract* (2025) 25(1):e13403. Epub 20240804. doi: 10.1111/papr.13403.
205. Shnayder-Adams MM, Masotti M, Sanogo ML. Clinical Outcomes after Median Arcuate Ligament Release in Patients Responsive to Celiac Plexus Block. *J Vasc Interv Radiol* (2024) 35(4):558–62. Epub 20240103. doi: 10.1016/j.jvir.2023.12.569.

© 2026 by the author(s). Distributed under a Creative Commons CC BY license.

Preprints.org | NOT PEER-REVIEWED | Posted: 24 November 2026 https://doi.org/10.20944/preprints202611.2421.v1

206. Spencer EB, Elhage Hassan M, Saikia J, Ajeya D, Phillips R, Steinberg RS, et al. Association and Post-Iliac Vein Stenting Symptom Improvement of Postural Orthostatic Tachycardia Syndrome and Orthostatic Intolerance with Pelvic Venous Disorders: Two Retrospective Studies. *EClinicalMedicine* (2026) 92:103772. Epub 20260203. doi: 10.1016/j.eclinm.2026.103772.
207. Zurcher KS, Staack SO, Spencer EB, Liska A, Alzubaidi SJ, Patel IJ, et al. Venous Anatomy and Collateral Pathways of the Pelvis: An Angiographic Review. *Radiographics* (2022) 42(5):1532–45. Epub 20220722. doi: 10.1148/rg.220012.
208. Davis BM, Rantanen P, Seo G, Thadani S, Spencer EB, Hepworth E, et al. An Overview of Vascular Compression Syndromes and Associations with Autonomic Dysfunction: A Review. *Biomedicines* (2026) 14(3). Epub 20260317. doi: 10.3390/biomedicines14030689.
209. Ormiston CK, Padilla E, Van DT, Boone C, You S, Roberts AC, et al. May-Thurner Syndrome in Patients with Postural Orthostatic Tachycardia Syndrome and Ehlers-Danlos Syndrome: A Case Series. *Eur Heart J Case Rep* (2022) 6(4):ytac161. Epub 20220409. doi: 10.1093/ehjcr/ytac161.
210. Smith SJ, Smith BH, Sichlau MJ, Chen B, Knight D, Rowe PC. Nonpelvic Comorbid Symptoms of 45 Patients with Pain of Pelvic Venous Origin, before and after Treatment. *Phlebology* (2025) 40(2):66–79. Epub 20240810. doi: 10.1177/02683555241273109.
211. Ogunlade SB, Brown D, Rozen T, Lewis AR, Toskich BB, Fairweather D, et al. Comparative Assessment of Left Common Iliac Vein Compression in Patients with Hypermobile Ehlers-Danlos Syndrome, Hypermobility Spectrum Disorder and Healthy Controls - a Retrospective Single-Centre Study. *Phlebology* (2026) 41(6):506–14. Epub 20251117. doi: 10.1177/02683555251400392.
212. Heilijgers F, Gloviczki P, O'Sullivan G, Chavent B, Avgerinos ED, Harth K, et al. Nutcracker Syndrome (a Delphi Consensus). *J Vasc Surg Venous Lymphat Disord* (2025) 13(1):101970. Epub 20241002. doi: 10.1016/j.jvsv.2024.101970.
213. Amato ACM, da Silva AEC, Bernal IM, de Oliveira JC, Di Paschoal Almeida Ribeiro M, Schinzari PS, et al. Combined Nutcracker and Ehlers-Danlos Syndromes: A Case Report. *EJVES Vasc Forum* (2020) 47:12–7. Epub 20200227. doi: 10.1016/j.ejvsvf.2020.02.005.
214. Rozen TD, Devcic Z, Toskich B, Caserta MP, Sandhu SJS, Huynh T, et al. Nutcracker Phenomenon with a Daily Persistent Headache as the Primary Symptom: Case Series and a Proposed Pathogenesis Model Based on a Novel Mri Technique to Evaluate for Spinal Epidural Venous Congestion. *J Neurol Sci* (2022) 434:120170. Epub 20220126. doi: 10.1016/j.jns.2022.120170.
215. Rozen TD, Devcic Z, Lewis AR, Sandhu SJS, Erben Y, Toskich BB. A Secondary Daily Persistent Headache from Onset with Underlying Nutcracker Physiology and Spinal Epidural Venous Congestion: Case Series with Lumbar Vein Embolization as a Therapeutic Approach. *Ther Adv Neurol Disord* (2023) 16:17562864231213243. Epub 20231122. doi: 10.1177/17562864231213243.
216. Rozen TD, Devcic Z, Toskich BB, Fairweather D, Bruno KA. A Possible Newly Defined and Treatable Secondary Cause of Early Morning Wake-up Headaches in an Older Hypermobile Woman: Nutcracker Physiology with Spinal Epidural Venous Congestion. *Case Rep Neurol* (2024) 16(1):71–8. Epub 20240207. doi: 10.1159/000537705.
217. Kolber MK, Cui Z, Chen CK, Habibollahi P, Kalva SP. Nutcracker Syndrome: Diagnosis and Therapy. *Cardiovasc Diagn Ther* (2021) 11(5):1140–9. doi: 10.21037/cdt-20-160.
218. Sarikaya S, Altas O, Ozgur MM, Hancer H, Aksut M, Topcu KO, et al. Contemporary Management of Nutcracker Syndrome: A Systematic Review. *Ann Vasc Surg* (2025) 121:406–21. Epub 20250813. doi: 10.1016/j.avsg.2025.07.043.
219. Oka A, Awoniyi M, Hasegawa N, Yoshida Y, Tobita H, Ishimura N, et al. Superior Mesenteric Artery Syndrome: Diagnosis and Management. *World J Clin Cases* (2023) 11(15):3369–84. doi: 10.12998/wjcc.v11.i15.3369.
220. Mohammed A, Zinabu SW, Michael MB. Navigating Complexities: A Case of Multiple Abdominopelvic Vascular Compression Syndromes in Ehlers-Danlos Syndrome. *Cureus* (2024) 16(7):e63848. Epub 20240704. doi: 10.7759/cureus.63848.

© 2026 by the author(s). Distributed under a Creative Commons CC BY license.

Preprints.org | NOT PEER-REVIEWED | Posted: 24 November 2026 https://doi.org/10.20944/preprints202611.2421.v1

221. Maria MS, Anoosh F, Houssam O, Joshua K, Shankar L, Anish J, et al. Superior Mesenteric Artery Syndrome: A Contemporary Review of Diagnosis and Surgical Management. *J Gastrointest Surg* (2026) 30(9):102506. Epub 20260725. doi: 10.1016/j.gassur.2026.102506.
222. Reinstein E, Pimentel M, Pariani M, Nemec S, Sokol T, Rimoin DL. Visceroptosis of the Bowel in the Hypermobility Type of Ehlers-Danlos Syndrome: Presentation of a Rare Manifestation and Review of the Literature. *Eur J Med Genet* (2012) 55(10):548–51. Epub 20120707. doi: 10.1016/j.ejmg.2012.06.012.
223. Thwaites PA, Gibson PR, Burgell RE. Hypermobile Ehlers-Danlos Syndrome and Disorders of the Gastrointestinal Tract: What the Gastroenterologist Needs to Know. *J Gastroenterol Hepatol* (2022) 37(9):1693–709. Epub 20220720. doi: 10.1111/jgh.15927.
224. Alsaleh N, Yaseen W, Alshamat RA, Aljurushi R, Alshareef B. Superior Mesenteric Artery Syndrome Following Colorectal Surgery: A Systematic Review. *Ann Med Surg (Lond)* (2025) 87(5):2763–73. Epub 20250328. doi: 10.1097/ms9.0000000000003209.
225. England J, Li N. Superior Mesenteric Artery Syndrome: A Review of the Literature. *J Am Coll Emerg Physicians Open* (2021) 2(3):e12454. Epub 20210618. doi: 10.1002/emp2.12454.
226. Illig KA, Donahue D, Duncan A, Freischlag J, Gelabert H, Johansen K, et al. Reporting Standards of the Society for Vascular Surgery for Thoracic Outlet Syndrome. *J Vasc Surg* (2016) 64(3):e23–35. doi: 10.1016/j.jvs.2016.04.039.
227. Ferrante MA, Ferrante ND. The Thoracic Outlet Syndromes: Part 1. Overview of the Thoracic Outlet Syndromes and Review of True Neurogenic Thoracic Outlet Syndrome. *Muscle Nerve* (2017) 55(6):782–93. Epub 20170321. doi: 10.1002/mus.25536.
228. Jiang D, Weiss R, Lind B, Morcos O, Lee CJ. Predisposing Anatomy for Thoracic Outlet Syndrome and Functional Outcomes after Supraclavicular Thoracic Outlet Decompression in Athletes. *Vasc Specialist Int* (2024) 40:19. Epub 20240611. doi: 10.5758/vsi.240011.
229. Munro T, Sak L, Ulloa JG, O'Connell JB, Gelabert HA. The Intersection of Hypermobile Ehlers-Danlos Syndrome and Thoracic Outlet Syndrome. *Ann Vasc Surg* (2026) 134:33–9. Epub 20260904. doi: 10.1016/j.avsg.2026.08.046.
230. Sanders RJ, Annest SJ. Thoracic Outlet and Pectoralis Minor Syndromes. *Semin Vasc Surg* (2014) 27(2):86–117. Epub 20150218. doi: 10.1053/j.semvascsurg.2015.02.001.
231. Christoforou ME, Lum YW, Sroge SC, Azola AM, Rowe PC. Improvement in Upper Limb and Systemic Myalgic Encephalomyelitis/Chronic Fatigue Syndrome (Me/Cfs) Symptoms after Surgical Treatment of Neurogenic Thoracic Outlet Syndrome. *Cureus* (2025) 17(8):e90494. Epub 20250819. doi: 10.7759/cureus.90494.
232. Sanders RJ, Hammond SL, Rao NM. Diagnosis of Thoracic Outlet Syndrome. *J Vasc Surg* (2007) 46(3):601–4. doi: 10.1016/j.jvs.2007.04.050.
233. Nord KM, Kapoor P, Fisher J, Thomas G, Sundaram A, Scott K, et al. False Positive Rate of Thoracic Outlet Syndrome Diagnostic Maneuvers. *Electromyogr Clin Neurophysiol* (2008) 48(2):67–74.
234. Gillet R, Teixeira P, Meyer JB, Rauch A, Raymond A, Dap F, et al. Dynamic Ct Angiography for the Diagnosis of Patients with Thoracic Outlet Syndrome: Correlation with Patient Symptoms. *J Cardiovasc Comput Tomogr* (2018) 12(2):158–65. Epub 20171202. doi: 10.1016/j.jcct.2017.11.008.
235. Beason AM, Thayer JA, Arras N, Franke JD, Mailey BA. Anterior Scalene Muscle Block Response Predicts Outcomes Following Thoracic Outlet Decompression. *Hand (N Y)* (2024) 19(3):361–6. Epub 20221105. doi: 10.1177/15589447221131850.
236. Aktas I, Ofluoglu D, Albay T. The Relationship between Benign Joint Hypermobility Syndrome and Carpal Tunnel Syndrome. *Clin Rheumatol* (2008) 27(10):1283–7. Epub 20080605. doi: 10.1007/s10067-008-0909-x.
237. Granata G, Padua L, Celletti C, Castori M, Saraceni VM, Camerota F. Entrapment Neuropathies and Polyneuropathies in Joint Hypermobility Syndrome/Ehlers-Danlos Syndrome. *Clin Neurophysiol* (2013) 124(8):1689–94. Epub 20130604. doi: 10.1016/j.clinph.2012.12.051.
238. Dekker TJ, DePhillipo NN, Kennedy MI, Aman ZS, Schairer WW, LaPrade RF. Clinical Characteristics and Outcomes after Anatomic Reconstruction of the Proximal Tibiofibular Joint. *Arthroscopy* (2020) 36(6):1649–54. Epub 20200213. doi: 10.1016/j.arthro.2020.01.056.

© 2026 by the author(s). Distributed under a Creative Commons CC BY license.

Preprints.org | NOT PEER-REVIEWED | Posted: 24 November 2026 https://doi.org/10.20944/preprints202611.2421.v1

239. O'Reilly OC, Carruthers KH, Siparsky PN. Bilateral, Atraumatic Proximal Tibiofibular Joint Instability Treated with Suspensory Button Fixation. *Orthopedics* (2017) 40(6):e1107–e11. Epub 20170804. doi: 10.3928/01477447-20170719-05.
240. Gardner JE, Jones H, Wagner ER, Bowers RL. Ultrasound Diagnosis of Upper Extremity Peripheral Entrapment Neuropathies: A Narrative Review. *JBJS Rev* (2024) 12(9). Epub 20240919. doi: 10.2106/jbjs.Rvw.24.00099.
241. De Wandele I, Rombaut L, Leybaert L, Van de Borne P, De Backer T, Malfait F, et al. Dysautonomia and Its Underlying Mechanisms in the Hypermobility Type of Ehlers-Danlos Syndrome. *Semin Arthritis Rheum* (2014) 44(1):93–100. Epub 20131230. doi: 10.1016/j.semarthrit.2013.12.006.
242. Novak P, Systrom DM, Marciano SP, Witte A, Warren A, Felsenstein D, et al. Hypermobile Ehlers-Danlos Syndrome: Cerebrovascular, Autonomic and Neuropathic Features. *Am J Med Open* (2025) 14:100111. Epub 20250718. doi: 10.1016/j.ajmo.2025.100111.
243. Roma M, Marden CL, De Wandele I, Francomano CA, Rowe PC. Postural Tachycardia Syndrome and Other Forms of Orthostatic Intolerance in Ehlers-Danlos Syndrome. *Auton Neurosci* (2018) 215:89–96. Epub 20180305. doi: 10.1016/j.autneu.2018.02.006.
244. Rowe PC, Barron DF, Calkins H, Maumenee IH, Tong PY, Geraghty MT. Orthostatic Intolerance and Chronic Fatigue Syndrome Associated with Ehlers-Danlos Syndrome. *J Pediatr* (1999) 135(4):494–9. doi: 10.1016/s0022-3476(99)70173-3.
245. Rowe P. *Selected Heritable Disorders of Connective Tissue and Disability*: The National Academies Press (2022).
246. van Campen C, Verheugt FWA, Rowe PC, Visser FC. Cerebral Blood Flow Is Reduced in Me/Cfs during Head-up Tilt Testing Even in the Absence of Hypotension or Tachycardia: A Quantitative, Controlled Study Using Doppler Echography. *Clin Neurophysiol Pract* (2020) 5:50–8. Epub 20200208. doi: 10.1016/j.cnp.2020.01.003.
247. van Campen LMC, Rowe PC, Visser FC. The Myalgic Encephalomyelitis/Chronic Fatigue Syndrome Patients with Joint Hypermobility Show Larger Cerebral Blood Flow Reductions during Orthostatic Stress Testing Than Patients without Hypermobility: A Case Control Study. *Medical Research Archives* (2021) 9(6). doi: 10.18103/mra.v9i6.2494.
248. Hakim A, De Wandele I, O'Callaghan C, Pocinki A, Rowe P. Chronic Fatigue in Ehlers-Danlos Syndrome-Hypermobile Type. *Am J Med Genet C Semin Med Genet* (2017) 175(1):175–80. Epub 20170210. doi: 10.1002/ajmg.c.31542.
249. Beissner F, Meissner K, Bär KJ, Napadow V. The Autonomic Brain: An Activation Likelihood Estimation Meta-Analysis for Central Processing of Autonomic Function. *J Neurosci* (2013) 33(25):10503–11. doi: 10.1523/jneurosci.1103-13.2013.
250. Quadt L, Critchley H, Nagai Y. Cognition, Emotion, and the Central Autonomic Network. *Auton Neurosci* (2022) 238:102948. Epub 20220131. doi: 10.1016/j.autneu.2022.102948.
251. Goldstein DS. Stress and the "Extended" Autonomic System. *Auton Neurosci* (2021) 236:102889. Epub 20211002. doi: 10.1016/j.autneu.2021.102889.
252. Lamotte G, Shouman K, Benarroch EE. Stress and Central Autonomic Network. *Auton Neurosci* (2021) 235:102870. Epub 20210825. doi: 10.1016/j.autneu.2021.102870.
253. Mohamed AZ, Kwiatek R, Del Fante P, Calhoun VD, Lagopoulos J, Shan ZY. Functional Mri of the Brainstem for Assessing Its Autonomic Functions: From Imaging Parameters and Analysis to Functional Atlas. *J Magn Reson Imaging* (2024) 60(5):1880–91. Epub 20240209. doi: 10.1002/jmri.29286.
254. Su TJ, Lin CJ, Liu YL, Hsueh HW, Hsieh ST, Chao CC, et al. Altered Connectivity of Central Autonomic Network: Effects of Dysautonomia in Hereditary Transthyretin Amyloidosis with Polyneuropathy. *Amyloid* (2024) 31(4):257–65. Epub 20240724. doi: 10.1080/13506129.2024.2383450.
255. Johnson JW, Mirro I, Kontorovich AR. Too High and Too Loose: Dysautonomia and the Hypertensive Paradox in Hypermobility Disorders. *Curr Opin Cardiol* (2026) 41(4):260–6. Epub 20260520. doi: 10.1097/hco.0000000000001310.
256. Shibao C, Arzubiaga C, Roberts LJ, 2nd, Raj S, Black B, Harris P, et al. Hyperadrenergic Postural Tachycardia Syndrome in Mast Cell Activation Disorders. *Hypertension* (2005) 45(3):385–90. Epub 20050214. doi: 10.1161/01.Hyp.0000158259.68614.40.

© 2026 by the author(s). Distributed under a Creative Commons CC BY license.

Preprints.org | NOT PEER-REVIEWED | Posted: 24 November 2026 https://doi.org/10.20944/preprints202611.2421.v1

257. Cazzato D, Castori M, Lombardi R, Caravello F, Bella ED, Petrucci A, et al. Small Fiber Neuropathy Is a Common Feature of Ehlers-Danlos Syndromes. *Neurology* (2016) 87(2):155–9. Epub 20160615. doi: 10.1212/wnl.0000000000002847.
258. Fernandez A, Aubry-Rozier B, Vautey M, Berna C, Suter MR. Small Fiber Neuropathy in Hypermobile Ehlers Danlos Syndrome/Hypermobility Spectrum Disorder. *J Intern Med* (2022) 292(6):957–60. Epub 20220715. doi: 10.1111/joim.13539.
259. Igharo D, Thiel JC, Rolke R, Akkaya M, Weis J, Katona I, et al. Skin Biopsy Reveals Generalized Small Fibre Neuropathy in Hypermobile Ehlers-Danlos Syndromes. *Eur J Neurol* (2023) 30(3):719–28. Epub 20221213. doi: 10.1111/ene.15649.
260. Thijs RD, Brignole M, Falup-Pecurariu C, Fanciulli A, Freeman R, Guaraldi P, et al. Recommendations for Tilt Table Testing and Other Provocative Cardiovascular Autonomic Tests in Conditions That May Cause Transient Loss of Consciousness : Consensus Statement of the European Federation of Autonomic Societies (Efas) Endorsed by the American Autonomic Society (Aas) and the European Academy of Neurology (Ean). *Auton Neurosci* (2021) 233:102792. Epub 20210319. doi: 10.1016/j.autneu.2021.102792.
261. Kool D, Hoeijmakers JG, Waxman SG, Faber CG. Small Fiber Neuropathy. *Int Rev Neurobiol* (2024) 179:181–231. Epub 20241029. doi: 10.1016/bs.irn.2024.10.001.
262. Dell'Aversana D, Provitera V, Trinchillo A, Masciarelli F, Tozza S, Caporaso G, et al. Distinct Sensory and Autonomic Involvement in Hypermobile Ehlers-Danlos Syndrome Compared with Idiopathic Small Fiber Neuropathy: A Multimodal Study. *Sci Rep* (2026). Epub 20260703. doi: 10.1038/s41598-026-60461-6.
263. Kersebaum D, Baron R, Gierthmühlen J, Forstenpointner J. Autonomic and Sensory Dysfunction in Hypermobile Ehlers-Danlos Syndrome: How Do Small Fibers Contribute? *Auton Neurosci* (2025) 260:103306. Epub 20250529. doi: 10.1016/j.autneu.2025.103306.
264. Furia A, Liguori R, Donadio V. Small-Fiber Neuropathy: An Etiology-Oriented Review. *Brain Sci* (2025) 15(2). Epub 20250206. doi: 10.3390/brainsci15020158.
265. Cinquina V, Carini G, Chiarelli N, Vezzoli M, Bertini V, Venturini M, et al. Proximity Extension Assay-Based Serum Proteomic Profiling Identifies Shared Protein Signatures in Hypermobile Ehlers-Danlos Syndrome and Hypermobility Spectrum Disorders. *Clin Proteomics* (2026) 23(1). Epub 20260307. doi: 10.1186/s12014-026-09588-2.
266. Petropoulos IN, Madani OA, Gad HY, Mahfoud ZR, Ponirakis G, MacDonald R, et al. Corneal Confocal Microscopy to Diagnose Peripheral Neuropathy: A Systematic Review and Meta-Analysis. *Eur J Neurol* (2025) 32(11):e70396. doi: 10.1111/ene.70396.
267. Castells M, Giannetti MP, Hamilton MJ, Novak P, Pozdnyakova O, Nicoloro-SantaBarbara J, et al. Mast Cell Activation Syndrome: Current Understanding and Research Needs. *J Allergy Clin Immunol* (2024) 154(2):255–63. Epub 20240606. doi: 10.1016/j.jaci.2024.05.025.
268. Brock I, Prendergast W, Maitland A. Mast Cell Activation Disease and Immunoglobulin Deficiency in Patients with Hypermobile Ehlers-Danlos Syndrome/Hypermobility Spectrum Disorder. *Am J Med Genet C Semin Med Genet* (2021) 187(4):473–81. Epub 20211107. doi: 10.1002/ajmg.c.31940.
269. Cuenca-Gómez JA, Dawid-Milner MS, Sánchez-Martínez R. Association between Ehlers-Danlos Syndrome and Mast Cell Activation Syndrome: Is There Scientific Evidence? *Rev Clin Esp (Barc)* (2026) 226(2):502457. Epub 20260117. doi: 10.1016/j.rceng.2026.502457.
270. Seneviratne SL, Maitland A, Afrin L. Mast Cell Disorders in Ehlers-Danlos Syndrome. *Am J Med Genet C Semin Med Genet* (2017) 175(1):226–36. Epub 20170306. doi: 10.1002/ajmg.c.31555.
271. Yao L, Subramaniam K, Raja KM, Arunachalam A, Tran A, Pandey T, et al. Association of Postural Orthostatic Tachycardia Syndrome, Hypermobility Spectrum Disorders, and Mast Cell Activation Syndrome in Young Patients; Prevalence, Overlap and Response to Therapy Depends on the Definition. *Front Neurol* (2025) 16:1513199. Epub 20250425. doi: 10.3389/fneur.2025.1513199.
272. Lyons JJ, Yu X, Hughes JD, Le QT, Jamil A, Bai Y, et al. Elevated Basal Serum Tryptase Identifies a Multisystem Disorder Associated with Increased Tpsab1 Copy Number. *Nat Genet* (2016) 48(12):1564–9. Epub 20161017. doi: 10.1038/ng.3696.

© 2026 by the author(s). Distributed under a Creative Commons CC BY license.

Preprints.org | NOT PEER-REVIEWED | Posted: 24 November 2026 https://doi.org/10.20944/preprints202611.2421.v1

273. Vazquez M, Chovanec J, Kim J, DiMaggio T, Milner JD, Francomano CA, et al. Hereditary Alpha-Tryptasemia Modifies Clinical Phenotypes among Individuals with Congenital Hypermobility Disorders. *HGG Adv* (2022) 3(2):100094. Epub 20220222. doi: 10.1016/j.xhgg.2022.100094.
274. Green DP, Limjunyawong N, Gour N, Pundir P, Dong X. A Mast-Cell-Specific Receptor Mediates Neurogenic Inflammation and Pain. *Neuron* (2019) 101(3):412–20.e3. Epub 20190124. doi: 10.1016/j.neuron.2019.01.012.
275. Serhan N, Basso L, Sibilano R, Petitfils C, Meixiong J, Bonnart C, et al. House Dust Mites Activate Nociceptor-Mast Cell Clusters to Drive Type 2 Skin Inflammation. *Nat Immunol* (2019) 20(11):1435–43. Epub 20191007. doi: 10.1038/s41590-019-0493-z.
276. Shimbori C, Upagupta C, Bellaye PS, Ayaub EA, Sato S, Yanagihara T, et al. Mechanical Stress-Induced Mast Cell Degranulation Activates Tgf-β1 Signalling Pathway in Pulmonary Fibrosis. *Thorax* (2019) 74(5):455–65. Epub 20190226. doi: 10.1136/thoraxjnl-2018-211516.
277. Royer SP, Han SJ. Mechanobiology in the Comorbidities of Ehlers Danlos Syndrome. *Front Cell Dev Biol* (2022) 10:874840. Epub 20220425. doi: 10.3389/fcell.2022.874840.
278. Sköld CM, Ohkuni Y, Liu XD, Numerof R, Rennard SI. Co-Cultured Human Mast Cells Stimulate Fibroblast-Mediated Contraction of Collagen Gels. *Inflammation* (2001) 25(1):47–51. doi: 10.1023/a:1007075628316.
279. Monument MJ, Hart DA, Salo PT, Befus AD, Hildebrand KA. Neuroinflammatory Mechanisms of Connective Tissue Fibrosis: Targeting Neurogenic and Mast Cell Contributions. *Adv Wound Care (New Rochelle)* (2015) 4(3):137–51. doi: 10.1089/wound.2013.0509.
280. Pelisenco IA, Cinquina V, Chiarelli N, Bertini V, Martini P, Carini G, et al. Multi-Omic Integration of the Mirnome and Transcriptome in Dermal Fibroblasts from Hypermobile Ehlers-Danlos Syndrome and Hypermobility Spectrum Disorders Identifies Convergent Candidate Mirna-Mrna Regulatory Networks Linking Extracellular Matrix Remodeling and Inflammation. *Int J Mol Sci* (2026) 27(19). Epub 20260926. doi: 10.3390/ijms27198628.
281. Akin C, Gülen T, Castells MC, Elberink HO, Valent P. Diagnosis and Management of Patients with Mast Cell Activation Syndromes: Status 2026. *J Allergy Clin Immunol Pract* (2026) 14(1):19–28. Epub 20251122. doi: 10.1016/j.jaip.2025.10.046.
282. Valent P, Bonadonna P, Hartmann K, Broesby-Olsen S, Brockow K, Butterfield JH, et al. Why the 20% + 2 Tryptase Formula Is a Diagnostic Gold Standard for Severe Systemic Mast Cell Activation and Mast Cell Activation Syndrome. *Int Arch Allergy Immunol* (2019) 180(1):44–51. Epub 20190628. doi: 10.1159/000501079.
283. Afrin LB, Ackerley MB, Bluestein LS, Brewer JH, Brook JB, Buchanan AD, et al. Diagnosis of Mast Cell Activation Syndrome: A Global "Consensus-2". *Diagnosis (Berl)* (2021) 8(2):137–52. Epub 20200422. doi: 10.1515/dx-2020-0005.
284. Gulen T. Using the Right Criteria for Mcas. *Curr Allergy Asthma Rep* (2024) 24(2):39–51. Epub 20240120. doi: 10.1007/s11882-024-01126-0.
285. Butterfield JH. Nontryptase Urinary and Hematologic Biomarkers of Mast Cell Expansion and Mast Cell Activation: Status 2022. *J Allergy Clin Immunol Pract* (2022) 10(8):1974–84. Epub 20220326. doi: 10.1016/j.jaip.2022.03.008.
286. Butterfield JH. Increased Excretion of Mast Cell Mediator Metabolites during Mast Cell Activation Syndrome. *J Allergy Clin Immunol Pract* (2023) 11(8):2542–6. Epub 20230228. doi: 10.1016/j.jaip.2023.02.017.
287. Hamilton MJ, Zhao M, Giannetti MP, Weller E, Hufdhi R, Novak P, et al. Distinct Small Intestine Mast Cell Histologic Changes in Patients with Hereditary Alpha-Tryptasemia and Mast Cell Activation Syndrome. *Am J Surg Pathol* (2021) 45(7):997–1004. doi: 10.1097/pas.0000000000001676.
288. Kulin D, Holtmann G, Fairlie T, Staller K, Nurko S, Keefer L, et al. Meta-Analysis: Chronic Gastrointestinal Symptoms and Comorbidities in Hypermobile Ehlers-Danlos Syndrome and Hypermobility Spectrum Disorders. *Aliment Pharmacol Ther* (2026) 64(5):574–89. Epub 20260712. doi: 10.1111/apt.70856.
289. Aziz Q, Harris LA, Goodman BP, Simrén M, Shin A. Aga Clinical Practice Update on Gi Manifestations and Autonomic or Immune Dysfunction in Hypermobile Ehlers-Danlos Syndrome: Expert Review. *Clin Gastroenterol Hepatol* (2025) 23(8):1291–302. Epub 20250519. doi: 10.1016/j.cgh.2025.02.015.

© 2026 by the author(s). Distributed under a Creative Commons CC BY license.

Preprints.org | NOT PEER-REVIEWED | Posted: 24 November 2026 https://doi.org/10.20944/preprints202611.2421.v1

290. Alomari M, Hitawala A, Chadalavada P, Covut F, Al Momani L, Khazaaleh S, et al. Prevalence and Predictors of Gastrointestinal Dysmotility in Patients with Hypermobile Ehlers-Danlos Syndrome: A Tertiary Care Center Experience. *Cureus* (2020) 12(4):e7881. Epub 20200429. doi: 10.7759/cureus.7881.
291. Nabar S, Fernandez J, Prakash V, Safder S. Gastrointestinal Manifestations Seen in Pediatric Patients Diagnosed with Small Fiber Neuropathy. *J Pediatr Gastroenterol Nutr* (2024) 78(3):583–91. Epub 20240123. doi: 10.1002/jpn3.12099.
292. Pimentel M, Morales W, Lezcano S, Sun-Chuan D, Low K, Yang J. Low-Dose Nocturnal Tegaserod or Erythromycin Delays Symptom Recurrence after Treatment of Irritable Bowel Syndrome Based on Presumed Bacterial Overgrowth. *Gastroenterol Hepatol (N Y)* (2009) 5(6):435–42.
293. Damianos JA, Jin M, Velasquez LO, Chowla N, Wang XJ. Small Intestinal Microbial Dysbiosis Is Common in Patients with Hypermobility Disorders and Gastrointestinal Symptoms. *Advances in Integrative Medicine* (2026) 13(2):100646. doi: https://doi.org/10.1016/j.aimed.2026.100646.
294. Fikree A, Chelimsky G, Collins H, Kovacic K, Aziz Q. Gastrointestinal Involvement in the Ehlers-Danlos Syndromes. *Am J Med Genet C Semin Med Genet* (2017) 175(1):181–7. Epub 20170210. doi: 10.1002/ajmg.c.31546.
295. Kciuk O, Li Q, Huszti E, McDermott CD. Pelvic Floor Symptoms in Cisgender Women with Ehlers-Danlos Syndrome: An International Survey Study. *Int Urogynecol J* (2023) 34(2):473–83. Epub 20220625. doi: 10.1007/s00192-022-05273-8.
296. Zhou W, Zikos TA, Halawi H, Sheth VR, Gurland B, Nguyen LA, et al. Anorectal Manometry for the Diagnosis of Pelvic Floor Disorders in Patients with Hypermobility Spectrum Disorders and Hypermobile Ehlers-Danlos Syndrome. *BMC Gastroenterol* (2022) 22(1):538. Epub 20221223. doi: 10.1186/s12876-022-02572-8.
297. Böhn L, Störsrud S, Törnblom H, Bengtsson U, Simrén M. Self-Reported Food-Related Gastrointestinal Symptoms in Ibs Are Common and Associated with More Severe Symptoms and Reduced Quality of Life. *Am J Gastroenterol* (2013) 108(5):634–41. doi: 10.1038/ajg.2013.105.
298. Mulak A, Taché Y, Larauche M. Sex Hormones in the Modulation of Irritable Bowel Syndrome. *World J Gastroenterol* (2014) 20(10):2433–48. doi: 10.3748/wjg.v20.i10.2433.
299. Sulaimi F, Ong TSK, Tang ASP, Quek J, Pillay RM, Low DT, et al. Risk Factors for Developing Irritable Bowel Syndrome: Systematic Umbrella Review of Reviews. *BMC Med* (2025) 23(1):103. Epub 20250221. doi: 10.1186/s12916-025-03930-5.
300. Jennings S, Russell N, Jennings B, Slee V, Sterling L, Castells M, et al. The Mastocytosis Society Survey on Mast Cell Disorders: Patient Experiences and Perceptions. *J Allergy Clin Immunol Pract* (2014) 2(1):70–6. Epub 20131203. doi: 10.1016/j.jaip.2013.09.004.
301. Golden DBK. The Many Faces of Mast Cell Disorders-a House of Mirrors? *J Allergy Clin Immunol Pract* (2019) 7(4):1139–41. doi: 10.1016/j.jaip.2019.02.003.
302. McGill SK, Hashash JG, Platts-Mills TA. Aga Clinical Practice Update on Alpha-Gal Syndrome for the Gi Clinician: Commentary. *Clin Gastroenterol Hepatol* (2023) 21(4):891–6. Epub 20230225. doi: 10.1016/j.cgh.2022.12.035.
303. Butt MF, Dervin H, Hoshino S, Yazaki E, Gerard P, Sweis R, et al. Esophageal Dysmotility and Gastroesophageal Reflux Disease Risk in Hypermobile Ehlers-Danlos Syndrome. *Clin Gastroenterol Hepatol* (2026). Epub 20260511. doi: 10.1016/j.cgh.2026.04.019.
304. Mehta D, Simmonds L, Hakim AJ, Matharu M. Headache Disorders in Patients with Ehlers-Danlos Syndromes and Hypermobility Spectrum Disorders. *Front Neurol* (2024) 15:1460352. Epub 20241108. doi: 10.3389/fneur.2024.1460352.
305. Tariq A, Khan MN, Jamali AG, Amir Basra M, Mahato A, Imran SM, et al. Association between Orthostatic Intolerance Symptoms and Cognitive Complaints in Hypermobile Ehlers-Danlos Syndrome (Heds) and Joint Hypermobility Spectrum Disorder (Jhsd): A Cross-Sectional Analysis. *Cureus* (2025) 17(6):e86123. Epub 20250616. doi: 10.7759/cureus.86123.
306. Müller K, Thiel JC, Schopen L, Fimm B, Schulz JB, Maier A. Impaired Attention and Cognitive Deficits Associated with Pain and Autonomic Symptoms in Hypermobile Ehlers-Danlos Syndrome: A Pilot Study. *Clin Auton Res* (2026) 36(2):223–32. Epub 20260309. doi: 10.1007/s10286-026-01191-7.

© 2026 by the author(s). Distributed under a Creative Commons CC BY license.

Preprints.org | NOT PEER-REVIEWED | Posted: 24 November 2026 https://doi.org/10.20944/preprints202611.2421.v1

307. Ashina M, Hansen JM, Do TP, Melo-Carrillo A, Burstein R, Moskowitz MA. Migraine and the Trigeminovascular System-40 Years and Counting. *Lancet Neurol* (2019) 18(8):795–804. Epub 20190531. doi: 10.1016/s1474-4422(19)30185-1.
308. Chopra P, Tinkle B, Hamonet C, Brock I, Gompel A, Bulbena A, et al. Pain Management in the Ehlers-Danlos Syndromes. *Am J Med Genet C Semin Med Genet* (2017) 175(1):212–9. Epub 20170210. doi: 10.1002/ajmg.c.31554.
309. Kosek E, Clauw D, Nijs J, Baron R, Gilron I, Harris RE, et al. Chronic Nociplastic Pain Affecting the Musculoskeletal System: Clinical Criteria and Grading System. *Pain* (2021) 162(11):2629–34. doi: 10.1097/j.pain.0000000000002324.
310. Montemayor Zarazúa AP, Elizondo Solis CV, Ayala García C, Pacheco Estrella DJ, Ilizaliturri Guerra O, Arana Guajardo AC, et al. Linking Central Sensitization to Multisystemic Manifestations in Hypermobile Ehlers-Danlos Syndrome. *Front Pain Res (Lausanne)* (2026) 7:1799439. Epub 20260630. doi: 10.3389/fpain.2026.1799439.
311. Schubert-Hjalmarsson E, Fasth A, Ickmans K, Söderpalm AC, Lundberg M. Exploring Signs of Central Sensitization in Adolescents with Hypermobility Spectrum Disorder or Hypermobile Ehlers-Danlos Syndrome. *Eur J Pain* (2025) 29(1):e4754. Epub 20241111. doi: 10.1002/ejp.4754.
312. Rolke R, Baron R, Maier C, Tölle TR, Treede DR, Beyer A, et al. Quantitative Sensory Testing in the German Research Network on Neuropathic Pain (Dfns): Standardized Protocol and Reference Values. *Pain* (2006) 123(3):231–43. Epub 20060511. doi: 10.1016/j.pain.2006.01.041.
313. Yarnitsky D, Bouhassira D, Drewes AM, Fillingim RB, Granot M, Hansson P, et al. Recommendations on Practice of Conditioned Pain Modulation (Cpm) Testing. *Eur J Pain* (2015) 19(6):805–6. Epub 20141020. doi: 10.1002/ejp.605.
314. Hartle M, Bateman L, Vernon SD. Dissecting the Nature of Post-Exertional Malaise. *Fatigue: Biomedicine, Health & Behavior* (2021) 9(1):33–44. doi: 10.1080/21641846.2021.1905415.
315. Committee on the Diagnostic Criteria for Myalgic Encephalomyelitis/Chronic Fatigue S, Board on the Health of Select P, Institute of M. The National Academies Collection: Reports Funded by National Institutes of Health. *Beyond Myalgic Encephalomyelitis/Chronic Fatigue Syndrome: Redefining an Illness*. Washington (DC): National Academies Press (US)
316. Copyright 2015 by the National Academy of Sciences. All rights reserved. (2015).
317. Bragée B, Michos A, Drum B, Fahlgren M, Szulkin R, Bertilson BC. Signs of Intracranial Hypertension, Hypermobility, and Craniocervical Obstructions in Patients with Myalgic Encephalomyelitis/Chronic Fatigue Syndrome. *Front Neurol* (2020) 11:828. Epub 20200828. doi: 10.3389/fneur.2020.00828.
318. Quadt L, Savage G, Bond R, Davies KA, Critchley HD, Eccles JA. Likely Neurodivergence and Variant Connective Tissue in Patients with Chronic Pain/Chronic Fatigue: A Case-Control Study. *J Psychiatr Res* (2026) 197:125–32. Epub 20260218. doi: 10.1016/j.jpsychires.2026.02.036.
319. Ruiz Maya T, Fettig V, Mehta L, Gelb BD, Kontorovich AR. Dysautonomia in Hypermobile Ehlers-Danlos Syndrome and Hypermobility Spectrum Disorders Is Associated with Exercise Intolerance and Cardiac Atrophy. *Am J Med Genet A* (2021) 185(12):3754–61. Epub 20210730. doi: 10.1002/ajmg.a.62446.
320. Ladell AJM, Golden DW, Oliemans JP, Walls KD, Manocha RHK, Fletcher JR. Perceived Quality of Life, Fatigue and the Metabolic Cost of Walking in Generalized Hypermobility Spectrum Disorder and Hypermobile Ehlers-Danlos Syndrome. *Front Rehabil Sci* (2025) 6:1706912. Epub 20251128. doi: 10.3389/fresc.2025.1706912.
321. Rombaut L, Malfait F, De Wandele I, Mahieu N, Thijs Y, Segers P, et al. Muscle-Tendon Tissue Properties in the Hypermobility Type of Ehlers-Danlos Syndrome. *Arthritis Care Res (Hoboken)* (2012) 64(5):766–72. doi: 10.1002/acr.21592.
322. Sheehan DS, Oliemans JP, Golden DW, Walls KD, Bennett EC, Skaper SJ, et al. To What Extent Do the Muscles and Tendons Influence Metabolic Cost and Exercise Tolerance in the Hypermobile Ehlers-Danlos Syndrome and Hypermobility Spectrum Disorders? *Clin Biomech (Bristol)* (2026) 131:106695. Epub 20251113. doi: 10.1016/j.clinbiomech.2025.106695.
323. Haunhorst S, Dudziak D, Scheibenbogen C, Seifert M, Sotzny F, Finke C, et al. Towards an Understanding of Physical Activity-Induced Post-Exertional Malaise: Insights into Microvascular Alterations and

© 2026 by the author(s). Distributed under a Creative Commons CC BY license.

Preprints.org | NOT PEER-REVIEWED | Posted: 24 November 2026 https://doi.org/10.20944/preprints202611.2421.v1

Immunometabolic Interactions in Post-Covid Condition and Myalgic Encephalomyelitis/Chronic Fatigue Syndrome. *Infection* (2025) 53(1):1–13. Epub 20240906. doi: 10.1007/s15010-024-02386-8.

324. Scheibenbogen C, Wirth KJ. Key Pathophysiological Role of Skeletal Muscle Disturbance in Post Covid and Myalgic Encephalomyelitis/Chronic Fatigue Syndrome (Me/Cfs): Accumulated Evidence. *J Cachexia Sarcopenia Muscle* (2025) 16(1):e13669. doi: 10.1002/jcsm.13669.
325. Jason LA, Katz BZ. Predisposing and Precipitating Factors in Epstein-Barr Virus-Caused Myalgic Encephalomyelitis/Chronic Fatigue Syndrome. *Microorganisms* (2025) 13(4). Epub 20250321. doi: 10.3390/microorganisms13040702.
326. Eccles JA, Cadar D, Quadt L, Hakim AJ, Gall N, Bowyer V, et al. Is Joint Hypermobility Linked to Self-Reported Non-Recovery from Covid-19? Case-Control Evidence from the British Covid Symptom Study Biobank. *BMJ Public Health* (2024) 2(1):e000478. Epub 20240220. doi: 10.1136/bmjph-2023-000478.
327. Torok RA, Lubell J, Rudy RM, Eccles J, Quadt L. Variant Connective Tissue as a Risk Factor for Long Covid: A Case-Control Study of Data from a Retrospective Online Survey of Adults in the USA and Uk. *BMJ Public Health* (2025) 3(2):e002949. Epub 20250917. doi: 10.1136/bmjph-2025-002949.
328. Keller B, Receno CN, Franconi CJ, Harenberg S, Stevens J, Mao X, et al. Cardiopulmonary and Metabolic Responses during a 2-Day Cpet in Myalgic Encephalomyelitis/Chronic Fatigue Syndrome: Translating Reduced Oxygen Consumption to Impairment Status to Treatment Considerations. *J Transl Med* (2024) 22(1):627. Epub 20240705. doi: 10.1186/s12967-024-05410-5.
329. Lim EJ, Kang EB, Jang ES, Son CG. The Prospects of the Two-Day Cardiopulmonary Exercise Test (Cpet) in Me/Cfs Patients: A Meta-Analysis. *J Clin Med* (2020) 9(12). Epub 20201214. doi: 10.3390/jcm9124040.
330. Domany KA, Hantragool S, Smith DF, Xu Y, Hossain M, Simakajornboon N. Sleep Disorders and Their Management in Children with Ehlers-Danlos Syndrome Referred to Sleep Clinics. *J Clin Sleep Med* (2018) 14(4):623–9. Epub 20180415. doi: 10.5664/jcsm.7058.
331. Gaisl T, Giunta C, Bratton DJ, Sutherland K, Schlatzer C, Sievi N, et al. Obstructive Sleep Apnoea and Quality of Life in Ehlers-Danlos Syndrome: A Parallel Cohort Study. *Thorax* (2017) 72(8):729–35. Epub 20170110. doi: 10.1136/thoraxjnl-2016-209560.
332. Tinkle B, Castori M, Berglund B, Cohen H, Grahame R, Kazkaz H, et al. Hypermobile Ehlers-Danlos Syndrome (A.K.A. Ehlers-Danlos Syndrome Type Iii and Ehlers-Danlos Syndrome Hypermobility Type): Clinical Description and Natural History. *Am J Med Genet C Semin Med Genet* (2017) 175(1):48–69. Epub 20170201. doi: 10.1002/ajmg.c.31538.
333. Lam CY, Palsson OS, Whitehead WE, Sperber AD, Tornblom H, Simren M, et al. Rome Iv Functional Gastrointestinal Disorders and Health Impairment in Subjects with Hypermobility Spectrum Disorders or Hypermobile Ehlers-Danlos Syndrome. *Clin Gastroenterol Hepatol* (2021) 19(2):277–87.e3. Epub 20200225. doi: 10.1016/j.cgh.2020.02.034.
334. Sedky K, Gaisl T, Bennett DS. Prevalence of Obstructive Sleep Apnea in Joint Hypermobility Syndrome: A Systematic Review and Meta-Analysis. *J Clin Sleep Med* (2019) 15(2):293–9. Epub 20190215. doi: 10.5664/jcsm.7636.
335. Guilleminault C, Primeau M, Chiu HY, Yuen KM, Leger D, Metlaine A. Sleep-Disordered Breathing in Ehlers-Danlos Syndrome: A Genetic Model of Osa. *Chest* (2013) 144(5):1503–11. doi: 10.1378/chest.13-0174.
336. Lau J, Kaelber DC, Otteson TD. Prevalence of Obstructive Sleep Apnea and Related Oropharyngeal Symptoms in Pediatric Ehlers Danlos Patients. *Int J Pediatr Otorhinolaryngol* (2025) 195:112460. Epub 20250630. doi: 10.1016/j.ijporl.2025.112460.
337. Stöberl AS, Gaisl T, Giunta C, Sievi NA, Singer F, Möller A, et al. Obstructive Sleep Apnoea in Children and Adolescents with Ehlers-Danlos Syndrome. *Respiration* (2019) 97(4):284–91. Epub 20181128. doi: 10.1159/000494328.
338. Zhang KL, Wallon R, Laukaitis CM, Davies C. Obstructive Sleep Apnea and Cpap Efficacy in Patients with Hypermobile Ehlers-Danlos Syndrome and Hypermobility Spectrum Disorder: A Case-Control Study. *Sleep Breath* (2026) 30(4). Epub 20260708. doi: 10.1007/s11325-026-03763-3.
339. De Wandele I, Rombaut L, De Backer T, Peersman W, Da Silva H, De Mits S, et al. Orthostatic Intolerance and Fatigue in the Hypermobility Type of Ehlers-Danlos Syndrome. *Rheumatology (Oxford)* (2016) 55(8):1412–20. Epub 20160418. doi: 10.1093/rheumatology/kew032.

© 2026 by the author(s). Distributed under a Creative Commons CC BY license.

Preprints.org | NOT PEER-REVIEWED | Posted: 24 November 2026 https://doi.org/10.20944/preprints202611.2421.v1

340. Mathias CJ, Owens A, Iodice V, Hakim A. Dysautonomia in the Ehlers-Danlos Syndromes and Hypermobility Spectrum Disorders-with a Focus on the Postural Tachycardia Syndrome. *Am J Med Genet C Semin Med Genet* (2021) 187(4):510–9. Epub 20211112. doi: 10.1002/ajmg.c.31951.
341. Crews-Stowe C, Tudini F, Jung MK, Forman J, Riley B, Eton S, et al. Sleep Characteristics in Individuals with Ehlers-Danlos Syndrome. *Med Sci (Basel)* (2025) 13(3). Epub 20250627. doi: 10.3390/medsci13030085.
342. Hertel AK, Jones JT, Lytch A, Cramer E, Schroeder A, Black WR. Prevalence of Psychiatric and Sleep Disorders and Their Impact on Quality of Life in Children with Hypermobile Ehlers-Danlos Syndrome: An Observational Study. *Rheumatol Int* (2025) 45(4):81. Epub 20250325. doi: 10.1007/s00296-025-05836-0.
343. MacKintosh EW, Chen ML, Wenger T, Carlin K, Young L. Risk Factors and Inadequacy of Screening for Sleep-Disordered Breathing in Children with Marfan Syndrome. *Pediatr Cardiol* (2021) 42(3):510–6. Epub 20210104. doi: 10.1007/s00246-020-02508-7.
344. Bucknill E, Quadt L, Dew R, Colasanti A, Muller-Pollard CS, Critchley HD, et al. Embracing Complexity: Connecting Bipolar Affective Disorder, Joint Hypermobility and Neurodivergence. *Br J Psychiatry* (2026):1–9. Epub 20260120. doi: 10.1192/bjp.2025.10483.
345. Bulbena A, Baeza-Velasco C, Bulbena-Cabré A, Pailhez G, Critchley H, Chopra P, et al. Psychiatric and Psychological Aspects in the Ehlers-Danlos Syndromes. *Am J Med Genet C Semin Med Genet* (2017) 175(1):237–45. Epub 20170210. doi: 10.1002/ajmg.c.31544.
346. Casanova EL, Baeza-Velasco C, Buchanan CB, Casanova MF. The Relationship between Autism and Ehlers-Danlos Syndromes/Hypermobility Spectrum Disorders. *J Pers Med* (2020) 10(4). Epub 20201201. doi: 10.3390/jpm10040260.
347. Csecs JLL, Iodice V, Rae CL, Brooke A, Simmons R, Quadt L, et al. Joint Hypermobility Links Neurodivergence to Dysautonomia and Pain. *Front Psychiatry* (2021) 12:786916. Epub 20220202. doi: 10.3389/fpsyt.2021.786916.
348. Sharp HEC, Critchley HD, Eccles JA. Connecting Brain and Body: Transdiagnostic Relevance of Connective Tissue Variants to Neuropsychiatric Symptom Expression. *World J Psychiatry* (2021) 11(10):805–20. Epub 20211019. doi: 10.5498/wjp.v11.i10.805.
349. Chen G, Olver JS, Kanaan RA. Functional Somatic Syndromes and Joint Hypermobility: A Systematic Review and Meta-Analysis. *J Psychosom Res* (2021) 148:110556. Epub 20210624. doi: 10.1016/j.jpsychores.2021.110556.
350. Kennedy M, Loomba K, Ghani H, Riley B. The Psychological Burden Associated with Ehlers-Danlos Syndromes: A Systematic Review. *J Osteopath Med* (2022) 122(8):381–92. Epub 20220414. doi: 10.1515/jom-2021-0267.
351. Cederlöf M, Larsson H, Lichtenstein P, Almqvist C, Serlachius E, Ludvigsson JF. Nationwide Population-Based Cohort Study of Psychiatric Disorders in Individuals with Ehlers-Danlos Syndrome or Hypermobility Syndrome and Their Siblings. *BMC Psychiatry* (2016) 16:207. Epub 20160704. doi: 10.1186/s12888-016-0922-6.
352. Kindgren E, Quiñones Perez A, Knez R. Prevalence of Adhd and Autism Spectrum Disorder in Children with Hypermobility Spectrum Disorders or Hypermobile Ehlers-Danlos Syndrome: A Retrospective Study. *Neuropsychiatr Dis Treat* (2021) 17:379–88. Epub 20210210. doi: 10.2147/ndt.S290494.
353. Bulbena-Cabré A, Baeza-Velasco C, Rosado-Figuerola S, Bulbena A. Updates on the Psychological and Psychiatric Aspects of the Ehlers-Danlos Syndromes and Hypermobility Spectrum Disorders. *Am J Med Genet C Semin Med Genet* (2021) 187(4):482–90. Epub 20211122. doi: 10.1002/ajmg.c.31955.
354. Westerman M, Kafkas A, Parry-Jones A, Strong S, Retzler C, Hallam G. Neurobiological and Neuropsychological Disturbance in Eds. *Front Neurol* (2025) 16:1648702. Epub 20251031. doi: 10.3389/fneur.2025.1648702.
355. Baeza-Velasco C, Vergne J, Poli M, Kalisch L, Calati R. Autism in the Context of Joint Hypermobility, Hypermobility Spectrum Disorders, and Ehlers-Danlos Syndromes: A Systematic Review and Prevalence Meta-Analyses. *Autism* (2025) 29(8):1939–58. Epub 20250327. doi: 10.1177/13623613251328059.
356. Eccles JA, Beacher FD, Gray MA, Jones CL, Minati L, Harrison NA, et al. Brain Structure and Joint Hypermobility: Relevance to the Expression of Psychiatric Symptoms. *Br J Psychiatry* (2012) 200(6):508–9. Epub 20120426. doi: 10.1192/bjp.bp.111.092460.

© 2026 by the author(s). Distributed under a Creative Commons CC BY license.

Preprints.org | NOT PEER-REVIEWED | Posted: 24 November 2026 https://doi.org/10.20944/preprints202611.2421.v1

357. Mallorquí-Bagué N, Garfinkel SN, Engels M, Eccles JA, Pailhez G, Bulbena A, et al. Neuroimaging and Psychophysiological Investigation of the Link between Anxiety, Enhanced Affective Reactivity and Interoception in People with Joint Hypermobility. *Front Psychol* (2014) 5:1162. Epub 20141014. doi: 10.3389/fpsyg.2014.01162.
358. Fletcher EKS, Fischer AL, Manocha RHK. Depressive Symptoms Are Highly Prevalent and Associated with Fatigue and Pain Catastrophizing in the Hypermobility Spectrum Disorders and Hypermobile Ehlers Danlos Syndrome: A Cross-Sectional Study. *Rheumatol Int* (2025) 45(5):128. Epub 20250428. doi: 10.1007/s00296-025-05869-5.
359. Desmedt O, Luminet O, Walentynowicz M, Corneille O. The New Measures of Interoceptive Accuracy: A Systematic Review and Assessment. *Neurosci Biobehav Rev* (2023) 153:105388. Epub 20230912. doi: 10.1016/j.neubiorev.2023.105388.
360. Leone CM, Celletti C, Gaudiano G, Puglisi PA, Fasolino A, Cruccu G, et al. Pain Due to Ehlers-Danlos Syndrome Is Associated with Deficit of the Endogenous Pain Inhibitory Control. *Pain Med* (2020) 21(9):1929–35. doi: 10.1093/pm/pnaa038.
361. Bulbena A, Rosado S, Cabaleiro M, Martinez M, Baeza-Velasco C, Martin LM, et al. Validation of the Neuroconnective Endophenotype Questionnaire (Neq): A New Clinical Tool for Medicine and Psychiatry Resulting from the Contribution of Ehlers-Danlos Syndrome. *Front Med (Lausanne)* (2023) 10:1039223. Epub 20230510. doi: 10.3389/fmed.2023.1039223.
362. Ritelli M, Chiarelli N, Cinquina V, Bertini V, Piantoni S, Caproli A, et al. Bridging the Diagnostic Gap for Hypermobile Ehlers-Danlos Syndrome and Hypermobility Spectrum Disorders: Evidence of a Common Extracellular Matrix Fragmentation Pattern in Patient Plasma as a Potential biomarker. *Am J Med Genet A* (2025) 197(1):e63857. Epub 20240903. doi: 10.1002/ajmg.a.63857.
363. Humphrey JD, Dufresne ER, Schwartz MA. Mechanotransduction and Extracellular Matrix Homeostasis. *Nat Rev Mol Cell Biol* (2014) 15(12):802–12. Epub 20141022. doi: 10.1038/nrm3896.
364. Slater AM, Barclay SJ, Granfar RMS, Pratt RL. Fascia as a Regulatory System in Health and Disease. *Front Neurol* (2024) 15:1458385. Epub 20240807. doi: 10.3389/fneur.2024.1458385.
365. Wang TJ, Stecco A, Hakim AJ, Schleip R. Fascial Pathophysiology in Hypermobility Spectrum Disorders and Hypermobile Ehlers-Danlos Syndrome: A Review of Emerging Evidence. *Int J Mol Sci* (2025) 26(12). Epub 20250611. doi: 10.3390/ijms26125587.
366. Wang TJ, Stecco A. Fascial Thickness and Stiffness in Hypermobile Ehlers-Danlos Syndrome. *Am J Med Genet C Semin Med Genet* (2021) 187(4):446–52. Epub 20211106. doi: 10.1002/ajmg.c.31948.
367. Wang TJ, Stecco A, Schleip R, Stecco C, Pirri C. Change in Gliding Properties of the Iliotibial Tract in Hypermobile Ehlers-Danlos Syndrome. *J Ultrasound* (2023) 26(4):809–13. Epub 20230219. doi: 10.1007/s40477-023-00775-7.
368. Chiarelli N, Zoppi N, Ritelli M, Venturini M, Capitanio D, Gelfi C, et al. Biological Insights in the Pathogenesis of Hypermobile Ehlers-Danlos Syndrome from Proteome Profiling of Patients' Dermal Myofibroblasts. *Biochim Biophys Acta Mol Basis Dis* (2021) 1867(4):166051. Epub 20201228. doi: 10.1016/j.bbadis.2020.166051.
369. Zoppi N, Chiarelli N, Binetti S, Ritelli M, Colombi M. Dermal Fibroblast-to-Myofibroblast Transition Sustained by αvß3 Integrin-Ilk-Snail1/Slug Signaling Is a Common Feature for Hypermobile Ehlers-Danlos Syndrome and Hypermobility Spectrum Disorders. *Biochim Biophys Acta Mol Basis Dis* (2018) 1864(4 Pt A):1010–23. Epub 20180105. doi: 10.1016/j.bbadis.2018.01.005.
370. Vernino S, Bourne KM, Stiles LE, Grubb BP, Fedorowski A, Stewart JM, et al. Postural Orthostatic Tachycardia Syndrome (Pots): State of the Science and Clinical Care from a 2019 National Institutes of Health Expert Consensus Meeting - Part 1. *Auton Neurosci* (2021) 235:102828. Epub 20210605. doi: 10.1016/j.autneu.2021.102828.
371. Hugon-Rodin J, Lebègue G, Becourt S, Hamonet C, Gompel A. Gynecologic Symptoms and the Influence on Reproductive Life in 386 Women with Hypermobility Type Ehlers-Danlos Syndrome: A Cohort Study. *Orphanet J Rare Dis* (2016) 11(1):124. Epub 20160913. doi: 10.1186/s13023-016-0511-2.

© 2026 by the author(s). Distributed under a Creative Commons CC BY license.

Preprints.org | NOT PEER-REVIEWED | Posted: 24 November 2026 https://doi.org/10.20944/preprints202611.2421.v1

Disclaimer/Publisher's Note: The statements, opinions and data contained in all publications are solely those of the individual author(s) and contributor(s) and not of MDPI and/or the editor(s). MDPI and/or the editor(s) disclaim responsibility for any injury to people or property resulting from any ideas, methods, instructions or products referred to in the content.

© 2026 by the author(s). Distributed under a Creative Commons CC BY license.