

Case Report

Not peer-reviewed version

---

# Development of Endosalpingiosis in Patients with a History of Breast Cancer

---

Yuuka Matsumoto , [Takuma Hayashi](#) <sup>\*</sup> , Yasuaki Amano , Kaoru Abiko , Ikuo Konishi

Posted Date: 27 November 2024

doi: 10.20944/preprints202411.2108.v1

Keywords: endosalpingiosis; breast cancer; malignant tumor; benign tumor; cyst; fallopian tube



Preprints.org is a free multidisciplinary platform providing preprint service that is dedicated to making early versions of research outputs permanently available and citable. Preprints posted at Preprints.org appear in Web of Science, Crossref, Google Scholar, Scilit, Europe PMC.

Copyright: This open access article is published under a Creative Commons CC BY 4.0 license, which permit the free download, distribution, and reuse, provided that the author and preprint are cited in any reuse.

Disclaimer/Publisher's Note: The statements, opinions, and data contained in all publications are solely those of the individual author(s) and contributor(s) and not of MDPI and/or the editor(s). MDPI and/or the editor(s) disclaim responsibility for any injury to people or property resulting from any ideas, methods, instructions, or products referred to in the content.

## Case Report

# Development of Endosalpingiosis in Patients with a History of Breast Cancer

Yuuka Matsumoto <sup>1</sup>, Takuma Hayashi <sup>2,3,4,\*</sup>, Yasuaki Amano <sup>1</sup>, Kaoru Abiko <sup>1</sup> and Ikuo Konishi <sup>1,3,5</sup>

<sup>1</sup> Department of Obstetrics and Gynecology, National Hospital Organization Kyoto Medical Center, Kyoto City, Kyoto, Japan

<sup>2</sup> Cancer Medicine, National Hospital Organization Kyoto Medical Center, Kyoto City, Kyoto, Japan

<sup>3</sup> Seeds Development and Research Platform Project, Japan Agency for Medical Research and Development (AMED), Chiyoda-Ku, Tokyo, Japan

<sup>4</sup> Department of Cancer Medicine, National Hospital Organization Kyoto Medical Center, Fushimi-Ku, Kyoto, Kyoto 612-8555, Japan

<sup>5</sup> Kyoto University Graduate School of Medicine, Kyoto City, Kyoto, Japan

\* Correspondence: yoyoyo224@hotmail.com

**Abstract:** Endosalpingiosis occurs in relatively young women. The incidence of endosalpingiosis exceeds that of other diseases affecting female tissues. As endosalpingiosis is a benign tumor, several women with endosalpingiosis are asymptomatic. Endosalpingiosis is a lesion characterized by the presence of ectopic glandular tissues lined with epithelium similar to the tubal-type epithelium. Therefore, the development of endosalpingiosis is frequently incidentally discovered during abdominal surgery for other diseases. A definitive diagnosis of endosalpingiosis is made by pathological diagnosis and pathological findings on the surgically removed tissue. In some cases, glandular structures comprising a single layer of columnar to cuboidal epithelial cells are observed in surgically removed tissues of the uterine body, bilateral peritoneal tissues, omental tissues, and even lymph node tissues. Recently, our medical staff has experienced cases of endosalpingiosis with a history of breast cancer, which rarely has clinically significant consequences. Elucidating the mechanism of endosalpingiosis will facilitate understanding of the origin of primary tumors in the ovaries and peritoneum. Furthermore, to prevent unnecessary additional surgical treatments (e.g., chemotherapy), differentiating endosalpingiosis from ovarian borderline (low-grade) tumors or dissemination of malignant tumors and from endosalpingiosis and primary peritoneal mesothelioma or serous tumors is essential. We here discuss the historical and medical aspects of tubal endometriosis, which was discovered as an intraabdominal mass and incidentally diagnosed.

**Keywords:** endosalpingiosis; breast cancer; malignant tumor; benign tumor; cyst; fallopian tube

## Introduction

The diagnostic procedure for fallopian tube tumors commences with clinical assessment (patient interview), followed by physical examination (external and pelvic) and ultrasonography. The results of these tests will determine the presence or absence of fallopian tube and/or ovarian tumors. Moreover, to a certain extent, these tests allow for the determination of whether the tumor is benign or malignant. The tumor is benign in most cases when ultrasonography reveals a cystic tumor (sac-like structure). A large swollen ovary is called an ovarian tumor. Ovarian tumors are divided into the following two categories: cystic ovarian tumors (ovarian cysts), which are fluid-filled sac-like structures, and solid ovarian tumors, which are growing hard lumps. Approximately 80%–90% of ovarian tumors are ovarian cysts that collect fluid. Ovarian cysts are classified into the following four types: serous cystadenomas, mucinous cystadenomas, mature cystic teratomas, and chocolate cysts [1].

However, malignant or borderline malignant tumors are suspected in cases wherein a mixture of solid (lump tissue) and cystic parts is noted or when the entire tumor is observed to be solid [2]. Magnetic resonance imaging (MRI) or tumor marker measurement is performed when more detailed information is deemed necessary. To avoid unnecessary follow-up treatments (e.g., chemotherapy)

following surgical procedures, the doctor in charge must comprehensively determine from the results of these tests whether the patient's tumor is benign, malignant, or borderline malignant. However, as the accuracy of these tests is limited, a definitive diagnosis is ultimately made on the basis of the results of a surgical histopathological examination using the tumor tissue removed by surgical treatment.

Ultrasonography of a 68-year-old woman with no subjective symptoms revealed a right adnexal tumor measuring 97 × 61 mm consisting of a collection of microcysts. Cervical cancer screening results showed a diagnosis of negative for intraepithelial lesion or malignancy (NILM) [3]. However, at the age of 51, she developed breast cancer and underwent hormone therapy; therefore, our medical staff suspected that she might have developed high-grade serous carcinoma. Furthermore, ultrasonography revealed two left adnexal tumors measuring 8 × 8 and 10 × 9 mm. Conversely, contrast MRI did not reveal any solid areas within the mass, and no findings suggestive of a malignant tumor were observed. However, the tumor was surgically removed owing to its large size. Based on the results of the surgical histopathological examination using the removed tumor tissue, the tumor was diagnosed as endosalpingiosis [4]. Endosalpingiosis is not a malignant tumor; therefore, no additional treatment, including chemotherapy, is necessary. Tumors that develop in the bilateral gynecological appendages are not necessarily malignant tumors. To avoid unnecessary additional treatments (e.g., chemotherapy) following surgical treatment, the differential diagnosis between endosalpingiosis and ovarian borderline (low-grade) tumors or malignant tumor dissemination is essential.

Endosalpingiosis is the presence of glands lined by benign tubal-type epithelium outside the fallopian tube [4,5].

Localization: peritoneum, pelvic or abdominal organs, skin, nerves, and lymph nodes.

Clinical features: It is usually an incidental finding.

Epidemiology: It occurs in approximately 12.5% of women, with a wide age range.

## Materials and Methods

### *MRI*

To determine the presence, size, and location of the patient's mass, contrast-enhanced MRI was performed to localize the patient's mass using MRI equipment (Vantage Centurian: Vantage Galan 3T MRT-3020, Canon Medical Systems, Inc., Ohtawara, Tochigi, Japan).

### *Laparoscopic Surgery*

Pyloric gastrectomy and reconstruction of the remnant stomach and duodenum were performed by laparoscopic surgery using a laparoscope (ENDO EYE FLEX 3D, Olympus Corporation, Shinjuku, Tokyo, Japan) and a surgical device (HICURA, Olympus Corporation, Shinjuku, Tokyo, Japan) for surgically treating the gastric corpus area where the gastric tumor was detected.

### *Histopathological Examination*

A surgical pathologist performed a histopathological analysis of the sections from the formalin-fixed paraffin-embedded resected tissue to assess the gross and histopathological characteristics of the resected specimens.

Using the standard procedure, hematoxylin and eosin staining analyses were performed.

## Case

In April 2024, a 68-year-old woman visited a local hospital for a health checkup. At that time, her attending physician emphasized that she had developed ovarian enlargement. Ultrasonography revealed a right adnexal tumor containing a collection of small cysts measuring 97 × 61 mm and two left adnexal tumors containing a collection of small cysts measuring 8 × 8 and 10 × 9 mm. Contrast-enhanced T1low or T2high MRI revealed a homogeneous tumor mass in the left adnexa and a heterogeneous tumor mass in the right adnexa (Figure 1). Contrast-enhanced MRI did not reveal any solid part within the mass; therefore, no findings suggestive of a malignant tumor development were noted.

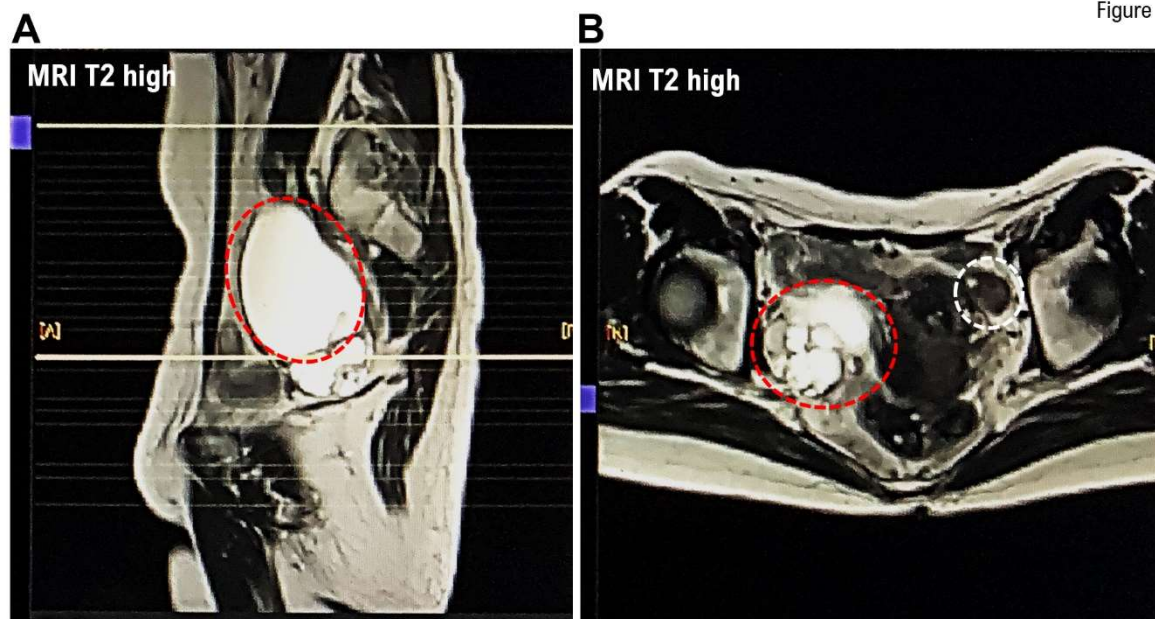


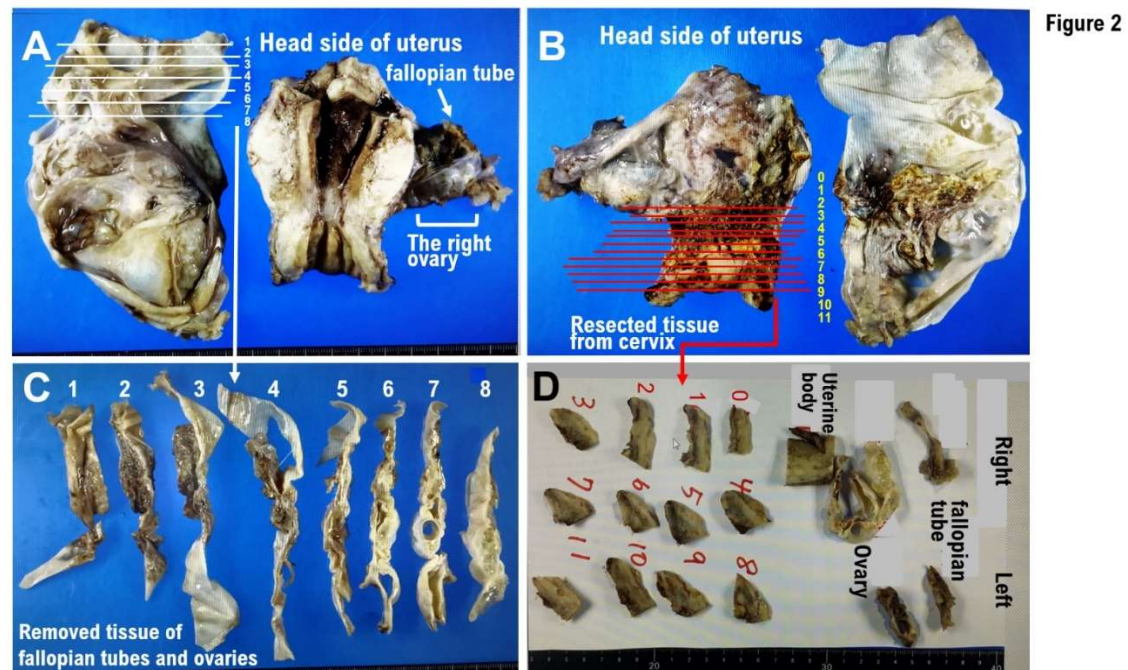
Figure 1

**Figure 1.** Magnetic resonance imaging (MRI) of tumors in the fallopian tubes and ovaries of a patient with a history of breast cancer. A patient who developed breast cancer in her 50s and was undergoing hormone therapy developed fallopian tube and ovarian tumors at approximately 10 years following the initial breast cancer onset. (A) Horizontal cross-sectional image obtained from MRI. (B) Vertical cross-sectional image acquired from MRI. The results reveal a tumor appearing as a multilocular cystic mass in the right ovary. However, some stained glass patterns in the right ovarian tissue without solid areas have also been revealed in the MRI. Several very small cysts are also noted in the left ovary on MRI. The red circle indicates the right ovarian tumor. The white circle indicates the left ovarian tumor.

Her doctor urgently referred her to our medical group for further examination and treatment. Contrast MRI revealed a multilocular cystic mass measuring approximately 70 mm in the short axis in the right ovary, with some stained glass patterns (Figure 1). A homogeneous cluster of tumors was observed in her right ovary; however, no solid area was noted. Contrast-enhanced MRI revealed multiple small cysts and mild induration in the Douglas pouch and a mobile cystic mass that was believed to be a right adnexal mass on the cranial side of the uterine body. Furthermore, contrast-enhanced MRI revealed two small cysts in the left ovary; however, the cysts were not in contact with each other and were not diagnosed as neoplasm. In the uterine corpus, small uterine leiomyomas were observed; however, no endometrial hyperplasia was noted (Figure 1). Therefore, her physician recommended surgical treatment, including laparoscopic total hemodialysis, bilateral salpingo-oophorectomy (BSO), and partial omentectomy.

#### *Histological Findings*

No evidence of mucinous cystadenomas or malignant or borderline malignant lesions was noted in the bilateral ovarian tissues. Leiomyomas, endometrial polyps, ectopic fallopian tube epithelium, and adenomyosis were noted in the uterine body tissue. No squamous intraepithelial lesion (SIL) or malignant findings were observed in the cervical tissue. Ectopic fallopian tube and calcified tissues were observed in the peritoneum of Douglas fossa (Figure 2). Histological examinations revealed no malignant findings.



**Figure 2.** Gross and histopathological morphology of the fallopian tube and ovarian tumors. Tissue specimens from the whole uterus, bilateral salpingo-oophorectomy (BSO), and Douglas fossa peritoneal resection. **(A)** Gross findings of the excised tissues fixed in formalin. Gross histology revealing a massively enlarged right ovary. A photograph showing an enlarged right fallopian tube. A small white uterine leiomyoma is observed in the uterus. No endometrial thickening is noted. **(B)** A photograph showing the tissue specimens from the whole uterus, BSO, and Douglas fossa peritoneal resection photographed from the back. **(C)** The fallopian tube and ovarian tissues shown in panel A are excised horizontally, which are subsequently further excised horizontally into eight tissue sections, each of which is then prepared as a specimen. **(D)** The patient requires a diagnosis by surgical pathology examination of the surgically removed cervical tissues owing to her history of cervical intraepithelial neoplasia. The cervical tissue shown in panel B is excised horizontally, which is subsequently further excised horizontally into 12 tissue sections, each of which is then prepared as a specimen.

#### Histopathological examination

Clinical diagnosis: ovarian tumor and cervical dysplasia

Clinical course:

Suspected right ovarian mucinous adenoma (benign~border)

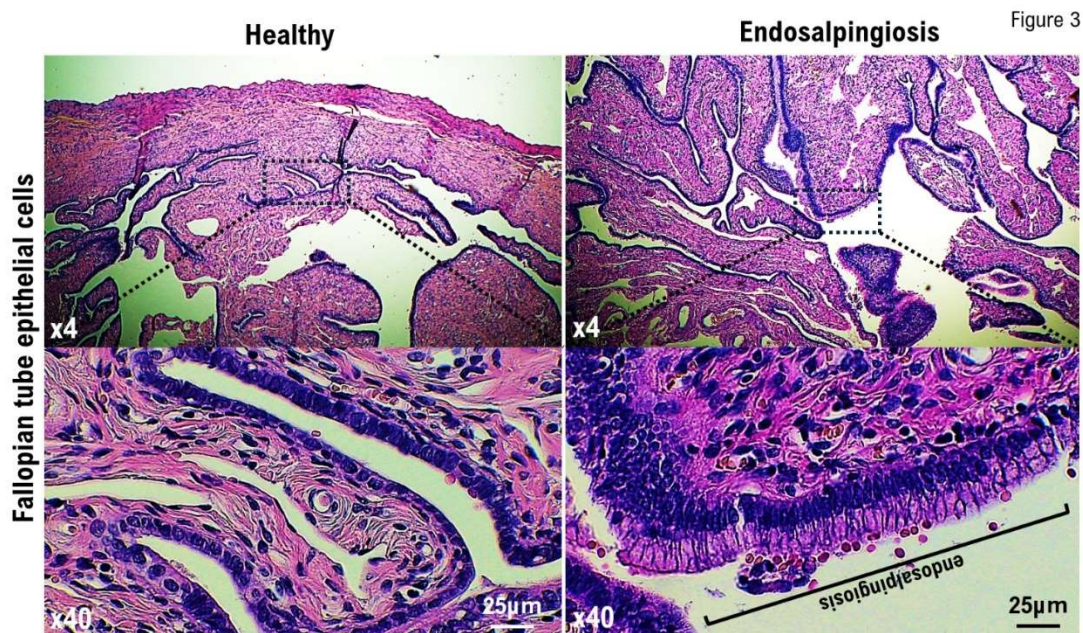
left ovarian cyst

History of cervical intraepithelial neoplasia (CIN) (details unknown, 2024/4: NILM). Laparoscopic total hysterectomy and BSO were performed owing to bilateral ovarian tumors and a history of CIN. The right ovary measured 9 cm in size and was multilocular.

#### Pathology findings

The specimens included total hysterectomy tissue specimen, bilateral adnexal specimen, and Douglas fossa peritoneal resection specimen. The ovaries and fallopian tubes were divided into eight sections, and all tissue blocks were used as specimens (Figure 2A,C). In the right ovary, a multilocular cystic lesion containing mucus was noted (Figure 2C) and no solid areas were observed. The tissue containing the lesion site was used as a specimen. The cervix was divided into 12 sections, and all tissue blocks were used as specimens (Figure 2B,D). A 12-mm cyst was observed in the left ovarian tissue. The uterine corpus had a leiomyomatous nodule and an endometrial polyp.

Pathological diagnosis (Figure 3)



**Figure 3. Endosalpingiosis development within the right fallopian tube as revealed by histopathological examination. (A)** A photograph showing the fallopian tube tissue obtained from the healthy donor. The normal architecture of age-appropriate tubal tissue is observed in the fallopian tubes obtained from volunteers of the same age as the patients. **(B)** A photograph showing the fallopian tube tissue obtained from the patient. Abnormal architecture of not age-appropriate tubal tissue is observed in the fallopian tubes obtained from the patient. The epithelial cells formed in the patient's fallopian tube form ciliated cuboidal structures. The ciliated cuboidal epithelium lines both the fallopian tubes and cysts that develop in endosalpingiosis. The epithelial cells formed in the patient's fallopian tube form ciliated cuboidal structures. The ciliated cuboidal epithelium lines both the fallopian tubes and cysts that develop in endosalpingiosis.

Ovary and fallopian tube, bilateral, salpingo-oophorectomy:

- mucinous cystadenoma (bilateral ovaries)

Uterine corpus, hysterectomy:

- leiomyoma, endometrial polyp, endosalpingiosis, and adenomyosis

Uterine cervix, hysterectomy:

- no evidence of SIL

Peritoneum of Douglas fossa, excision:

- endosalpingiosis

## Discussion

In recent years, as an individualized medicine, cancer treatment using antitumor agents selected on the basis of cancer gene panel testing results has been actively implemented in several countries for patients with advanced or metastatic cancer [6]. Individuals with pathogenic variants (PVs) (pathogenic mutations and/or gene amplifications) in the *germline breast cancer susceptibility gene 1 (BRCA1) gene* or *gBRCA2 gene* are prone to developing early onset breast cancer in their 30s [7,8]. Those with *gBRCA1* PVs and/or *gBRCA2* PVs are prone to developing high-grade serous ovarian cancer within 10 years of the first breast cancer onset. Therefore, BRACAnalysis diagnostic system testing (Myriad Genetics, Inc., Salt Lake City, UT, USA) was performed on the patient, and the results showed no *gBRCA1* PVs and/or *gBRCA2* PVs. Hormone treatment administered for breast cancer sparing can increase the incidence of gynecological malignancies, including ovarian and/or fallopian tube cancers [9]. The patient was undergoing hormone treatment for breast cancer sparing. Therefore, we suspected the development of fallopian tube and ovarian cancers induced by hormone treatment for breast cancer preservation. Ultimately, following a histopathological examination, her ovarian tumor was diagnosed as endosalpingiosis.

The etiology of endosalpingiosis is believed to be due to the coelomic metaplasia theory, in which tissues derived from the Mullerian duct invade and proliferate within the coelomic epithelium during development, and the transplantation theory, in which shed tissues reflux into the peritoneal cavity [10,11]. Surgical treatments, including tubal ligation and salpingectomy, as well as chronic pelvic inflammatory diseases, including salpingitis, are believed to be triggers for endosalpingitis. Furthermore, although the clinical significance of endosalpingiosis remains unclear, endosalpingiosis frequently occurs in cases of low-grade serous ovarian cancer and borderline tumors [12]. It is believed that the fallopian tube epithelium is the most likely source of high-grade serous ovarian cancer [13]. However, as the mechanism of development of low-grade serous ovarian cancer remains unknown, research into the relationship between endosalpingiosis and serous ovarian cancer has been ongoing based on the abovementioned reports. In the present case, our medical staff employed a 4K camera to demonstrate that the white lesion approximately 3 mm in size with a 1-mm transparent cyst formation in the center, located in the postmenopausal Douglas cavity peritoneum, was endosalpingiosis.

## Conclusions

Tumors arising in the bilateral gynecological appendages are not necessarily malignant. The differential diagnosis between endosalpingiosis and ovarian borderline (low-grade) tumors or malignant tumor dissemination is significant to avoid unnecessary additional treatments, including chemotherapy, following surgical treatment.

**Author Contributions:** All authors had full access to the data in the study and take responsibility for the integrity of the data and accuracy of the data analysis. Y.M. Y.A. and K.A. performed the recommendation operations (TLH, BSO, pOM). Conceptualization, T.H. and I.K.; writing—original draft, T.H. and I.K.; writing—review & editing, I.K.; visualization, T.H. and I.K.; supervision, T.H. and I.K.; funding acquisition, T.H. and I.K. All authors have read and agreed to the published version of the manuscript.

**Funding:** This clinical research was performed with research funding from the following: Japan Society for Promoting Science for T.H. (Grant No. 19K09840), START-program Japan Science and Technology Agency for T.H. (Grant No. STSC20001), and the National Hospital Organization Multicenter clinical study for T.H. (Grant No. 2019-Cancer in general-02), and The Japan Agency for Medical Research and Development (AMED) (Grant No. 22ym0126802j0001), Tokyo, Japan.

**Institutional Review Board Statement:** This study was reviewed and approved by the Central Ethics Review Board of the National Hospital Organization Headquarters in Japan (Tokyo, Japan) on 8 November 2019, and Kyoto University School of Medicine (Kyoto, Japan) on 17 August 2019, with approval codes NHO H31-02 and M192. The completion numbers for the authors are AP0000151756, AP0000151757, AP0000151769, and AP000351128. As this research was considered clinical research, consent to participate was required. After briefing regarding the clinical study and approval of the research contents, the participants signed an informed consent form.

**Informed Consent Statement:** A multi-center retrospective observational clinical study of subjects who underwent cancer genomic medicine at a cancer medical facility in Kyoto, Japan. This study was reviewed and approved by the Central Ethics Review Board of the National Hospital Organization Headquarter in Japan (Tokyo, Japan) on 18 November 2020, and Kyoto University School of Medicine (Kyoto, Japan) on 24 August 2022, with approval codes NHO R4-04 and M237. All participants agreed to take part in the present study. We have obtained Informed Consent Statements from people participating in clinical studies.

**Data Availability Statement:** Data available on request due to restrictions eg privacy or ethical The data presented in this study are available on request from the corresponding author.

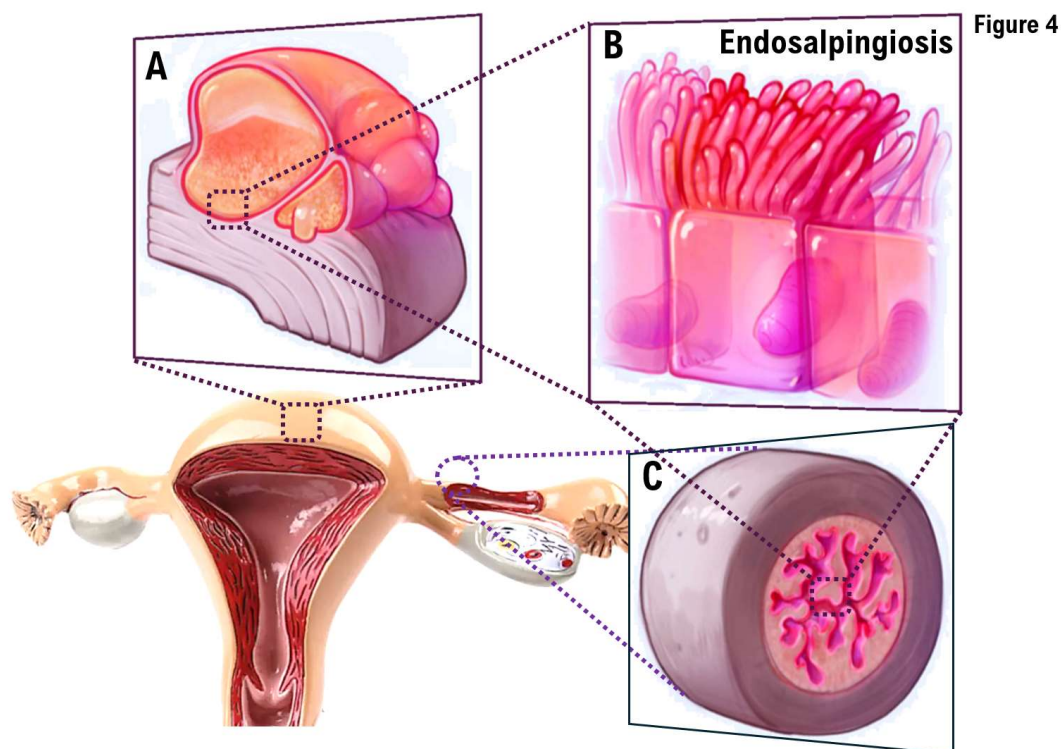
**Acknowledgments:** We thank all medical staff for clinical research at Kyoto University Hospital and the National Hospital Organization Kyoto Medical Center.

**Conflicts of Interest:** The authors declare no conflict of interest.

## References

1. Matalliotakis M, Matalliotaki C, Tsakiridis I, Dagklis T, Michos G, Romanos A, Krithinakis K, Kalogiannidis IA. Co-existence of Ovarian Teratomas With Other Gynecological Tumors. *Cureus*. 2024 Apr 11;16(4):e58068. doi: 10.7759/cureus.58068.

2. Chui MH, Song Q, Zhu J, Jiao Y, Wang B, Wang Y, Wang TL, Vang R, Shih IM. Early Genetic Divergence of High-Grade Carcinomas Originating from Low-Grade Serous Ovarian Neoplasms. *Mod Pathol*. 2024 Oct 9;38(1):100629. doi: 10.1016/j.modpat.2024.100629.
3. Cui X, Yang D, Zhang J, Zhao Y, Cui Z, Wang C, Qiao Y. Clinical value of optical coherence tomography in the early diagnosis of cervical cancer and precancerous lesions: a cross-sectional study. *Front Oncol*. 2024 Jul 29;14:1423128. doi: 10.3389/fonc.2024.1423128.
4. Shapiro S, Abdulkhak A, Lenczowski J, Sayeed S, Mochel M.J Cutaneous endosalpingiosis arising from C-section scar: A case report with review of literature. *Cutan Pathol*. 2023 Apr;50(4):310-315. doi: 10.1111/cup.14335.
5. Chui MH, Shih IM. Oncogenic BRAF and KRAS mutations in endosalpingiosis. *J Pathol*. 2020 Feb;250(2):148-158. doi: 10.1002/path.5353.
6. Grellety T, Lucchesi C, Hostein I, Auzanneau C, Khalifa E, Soubeyran I, Italiano A. High-depth sequencing of paired primary and metastatic tumours: Implications for personalised medicine. *Eur J Cancer*. 2017 Oct;84:250-256. doi: 10.1016/j.ejca.2017.07.019.
7. Zhang Z, Ye S, Bernhardt SM, Nelson HD, Velie EM, Borges VF, Woodward ER, Evans DGR, Schedin PJ. Postpartum Breast Cancer and Survival in Women With Germline BRCA Pathogenic Variants. *JAMA Netw Open*. 2024 Apr 1;7(4):e247421. doi: 10.1001/jamanetworkopen.2024.7421.
8. Yerushalmi R, Pomerantz A, Lewin R, Paluch-Shimon S, Soussan-Gutman L, Baehner FL, Voet H, Bareket-Samish A, Kedar I, Goldberg Y, Peretz-Yablonski T, Kadouri L. BRCA1/2 mutation carriers vs the general breast cancer population (N = 799,986): 21-gene assay-based molecular characterization. *Breast Cancer Res Treat*. 2024 Jul;206(1):67-76. doi: 10.1007/s10549-024-07271-4.
9. Kuo DY, Jones J, Fields AL, Runowicz CD, Goldberg GL. Endometrioid adenocarcinoma of the ovary and long-term tamoxifen therapy: a coincidence or a cause for concern? *Eur J Gynaecol Oncol*. 1997;18(6):457-60.
10. Yiğit S, Dere Y, Yetimlar H, Ett D. Tumor-like cystic endosalpingiosis in the myometrium: a case report and a review of the literature. *Turk Patoloji Derg*. 2014;30(2):145-8. doi: 10.5146/tjpath.2013.01176.
11. Shield P. Peritoneal washing cytology. *Cytopathology*. 2004 Jun;15(3):131-41. doi: 10.1111/j.1365-2303.2004.00140.x.
12. Sunde J, Wasickanin M, Katz TA, Wickersham EL, Steed DOE, Simper N. Prevalence of endosalpingiosis and other benign gynecologic lesions. *PLOS ONE*, 2020 ; 13 ; 15 : e0232487 .
13. Lisio MA, Fu L, Goyeneche A, Gao ZH, Telleria C. High-Grade Serous Ovarian Cancer: Basic Sciences, Clinical and Therapeutic Standpoints. *Int. J. Mol. Sci*. 2019 ; 20 : 952.



**Figure 4.** Illustrations of endosalpingiosis. A photograph illustrating endosalpingiosis. **(B)** Ciliated cuboidal epithelium lining the fallopian tubes and cysts that develop in endosalpingiosis. **(C)** A photograph showing endosalpingiosis in the fallopian tube.

**Disclaimer/Publisher's Note:** The statements, opinions and data contained in all publications are solely those of the individual author(s) and contributor(s) and not of MDPI and/or the editor(s). MDPI and/or the editor(s) disclaim responsibility for any injury to people or property resulting from any ideas, methods, instructions or products referred to in the content.