

Review

Not peer-reviewed version

---

# Key Points in Prostate Cancer Diagnosis

---

[Antonella A Chesca](#) \*

Posted Date: 9 July 2024

doi: 10.20944/preprints202401.1977.v4

Keywords: prostate; functionality; enzymatic activity; cancer; diagnosis



Preprints.org is a free multidiscipline platform providing preprint service that is dedicated to making early versions of research outputs permanently available and citable. Preprints posted at Preprints.org appear in Web of Science, Crossref, Google Scholar, Scilit, Europe PMC.

Copyright: This is an open access article distributed under the Creative Commons Attribution License which permits unrestricted use, distribution, and reproduction in any medium, provided the original work is properly cited.

Review

# Key Points in Prostate Cancer Diagnosis

Antonella Chesca

Transilvania University of Brasov, Romania; anto.chesca@gmail.com or antonella.chesca@unitbv.ro

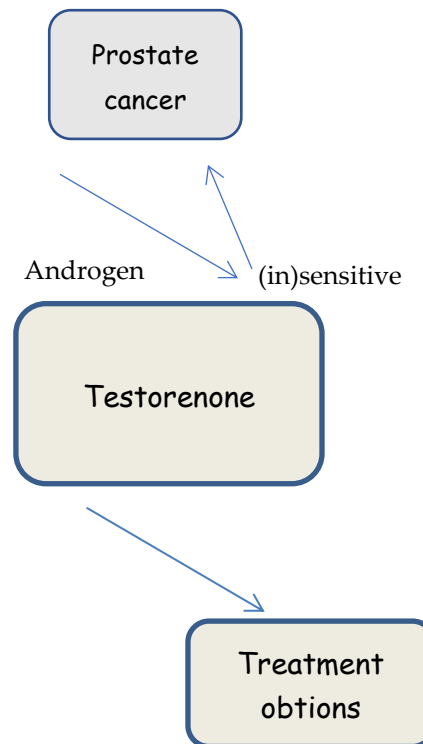
**Abstract:** Our target point within this following steps, is prostate cancer. Prostate cancer is classified structurally, by its Gleason Score. Phosphatases are implicated in different cell alterations, including proliferation, differentiation and carcinogenesis. In specific life circumstances, proteins are regulators with implications in intracellular signaling pathways. Alterations in phosphatases functionality represent a key point in malignancy development. We try within our description, to focus on an important process referring to dysregulation of phosphatase activity. More than, we will discuss therapeutic key points referring to compounds that inhibits phosphatase proteins with implications in carcinogenesis. Researchers try to investigate and to conclude on prostate cancer using also genomic analyses, clinically useful biomarkers and imaging methods. So finally after following description steps, purposed aim is to conclude on prostate cancer and different key points abordation.

**Keywords:** prostate; functionality; enzymatic activity; cancer; diagnosis

---

## 1. Introduction

Prostate cancer (PC) is not only the most common solid cancer, but also the second most common cause of cancer-related death in men. Prostate cancer is one of the malignancies that affects men and significantly contributes to increased mortality rates in men globally. When prostate cancer is suspected, tissue biopsy remains the standard of care for diagnosis. Advances in the diagnosis and treatment of prostate cancer have improved the ability to stratify patients by risk and allowed clinicians to recommend therapy based on cancer prognosis and patient preference. The management of prostate cancer continues to evolve rapidly, with substantial advances being made in understanding. Many prostate cancers are detected on the basis of elevated plasmatic levels of prostate-specific antigen (PSA > 4 ng/mL), a glycoprotein normally expressed by prostate tissue. Diet and physical activity play an important role in prostate cancer development and progression. [1-5]. Fortunately, most prostate cancers tend to grow slowly and are low-grade with relatively low risk and limited aggressiveness. When the cancer is limited to the prostate, it is considered localized and potentially curable. There are no initial or early symptoms in most cases, but late symptoms may include fatigue due to anemia, bone pain, paralysis from spinal metastases, and renal failure from bilateral ureteral obstruction.[Figure 1].



**Figure 1.** Prostate cancer, from etiology to possible options for treatment.

## 2. Key Points in Diagnosis and Prostatic Cancer Management

Diagnosis is primarily based on prostate-specific antigen (PSA) testing and transrectal ultrasound-guided (TRUS) prostate tissue biopsies, although PSA testing for screening remains controversial.

Newer diagnostic modalities include free and total PSA levels, PCA3 urine testing, The worldwide variations in prostate cancer incidence might be attributed to PSA testing. [6]

According to recently conducted research studies, around 20-40% of the prostate cancer cases in the USA and Europe could be due to overdiagnosis through extensive PSA testing.[7-9]

Prostate Health Index scoring (PHI), the“4K” test, exosome testing, genomic analysis, MRI imaging, PIRADS scoring, and MRI-TRUS fusion guided biopsies.

Temporal trends of prostate cancer incidence and mortality varied significantly internationally during the past years, and they seem tightly correlated to the adoption of PSA testing for early detection of the disease especially in Western countries. [10] Although the reasons are not clear, it may reflect both early detection and improved treatment. [11-13] In recent years, the development of novel genetic technologies allowed for the first time a comprehensive analysis of genetic and epigenetic changes in human prostate cancer. classical prognostic factors such as PSA testing, Gleason score and clinical cancer staging have demonstrated not to be always sufficient to lead to a clinically relevant cancer diagnosis. This information, combined with targeted functional studies, helped to identify critical signaling pathways that are casually involved in prostate cancer initiation and progression. we are moving toward personalized medicine, oncogenetic testing and biomarker profiling will facilitate the optimal therapeutic intervention based on the alterations observed in single patients. [14] [15]

## 3. Historical Key Points in Prostatic Malignancy

In ancient Greek the masculine term “prostatēs” meant “president” and was exclusively used in a non-medical sense. It was not until the Renaissance that anatomists discovered the organ naming it “glandulous body.” In 1600 the French physician du Laurens introduced the metaphoric

denomination “prostatae.” However he and his contemporaries misinterpreted the history of the organ and the term, choose the wrong gender when translating it into Latin, and believed that it designated a double organ. Only in the 1800s was this anatomical error corrected while the grammatical one lived on.

The history of radical prostatectomy was initially characterised by the problems in approaching this relatively difficult accessible organ. In 1867, Theodor Billroth in Vienna performed the first partial prostatectomy via a perineal access. In 1904, Hugh Hampton Young and William Stewart Halsted at the Johns Hopkins Hospital in Baltimore / USA carried out the first successful extracapsular perineal prostatectomy and opened up a new era. In Germany, Prof. Friedrich Voelcker in Halle in 1924 developed the so-called ischiorectal prostatectomy. Huggins established the androgen-dependence of the prostate in the 1940s. But it was left to Terence Millin to publish in 1945 the first series of retropubic prostatectomies. In 1952, the sacroperineal approach according to Thiermann and the sacral prostatectomy according to were introduced. It was two discoveries of the 1960s that gave impetus for the study of prostate tissue androgens. The first was the radioimmunoassay (RIA), the Nobel-winning achievement of Yalow and Berson, providing for the first time a convenient method to quantify androgens and other hormones in body fluids.

Finally, in 1991 another new era in prostate surgery started with the first laparoscopic prostatectomy. This development peaked in 2011 with the presentation of the laparoscopic DaVinci prostatectomy by Binder.

#### **4. Acid Phosphatase in Prostate Cancer**

An increasing number of recent studies have identified PAP as a significant prognostic factor for patients with intermediate- and high-risk prostate cancer. PAP appears to be particularly valuable in predicting distant failure in higher-risk patients for whom high levels of local control are achieved with aggressive initial local treatment. Prostatic acid phosphatase (PAP) emerged as the world's first clinically useful tumor marker in the 1940s and 1950s. With the introduction of the prostate-specific antigen (PSA) test in the 1980s, which performed significantly better than PAP in terms of screening and monitoring response to treatment, PAP fell into disfavor.

#### **5. Alkaline Phosphatase in Prostate Cancer**

ALP is a fast and readily available biomarker for prostate cancer (PCa), prognosis. High serum alkaline phosphatase (ALP) is significantly associated with poor overall survival (OS) and progression-free survival (PFS) except for cancer-specific survival (CSS) in prostate cancer (PCa), (ALP) is an efficient and convenient biomarker for prostate cancer (PCa), prognosis. Many studies have evaluated the relationship between alkaline phosphatase (ALP) and the prognosis for prostate cancer (PCa). Prostate cancer patients with bone metastases have higher levels of PSA and ALP than those without. The enzyme ALP can physiologically dephosphorylate compounds under alkaline pH environment. [16] We speculate that bone metastatic cancer may also lead to the rising of serum ALP, given that bone is the most common metastatic site of PCa.

#### **6. Prostate Cancer Markers**

Many prostate cancer markers including prostate-specific antigen (PSA), prostate specific membrane antigen (PSMA), prostate acid phosphatase (PAP), and prostate stem cell antigen (PSCA) have been identified so far. [18- 23]

##### *6.1. Prostate Specific Membrane Antigen (PSMA)*

PSMA has known enzymatic activities and acts as a glutamate-preferring carboxypeptidase. [24-26] The use of PSMA as a therapeutic antigenic target for antibodies has recently become more than a hypothetical proposal. Recent studies with an anti-PSMA mAb have used linkages to radionuclides to treat metastatic prostate cancer. [ 27] By using different combinations of anti-PSMA antibodies or antibodies to other previously described targets such as GM2, KSA, Thomsen-Friedenreich antigen,

or others yet to be identified, one could perhaps develop a more powerful and/or more precisely targeted treatment strategy for prostate cancer. [ 28] The PSMA protein has a unique 3-part structure: a 19-amino-acid internal portion, a 24-amino-acid transmembrane portion, and a 707-amino-acid external portion. [ 29] [ 30] The PSMA gene is located on the short arm of chromosome 11 in a region that is not commonly deleted in prostate cancer. [ 31] PSMA does have an internalization signal that allows internalization of the protein on the cell surface into an endosomal compartment. [ 32] Originally developed with a type of prostate cancer cell line known as LNCaP cells, the mAb 7E11 was the first anti-PSMA antibody. It recognizes and binds a PSMA intracellular or cytoplasmic epitope. [ 33] [ 34] Recent anti-PSMA antibodies have identified dimer-specific epitopes on PSMA-expressive tumor cells. [ 35] Studies have consistently demonstrated PSMA expression in all types of prostate tissue and increased PSMA expression in cancer tissue. [36-41]

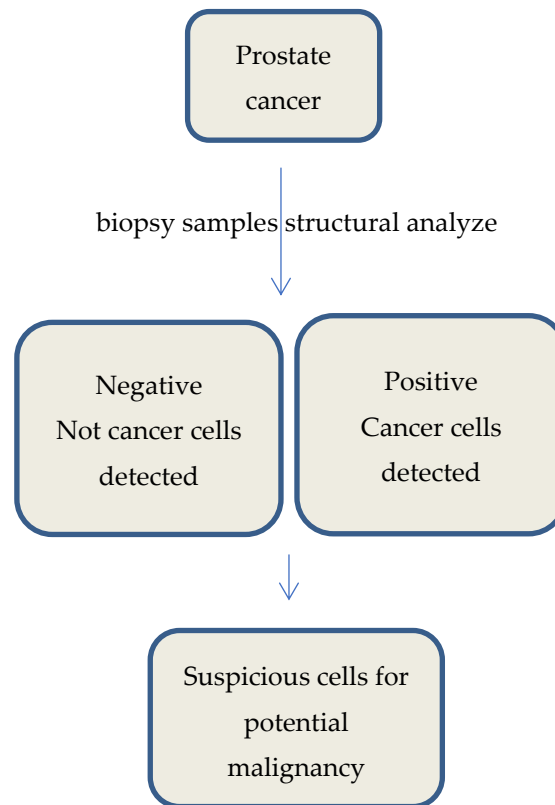
### 6.2. Prostate Acid Phosphatase (PAP)

PAP enzymatic activity occurs when PAP forms a homodimer that consists of two catalytically inactive subunits (50 kDa) bound by non-covalent bonds. [42-43] As the name suggests, PAP shows phosphatase activity in acidic condition (pH 4-6). [44] Human PAP, also known as Acpp or prostatic specific acid phosphatase (PSAP), is a secreted glycoprotein (100 kDa) enzyme (E.C. 3.1.3.2) that is synthesized in the prostate gland's epithelial cells. [45] In human, PAP is one of the major proteins secreted by prostate columnar epithelium secretory cells following puberty. [46] PAP expression is associated with the sex hormone testosterone which determines secondary sexual characteristics. [47] Robust expression of PAP was detected in high Gleason score prostate cancer. [48] The PAP gene is located in chromosome 3q21-23 in humans. The molecular mechanisms underlying PAP gene regulation are not fully understood. However, many *trans*-acting factors including androgen/androgen receptor, NF- $\kappa$ B, TNF- $\alpha$  and IL-1 are involved in the regulation of PAP gene expression. The androgen is an essential factor for human PAP expression. Upstream deletion analysis confirmed that 577bp in -1356/-799 region is *cis*-acting enhancer region. Furthermore, prostate cancer specific PAP expression is increased due to NF- $\kappa$ B binding to AGGTGT motif in -1254/-1249 region that is located in the PAP promoter region. [49] PAP can regulate prostate cell growth in two signaling pathways. Human ErbB-2 (HER-2) can be homodimerized when it is phosphorylated at a tyrosine residue in early developmental stages of prostate cancer. [50] Late stage prostate cancer had a low level of PAP, suggesting a high risk for malignant tumor formation. [51]

### 6.3. Prostate Stem Cell Antigen (PSCA)

The PSCA gene is located on chromosome 8q24.2 and encodes a 123 amino acid cell surface protein with 30% homology to stem cell antigen type 2 (SCA-2), an immature lymphocyte cell surface marker. It is because of this relatively weak homology that PSCA was named inaccurately since it is not a marker for a stem cell population nor is it exclusively expressed in the prostate. Like SCA-2, PSCA is a member of the Thy-1/Ly-6 family of glycosylphosphatidylinositol (GPI) anchored surface proteins. Additionally, a murine PSCA (mPSCA) homologue has been identified with 70% homology to human PSCA at the nucleotide and amino acid levels, which is located on chromosome 15. [52] With any potential immunotherapeutic target it is necessary to assess the normal tissue expression. Ideal targets show overexpression on target cells with limited or no expression on normal tissues, thereby reducing the risk of autoimmunity as a side effect. PSCA messenger RNA (mRNA) expression in normal human tissues was found to be predominantly expressed in prostate. [53] [54] An additional study showed a higher percentage of metastatic prostate cancer cases staining positive for PSCA mRNA compared with nonmalignant prostate disease and organ-confined prostate cancer. [55] Whether overexpression of PSCA in humans is causative of prostate carcinogenesis remains unknown. The PSCA gene was originally identified through an analysis of genes up-regulated in the human prostate cancer LAPC-4 xenograft model. [56] [Figure 2]





**Figure 2.** Types of results after structural analysis for prostate cancer diagnosis.

## 7. Modern Methods for Diagnosis in Prostate Cancer

One of possible causes of prostate malignancy could be gene mutations. In this idea, from studies we know that candidate genes for prostate cancer predisposition are important. So, genes that partake in the androgen pathway and metabolism of testosterone, play a significant role in malignancy developmental status. Structural aspects and particularities, are important in analyse, such as epithelium and cells from prostate particularly modified.[57] The identification of malignancy biomarkers and targeting of specific genetic mutations can be used for a proper treatment in prostate neoplasia. In this idea we can mention that biomarkers which can be used for targeted treatment in prostate cancer, are DNA tumor biomarkers, More than, we can mention that a specific androgen receptor signalling pathway and testosterone play a significant role in prostate malignancy. [58]

From another point of view, artificial intelligence (AI) and machine learning algorithms have nowadays advanced. Following previously mentioned techniques, finally result new classifications in prostate cancer. Actually, the availability of new molecular markers, as well as the introduction of advanced imagistical techniques play a great role in prostate cancer diagnosis. In this idea we can mention, multiparametric magnetic resonance imaging (mpMRI) and prostate-specific membrane antigen positron emission tomography (PSMA-PET) [59]. Knowing the guidelines, we must talk a little bit related to idea that each man at risk of prostate cancer should have an MRI of the prostate practically performed prior obtaining a prostate biopsy [60]. Modern imagistical methods, help in idea to avoid and to minimize complications to lower urinary tract. In prostate cancer hematuria, and temporary erectile dysfunction are affected. [61]. More than, medical routine practice, include techniques such as screening, detection, in prostate cancer (PCa), useful for classification, treatment, and prognosis.

## 8. Discussions

Prostate cancer research in the past decade has made huge stride in the understanding of the disease process and standardization of diagnostic criteria. PAP has a significantly higher correlation

with the morphological characteristics of prostate cancer and can provide a more efficient prognosis than any other markers currently available. Since PAP is a proportional measure of prostate cancer progression, it can also be used in immunotherapy of prostate cancer. More molecular studies on PAP increase in prostate cancer and different forms of PAP including transmembrane PAP are needed to unveil the detailed mechanism of PAP in prostate cancer. Although PAP has been used as a marker of prostate cancer for decades, normal physiological functions of PAP must still be identified. To better understand the diverse roles of PAP *in vivo*, a systematic and integrated approach will be needed. PSCA is a cell surface protein that has been demonstrated to be up-regulated in prostate cancer, along with several other tumors. Because of its limited expression in normal tissues, PSCA has significant potential as a diagnostic, prognostic and therapeutic tool in the management of prostate cancer patients. Animal models that recapitulate human prostatic disease have allowed PSCA to be validated as a therapeutic target in a multitude of approaches and clinical trials have proven the safety of PSCA immunotherapy, thereby giving hope for future successes. With animal models as the foundation, an appropriate vaccination strategy with PSCA as the immune target should be initiated in a human clinical trial. The ultimate goal in prostate cancer research is to discover, design and develop better diagnostic, prognostic and therapeutic options for patients. Imagistical methods are useful in diagnostic and in management of prostate cancer.

## 9. Conclusions

As we know, prostate cancer is one of the most commonly pathology, diagnosed in adult age to mens. Ethiological key point include sexual activity. In prostate cancer, primarily diagnosis include laboratory tests such as prostate-specific antigen (PSA) and imagistical methods such as MRI scans, and prostate tissue biopsies, if needed. Looking forward new trends in management of prostate cancer.

## References

1. Chan JM, Gann PH, Giovannucci EL. Role of diet in prostate cancer development and progression. *J Clin Oncol.* 2005;23(32):8152–8160.
2. Giovannucci E, Rimm EB, Colditz GA, Stampfer MJ, Ascherio A, Chute CG, Willett WC. A prospective study of dietary fat and risk of prostate cancer. *J Natl Cancer Inst.* 1993;85(19):1571–1579. doi: 10.1093/jnci/85.19.1571.
3. Kolonel LN, Nomura AM, Cooney RV. Dietary fat and prostate cancer: current status. *J Natl Cancer Inst.* 1999;91(5):414–428.
4. Platz EA, Leitzmann MF, Michaud DS, Willett WC, Giovannucci E. Interrelation of energy intake, body size, and physical activity with prostate cancer in a large prospective cohort study. *Cancer Res.* 2003;63(23):8542–8548.
5. Willis MS, Wians FH. The role of nutrition in preventing prostate cancer: a review of the proposed mechanism of action of various dietary substances. *Clin Chim Acta.* 2003;330(1-2):57–83.
6. Quinn M, Babb P. Patterns and trends in prostate cancer incidence, survival, prevalence and mortality. Part I: international comparisons. *BJU Int.* 2002;90(2):162–173.
7. Quinn M, Babb P. Patterns and trends in prostate cancer incidence, survival, prevalence and mortality. Part I: international comparisons. *BJU Int.* 2002;90(2):162–173.
8. Draisma G, Etzioni R, Tsodikov A, Mariotto A, Wever E, Gulati R, Feuer E. et al. Lead time and overdiagnosis in prostate-specific antigen screening: importance of methods and context. *J Natl Cancer Inst.* 2009;101(6):374–383.
9. Etzioni R, Penson DF, Legler JM, di Tommaso D, Boer R, Gann PH, Feuer EJ. Overdiagnosis due to prostate-specific antigen screening: lessons from U.S. prostate cancer incidence trends. *J Natl Cancer Inst.* 2002;94(13):981–990.
10. Taitt HE. Global Trends and Prostate Cancer: A review of incidence, detection, and mortality as influenced by race, ethnicity, and geographic location. *Am J Mens Health.* 2018;12(6):1807–1823.
11. Collin SM, Martin RM, Metcalfe C, Gunnell D, Albertsen PC, Neal D, Hamdy F. et al. Prostate-cancer mortality in the USA and UK in 1975–2004: an ecological study. *Lancet Oncol.* 2008;9(5):445–452.
12. Etzioni R, Tsodikov A, Mariotto A, Szabo A, Falcon S, Wegelin J, DiTommaso D. et al. Quantifying the role of PSA screening in the US prostate cancer mortality decline. *Cancer Causes Control.* 2008;19(2):175–181.
13. Lim LS, Sherin K, Committee APP. Screening for prostate cancer in U.S. men ACPM position statement on preventive practice. *Am J Prev Med.* 2008;34(2):164–170.
14. Jorgensen JT. Drug-diagnostics co-development in oncology. *Front Oncol.* 2014;4:208.

15. Olsen D, Jorgensen JT. Companion diagnostics for targeted cancer drugs - clinical and regulatory aspects. *Front Oncol*. 2014;4:105.
16. Sharma U, Pal D, Prasad R. Alkaline phosphatase: an overview. *Indian J Clin Biochem*. 2014;29(3):269–278.
17. Groot MT, Boeken Kruger CG, Pelger RC, Uyl-de Groot CA. Costs of prostate cancer, metastatic to the bone, in The Netherlands. *Eur Urol*. 2003;43(3):226–232.
18. Truong L. D., Kadmon D., McCune B. K., Flanders K. C., Scardino P. T., Thompson T. C. Association of transforming growth factor-beta 1 with prostate cancer: An immunohistochemical study. *Hum. Pathol*. (1993);24:4–9.
19. Hobisch A., Eder I. E., Putz T., Horninger W., Bartsch G., Klocker H., Culig Z. Interleukin-6 regulates prostate-specific protein expression in prostate carcinoma cells by activation of the androgen receptor. *Cancer Res*. (1998);58:4640–4645.
20. Bussemakers M. J., van Bokhoven A., Verhaegh G. W., Smit F. P., Karthaus H. F., Schalken J. A., Debruyne F. M., Ru N., Isaacs W. B. DD3: a new prostate-specific gene, highly overexpressed in prostate cancer. *Cancer Res*. (1999);59:5975–5979.
21. Gupta A., Lotan Y., Ashfaq R., Roehrborn C. G., Raj G. V., Aragaki C. C., Montorsi F., Shariat S. F. Predictive value of the differential expression of the urokinase plasminogen activation axis in radical prostatectomy patients. *Eur. Urol*. (2009);55:1124–1133.
22. Madu C. O., Lu Y. Novel diagnostic biomarkers for prostate cancer. *J. Cancer*. (2010);1:150–177.
23. Batta A., Panag KMD S., Singh J. Diagnosis of prostate cancer --- Role of biomarkers. *Int. J. Cur. Biomed. Phar. Res*. (2012);2:339–345.
24. Pinto JT, Suffoletto BP, Berzin TM, et al. Prostate-specific membrane antigen: a novel folate hydrolase in human prostatic carcinoma cells. *Clin Cancer Res*. 1996;2:1445–1451.
25. Carter RE, Feldman AR, Coyle JT. Prostate-specific membrane antigen is a hydrolase with substrate and pharmacologic characteristics of a neuropeptidase. *Proc Natl Acad Sci USA*. 1996;93:749–753.
26. Halsted CH, Ling EH, Luthi-Carter R, et al. Folylpoly-gamma-glutamate carboxypeptidase from pig jejunum: molecular characterization and relation to glutamate carboxypeptidase II. *J Biol Chem*. 1998;273:20417–20424.
27. Bander NH, Trabulsi EJ, Kostakoglu L, et al. Targeting metastatic prostate cancer with radiolabeled monoclonal antibody J591 to the extracellular domain of prostate specific membrane antigen. *J Urol*. 2003;170:1717–1721.
28. Weijerman PC, Zhang Y, Shen J, et al. Expression of prostatic factors measured by reverse transcription polymerase chain reaction in human papillomavirus type 18 deoxyribonucleic acid immortalized prostate cell lines. *Urology*. 1998;51:657–662.
29. Leek J, Lench N, Maraj B, et al. Prostate-specific membrane antigen: evidence for the existence of a second related human gene. *Br J Cancer*. 1995;72:583–588.
30. Denekamp J, Dasu A, Waites A. Vasculature and microenvironmental gradients: the missing links in novel approaches to cancer therapy? *Adv Enz Regul*. 1998;38:281–299.
31. O'Keefe DS, Su S, Bacich DJ, et al. Mapping, genomic organization and promoter analysis of the human prostate-specific membrane antigen gene. *Biochem Biophys Acta*. 1998;1443:113–127.
32. Rajasekaran SA, Anilkumar G, Oshima E, et al. A novel cytoplasmic tail MXXXL motif mediates the internalization of prostate-specific membrane antigen. *Mol Biol Cell*. 2003;14:4835–4845.
33. Troyer JK, Beckett ML, Wright GL., Jr. Detection and characterization of the prostate-specific membrane antigen (PSMA) in tissue extracts and body fluids. *Int J Cancer*. 1995;62:552–558.
34. Troyer JK, Beckett ML, Wright GL., Jr. Location of prostate-specific membrane antigen in the LNCaP prostate carcinoma cell line. *Prostate*. 1997;30:232–242.
35. Schulke N, Varlamova OA, Donovan GP, et al. The homodimer of prostate-specific membrane antigen is a functional target for cancer therapy. *Proc Natl Acad Sci USA*. 2003;100:12590–12595.
36. Horoszewicz JS, Kawinski E, Murphy GP. Monoclonal antibodies to a new antigenic marker in epithelial cells and serum of prostatic cancer patients. *Anticancer Res*. 1987;7:927–936.
37. Lopes AD, Davis WL, Rosenstraus MJ, et al. Immunohistochemical and pharmacokinetic characterization of the site-specific immunoconjugate CYT-356 derived from antiprostata monoclonal antibody 7E11-C5. *Cancer Res*. 1990;50:6423–6429.
38. Silver DA, Pellicer I, Fair WR, et al. Prostatespecific membrane antigen expression in normal and malignant human tissues. *Clin Cancer Res*. 1997;3:81–85.
39. Troyer JK, Beckett ML, Wright GL., Jr. Detection and characterization of the prostate-specific membrane antigen (PSMA) in tissue extracts and body fluids. *Int J Cancer*. 1995;62:552–558.
40. Chang SS, Reuter VE, Heston WD, Gaudin PB. Comparison of anti-prostate-specific membrane antigen antibodies and other immunomarkers in metastatic prostate carcinoma. *Urology*. 2001;57:1179–1183.
41. Kawakami M, Nakayama J. Enhanced expression of prostate-specific membrane antigen gene in prostate cancer as revealed by in situ hybridization. *Cancer Res*. 1997;57:2321–2324.



42. Kuciel R., Bakalova A., Mazurkiewicz A., Bilska A., Ostrowski W. Is the subunit of prostatic phosphatase active? Reversible denaturation of prostatic acid phosphatase. *Biochem. Int.* (1990);22:329–334.
43. Lee H., Chu T. M., Li S. S., Lee C. L. Homodimer and heterodimer subunits of human prostatic acid phosphatase. *Biochem. J.* (1991);277:759–765.
44. Zelivianski S., Comeau D., Lin M. F. Cloning and analysis of the promoter activity of the human prostatic acid phosphatase gene. *Biochem. Biophys. Res. Commun.* (1998);245:108–112.
45. Vihko P., Kontturi M., Korhonen L. K. Purification of human prostatic acid phosphatase by affinity chromatography and isoelectric focusing. Part I. *Clin. Chem.* (1978);24:466–470.
46. Graddis T. J., McMahan C. J., Tamman J., Page K. J., Trager J. B. Prostatic acid phosphatase expression in human tissues. *Int. J. Clin. Exp. Pathol.* (2011);4:295–306.
47. Goldfarb D. A., Stein B. S., Shamszadeh M., Petersen R. O. Age-related changes in tissue level of prostatic acid phosphatase and prostate specific antigen. *J. Urol.* (1986);136:1266–1269.
48. Gunia S., Koch S., May M., Dietel M., Erbersdobler A. Expression of prostatic acid phosphatase (PSAP) in transurethral resection specimens of the prostate is predictive of histopathologic tumor stage in subsequent radical prostatectomies. *Virchows. Arch.* (2009);454:573–579.
49. Zelivianski S., Glowacki R., Lin M. F. Transcriptional activation of the human prostatic acid phosphatase gene by NF- $\kappa$ B via a novel hexanucleotide-binding site. *Nucleic. Acid. Res.* (2004);32:3566–3580.
50. Lin M. F., Garcia-Arenas R., Xia X. Z., Biela B., Lin F. F. The cellular level of prostatic acid phosphatase and the growth of human prostate carcinoma cells. *Differentiation.* (1994);57:143–149.
51. Merrick G. S., Butler W. M., Wallner K. E., Allen Z., DeFilippo J. L., Adamovich E. Enzymatic prostatic acid phosphatase in the clinical staging of patients diagnosed with prostate cancer. *W. V. Med. J.* (2005);101:116–119.
52. Reiter RE, Gu Z, Watabe T, Thomas G, Szigeti K, Davis E, Wahl M, Nisitani S, Yamashiro J, Le Beau M, Loda M, Witte O. Prostate stem cell antigen: A cell surface marker overexpressed in prostate cancer. *Proc. Natl. Acad. Sci. USA.* 1998;95:1735–1740.
53. Reiter RE, Gu Z, Watabe T, Thomas G, Szigeti K, Davis E, Wahl M, Nisitani S, Yamashiro J, Le Beau M, Loda M, Witte O. Prostate stem cell antigen: A cell surface marker overexpressed in prostate cancer. *Proc. Natl. Acad. Sci. USA.* 1998;95:1735–1740.
54. Cunha AC, Weigle B, Kiessling A, Bachmann M, Rieber EP. Tissue-specificity of prostate specific antigens: comparative analysis of transcript levels in prostate non-prostate tissues. *Cancer Lett.* 2006;236:229–238.
55. Ross S, Spencer S, Holcomb I, Tan C, Hongo J, Devaux B, Rangell L, Keller G, Schow P, Steeves R, Lutz R, Frantz G, Hillan K, Peale F, Tobin P, Eberhard D, Rubin M, Lasky L, Koeppen H. Prostate stem cell antigen as therapy target: tissue expression in vivo efficacy of an immunoconjugate. *Cancer Res.* 2002;62:2546–2553.
56. Reiter RE, Gu Z, Watabe T, Thomas G, Szigeti K, Davis E, Wahl M, Nisitani S, Yamashiro J, Le Beau M, Loda M, Witte O. Prostate stem cell antigen: A cell surface marker overexpressed in prostate cancer. *Proc. Natl. Acad. Sci. USA.* 1998;95:1735–1740.
57. Bluemn E.G., Nelson P.S. The androgen/androgen receptor axis in prostate cancer. *Curr. Opin. Oncol.* 2012;24:251–257. doi: 10.1097/CCO.0b013e32835105b3.
58. Ziaran S., Novakova Z.V., Böhmer D., Danišovič L. Biomarkers for determination prostate cancer: Implication for diagnosis and prognosis. *Neoplasma.* 2015;62:683–691. doi: 10.4149/neo\_2015\_082.
59. Kasivisvanathan V., Rannikko A.S., Borghi M., Panebianco V., Mynderse L.A., Vaarala M.H., Briganti A., Budäus L., Hellewell G., Hindley R.G., et al. MRI-Targeted or Standard Biopsy for Prostate-Cancer Diagnosis. *N. Engl. J. Med.* 2018;378:1767–1777.
60. Albright F., Stephenson R.A., Agarwal N., Teerlink C.C., Lowrance W.T., Farnham J.M., Albright L.A.C. Prostate cancer risk prediction based on complete prostate cancer family history. *Prostate.* 2015;75:390–398.
61. Prando A. Diffusion-weighted MRI of peripheral zone prostate cancer: Comparison of tumor apparent diffusion coefficient with Gleason score and percentage of tumor on core biopsy. *Int. Braz. J. Urol.* 2010;36:504–517.

**Disclaimer/Publisher's Note:** The statements, opinions and data contained in all publications are solely those of the individual author(s) and contributor(s) and not of MDPI and/or the editor(s). MDPI and/or the editor(s) disclaim responsibility for any injury to people or property resulting from any ideas, methods, instructions or products referred to in the content.