Preprints.org

Review

Not peer-reviewed version

Minimally Invasive Surgery and Emerging Technologies in Emergency Abdominal Surgery: A Narrative Review Focusing on Indocyanine Green Fluorescence, Robotic Assistance and Artificial Intelligence

Mihaela Misca *, Iulian Brezean, Giulia Montori, Mauro Podda, Luca Ansaloni, Alberto Arezzo, Andrea Balla, Carlo Bergamini, Chiara Gerardi, Alessio Giordano, Wanda Luisa Rita Petz, Micaela Piccoli, Michelangelo Salemi, Silvio Garattini, Salvador Morales Conde, Ferdinando Agresta *

Posted Date: 10 November 2026

Keywords: minimally invasive surgery; emergency abdominal surgery; indocyanine green; fluorescence-guided surgery; robotic surgery; artificial intelligence

Preprints.org is a free multidisciplinary platform providing preprint service that is dedicated to making early versions of research outputs permanently available and citable. Preprints posted at Preprints.org appear in Web of Science, Crossref, Google Scholar, Scilit, Europe PMC, OpenAlex.

Copyright: This open access article is published under a Creative Commons CC BY 4.0 license, which permit the free download, distribution, and reuse, provided that the author and preprint are cited in any reuse.

Preprints.org | NOT PEER-REVIEWED | Posted: 10 November 2026 https://doi.org/10.20944/preprints202611.0948.v1

Disclaimer/Publisher's Note: The statements, opinions, and data contained in all publications are solely those of the individual author(s) and contributor(s) and not of MDPI and/or the editor(s). MDPI and/or the editor(s) disclaim responsibility for any injury to people or property resulting from any ideas, methods, instructions, or products referred to in the content.

Review

Minimally Invasive Surgery and Emerging Technologies in Emergency Abdominal Surgery: A Narrative Review Focusing on Indocyanine Green Fluorescence, Robotic Assistance and Artificial Intelligence

Mihaela Misca [1], Iulian Brezean [1], Giulia Montori [2], Mauro Podda [3], Luca Ansaloni [4], Alberto Arezzo [5], Andrea Balla [6], Carlo Bergamini [7], Chiara Gerardi [8], Alessio Giordano [7], Wanda Luisa Rita Petz [9], Micaela Piccoli [10], Michelangelo Salemi [11], Silvio Garattini [8], Salvador Morales Conde [6] and Ferdinando Agresta [2,*]

[1] 2nd General Surgery Department, "Dr. I. Cantacuzino" Clinical Hospital, Bucharest, Romania
[2] Unit of General and Emergency Surgery, Vittorio Veneto Hospital, ULSS 2 Marca Trevigiana, Via C. Forlanini 71, 31029 Vittorio Veneto, Italy
[3] Department of Surgical Science, University of Cagliari, Cagliari, Italy
[4] Unit of General Surgery I, Fondazione IRCCS Policlinico San Matteo, University of Pavia, Pavia, Italy
[5] Department of Surgical Sciences, University of Torino, Torino, Italy
[6] Department of General and Digestive Surgery, University Hospital Virgen Macarena, University of Sevilla, Sevilla, Spain
[7] Emergency Surgery Unit, Department of Surgery, Careggi University Hospital, Florence, Italy
[8] Istituto di Ricerche Farmacologiche "Mario Negri" IRCCS, Milan, Italy
[9] General Surgery Department, Gruppo Ospedaliero Moncucco, Locarno, Switzerland
[10] Department of General, Emergency Surgery and New Technologies, Baggiovara General Hospital, 41126 Modena, Italy
[11] Medical Department, Vittorio Veneto Hospital, ULSS 2 Marca Trevigiana, Via C. Forlanini 71, 31029 Vittorio Veneto, Italy
* Correspondence: ferdinandoagresta@gmail.com

Abstract

Minimally invasive surgery (MIS) is progressively transforming emergency abdominal care through high-definition visualization, indocyanine green (ICG) fluorescence imaging, robotic-assisted platforms and the emerging integration of artificial intelligence (AI). This narrative review traces the evolution from conventional laparoscopy to fluorescence-guided, robotic-assisted and AI-supported emergency surgery. Publications were identified in PubMed, EMBASE and Web of Science, prioritizing guidelines, consensus statements, systematic reviews, meta-analyses and recent clinical studies. Current evidence supports a laparoscopic-first approach in hemodynamically stable patients with acute appendicitis, acute calculous cholecystitis, perforated peptic ulcer and selected cases of adhesive small bowel obstruction, strangulated hernia, complicated diverticulitis and penetrating trauma, whereas open laparotomy remains mandatory in hemorrhagic or septic shock. Near-infrared ICG imaging has expanded from elective to emergency practice for biliary anatomy identification, bowel perfusion assessment and anastomotic decision-making, although prospective emergency data remain limited. Robotic systems offer dexterity, ergonomics and integrated imaging, but emergency use is constrained by availability, cost, docking time and team training. AI is being explored for anatomy recognition, risk prediction, augmented reality and autonomous subtasks, with decision support the most realistic near-term role. The value of these technologies depends less on the technology itself than on patient selection, surgical expertise, team preparedness and institutional readiness.

© 2026 by the author(s). Distributed under a Creative Commons CC BY license.

Preprints.org | NOT PEER-REVIEWED | Posted: 10 November 2026 https://doi.org/10.20944/preprints202611.0948.v1

Keywords: minimally invasive surgery; emergency abdominal surgery; indocyanine green; fluorescence-guided surgery; robotic surgery; artificial intelligence

1. Introduction

Emergency abdominal surgery demands rapid and precise intervention in patients with evolving physiological derangement, incomplete diagnostic work-up and little time for preoperative optimization. When clinical stability and operative conditions allow, minimally invasive surgery (MIS) offers a safe alternative to open procedures, aiming to reduce surgical trauma, pain, hospital stay and complications [1]. Although MIS is standard in many elective procedures, its adoption in emergency abdominal surgery remains comparatively limited and strongly dependent on patient stability, surgeon expertise, institutional logistics and equipment availability. Emergency general surgery carries a disproportionate share of perioperative morbidity and mortality compared with elective surgery, particularly in older or physiologically compromised patients [2], and compliance with structured guidelines such as the WSES Bologna recommendations for adhesive small bowel obstruction is associated with shorter length of stay and better outcomes [3].

Beyond the choice of access, contemporary emergency surgery is being reshaped by technologies acting at distinct but interlocking levels of the operative workflow: three-dimensional (3D) reconstruction and, in selected cases, patient-specific 3D printing for planning [4,5]; advanced energy devices for dissection and hemostasis in inflamed or oedematous fields [6,7]; fluorescence-guided imaging with indocyanine green (ICG), augmented reality (AR), robotic instrumentation and computer-aided anatomical recognition for real-time decision-making; and topical hemostatic agents and antifibrinolytic strategies as adjuncts in coagulopathic or anatomically constrained fields [8]. Robotic platforms, including single-port systems, have progressively addressed the limitations of conventional laparoscopy—restricted articulation, two-dimensional vision, tremor amplification and ergonomic strain [9–11].

ICG fluorescence is increasingly integrated into laparoscopic and robotic procedures; meta-analyses have demonstrated its safety and effectiveness in elective surgery, while prospective investigation in acute care is still needed [12–14]. The recent WSES international consensus position paper on ICG fluorescence-guided surgery in the emergency setting is a major step towards standardization of indications, doses and reporting [15]. In parallel, artificial intelligence (AI) is emerging as a complementary tool for intraoperative anatomical recognition, AR overlays, perfusion analysis and autonomous subtasks [16,17], and large language models (LLMs) have broadened the conceptual scope of computational assistance in surgery [18,19]. Systematic reviews suggest a measurable expansion of fluorescence-guided surgery beyond elective cholecystectomy and colorectal resection into trauma, mesenteric pathology and complex hernia repair [20,21], while international surveys confirm that emergency surgeons perceive these technologies as meaningful adjuncts but report persistent heterogeneity in protocols and reporting [22]. Translation of these tools into acute care therefore requires structured training and governance; proctoring, MIS fellowships and formal credentialing have been linked with improved outcomes in both elective and acute settings [23,24].

Against this background, the present review summarizes the current role of MIS and emerging technologies in emergency abdominal surgery, with particular focus on ICG fluorescence, robotic-assisted platforms and AI as the most rapidly evolving domains, and with a shorter account of advanced energy devices, hemostatic agents and 3D reconstruction as complementary technological pillars. Rather than advocating indiscriminate adoption, the review emphasizes a balanced, clinically grounded approach in which innovation is integrated only when it enhances safety, efficiency and decision-making in appropriately selected patients.

© 2026 by the author(s). Distributed under a Creative Commons CC BY license.

Preprints.org | NOT PEER-REVIEWED | Posted: 10 November 2026 https://doi.org/10.20944/preprints202611.0948.v1

2. Materials and Methods

This article was designed as a narrative review and was not conceived as a systematic review or meta-analysis. MEDLINE through PubMed, EMBASE and Web of Science were searched for guidelines, consensus statements, systematic reviews, meta-analyses and clinically relevant studies addressing minimally invasive or technology-assisted approaches in emergency abdominal surgery. Search terms combined "emergency abdominal surgery", "acute care surgery", "minimally invasive surgery", "laparoscopy", "robotic surgery", "single-port robotic surgery", "indocyanine green", "fluorescence-guided surgery", "image-guided surgery", "augmented reality", "three-dimensional reconstruction", "3D printing", "advanced energy devices", "hemostatic agents", "tranexamic acid", "artificial intelligence", "large language models" and "surgical training". The search was limited to English-language publications from 2015 onwards; records were screened on title and abstract, and the reference lists of the most relevant articles were screened manually. Landmark studies predating this window were retained where they provided essential mechanistic or historical context. Evidence is organized as a historical narrative, a condition-focused synthesis and a technology-centred discussion, supported by summary tables and schematic figures.

3. Historical Evolution of Minimally Invasive Emergency Abdominal Surgery

The contemporary landscape of emergency abdominal surgery is the result of nearly five decades of technological evolution in which successive innovations have been layered onto, rather than substituted for, established surgical principles. Five overlapping eras can be identified (Table 1, Figure 1).

The *conventional laparoscopy era* (1980s–1990s) was defined by standard trocars, two-dimensional optics, monopolar electrosurgery and manual knot-tying, initially in elective cholecystectomy and only later in selected emergencies such as appendicitis, perforated ulcer and diagnostic laparoscopy for trauma; outcomes were reported mainly in observational series showing reduced wound morbidity and faster recovery. The *advanced laparoscopic emergency surgery era* (2000s–2010s) was shaped by advanced energy devices, high-definition optics and refined staplers, broadening indications to perforated peptic ulcer, complicated diverticulitis, adhesive small bowel obstruction, strangulated hernias and selected penetrating trauma, with increasingly detailed recommendations from the World Society of Emergency Surgery (WSES) and the European Association for Endoscopic Surgery (EAES) [12,25]; variable access during off-hours activity nonetheless remained a structural limitation [26,27].

The *fluorescence-guided surgery era* (mid-2010s–present) followed the adaptation of ICG imaging, originally developed for ophthalmologic and cardiac angiography, to near-infrared optics on laparoscopic and robotic platforms [25,28,29]. Elective colorectal anastomosis, lymph node mapping and liver segmentectomy served as the testing ground for techniques since translated to difficult cholecystectomy, bowel perfusion assessment in strangulated hernia and mesenteric ischemia, and trauma laparotomy [15,20,30–32]; the WSES consensus position paper marks the formal consolidation of this era [15]. The *robotic-assisted surgery era* (2000s–present, accelerating from 2015) introduced stereoscopic vision, wristed instruments, tremor filtration and ergonomic console operation [33,34], but emergency adoption lagged behind elective use for structural reasons; from around 2015, observational series, national database analyses and systematic reviews began to define robotic roles in emergency cholecystectomy, hernia repair, colorectal surgery and selected trauma [35–37], and single-port platforms further broadened the conceptual envelope [10,11]. The emerging *AI- and image-guided surgery era* (2020s–future) is defined by deep learning for surgical phase and anatomy recognition and risk prediction [38–40], AR overlays of 3D reconstructions, quantitative perfusion analysis and the integration of LLMs into decision-support workflows [18,19,41,42].

These eras coexist as reinforcing layers: a modern emergency cholecystectomy may concurrently rely on laparoscopic access, advanced energy devices, fluorescent cholangiography and, in selected institutions, robotic instrumentation and AI-based safety monitoring.

© 2026 by the author(s). Distributed under a Creative Commons CC BY license.

Preprints.org | NOT PEER-REVIEWED | Posted: 10 November 2026 https://doi.org/10.20944/preprints202611.0948.v1

Table 1. Evolution of minimally invasive emergency abdominal surgery over time.

Era	Approximate period	Defining technologies	Representative emergency applications	Conceptual advances
Conventional laparoscopy	1980s–1990s	Basic 2D laparoscope; monopolar energy; manual sutures; rigid trocars	Diagnostic laparoscopy; laparoscopic appendectomy; selected cholecystectomy	Smaller incisions; reduced wound morbidity; basic insufflation standards
Advanced laparoscopic emergency surgery	2000s–2010s	HD optics; advanced bipolar and ultrasonic devices; modern staplers	Perforated peptic ulcer; complicated diverticulitis; adhesive SBO; strangulated hernias; selected penetrating trauma	Broader emergency indications; safer hemostasis; international guidelines (WSES, EAES)
Fluorescence-guided surgery	Mid-2010s–present	ICG; near-infrared optics integrated on laparoscopic/robotic platforms	Difficult acute cholecystitis; mesenteric ischemia; strangulated hernia; trauma bowel viability; anatomical hepatectomy	Real-time physiological and anatomical visualization; WSES consensus framework
Robotic-assisted surgery	2000s–present (emergency from ~2015)	Multiport platforms; single-port systems; 3D stereoscopic vision; wristed instruments	Robotic cholecystectomy for acute cholecystitis; hiatal hernia; colorectal emergencies; selected hepatobiliary procedures	Improved dexterity, ergonomics and tremor filtration; diversifying platforms
AI- and image-guided surgery	2020s–future	Deep learning for phase/anatomy recognition; AR navigation; 3D reconstruction and printing; LLMs	Intraoperative decision support; risk prediction; navigation overlays; documentation; partial autonomy	Data-integrated operative environments; convergence of imaging, robotics and AI

AI: artificial intelligence; AR: augmented reality; EAES: European Association for Endoscopic Surgery; HD: high-definition; ICG: indocyanine green; LLM: large language model; SBO: small bowel obstruction; WSES: World Society of Emergency Surgery.

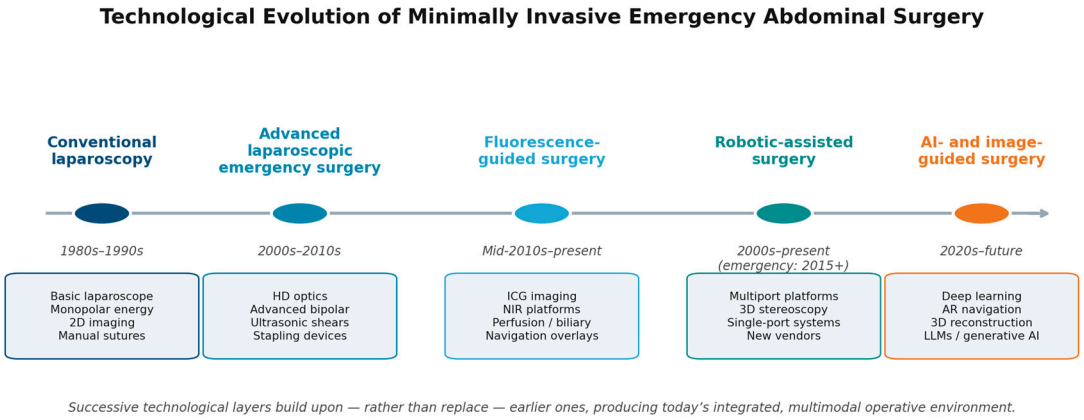

Figure 1. Timeline of the technological evolution from conventional laparoscopy to AI- and image-guided surgery in the management of emergency abdominal conditions.

© 2026 by the author(s). Distributed under a Creative Commons CC BY license.

Preprints.org | NOT PEER-REVIEWED | Posted: 10 November 2026 https://doi.org/10.20944/preprints202611.0948.v1

4. Current Evidence and Patient Selection in Major Emergency Abdominal Conditions

4.1. Patient Selection

Large observational studies and international surveys indicate that fewer than 20% of major emergency operations are approached laparoscopically, despite established benefits for several indications [12,26], and adoption varies even within the same institution according to surgeon expertise and organizational models [26,27]. Selection is primarily dictated by hemodynamic status. The WSES Cesena guidelines recommend laparoscopy as the first approach for stable patients requiring emergency surgery for general surgical emergencies or abdominal trauma, provided that expertise and equipment are available, whereas hemorrhagic or septic shock mandates open laparotomy [1,12]. Established laparoscopic-first indications in stable patients include acute appendicitis, acute calculous cholecystitis, perforated peptic ulcer, adhesive small bowel obstruction, incarcerated or strangulated hernias, selected complicated diverticulitis and penetrating thoraco-abdominal trauma [1,12,26,27,43]; for acute mesenteric ischemia and unstable trauma, open laparotomy remains mandatory [12]. A practical framework should therefore include hemodynamic stability, expected feasibility of adequate visualization, equipment availability, surgeon and team proficiency, anesthesiology support and a low threshold for conversion. Technological availability—fluorescence imaging, energy devices suitable for friable tissue, immediate access to hemostatic agents—has become an additional axis of selection that may modify the threshold for attempting MIS in demanding scenarios, provided that physiological criteria are respected and conversion pathways are predefined [26,27].

Surgical site infection remains a major driver of morbidity after emergency abdominal surgery, with incidences of 15–25% in observational cohorts [44,45]; minimally invasive access is an integral element of infection-prevention bundles. Enhanced recovery after surgery (ERAS) principles have been adapted to emergency laparotomy [46], and randomized trials in perforated duodenal ulcer and emergency small bowel surgery [47,48], scoping reviews in intestinal obstruction [49] and comparative studies in laparoscopic appendectomy and penetrating trauma [50,51] show shorter stay, faster bowel recovery and reduced opioid requirements without increased complications. MIS access, fluorescence and energy technologies and structured ERAS pathways thus define an integrated approach to acute care surgery.

4.2. Condition-Specific Evidence

Acute appendicitis is the most extensively studied indication: meta-analyses of randomized and cohort studies consistently show lower pain, fewer superficial infections, faster return to work and shorter hospitalization with laparoscopic appendectomy, with benefits particularly evident in obese patients and complicated forms treated by trained teams [52]. Robotic appendectomy appears clinically equivalent but longer and costlier, supporting restriction to selected or training contexts.

In *acute calculous cholecystitis*, the ACDC and CHOCOLATE trials established early laparoscopic cholecystectomy over delayed surgery or initial drainage. Robotic and laparoscopic approaches show comparable conversion, bile duct injury and mortality, with longer robotic operative times [53,54]. Fluorescent cholangiography improves identification of biliary anatomy in difficult cases, and randomized data support routine use to enhance safety [30,55–58].

For *perforated peptic ulcer*, meta-analyses and trial sequential analyses of randomized trials show that laparoscopic repair reduces mortality, total complications, ileus and wound complications and lowers early pain scores [59,60]; laparoscopy is the standard minimally invasive technique for stable patients, with open surgery reserved for instability, very large defects or absent expertise.

Adhesive small bowel obstruction is a nuanced indication: in patients with single-band adhesions, limited distension and no peritonitis, a laparoscopic-first strategy shortens stay and accelerates recovery [61], although population-based analyses highlight an increased risk of inadvertent enterotomy and conversion in less favourable cases [62]. Compliance with the WSES Bologna guidelines

© 2026 by the author(s). Distributed under a Creative Commons CC BY license.

Preprints.org | NOT PEER-REVIEWED | Posted: 10 November 2026 https://doi.org/10.20944/preprints202611.0948.v1

improves outcomes [3], and ICG is increasingly investigated to assess bowel viability after adhesiolysis [1,31].

In *strangulated and incarcerated hernias*, MIS is feasible in stable patients, and ICG fluorescence allows objective assessment of bowel viability after reduction, either confirming viability of suspicious segments or unmasking subtle ischemia [63–66]; robotic repair has been described in emergency hiatal and ventral hernia with limited evidence [67]. In *complicated diverticulitis*, the LADIES, SCANDIV and DILALA trials yielded heterogeneous results, with consensus supporting selective laparoscopic lavage in Hinchey III and resection in Hinchey IV; ICG and robotic platforms may refine dissection and anastomotic perfusion assessment [25,35].

In *abdominal trauma*, diagnostic and selective therapeutic laparoscopy in stable penetrating injuries reduces non-therapeutic laparotomies and addresses diaphragmatic and selected visceral injuries [12]; in blunt trauma the role is restricted to stable patients with focal injury. ICG can refine the extent of resection in contused or devascularized bowel [31,32], while robotic platforms are rarely deployed in true trauma laparotomy but may be used in staged surgery and abdominal wall reconstruction [37]. In *hepatobiliary and pancreatic emergencies*, ICG-guided anatomical hepatectomy, 3D planning and, in specialized centres, robotic platforms have been applied to selected urgent scenarios [4,5,14,68–70], with evidence limited to single-centre series.

Taken together, the evidence supports a graduated approach: laparoscopic appendectomy, cholecystectomy and perforated ulcer repair are supported by multiple randomized and meta-analytic studies; laparoscopic management of strangulated hernia, adhesive obstruction and selected diverticulitis by predominantly observational data and selected trials; and robotic and AI-supported approaches by early, largely elective-derived experience (Table 2).

Table 2. Current indications and evidence supporting minimally invasive emergency abdominal procedures.

Indication	Recommended MIS approach	Strength of evidence	Key outcomes versus open surgery
Acute appendicitis	Laparoscopic appendectomy	Multiple RCTs and meta-analyses	Lower SSI; faster recovery; reduced LOS; favourable in obesity and complicated forms
Acute calculous cholecystitis	Laparoscopic cholecystectomy ± ICG cholangiography; robotic in selected centres	Multiple RCTs (ACDC, CHOCOLATE); RCT on ICG; meta-analyses on robotics	Reduced LOS; ICG improves biliary visualization; robotic comparable but longer operative time
Perforated peptic ulcer	Laparoscopic repair with omental patch	RCTs, meta-analyses, trial sequential analysis	Lower mortality, fewer complications, less pain, lower wound morbidity
Adhesive small bowel obstruction	Selective laparoscopy in stable patients with limited distension	Cohort studies; scoping reviews; WSES guidelines	Faster recovery; lower wound morbidity; risk of inadvertent enterotomy
Strangulated/incarcerated hernias	Laparoscopic reduction and repair; ICG for bowel viability	Case series; systematic reviews	Lower wound morbidity; ICG may reduce unnecessary resections
Complicated diverticulitis (Hinchey III)	Selective laparoscopic lavage or resection	RCTs (LADIES, SCANDIV, DILALA); heterogeneous	Case-dependent; resection preferred in fecal peritonitis
Penetrating thoracoabdominal trauma (stable)	Diagnostic/selective therapeutic laparoscopy	Observational and selected prospective series	Fewer non-therapeutic laparotomies; identifies diaphragmatic injuries
Blunt trauma (selected, stable)	Selective laparoscopy	Limited observational data	Feasible in stable patients with focal injuries

© 2026 by the author(s). Distributed under a Creative Commons CC BY license.

Preprints.org | NOT PEER-REVIEWED | Posted: 10 November 2026 https://doi.org/10.20944/preprints202611.0948.v1

Indication	Recommended MIS approach	Strength of evidence	Key outcomes versus open surgery
Acute mesenteric ischemia	Open laparotomy mainly; ICG adjunct	Limited; case series	ICG may refine extent of resection
Ruptured/complicated hepatobiliary disease	Laparoscopic/robotic in selected centres; ICG-guided	Single-centre series; pooled analyses	Feasibility shown; outcomes dependent on expertise

ICG: indocyanine green; LOS: length of stay; MIS: minimally invasive surgery; RCT: randomized controlled trial; SSI: surgical site infection; WSES: World Society of Emergency Surgery.

5. Indocyanine Green Fluorescence-Guided Surgery

5.1. Principles and Platforms

ICG is a water-soluble tricarbocyanine dye that binds plasma or interstitial proteins after intravenous, submucosal or targeted injection and emits near-infrared fluorescence (excitation ~750–800 nm, emission ~800–850 nm) detectable by optics integrated into laparoscopic and robotic platforms [29,71]. Systems such as Firefly on the da Vinci robot overlay fluorescence onto the operative view in real time, allowing identification of bile ducts, vessels, lymphatics and perfusion zones without interrupting workflow [16,28,72]. ICG has rapid hepatic clearance and an excellent safety profile, with sporadic mild hypersensitivity reactions [73]. Dose, timing and route vary substantially across protocols—intravenous boluses from 2.5 mg to 0.25 mg/kg for biliary visualization or perfusion assessment, intracholecystic or submucosal injection for targeted mapping—and this heterogeneity remains a key barrier to comparison between studies and to standardized emergency pathways [74,75]. Modern platforms offer simultaneous white-light and near-infrared visualization, intensity-based colour mapping and real-time perfusion quantification, and NIR-II fluorophores and dual-modality probes, still preclinical, promise greater tissue penetration and tumour-targeted applications [71].

5.2. Anatomical and Physiological Applications

Anatomical applications include mapping of vascular and biliary structures during procedures at risk of injury [20,70]. Physiological assessment centres on tissue perfusion before anastomosis. Pooled analyses of randomized and observational studies in elective colorectal surgery show that ICG perfusion assessment reduces the odds of anastomotic leak, particularly in left-sided and low rectal resections [76,77], and network meta-analyses suggest the protective effect is most pronounced in low and ultra-low anastomoses [78,79]. The phase 3 AVOID trial, which did not confirm earlier observational signals in elective minimally invasive colorectal surgery, has reframed the discussion by emphasizing standardized interpretation and adequately powered patient selection [74]. Translated to acute care, this supports selective integration of perfusion mapping in emergency resections involving compromised pedicles, strangulated bowel or ischemic transitional zones, recognizing that fluorescence does not replace surgical judgement [1,25]. Health technology assessments report improved vessel identification, lymph node detection and tissue discrimination with ICG compared with white light [25], and the technique also has educational value for intraoperative anatomical orientation [80].

5.3. Applications in the Emergency Setting

The most promising emergency applications are bowel perfusion assessment in strangulated hernia, adhesive obstruction, mesenteric ischemia and colorectal obstruction; anastomotic decision-making; and biliary anatomy identification during difficult cholecystectomy [1,15,30,81,82]. A randomized trial of routine ICG during emergency laparoscopic cholecystectomy reported enhanced visualization of extrahepatic biliary anatomy and improved operative safety [30]; prospective cohorts confirm real-time identification of the cystic duct, common hepatic duct and biliary junction even in moderate and severe cholecystitis according to the Tokyo grading [55,56], and a fixed intravenous

© 2026 by the author(s). Distributed under a Creative Commons CC BY license.

Preprints.org | NOT PEER-REVIEWED | Posted: 10 November 2026 https://doi.org/10.20944/preprints202611.0948.v1

dose 12 h before surgery is feasible in urgently admitted patients and supports achievement of the critical view of safety [57]. Narrative reviews of the difficult cholecystectomy reinforce ICG as an aid to reduce conversion and bile duct injury, without replacing meticulous dissection and bailout strategies [58].

In small bowel obstruction, standardized ICG protocols have been proposed to assess viability and guide decision-making [1], and fluorescence-guided adhesiolysis has been described as a feasible adjunct that discriminates bowel from adhesions in real time [81]. In non-occlusive mesenteric ischemia, intraoperative fluorescence helped clarify the extent of bowel involvement [28], and in acute mesenteric ischemia ICG angiography has been reported to reduce extended resections [31]. In strangulated and incarcerated hernias, systematic reviews pooling several hundred patients indicate that ICG angiography may modify decisions on resection extent, with most studies reporting a favourable impact on resection length or reoperation rates, although a minority describe limited specificity and a risk of false reassurance when used in isolation [63]; case series in obturator, umbilical and inguinal hernias document both confirmation of viability and unmasking of ischemia in macroscopically viable segments [64–66]. In blunt and penetrating trauma, fluorescence angiography may define the perfusion boundary of contused bowel and reduce unnecessary enterectomy [31,32,83]; contemporary reviews of ICG in emergency general surgery note that fluorescent cholangiography is the most frequently reported application, while perfusion assessment in mesenteric injury and emergency colorectal resection is the most rapidly expanding domain [21]. Experience with ICG monitoring of colonic perfusion during aortic surgery is conceptually transferable to mesenteric and aortoenteric emergencies [84].

In hepatobiliary emergencies and urgent oncological scenarios, positive and negative staining through portal pedicle puncture under laparoscopic ultrasound guidance or systemic administration allows visualization of Couinaud territories on the surface and along the transection plane, supporting anatomical hepatectomy even with inflammation or impaired function [14,70]. Pediatric emergency surgery is a further setting in which ICG has been adopted with weight-adjusted dosing for complicated appendicitis, retroperitoneal tumours and biliary anomalies [13,72,85], though translation outside specialized centres depends on equipment and training.

The WSES consensus provides a structured framework for indications, doses and reporting across biliary, intestinal, vascular and oncological emergencies [15], but standardization of dose, timing, route, interpretation and reporting remains essential before widespread adoption can be considered evidence-based [15,82]. A key methodological development is the move from qualitative to quantitative interpretation: software extracting time-to-peak, inflow slope and maximum intensity from time–intensity curves, integrated with AI-based region-of-interest selection, may overcome the inter-observer variability that limits binary interpretation in low-flow or transitional zones where resection decisions are most consequential. Open questions include optimal timing relative to clinical stability, validated objective scores and the cost-effectiveness of routine use, all of which require prospective multicentre evaluation (Table 3).

Table 3. Clinical applications of indocyanine green (ICG) fluorescence in emergency abdominal surgery.

Application	Emergency indications	Typical dose/timing	Reported benefits	Limitations
Fluorescent cholangiography	Acute calculous cholecystitis; difficult laparoscopic cholecystectomy	2.5–7.5 mg IV, 30 min to 12 h preop; or intracystic injection	Identifies extrahepatic biliary anatomy; supports critical view of safety; may reduce biliary injury	Severe inflammation may reduce signal; variable timing across studies
Bowel perfusion assessment	Anastomotic decision-making; strangulated hernia;	0.1–0.3 mg/kg IV at the moment of evaluation	Refines transection line; may reduce anastomotic leak and overresection	Subjective interpretation; no standardized thresholds

© 2026 by the author(s). Distributed under a Creative Commons CC BY license.

Preprints.org | NOT PEER-REVIEWED | Posted: 10 November 2026 https://doi.org/10.20944/preprints202611.0948.v1

Application	Emergency indications	Typical dose/timing	Reported benefits	Limitations
	mesenteric ischemia; trauma			
Anatomical hepatectomy (positive/negative staining)	Ruptured HCC; selected urgent oncological resection	Portal pedicle injection (positive) or systemic IV (negative)	Defines Couinaud segments; supports precise parenchymal transection	Requires expertise and intraoperative ultrasound; learning curve
Trauma bowel viability	Blunt/penetrating abdominal injuries	0.1–0.3 mg/kg IV intraoperatively	Avoids unnecessary enterectomy; supports tailored resection	Limited prospective data; field deformation by blood
Fluorescent adhesiolysis	Difficult adhesive small bowel obstruction	Single IV bolus before adhesiolysis	Distinguishes bowel from adhesions in real time	Early experience; limited validation
Lymphatic/nodal mapping	Selected oncologic emergencies; rectal NET	Submucosal or peritumoral injection	Identifies sentinel and lateral nodes	Off-label in emergencies; no consensus protocols
Pediatric emergency surgery	Complicated appendicitis; biliary anomalies; retroperitoneal tumours	Weight-adjusted IV doses	Feasible and safe with weight-adjusted dosing	Restricted to specialized centres; equipment availability

HCC: hepatocellular carcinoma; ICG: indocyanine green; IV: intravenous; NET: neuroendocrine tumour.

6. Robotic-Assisted Surgery in the Emergency Setting

6.1. Current Indications and Outcomes

Robotic cholecystectomy for acute calculous cholecystitis is the most extensively reported indication: systematic reviews and meta-analyses show feasibility and acceptable safety, including in moderate and severe Tokyo grades [35,53,54]. Additional documented indications include incarcerated and strangulated hiatal hernias, ventral and incisional hernias, complicated diverticulitis, acute colorectal pathology and selected upper gastrointestinal emergencies such as perforated peptic ulcer [12,67], and highly selected hepatobiliary and pancreatic emergencies in single-centre experience [35,68]. In trauma, time pressure and incompatibility of docked carts with sudden repositioning restrict robotic platforms to stable scenarios, delayed staged interventions and abdominal wall reconstruction after damage control, although national analyses show steadily increasing case volume and complexity of robotic emergency general surgery in the United States [37].

A comprehensive systematic review of robot-assisted emergency general surgery, pooling thousands of patients across cholecystectomy, hernia repair, colorectal resection and bile duct exploration, reported encouraging length of stay, conversion and major complication rates while highlighting cost and the scarcity of prospective data [35]. A meta-analysis of robotic versus laparoscopic surgery for acute colorectal emergencies suggests comparable or favourable conversion and short-term morbidity in adequately resourced centres, with evidence limited by heterogeneity and observational design [36]. In acute cholecystitis, the largest dedicated meta-analysis found comparable conversion, bile duct injury, intraoperative complications and mortality, with longer robotic operative times reflecting docking and setup [53]; the RLEARN experience in a level 1 trauma centre supports feasibility across grades of severity [54]. Substantial gaps remain: the literature is predominantly observational and from selected high-volume centres; patient selection, severity grading and outcome definitions are heterogeneous; long-term, patient-reported and oncological outcomes are underreported; cost-effectiveness analyses specific to emergency robotics are scarce; and the impact on team performance is largely unexplored.

© 2026 by the author(s). Distributed under a Creative Commons CC BY license.

Preprints.org | NOT PEER-REVIEWED | Posted: 10 November 2026 https://doi.org/10.20944/preprints202611.0948.v1

6.2. Technical Advantages and Limitations

Stereoscopic 3D vision, wristed instruments with seven degrees of freedom, tremor filtration, motion scaling, ergonomic console operation and integration of fluorescence and 3D-reconstruction streams via TilePro-type functions [33,34] are particularly valuable in distorted anatomy, friable tissue, narrow spaces such as the deep pelvis and precise reconstructive maneuvers. Limitations are equally well documented: docking and undocking times, although reduced in newer designs, can compromise responsiveness in deteriorating patients; the absence of robust haptic feedback requires reliance on visual cues in oedematous or contaminated fields; instruments and per-case costs are higher; and physical separation of console surgeon and bedside team modifies communication patterns [24]. In catastrophic intraoperative events, conversion may be slowed by undocking, although streamlined emergency undocking protocols substantially mitigate this risk [86,87].

Single-port platforms such as the da Vinci SP have demonstrated feasibility across colorectal, cholecystectomy, abdominal wall, upper gastrointestinal and liver procedures with fewer incisions and acceptable short-term outcomes [10,11,68,88], but remain largely untested in emergencies because of docking time, limited working space with distended or inflamed bowel and the need for highly specialized teams.

6.3. Learning Curve, Training and Resources

Proficiency milestones for elective robotic procedures are generally reached after 20–50 cases [12], but extensive laparoscopic experience does not consistently accelerate robotic proficiency owing to different ergonomic, haptic and instrument-handling profiles [12,24]. Emergency deployment amplifies training requirements, since the whole team—bedside assistants, scrub staff and anesthesia providers—must be proficient in efficient docking, instrument exchange and rapid undocking [24]. The Japanese Endoscopic Surgical Skill Qualification System exemplifies a credentialing framework associated with measurable outcome improvement [23,24], and simulation environments reproducing intra-abdominal motion may refine emergency-oriented training [89,90].

Capital costs of several million USD per unit, recurrent maintenance, instrument and draping costs and dedicated personnel make per-case costs consistently higher than laparoscopy, even after offsets from shorter stay or fewer complications; cost-effectiveness in routine acute care remains poorly established, and 24-h availability of trained teams is logistically challenging during nights and weekends, when a large proportion of emergencies occur. In low- and middle-income settings these barriers remain a major obstacle, and more affordable platforms are likely to shape the global landscape in the coming decade.

6.4. Future Platforms

The entry of competing modular, table-mounted and specialty-specific systems is diversifying the market and may exert downward pressure on costs, while compact, rapidly deployable systems with integrated emergency undocking protocols are under development [86,87]. Integration with AI-based decision support, fluorescence, 3D reconstruction and AR overlays into unified environments may eventually enable real-time anatomical recognition, automated warnings for critical structures, perfusion quantification and partially autonomous execution of selected subtasks [16,17,41,42,91]. Endoluminal robotic platforms represent a further frontier for upper gastrointestinal hemorrhage, strictures and pancreaticobiliary disease, and should be evaluated through frameworks such as IDEAL [92]. Throughout, technology must augment rather than replace clinical judgement, and adoption should be paced by evidence rather than by competition between vendors (Table 4).

© 2026 by the author(s). Distributed under a Creative Commons CC BY license.

Preprints.org | NOT PEER-REVIEWED | Posted: 10 November 2026 https://doi.org/10.20944/preprints202611.0948.v1

Table 4. Current applications, advantages and limitations of robotic-assisted emergency abdominal surgery.

	Reported outcomes/evidence level	Advantages	Limitations
Acute calculous cholecystitis	Systematic reviews and meta-analyses; comparable to laparoscopy	Stereoscopic 3D vision; wristed dissection in inflamed triangle; ICG cholangiography integration	Longer operative time; cost; docking time
Strangulated and incarcerated hernias	Case series; selected reviews	Articulated instruments in narrow spaces; precise mesh fixation	Limited emergency data; selection bias
Hiatal hernia repair (emergency)	Small series; comparative reports	Precision and ergonomics in deep crural dissection	Time-sensitive cases may favour laparoscopy
Emergency colorectal procedures	Systematic reviews; observational cohorts	Pelvic precision; high-quality anastomosis; ICG integration	Limited prospective data; heterogeneity
Perforated peptic ulcer/upper GI emergencies	Selected series	Articulated suturing; ergonomic console	Most evidence from elective settings
Hepatobiliary and pancreatic emergencies	Highly selective; single-centre reports	Precision dissection; 3D-reconstruction integration	High complexity; specialized expertise required
Trauma laparotomy/staged trauma surgery	Rare; mostly subacute/reconstructive	Reconstructive precision in stable patients	Docking time; unsuitable for hemodynamic instability
Single-port platforms	Scoping reviews; small series	Fewer incisions; overcomes single-incision triangulation issues	Very limited emergency data; complex docking
Integration with AI, AR, fluorescence	Mostly preclinical/early clinical	Real-time decision support; navigation overlays	Not yet validated in emergency

AI: artificial intelligence; AR: augmented reality; GI: gastrointestinal; ICG: indocyanine green.

7. Artificial Intelligence, Image-Guided Navigation and Augmented Reality

7.1. Surgical Phase and Anatomy Recognition

AI is being explored to augment robotic and minimally invasive platforms across screening, diagnosis, intraoperative navigation and autonomous task execution [16,17]. The most mature area is automated surgical phase and instrument recognition on laparoscopic cholecystectomy video: systematic reviews report accuracies of roughly 81–93% for phase recognition and 71–98% for anatomical structure identification, improved by multi-task and ensemble architectures [38,39], with the Cholec80 dataset and EndoNet-type models serving as reference benchmarks and supporting automatic detection of the critical view of safety [40]. Semantic segmentation models trained on annotated colorectal video can highlight connective tissue, autonomic nerves and avascular planes; the Eureka model correctly identified anatomical structures in cases where trainee recognition was uncertain [91]. Although developed in elective contexts, such systems could plausibly support real-time monitoring of operative progression, early warning of deviation from safe milestones and structural recognition in inflamed or distorted emergency fields. Preclinical evaluation of autonomous systems such as the Smart Tissue Autonomous Robot (STAR) shows greater consistency than manual technique for selected subtasks under controlled conditions, but translation to emergency surgery remains speculative and requires rigorous validation, regulatory oversight and clear definitions of surgeon responsibility [16,17].

© 2026 by the author(s). Distributed under a Creative Commons CC BY license.

Preprints.org | NOT PEER-REVIEWED | Posted: 10 November 2026 https://doi.org/10.20944/preprints202611.0948.v1

7.2. Perioperative Risk Prediction

Machine learning models trained on large emergency general surgery cohorts estimate mortality, pneumonia, surgical site infection, thrombosis and prolonged ventilation, with random forest and gradient boosting generally outperforming ASA, APACHE II and the Emergency Surgery Score [93,94]. Disease-specific models have been proposed for bowel obstruction [95] and acute calculous cholecystitis [96]. Multimodal frameworks combining preoperative laboratory data, intraoperative annotations and postoperative monitoring streams predict adverse events such as anastomotic leak and acute kidney injury with improving accuracy as data richness increases [97]. Deployment requires external validation, resilience to dataset shift, interpretability, integration with electronic records and prospective regulatory pathways, together with ethical reflection on responsibility and consent when risk estimates guide decisions in patients lacking capacity [17].

7.3. Image-Guided Navigation and Augmented Reality

Image-guided navigation integrates preoperative volumetric datasets with intraoperative ultrasound, fluoroscopy and computer-vision reconstruction of laparoscopic video to overlay data onto the surgical view [20,98]; hybrid optical-vision tracking [99], Dynamic Shape Instantiation merging preoperative motion models with limited intraoperative imagery [9] and magnetic microsensor navigation for laparoscopic hepatectomy [100] illustrate the field. AR systems, often with head-mounted displays, overlay virtual anatomy and planned trajectories on the operative view, reducing attention shift to external monitors [101,102]. The central challenge in soft-tissue abdominal surgery is organ deformation under respiration, insufflation and manipulation: deformation-tracking pipelines combining probabilistic rigid registration with elastic compensation achieve submillimetric to millimetric accuracy in ex vivo and selected in vivo models [41], and markerless registration frameworks developed in other surgical fields demonstrate technical feasibility without additional intraoperative imaging [42]. Combination of near-infrared fluorescence mapping with AR overlays may maintain spatial accuracy under tissue deformation or poor landmark visibility [103]. Most systems have not been validated in emergency conditions, where blood, oedema and contamination further complicate registration, and surgeons must retain control over how images are fused and displayed so that augmentation supports rather than distracts from judgement.

7.4. Large Language Models and Generative AI

LLMs such as ChatGPT and Gemini have been evaluated for discharge summaries, operative notes, perioperative question-answering, education and decision support [18,19,104]; comparative evaluations in surgical oncology and esophageal surgery suggest contextually appropriate responses, but inconsistency, hallucination and bias remain critical limitations [18,19]. In emergency surgery, potential uses include rapid consultation of guidelines, structured support of multidisciplinary decisions, triage support and standardized documentation, but the absence of regulatory clearance, privacy concerns and the gap between language fluency and clinical reasoning imply that LLMs should be regarded as supplementary tools subordinate to surgeon judgement [18], with rigorous validation, transparency about training data and accountability frameworks required before clinical translation [105,106]. In the near term, the most realistic role of AI in emergency MIS is decision support—anatomy recognition, warnings for critical structures, objective perfusion assessment, prediction of conversion risk, risk stratification and documentation—rather than autonomy [17] (Table 5).

Table 5. Emerging artificial intelligence and image-guided technologies in emergency abdominal surgery.

Technology/application	Emergency-relevant use	Current evidence	Limitations
Surgical phase recognition	Real-time workflow monitoring; safety milestones (critical view of safety)	~81–93% accuracy on benchmark datasets (Cholec80 and others)	Limited validation outside elective cholecystectomy; dataset shift

© 2026 by the author(s). Distributed under a Creative Commons CC BY license.

Preprints.org | NOT PEER-REVIEWED | Posted: 10 November 2026 https://doi.org/10.20944/preprints202611.0948.v1

Technology/application	Emergency-relevant use	Current evidence	Limitations
Anatomical structure recognition	Critical view detection; nerve and vessel identification	~71–98% accuracy on annotated video	Performance degrades with blood, oedema and contamination
Real-time AI navigation in colorectal surgery	Plane and nerve identification	Pilot intraoperative deployment (e.g., Eureka)	Mostly elective; limited emergency validation
Perioperative risk prediction (ML)	Stratification for complications, mortality, AKI	Random forest/gradient boosting outperform ASA/APACHE retrospectively	Lack of external validation; interpretability
Multimodal predictive frameworks	Integration of clinical, intraoperative and physiological data	Narrative review evidence; accuracy grows with data richness	Implementation infrastructure required
ICG perfusion quantification	Bowel viability scoring; anastomotic decision-making	Pilot studies and computational analyses	No consensus thresholds
Augmented reality navigation	Overlay of 3D models in hepatobiliary and pelvic emergencies	Submillimetric to millimetric accuracy in ex vivo/selected in vivo studies	Tissue deformation; registration in emergency
Large language models/generative AI	Decision support; documentation; education	Performance comparable to clinicians in selected Q&A benchmarks	Hallucination; no regulatory clearance; bias
Autonomous surgical subtasks (e.g., STAR)	Anastomosis automation in selected scenarios	Preclinical; consistency exceeding manual in controlled conditions	Not validated for emergency; regulatory and ethical issues
3D reconstruction with virtual reality	Preoperative planning for complex hepatobiliary cases	Increasing adoption in elective and selected urgent cases	Time-intensive; requires expertise

AI: artificial intelligence; AKI: acute kidney injury; APACHE: Acute Physiology and Chronic Health Evaluation; ASA: American Society of Anesthesiologists; ICG: indocyanine green; ML: machine learning; Q&A: question and answer; STAR: Smart Tissue Autonomous Robot.

8. Complementary Technologies: Energy Devices, Hemostatic Agents and 3D Reconstruction

8.1. Advanced Energy and Sealing Devices

Hemostasis and tissue division are the most time-consuming components of emergency operations in which bleeding and inflammation distort anatomy. Monopolar electrosurgery has been complemented by advanced bipolar systems that combine pressure with computer-controlled energy to seal vessels up to 7 mm, ultrasonic shears that coagulate and divide simultaneously with minimal smoke and reduced lateral thermal spread, and integrated bipolar–ultrasonic platforms [7,107,108]. Bench comparisons show that advanced bipolar and integrated devices generally achieve higher burst pressures and more consistent seals than conventional bipolar instruments, with differences in speed, lateral spread and tissue adherence [109,110]. In emergency laparoscopic appendectomy, meta-analyses of clipless–sutureless techniques using ultrasonic or advanced bipolar devices report comparable stump-related morbidity with shorter operative time [6]; randomized comparison of integrated and advanced bipolar devices in laparoscopic left colon surgery shows comparable safety [111], and integrated devices reduce blood loss and operative time in urgent adrenal procedures [112]. Lateral thermal spread, contact with metallic clips, activation in fluid pools and smoke generation remain relevant risks in narrow or distorted spaces, and structured training in safe device

© 2026 by the author(s). Distributed under a Creative Commons CC BY license.

Preprints.org | NOT PEER-REVIEWED | Posted: 10 November 2026 https://doi.org/10.20944/preprints202611.0948.v1

handling is repeatedly emphasized [108]. Energy devices are not a substitute for an exposed dry field, appropriate tissue tension and clear identification of the structure to be sealed; in inflamed, oedematous or coagulopathic fields they must be combined with mechanical and pharmacological hemostasis.

8.2. Topical Hemostatic Agents and Antifibrinolytic Strategies

Topical hemostats are classified as mechanical (oxidized regenerated cellulose, gelatin, collagen), active (thrombin- and fibrin-based) and sealant agents (fibrin glues, polymer sealants, gelatin–thrombin matrices) [113–115]. A GRADE-based systematic review in trauma and emergency surgery concluded that fibrin adhesives are effective in the presence of coagulation disorders, mechanical hemostats are preferable with intact coagulation and sealants control residual oozing across coagulation states, and emphasized that none substitutes for sound surgical technique [114]. Carrier-bound fibrin sealants have been used in emergency liver, pancreatic and biliary surgery for diffuse oozing and biliary leakage with generally encouraging observational results [116]; kaolin-impregnated gauzes developed for prehospital care have been employed for pelvic packing in penetrating injury [117]; and cyanoacrylate glues have been used off-label for inaccessible presacral bleeding and as liquid embolic agents in unstable trauma [118,119]. Sprayable and injectable systems delivered through laparoscopic applicators allow uniform coverage of the gallbladder fossa, liver or splenic capsule and pelvic raw surfaces, and gelatin–thrombin matrices remain in place on dependent surfaces in coagulopathic patients [114,115]. Nanomaterial-based hydrogels, self-assembling peptides and chitosan–clay composites with combined hemostatic and antimicrobial properties are promising but largely preclinical [120,121]. Tranexamic acid reduces perioperative bleeding and transfusion across specialties, including extrahepatic abdominal surgery, without a significant increase in thromboembolic events within recommended doses [8], and should be integrated within damage control resuscitation and viscoelastic-guided correction rather than regarded as a substitute for surgical hemorrhage control. Algorithms that sequence energy-based hemostasis, mechanical control and topical adjuncts may standardize practice and reduce both undertreatment and unnecessary resource use.

8.3. Three-Dimensional Reconstruction, Virtual Planning and 3D Printing

Patient-specific 3D reconstructions from CT and MRI allow interactive simulation of resection planes, vascular ligation and remnant volume, and in hepatobiliary surgery virtual surgical planning has been associated with improved precision, reduced bleeding and fewer bile leaks in selected cohorts [4,69]. Deep learning segmentation based on U-Net architectures rapidly extracts parenchyma, tumours, vessels and biliary tree with high concordance to manual ground truth [122,123], and immersive virtual reality interfaces allow rehearsal of resection planes in three-dimensional space [124]. Patient-specific 3D printing reproduces variable tissue consistency and improves trainees' anatomical comprehension, but production times of roughly 30–35 h restrict its use to semi-urgent scenarios such as complex incisional hernia or planned interval surgery after damage control, although registry data suggest net operating-room time and cost savings in complex cases [5,125]. The greatest clinical value emerges when virtual models are integrated into the intraoperative environment through AR navigation coupled with intraoperative ultrasound and ICG segmental staining [41,42,91]; in emergencies, however, organ mobility, oedema, contamination and bleeding remain significant obstacles to accurate registration.

9. Training, Credentialing, Implementation and Equity

Safe integration of advanced technologies requires structured training and institutional preparedness. Position papers on MIS training emphasize that success in acute situations depends on surgeon expertise, equipment, operating-room organization, anesthesiology support and the competence of the whole team [23,24]; the Japanese qualification system, which initially accredited fewer than half of applicants, was associated with reduced major complications after gastrointestinal

© 2026 by the author(s). Distributed under a Creative Commons CC BY license.

Preprints.org | NOT PEER-REVIEWED | Posted: 10 November 2026 https://doi.org/10.20944/preprints202611.0948.v1

surgery [23,24]. Each technological layer—fluorescence, energy devices, hemostatic biomaterials, robotic and single-port systems, 3D software and AI assistants—entails specific cognitive and procedural skills, so that international position papers now incorporate modules on fluorescence imaging, energy device handling and team-based simulation [23,24], and dedicated simulators are needed for complex biliary MIS [89,90]. Credentialing should be modular and progressive: for ICG, pharmacology, dose, timing, pattern recognition and standardized reporting, extending to perfusion quantification; for robotics, didactic modules, simulation, proctored cases and logbooks; for AI, both technical use and a critical understanding of dataset bias, model drift and automation bias. Institutional readiness encompasses 24-h availability of emergency theatres, trained anesthesia and nursing teams, immediate access to fluorescence-capable platforms and clear conversion pathways, with national audit data showing that subspecialization, dedicated rosters and centralized governance independently influence outcomes [2,23,24].

Cost is a decisive dimension. Robotic platforms carry high acquisition, maintenance and consumable costs that are only partially offset by improved outcomes in high-volume elective practice, and emergency-specific cost-effectiveness analyses are scarce. Fluorescence platforms carry significant capital cost but a low marginal cost per case once infrastructure is in place; 3D printing introduces production and analyst time costs that registry data suggest can be recouped in selected complex cases [5,125]; and hemostatic agents must be selected according to coagulation status and scenario to avoid disproportionate spending [114]. Regulatory frameworks designed for static devices are challenged by adaptive AI systems that change after deployment; narrative reviews stress that innovation, regulation and global equity must be addressed jointly [98], and the IDEAL framework offers structured guidance for progressive evaluation of new procedures and technologies [92]. Patients undergoing emergency surgery are frequently unable to provide fully informed consent, so advanced technologies must be embedded in institutional policies that respect autonomy, involve surrogates and document deviations from standard care, and generative AI raises additional concerns about privacy, hallucination and bias [18,105,106]. Finally, the Lancet Commission on Global Surgery has documented that a large proportion of the world population lacks timely access to safe surgical care [126]; the increasing sophistication of MIS, fluorescence, robotic and AI tools risks widening these gaps unless accompanied by capacity building, affordable training platforms and robust low-maintenance equipment. Evidence from resource-limited settings shows that basic infection prevention bundles, antimicrobial stewardship and low-cost ERAS pathways yield measurable improvements even without high-end technology [44,127].

10. Future Directions

Innovation is converging towards data-integrated operating environments in which intraoperative video, fluorescence signals, robotic kinematics, anesthesia data and laboratory results are streamed to analytic platforms supporting both intraoperative decision-making and quality improvement; interoperability standards, secure storage and governance of data ownership and consent are prerequisites. Within such environments, real-time fusion of 3D models with ultrasound and fluorescence may support navigation in complex hepatobiliary and pelvic emergencies, AI-driven phase analysis may provide intraoperative safety monitoring, and predictive models may inform the choice between damage control and definitive surgery and the planning of postoperative monitoring [97]. Patient-specific factors—frailty, sarcopenia, immune status, microbiome and coagulation profile—are increasingly recognized as outcome determinants, and bedside molecular diagnostics and viscoelastic testing may eventually tailor the choice of energy device, hemostatic agent, prophylaxis and monitoring to the individual patient within a common safety architecture.

Beyond ICG, tumour-targeted molecular probes directed at carcinoembryonic antigen, prostate-specific membrane antigen and folate receptors have entered clinical trials and may eventually be transferred to emergencies such as ruptured or perforated malignancies [128], while dual-modality probes combining fluorescence with PET, SPECT or MR contrast remain confined to specialized centres. Endoluminal robotic platforms, evaluated through the IDEAL framework, may offer less

© 2026 by the author(s). Distributed under a Creative Commons CC BY license.

Preprints.org | NOT PEER-REVIEWED | Posted: 10 November 2026 https://doi.org/10.20944/preprints202611.0948.v1

invasive treatment of upper gastrointestinal hemorrhage, strictures and pancreaticobiliary disease [92], and natural orifice approaches illustrate the potential of combining endoscopic and surgical platforms in selected general and bariatric emergencies [129].

Taken together, these developments define a layered roadmap (Figure 2). At the foundational layer, structured patient selection, perioperative optimization, ERAS pathways and infection-prevention bundles provide the safety architecture; at the intermediate layer, laparoscopy, basic energy devices, topical hemostats and standard imaging remain central; at the advanced layer, ICG fluorescence, robotic platforms, advanced energy and hemostatic technologies, 3D planning and AI-based decision support enable precision interventions in selected scenarios; and at the frontier layer, generative AI, molecular imaging, endoluminal robotics, autonomous subtasks and data-integrated operating rooms outline a still-experimental horizon. The challenge for surgical leadership and healthcare systems is to ensure that progress within each layer reinforces the others, so that investment in advanced technology does not come at the expense of basic infrastructure, training and equity.

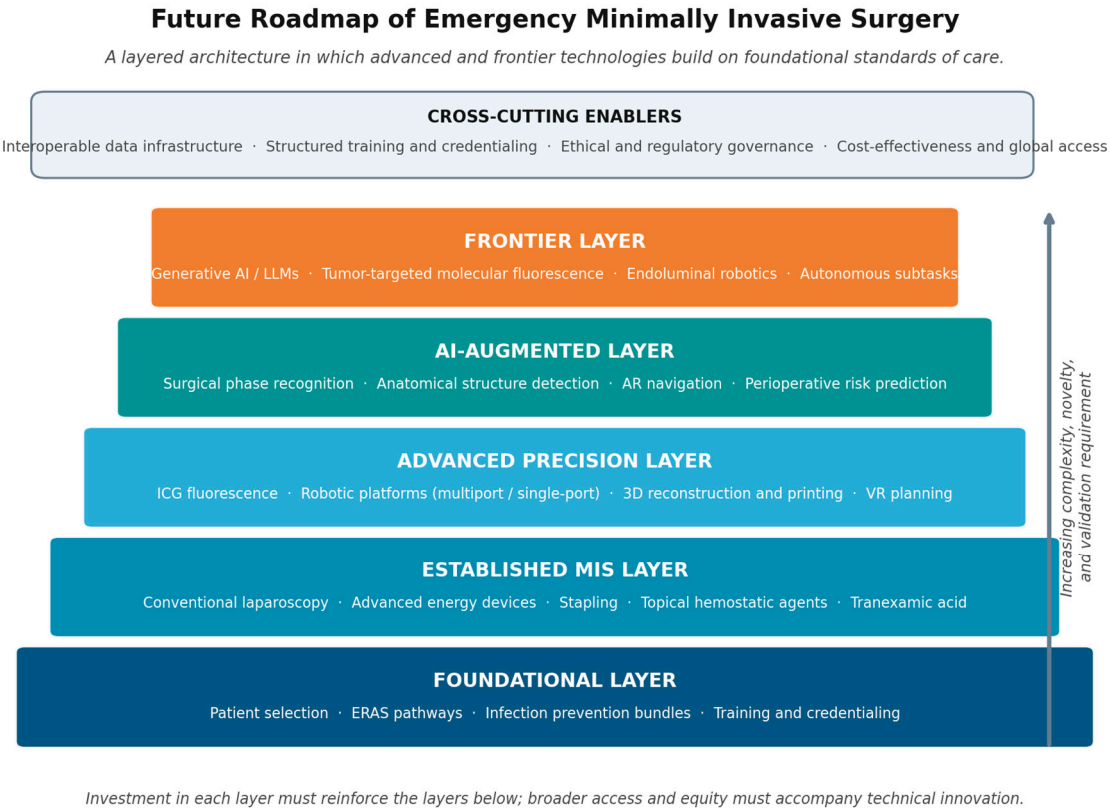

Figure 2. Future roadmap of emergency minimally invasive surgery, illustrated as a layered architecture in which advanced and frontier technologies build progressively on foundational standards of care, supported by cross-cutting enablers of training, governance and equity.

11. Conclusions

Minimally invasive surgery has evolved through five overlapping technological eras—conventional laparoscopy, advanced laparoscopic emergency surgery, fluorescence-guided surgery, robotic assistance and the emerging AI- and image-guided era—progressively reshaping selected areas of emergency abdominal care. Laparoscopic appendectomy, cholecystectomy and perforated ulcer repair in stable patients are supported by multiple randomized and meta-analytic studies; laparoscopic management of strangulated hernia, adhesive obstruction and selected diverticulitis by predominantly observational data and selected trials; and robotic and AI-supported approaches by early-

© 2026 by the author(s). Distributed under a Creative Commons CC BY license.

Preprints.org | NOT PEER-REVIEWED | Posted: 10 November 2026 https://doi.org/10.20944/preprints202611.0948.v1

phase evidence largely derived from elective practice. ICG fluorescence enhances biliary anatomy identification and perfusion assessment, with the WSES consensus providing a framework for standardization in the emergency setting [15]. Robotic platforms offer superior visualization, ergonomics and articulation, but remain constrained by time pressure, cost, training, availability and the need for rapid conversion pathways. The most realistic near-term role of AI is decision support—anatomy recognition, warnings for critical structures, objective perfusion assessment, conversion and complication risk prediction and structured documentation—rather than autonomy. Advanced energy devices, hemostatic agents and 3D reconstruction extend the safe boundary of MIS as complementary pillars.

The value of these technologies depends less on the technology itself than on appropriate patient selection, surgeon expertise, team preparedness, institutional readiness and disciplined judgement regarding when not to use a minimally invasive approach. Future research should consolidate the fragmentary evidence base through prospective multicentre studies and pragmatic randomized trials designed for the emergency setting, with harmonized outcomes, standardized fluorescence protocols and explicit reporting of selection criteria, and should develop interoperable digital infrastructure so that machine learning models can be trained and externally validated on representative emergency cohorts. Guided by rigorous methodology, structured training and ethical reflection, the combined progress of fluorescence imaging, robotic assistance, AI and complementary technologies may translate into measurable, equitable and sustainable improvement in outcomes for patients undergoing emergency abdominal surgery worldwide.

Author Contributions: Conceptualization, M.M., F.A. and G.M.; methodology, M.M., F.A. and G.M.; investigation and literature search, M.M., F.A. and G.M.; writing—original draft preparation, M.M., F.A. and G.M.; writing—review and editing, M.M., I.B., G.M., M.P., L.A., A.A., A.B., C.B., C.G., A.G., W.L.R.P., Mi.P., M.S., S.G., S.M.C. and F.A.; supervision, F.A. All authors have read and agreed to the published version of the manuscript.

Funding: This research received no external funding.

Institutional Review Board Statement: Not applicable.

Informed Consent Statement: Not applicable.

Data Availability Statement: No new data were created or analyzed in this study. Data sharing is not applicable to this article.

Acknowledgments: [To be completed by the authors. If any generative AI tool was used in the preparation of the manuscript, MDPI requires that it be declared here or in the Materials and Methods section.].

Conflicts of Interest: The authors declare no conflicts of interest.

References

1. Montori, G.; Serrano, E.; Procida, G.; et al. Standardization of indocyanine green (ICG) fluorescence in emergency surgery for small bowel obstruction: a preliminary experience. *Mini-invasive Surg* **2026**. https://doi.org/10.20517/2574-1225.2025.130
2. Anand, E.; Rahman, S.A.; Tomlinson, C.; Mercer, S.J.; Pucher, P.H. Comparison of major abdominal emergency surgery outcomes across organizational models of emergency surgical care: Analysis of the UK NELA national database. *J Trauma Acute Care Surg* **2023**, *96*, 305–312. https://doi.org/10.1097/ta.0000000000004056
3. Catena, F.; Di Saverio, S.; Kelly, M.D.; et al. Bologna Guidelines for Diagnosis and Management of Adhesive Small Bowel Obstruction (ASBO): 2010 Evidence-Based Guidelines of the World Society of Emergency Surgery. *World J Emerg Surg* **2011**, *6*, 5. https://doi.org/10.1186/1749-7922-6-5
4. Agrawal, H.; Tanwar, H.; Gupta, N. Revolutionizing hepatobiliary surgery: Impact of three-dimensional imaging and virtual surgical planning on precision, complications, and patient outcomes. *Artif Intell Gastroenterol* **2025**, *6*. https://doi.org/10.35712/aig.v6.i1.106746

© 2026 by the author(s). Distributed under a Creative Commons CC BY license.

Preprints.org | NOT PEER-REVIEWED | Posted: 10 November 2026 https://doi.org/10.20944/preprints202611.0948.v1

5. Avella, P.; Brunese, M.C.; Spiezia, S.; et al. Imaging-based 3D-printed anatomical models for preoperative planning in hepatopancreatobiliary surgery: a single-center pilot study, cost analysis, and systematic review. *Radiol Med* **2026**. https://doi.org/10.1007/s11547-026-02210-3
6. Singh, A.; Anand, S.; Pakkasjärvi, N.; Verma, A.; Bajpai, M. Energy Devices for Clipless–Sutureless Laparoscopic Appendectomy: A Systematic Review and Meta-Analysis on Utility and Safety. *Medicina (Kaunas)* **2022**, *58*, 1535. https://doi.org/10.3390/medicina58111535
7. Newcomb, W.L.; Hope, W.W.; Schmelzer, T.M.; et al. Comparison of blood vessel sealing among new electrosurgical and ultrasonic devices. *Surg Endosc* **2008**, *23*, 90–96. https://doi.org/10.1007/s00464-008-9932-x
8. Bouras, M.; Bourdiol, A.; Rooze, P.; Hourmant, Y.; Caillard, A.; Roquilly, A. Tranexamic acid: a narrative review of its current role in perioperative medicine and acute medical bleeding. *Front Med* **2024**, *11*. https://doi.org/10.3389/fmed.2024.1416998
9. Dagnino, G.; Kundrat, D. Robot-assistive minimally invasive surgery: trends and future directions. *Int J Intell Robot Appl* **2024**, *8*, 812–826. https://doi.org/10.1007/s41315-024-00341-2
10. Picciariello, A.; Annicchiarico, A.; Gallo, G.; Dezi, A.; Grossi, U. Evaluation of the da Vinci single-port system in colorectal cancer surgery: a scoping review. *Updates Surg* **2024**, *76*, 2515–2520. https://doi.org/10.1007/s13304-024-02014-y
11. Celotto, F.; Ramacciotti, N.; Mangano, A.; et al. Da Vinci single-port robotic system current application and future perspective in general surgery: A scoping review. *Surg Endosc* **2024**, *38*, 4814–4830. https://doi.org/10.1007/s00464-024-11126-w
12. Sermonesi, G.; Tian, B.W.C.A.; Vallicelli, C.; et al. Cesena guidelines: WSES consensus statement on laparoscopic-first approach to general surgery emergencies and abdominal trauma. *World J Emerg Surg* **2023**, *18*. https://doi.org/10.1186/s13017-023-00520-9
13. Luo, Y.; Zhang, H.; Wu, Q.; et al. Indocyanine green fluorescence imaging-assisted laparoscopy resection of retroperitoneal tumors in children: case report and literature review. *Front Pediatr* **2024**, *12*. https://doi.org/10.3389/fped.2024.1374919
14. Lai, M.C.; Geng, L.; Zheng, S.S.; Deng, J.F. Laparoscopic ultrasound-guided superselective portal vein injection combined with real-time indocyanine green fluorescence imaging and navigation for accurate resection of localized intrahepatic bile duct dilatation: a case report. *BMC Surg* **2021**, *21*. https://doi.org/10.1186/s12893-021-01325-w
15. De Simone, B.; Abu-Zidan, F.M.; Boni, L.; et al. Indocyanine green fluorescence-guided surgery in the emergency setting: the WSES international consensus position paper. *World J Emerg Surg* **2025**, *20*. https://doi.org/10.1186/s13017-025-00575-w
16. Erozkan, K.; Gorgun, E. Development of robotic surgical devices and its application in colorectal surgery. *Mini-invasive Surg* **2023**. https://doi.org/10.20517/2574-1225.2023.56
17. De Simone, B.; Deeken, G.; Catena, F. Balancing Ethics and Innovation: Can Artificial Intelligence Safely Transform Emergency Surgery? A Narrative Perspective. *J Clin Med* **2025**, *14*, 3111. https://doi.org/10.3390/jcm14093111
18. Daungsupawong, H.; Wiwanitkit, V. Comment on "From ChatGPT to Treatment: the Future of AI and Large Language Models in Surgical Oncology". *Indian J Surg Oncol* **2024**, *15*, 201. https://doi.org/10.1007/s13193-024-01886-1
19. Zhou, J.; Liu, Y.; Yang, Y.; Fang, P.; Chen, L.; Yuan, Y. The rise of ChatGPT-4: exploring its efficacy as a decision support tool in esophageal surgery – a research letter. *Int J Surg* **2024**, *110*, 5928–5930. https://doi.org/10.1097/js9.0000000000001696
20. Fransvea, P.; Fico, V.; Puccioni, C.; et al. Application of fluorescence-guided surgery in the acute care setting: a systematic literature review. *Langenbecks Arch Surg* **2023**, *408*. https://doi.org/10.1007/s00423-023-03109-7
21. Khalaf, M.H.; Abdelrahman, H.; El-Menyar, A.; et al. Utility of indocyanine green fluorescent dye in emergency general surgery: a review of the contemporary literature. *Front Surg* **2024**, *11*. https://doi.org/10.3389/fsurg.2024.1345831

© 2026 by the author(s). Distributed under a Creative Commons CC BY license.

Preprints.org | NOT PEER-REVIEWED | Posted: 10 November 2026 https://doi.org/10.20944/preprints202611.0948.v1

22. De Simone, B.; Abu-Zidan, F.M.; Gumbs, A.A.; et al. Knowledge, attitude, and practice of artificial intelligence in emergency and trauma surgery, the ARIES project: an international web-based survey. *World J Emerg Surg* **2022**, *17*. https://doi.org/10.1186/s13017-022-00413-3
23. Eguchi, S.; Nagahisa, Y.; Yamaguchi, K.; Inamura, Y.; Okabe, M.; Masui, T. Impact of Endoscopic Surgical Skill Qualification System on Surgical Technique and Training in Japan: Insights from an Eight-Year Survey. *J Laparoendosc Adv Surg Tech A* **2026**, *36*, 445–450. https://doi.org/10.1177/10926429261438097
24. de'Angelis, N.; Marchegiani, F.; Schena, C.A.; et al. Training curriculum in minimally invasive emergency digestive surgery: 2022 WSES position paper. *World J Emerg Surg* **2023**, *18*. https://doi.org/10.1186/s13017-023-00476-w
25. Cassinotti, E.; Al-Taher, M.; Antoniou, S.A.; et al. European Association for Endoscopic Surgery (EAES) consensus on Indocyanine Green (ICG) fluorescence-guided surgery. *Surg Endosc* **2023**, *37*, 1629–1648. https://doi.org/10.1007/s00464-023-09928-5
26. Ceresoli, M.; Pisano, M.; Abu-Zidan, F.; et al. Minimally invasive surgery in emergency surgery: a WSES survey. *World J Emerg Surg* **2022**, *17*. https://doi.org/10.1186/s13017-022-00419-x
27. Arnold, M.; Elhage, S.; Schiffern, L.; et al. Use of minimally invasive surgery in emergency general surgery procedures. *Surg Endosc* **2019**, *34*, 2258–2265. https://doi.org/10.1007/s00464-019-07016-1
28. Miyashita, R.; Kitazawa, M.; Tokumaru, S.; et al. Importance of intraoperative indocyanine green imaging in the management of non-occlusive mesenteric ischemia: a case report. *Surg Case Rep* **2023**, *9*. https://doi.org/10.1186/s40792-023-01614-x
29. Lombardi, P.M.; Mazzola, M.; Nicastro, V.; et al. The iGreenGO Study: The Clinical Role of Indocyanine Green Imaging Fluorescence in Modifying the Surgeon's Conduct During the Surgical Treatment of Advanced Gastric Cancer—Study Protocol for an International Multicenter Prospective Study. *Front Oncol* **2022**, *12*. https://doi.org/10.3389/fonc.2022.854754
30. She, W.H.; Cheung, T.T.; Chan, M.Y.; et al. Routine use of ICG to enhance operative safety in emergency laparoscopic cholecystectomy: a randomized controlled trial. *Surg Endosc* **2022**, *36*, 4442–4451. https://doi.org/10.1007/s00464-021-08795-2
31. Karampinis, I.; Keese, M.; Jakob, J.; et al. Indocyanine Green Tissue Angiography Can Reduce Extended Bowel Resections in Acute Mesenteric Ischemia. *J Gastrointest Surg* **2018**, *22*, 2117–2124. https://doi.org/10.1007/s11605-018-3855-1
32. Li, Z.R.; Cheng, Y.C.; Hong, Z.J. Diagnostic laparoscopy with indocyanine green fluorescence test for the evaluation of intestinal perfusion in abdominal blunt injury: a case report. *Int J Emerg Med* **2024**, *17*. https://doi.org/10.1186/s12245-024-00684-4
33. Kim, M.; Zhang, Y.; Jin, S. Soft tissue surgical robot for minimally invasive surgery: a review. *Biomed Eng Lett* **2023**, *13*, 561–569. https://doi.org/10.1007/s13534-023-00326-3
34. Navarrete-Arellano, M. Robotic-Assisted Minimally Invasive Surgery in Children. In *Latest Developments in Medical Robotics Systems*; IntechOpen: London, UK, 2021. https://doi.org/10.5772/intechopen.96684
35. Ibrahim, Y.; Rahman, M.A.; Pickering, O.; Cole, K.; Pucher, P.H. Current evidence and reported experiences for robot-assisted emergency general surgery: systematic review. *J Robot Surg* **2025**, *19*. https://doi.org/10.1007/s11701-025-02696-5
36. Coco, D.; Leanza, S. Robotic surgery in acute colorectal emergencies: a comprehensive systematic review and meta-analysis. *J Robot Surg* **2025**, *19*. https://doi.org/10.1007/s11701-025-02906-0
37. Charland, N.; Hadaya, J.; Mallick, S.; et al. National trends and outcomes of robotic emergency general surgery in the United States. *Surgery* **2024**, *176*, 835–840. https://doi.org/10.1016/j.surg.2024.05.002
38. Paracchini, S.; Taliento, C.; Pellecchia, G.; et al. Artificial intelligence in the operating room: A systematic review of AI models for surgical phase, instruments and anatomical structure identification. *Acta Obstet Gynecol Scand* **2025**, *104*, 2054–2064. https://doi.org/10.1111/aogs.70045
39. den Boer, R.B.; de Jongh, C.; Huijbers, W.T.E.; et al. Computer-aided anatomy recognition in intrathoracic and -abdominal surgery: a systematic review. *Surg Endosc* **2022**, *36*, 8737–8752. https://doi.org/10.1007/s00464-022-09421-5

© 2026 by the author(s). Distributed under a Creative Commons CC BY license.

Preprints.org | NOT PEER-REVIEWED | Posted: 10 November 2026 https://doi.org/10.20944/preprints202611.0948.v1

40. Twinanda, A.P.; Shehata, S.; Mutter, D.; Marescaux, J.; de Mathelin, M.; Padoy, N. EndoNet: A Deep Architecture for Recognition Tasks on Laparoscopic Videos. *IEEE Trans Med Imaging* **2017**, *36*, 86–97. https://doi.org/10.1109/tmi.2016.2593957
41. Wang, E.; Liu, Y.; Tu, P.; Taylor, Z.A.; Chen, X. Video-Based Soft Tissue Deformation Tracking for Laparoscopic Augmented Reality-Based Navigation in Kidney Surgery. *IEEE Trans Med Imaging* **2024**, *43*, 4161–4173. https://doi.org/10.1109/tmi.2024.3413537
42. Wang, J.; Suenaga, H.; Hoshi, K.; et al. Augmented Reality Navigation With Automatic Marker-Free Image Registration Using 3-D Image Overlay for Dental Surgery. *IEEE Trans Biomed Eng* **2014**, *61*, 1295–1304. https://doi.org/10.1109/tbme.2014.2301191
43. Mirabella, A.; Fiorentini, T.; Tutino, R.; et al. Laparoscopy is an available alternative to open surgery in the treatment of perforated peptic ulcers: a retrospective multicenter study. *BMC Surg* **2018**, *18*. https://doi.org/10.1186/s12893-018-0413-4
44. Garale, M.N.; Rewatkar, A.K.; Moktali, A.V.; Dalvi, A. Incidence and Risk Factors for Surgical Site Infections Following Emergency Laparotomies: A Prospective Observational Study. *Cureus* **2025**. https://doi.org/10.7759/cureus.80283
45. Wei, S.; Green, C.; Kao, L.S.; et al. Accurate risk stratification for development of organ/space surgical site infections after emergent trauma laparotomy. *J Trauma Acute Care Surg* **2019**, *86*, 226–231. https://doi.org/10.1097/ta.0000000000002143
46. de Boer, H.D.; Demartines, N. Invited Commentary: "Guidelines for Perioperative Care for Emergency: Laparotomy Enhanced Recovery After Surgery (ERAS) Society Recommendations Part 1—Preoperative: Diagnosis, Rapid Assessment and Optimization". *World J Surg* **2021**, *45*, 1291–1292. https://doi.org/10.1007/s00268-021-06083-7
47. Saurabh, K.; Sureshkumar, S.; Mohsina, S.; Mahalakshmy, T.; Kundra, P.; Kate, V. Adapted ERAS Pathway Versus Standard Care in Patients Undergoing Emergency Small Bowel Surgery: a Randomized Controlled Trial. *J Gastrointest Surg* **2020**, *24*, 2077–2087. https://doi.org/10.1007/s11605-020-04684-6
48. Mohsina, S.; Shanmugam, D.; Sureshkumar, S.; Kundra, P.; Mahalakshmy, T.; Kate, V. Adapted ERAS Pathway vs. Standard Care in Patients with Perforated Duodenal Ulcer—a Randomized Controlled Trial. *J Gastrointest Surg* **2018**, *22*, 107–116. https://doi.org/10.1007/s11605-017-3474-2
49. Buhl, M.S.A.; Jaensch, C.; Madsen, A.H. Enhanced recovery after surgery and intestinal obstruction: A scoping review. *World J Surg* **2024**, *48*, 2120–2131. https://doi.org/10.1002/wjs.12310
50. Nair ES, R.; Ghalige, H.S.; Tukaram, A.; P, D.; Priya, N. A Prospective Comparative Study of Enhanced Recovery After Surgery (ERAS) Versus Conventional Protocols in Emergency Laparoscopic Appendectomies. *Cureus* **2025**. https://doi.org/10.7759/cureus.100533
51. Fonseca, M.K.; Rizental, L.B.; da Cunha, C.E.B.; Baldissera, N.; Wagner, M.B.; Fraga, G.P. Applying enhanced recovery principles to emergency laparotomy in penetrating abdominal trauma: a case-matched study. *Eur J Trauma Emerg Surg* **2024**, *50*, 2123–2135. https://doi.org/10.1007/s00068-024-02577-w
52. Zhang, G.; Wu, B. Meta-analysis of the clinical efficacy of laparoscopic appendectomy in the treatment of acute appendicitis. *World J Emerg Surg* **2022**, *17*. https://doi.org/10.1186/s13017-022-00431-1
53. Jamal, Z.; Talal, M.A.; Saeed, J.; et al. Is robotic surgery ready for emergency cholecystectomy? A systematic review and meta-analysis of robotic versus laparoscopic approach in acute cholecystitis. *J Robot Surg* **2026**, *20*. https://doi.org/10.1007/s11701-026-03145-7
54. Klein, J.; Lemma, M.; Prabhakaran, K.; et al. Robotic versus Laparoscopic Emergency and Acute Care Surgery: Redefining Novelty (RLEARN): feasibility and benefit of robotic cholecystectomy for acute cholecystitis at a level 1 trauma center. *Trauma Surg Acute Care Open* **2024**, *9*, e001522. https://doi.org/10.1136/tsaco-2024-001522
55. Pesce, A.; Fabbri, N.; Bonazza, L.; Feo, C. The role of fluorescent cholangiography to improve operative safety in different severity degrees of acute cholecystitis during emergency laparoscopic cholecystectomy: a prospective cohort study. *Int J Surg* **2024**, *110*, 7775–7781. https://doi.org/10.1097/js9.0000000000002160
56. Serban, D.; Badiu, D.; Davitoiu, D.; et al. Systematic review of the role of indocyanine green near-infrared fluorescence in safe laparoscopic cholecystectomy (Review). *Exp Ther Med* **2021**, *23*. https://doi.org/10.3892/etm.2021.11110

© 2026 by the author(s). Distributed under a Creative Commons CC BY license.

Preprints.org | NOT PEER-REVIEWED | Posted: 10 November 2026 https://doi.org/10.20944/preprints202611.0948.v1

© 2026 by the author(s). Distributed under a Creative Commons CC BY license.

Preprints.org | NOT PEER-REVIEWED | Posted: 10 November 2026 https://doi.org/10.20944/preprints202611.0948.v1

57. Pavulans, J.; Jain, N.; Zeiza, K.; et al. Fluorescence Cholangiography for Extrahepatic Bile Duct Visualization in Urgent Mild and Moderate Acute Cholecystitis Patients Undergoing Laparoscopic Cholecystectomy: A Prospective Pilot Study. *J Clin Med* **2025**, *14*, 541. https://doi.org/10.3390/jcm14020541
58. Abdallah, H.S.; Sedky, M.H.; Sedky, Z.H. The difficult laparoscopic cholecystectomy: a narrative review. *BMC Surg* **2025**, *25*. https://doi.org/10.1186/s12893-025-02847-3
59. Sokhal, B.; Mohamedahmed, A.; Zaman, S.; et al. Laparoscopic versus open repair for peptic ulcer perforation: a systematic review, meta-analysis and trial sequential analysis of randomised controlled trials. Time to conclude!. *Ann R Coll Surg Engl* **2025**, *107*, 331–345. https://doi.org/10.1308/rcsann.2024.0082
60. Panin, S.I.; Nechay, T.V.; Sazhin, I.V.; et al. Laparoscopic suture repair for perforated peptic ulcer disease: a meta-review and trial sequential analysis. *Front Surg* **2025**, *12*. https://doi.org/10.3389/fsurg.2025.1496192
61. Huang, Y.; Fu, R.; Liu, D.; Wen, K. Keys to successful laparoscopic adhesiolysis for adhesive small bowel obstruction: A scoping review. *Heliyon* **2024**, *10*, e34359. https://doi.org/10.1016/j.heliyon.2024.e34359
62. Bauer, J.; Keeley, B.; Krieger, B.; et al. Adhesive Small Bowel Obstruction: Early Operative versus Observational Management. *Am Surg* **2015**, *81*, 614–620. https://doi.org/10.1177/000313481508100627
63. Christofi, A.; Traska, T.; Dimitroulis, D. Near-infrared indocyanine green angiography in recognizing bowel ischemia in emergency surgery: game changer or overrated?. *Innov Surg Sci* **2024**, *9*, 113–121. https://doi.org/10.1515/iss-2024-0013
64. Daskalopoulou, D.; Kankam, J.; Plambeck, J.; Ambe, P.C.; Zarras, K. Intraoperative real-time fluorescence angiography with indocyanine green for evaluation of intestinal viability during surgery for an incarcerated obturator hernia: a case report. *Patient Saf Surg* **2018**, *12*. https://doi.org/10.1186/s13037-018-0173-1
65. Nakashima, K.; Ryu, S.; Okamoto, A.; et al. Intestinal blood flow evaluation using the indocyanine green fluorescence imaging method in a case of incarcerated obturator hernia: A case report. *Asian J Endosc Surg* **2020**, *14*, 565–569. https://doi.org/10.1111/ases.12875
66. Del Giudice, R.; Mazzoni, G.; Tranfaglia, C.; Bellotti, A.; Zofrea, P. Laparoscopic Mesh Repair of a Strangulated Right Obturator Hernia With Intraoperative Indocyanine Green Assessment of Bowel Viability: A Case Report. *Cureus* **2025**. https://doi.org/10.7759/cureus.96211
67. Ceccarelli, G.; Pasculli, A.; Bugiantella, W.; et al. Minimally invasive laparoscopic and robot-assisted emergency treatment of strangulated giant hiatal hernias: report of five cases and literature review. *World J Emerg Surg* **2020**, *15*. https://doi.org/10.1186/s13017-020-00316-1
68. Jang, E.J.; Kim, K.W. Exploring the Potential of Robotic Single-Port Surgery for Gallbladder Cancer: Initial Insights and Future Prospects. *Ann Surg Oncol* **2024**, *32*, 440–442. https://doi.org/10.1245/s10434-024-16252-2
69. Zhao, Y.; Chen, T.; Wang, H.; et al. Influence of Three-Dimensional Visual Reconstruction Technology Combined with Virtual Surgical Planning of CTA Images on Precise Resection of Liver Cancer in Hepatobiliary Surgery. *Comput Math Methods Med* **2022**, *2022*, 1–9. https://doi.org/10.1155/2022/4376654
70. Jianxi, W.; Xiongfeng, Z.; Zehao, Z.; et al. Indocyanine green fluorescence-guided laparoscopic hepatectomy versus conventional laparoscopic hepatectomy for hepatocellular carcinoma: A single-center propensity score matching study. *Front Oncol* **2022**, *12*. https://doi.org/10.3389/fonc.2022.930065
71. Li, C.; Du, J.; Jiang, G.; et al. White-light activatable organic NIR-II luminescence nanomaterials for imaging-guided surgery. *Nat Commun* **2024**, *15*. https://doi.org/10.1038/s41467-024-50202-6
72. Esposito, C.; Settimi, A.; Del Conte, F.; et al. Image-Guided Pediatric Surgery Using Indocyanine Green (ICG) Fluorescence in Laparoscopic and Robotic Surgery. *Front Pediatr* **2020**, *8*. https://doi.org/10.3389/fped.2020.00314
73. Benya, R.; Quintana, J.; Brundage, B. Adverse reactions to indocyanine green: A case report and a review of the literature. *Cathet Cardiovasc Diagn* **1989**, *17*, 231–233. https://doi.org/10.1002/ccd.1810170410
74. Faber, R.A.; Meijer, R.P.J.; Droogh, D.H.M.; et al. Indocyanine green near-infrared fluorescence bowel perfusion assessment to prevent anastomotic leakage in minimally invasive colorectal surgery (AVOID): a multicentre, randomised, controlled, phase 3 trial. *Lancet Gastroenterol Hepatol* **2024**, *9*, 924–934. https://doi.org/10.1016/s2468-1253(24)00198-5

© 2026 by the author(s). Distributed under a Creative Commons CC BY license.

Preprints.org | NOT PEER-REVIEWED | Posted: 10 November 2026 https://doi.org/10.20944/preprints202611.0948.v1

75. Cassinotti, E.; Boni, L.; Baldari, L. Application of indocyanine green (ICG)-guided surgery in clinical practice: lesson to learn from other organs—an overview on clinical applications and future perspectives. *Updates Surg* **2022**, *75*, 357–365. https://doi.org/10.1007/s13304-022-01361-y
76. Mc Entee, P.D.; Singaravelu, A.; Boland, P.A.; Moynihan, A.; Creavin, B.; Cahill, R.A. Impact of indocyanine green fluorescence angiography on surgeon action and anastomotic leak in colorectal resections. A systematic review and meta-analysis. *Surg Endosc* **2025**, *39*, 1473–1489. https://doi.org/10.1007/s00464-025-11582-y
77. Kazi, M.; Ajith, A.; Bhoyar, A.; Yelamanchi, R. Fluorescence imaging in reducing anastomotic leak after left-sided colorectal resections: a systematic review and updated meta-analysis. *ANZ J Surg* **2024**, *94*, 2128–2136. https://doi.org/10.1111/ans.19201
78. Lucarini, A.; Guida, A.M.; Orville, M.; Panis, Y. Indocyanine green fluorescence angiography could reduce the risk of anastomotic leakage in rectal cancer surgery: a systematic review and meta-analysis of randomized controlled trials. *Colorectal Dis* **2024**, *26*, 408–416. https://doi.org/10.1111/codi.16868
79. Fok, K.Y.; Toh, J.W.T. Indocyanine green and height of anastomosis in colorectal surgery– a network meta-analysis. *Langenbecks Arch Surg* **2025**, *410*. https://doi.org/10.1007/s00423-025-03765-x
80. Ramadan, A.; Etrusco, A.; D'Amato, A.; et al. Evaluation of the benefit of indocyanine green as an educational and practical tool for ureteral identification in laparoscopic pelvic surgery: a cross-sectional study. *Minim Invasive Ther Allied Technol* **2024**, *33*, 302–310. https://doi.org/10.1080/13645706.2024.2376837
81. Chen, Q.; Cai, Y.; Cheng, K.; et al. Real-time fluorescence-guided adhesiolysis with indocyanine green in intra-abdominal surgery (with video). *Sci Rep* **2024**, *14*. https://doi.org/10.1038/s41598-024-51450-8
82. Perini, D.; Martellucci, J. Don't forget emergency surgery! Lessons to learn from elective indocyanine green-guided gastrointestinal interventions. *World J Gastrointest Surg* **2024**, *16*, 270–275. https://doi.org/10.4240/wjgs.v16.i2.270
83. Afifi, I.; Abdelrahman, H.; El-Faramawy, A.; et al. The use of Indocyanine green fluorescent in patients with abdominal trauma for better intraoperative decision-making and less bowel anastomosis leak: case series. *J Surg Case Rep* **2021**, *2021*. https://doi.org/10.1093/jscr/rjab235
84. Tam, A.; Abdel-Rahim, A.; Dix, F.; Barwell, J.; Mittapalli, D. Indocyanin Green Fluorescence Evaluation of Colonic Perfusion During Elective Open Abdominal Aortic Aneurysm Repair. *Vasc Endovascular Surg* **2023**, *58*, 42–46. https://doi.org/10.1177/15385744231189361
85. Onishi, S.; Yamada, K.; Murakami, M.; Kedoin, C.; Muto, M.; Ieiri, S. Co-injection of Bile and Indocyanine Green for Detecting Pancreaticobiliary Maljunction of Choledochal Cyst. *Eur J Pediatr Surg Rep* **2022**, *10*, e127–e130. https://doi.org/10.1055/s-0042-1747913
86. Wu, J.; Martin, M.J.; Kirkpatrick, V.; Cassaro, S.; Pérez Rodríguez, F. The Great Debate: Robotic vs Traditional Surgical Approach in the Acute Care Setting. *Am Surg* **2024**, *90*, 2357–2361. https://doi.org/10.1177/00031348241248802
87. Cole, K.; Shahdoost-Rad, A.; Ibrahim, Y.; et al. Robotic emergency general surgery, future or fallacy?: case-matched comparison of operative and clinical outcomes during the adoption phase in a tertiary centre. *J Robot Surg* **2025**, *19*. https://doi.org/10.1007/s11701-025-02851-y
88. Kim, H.S.; Oh, B.Y.; Cheong, C.; et al. Single-incision robotic colorectal surgery with the da Vinci SP® surgical system: initial results of 50 cases. *Tech Coloproctol* **2023**, *27*, 589–599. https://doi.org/10.1007/s10151-023-02791-5
89. Aburrous, M.; Shao, M.; Bailey, B.; et al. Are current laparoscopic common bile duct exploration simulators suitably designed to capture the complexity of the technique? A review of the literature and evaluation of those available. *Minim Invasive Ther Allied Technol* **2025**, *34*, 365–377. https://doi.org/10.1080/13645706.2025.2509220
90. Klok, J.W.; Rahimi, M.; Hardon, S.; et al. The impact of simulated intra-abdominal movement on basic laparoscopic skills development: a feasibility study. *Minim Invasive Ther Allied Technol* **2025**, *34*, 324–333. https://doi.org/10.1080/13645706.2025.2481394
91. Ryu, S.; Goto, K.; Kitagawa, T.; et al. Real-time Artificial Intelligence Navigation-Assisted Anatomical Recognition in Laparoscopic Colorectal Surgery. *J Gastrointest Surg* **2023**, *27*, 3080–3082. https://doi.org/10.1007/s11605-023-05819-1

© 2026 by the author(s). Distributed under a Creative Commons CC BY license.

Preprints.org | NOT PEER-REVIEWED | Posted: 10 November 2026 https://doi.org/10.20944/preprints202611.0948.v1

92. Shah, D.; Tesfai, F.M.; Boal, M.; Arezzo, A.; Francis, N. Evaluation of current and emerging endoluminal robotic platforms using the IDEAL framework. *Minim Invasive Ther Allied Technol* **2025**, *34*, 253–266. https://doi.org/10.1080/13645706.2025.2467805
93. Mao, T.; Zhao, X.; Xie, Q.; Gao, F. A commentary on 'Machine learning based peri-surgical risk calculator for abdominal related emergency general surgery: a multicenter retrospective study'. *Int J Surg* **2024**, *110*, 4502–4503. https://doi.org/10.1097/js9.0000000000001434
94. Stam, W.T.; Ingwersen, E.W.; Ali, M.; et al. Machine learning models in clinical practice for the prediction of postoperative complications after major abdominal surgery. *Surg Today* **2023**, *53*, 1209–1215. https://doi.org/10.1007/s00595-023-02662-4
95. Mazzotta, A.D.; Burti, E.; Causio, F.A.; et al. Machine Learning Approaches for the Prediction of Postoperative Major Complications in Patients Undergoing Surgery for Bowel Obstruction. *J Pers Med* **2024**, *14*, 1043. https://doi.org/10.3390/jpm14101043
96. Cicerone, O.; Frassini, S.; Gallotti, A.; et al. Development and validation of machine learning tools for predicting postoperative complications in acute calculous cholecystitis. *Updates Surg* **2025**. https://doi.org/10.1007/s13304-025-02476-8
97. Hossain, I.; Madani, A.; Laplante, S. Machine learning perioperative applications in visceral surgery: a narrative review. *Front Surg* **2024**, *11*. https://doi.org/10.3389/fsurg.2024.1493779
98. Saroha, S.; Patel, A. Balancing Surgical Innovation and Risk: A Narrative Review of Emerging Technologies, Regulation, and Global Access. *Cureus* **2025**. https://doi.org/10.7759/cureus.87957
99. Boretto, L.; Pelanis, E.; Regensburger, A.; Fretland, Å.A.; Edwin, B.; Elle, O.J. Hybrid optical-vision tracking in laparoscopy: accuracy of navigation and ultrasound reconstruction. *Minim Invasive Ther Allied Technol* **2024**, *33*, 176–183. https://doi.org/10.1080/13645706.2024.2313032
100. Igami, T.; Hayashi, Y.; Yokyama, Y.; Mori, K.; Ebata, T. Development of real-time navigation system for laparoscopic hepatectomy using magnetic micro sensor. *Minim Invasive Ther Allied Technol* **2024**, *33*, 129–139. https://doi.org/10.1080/13645706.2023.2301594
101. Sánchez-Margallo, J.A.; Plaza de Miguel, C.; Fernández Anzules, R.A.; Sánchez-Margallo, F.M. Application of Mixed Reality in Medical Training and Surgical Planning Focused on Minimally Invasive Surgery. *Front Virtual Real* **2021**, *2*. https://doi.org/10.3389/frvir.2021.692641
102. Avrumova, F.; Lebl, D.R. Augmented reality for minimally invasive spinal surgery. *Front Surg* **2023**, *9*. https://doi.org/10.3389/fsurg.2022.1086988
103. Zhang, Y.; Zhang, Y.; Yang, Y.; et al. Case report: Indocyanine green fluorescence-guided imaging in laparoscope, a more sensitive detection technique of lateral lymph nodes metastases from rectal neuroendocrine tumors. *Front Oncol* **2022**, *12*. https://doi.org/10.3389/fonc.2022.1101990
104. Spotnitz, M.; Idnay, B.; Gordon, E.R.; et al. A Survey of Clinicians' Views of the Utility of Large Language Models. *Appl Clin Inform* **2024**, *15*, 306–312. https://doi.org/10.1055/a-2281-7092
105. Pressman, S.M.; Borna, S.; Gomez-Cabello, C.A.; Haider, S.A.; Haider, C.; Forte, A.J. AI and Ethics: A Systematic Review of the Ethical Considerations of Large Language Model Use in Surgery Research. *Healthcare (Basel)* **2024**, *12*, 825. https://doi.org/10.3390/healthcare12080825
106. Dhawan, R.; Brooks, K.D.; Shauly, O.; Shay, D.; Losken, A. Ethical Considerations for Generative Artificial Intelligence in Plastic Surgery. *Plast Reconstr Surg Glob Open* **2025**, *13*, e6825. https://doi.org/10.1097/gox.0000000000006825
107. Jaiswal, A.; Huang, K.G. "Energy devices in gynecological laparoscopy – Archaic to modern era". *Gynecol Minim Invasive Ther* **2017**, *6*, 147–151. https://doi.org/10.1016/j.gmit.2017.08.002
108. Meneses Alves, T.; Ferreira De Castro, L.; Tomé, A.; Ferreira, H. Applications of different energy devices in laparoscopic and robotic gynecological surgery: a systematic review. *Arch Gynecol Obstet* **2025**, *312*, 691–719. https://doi.org/10.1007/s00404-025-08055-x
109. Person, B.; Vivas, D.A.; Ruiz, D.; Talcott, M.; Coad, J.E.; Wexner, S.D. Comparison of four energy-based vascular sealing and cutting instruments: A porcine model. *Surg Endosc* **2007**, *22*, 534–538. https://doi.org/10.1007/s00464-007-9619-8

© 2026 by the author(s). Distributed under a Creative Commons CC BY license.

Preprints.org | NOT PEER-REVIEWED | Posted: 10 November 2026 https://doi.org/10.20944/preprints202611.0948.v1

110. Kim, F.J.; Chammas, M.F.; Gewehr, E.; et al. Temperature safety profile of laparoscopic devices: Harmonic ACE (ACE), Ligasure V (LV), and plasma trisector (PT). *Surg Endosc* **2007**, *22*, 1464–1469. https://doi.org/10.1007/s00464-007-9650-9
111. Milsom, J.W.; Trencheva, K.; Momose, K.; et al. A pilot randomized controlled trial comparing THUNDERBEAT to the Maryland LigaSure energy device in laparoscopic left colon surgery. *Surg Endosc* **2021**, *36*, 4265–4274. https://doi.org/10.1007/s00464-021-08765-8
112. Patrone, R.; Gambardella, C.; Romano, R.M.; et al. The impact of the ultrasonic, bipolar and integrated energy devices in the adrenal gland surgery: literature review and our experience. *BMC Surg* **2019**, *18*. https://doi.org/10.1186/s12893-018-0457-5
113. Schreiber, M.A.; Neveleff, D.J. Achieving Hemostasis With Topical Hemostats: Making Clinically and Economically Appropriate Decisions in the Surgical and Trauma Settings. *AORN J* **2011**, *94*. https://doi.org/10.1016/j.aorn.2011.09.018
114. Tompeck, A.J.; Gajdhar, A.U.R.; Dowling, M.; et al. A comprehensive review of topical hemostatic agents: The good, the bad, and the novel. *J Trauma Acute Care Surg* **2019**, *88*, e1–e21. https://doi.org/10.1097/ta.0000000000002508
115. Echave, M.; Oyagüez, I.; Casado, M.A. Use of Floseal®, a human gelatine-thrombin matrix sealant, in surgery: a systematic review. *BMC Surg* **2014**, *14*. https://doi.org/10.1186/1471-2482-14-111
116. Simo, K.A.; Hanna, E.M.; Imagawa, D.K.; Iannitti, D.A. Hemostatic Agents in Hepatobiliary and Pancreas Surgery: A Review of the Literature and Critical Evaluation of a Novel Carrier-Bound Fibrin Sealant (TachoSil). *ISRN Surg* **2012**, *2012*, 1–12. https://doi.org/10.5402/2012/729086
117. Campbell, B.; Castater, C.; Smith, R.N.; Sciaretta, J.D.; Nguyen, J. Use of Kaolin-Impregnated Gauze Aids in Hemostasis and Blood Loss Mitigation in a Penetrating Injury to the Bladder and Small Bowel. *Cureus* **2023**. https://doi.org/10.7759/cureus.46583
118. Losanoff, J.E.; Richman, B.W.; Jones, J.W. Cyanoacrylate Adhesive in Management of Severe Presacral Bleeding. *Dis Colon Rectum* **2002**, *45*, 1118–1119. https://doi.org/10.1007/s10350-004-6372-0
119. Tsurukiri, J.; Ohta, S.; Hoshiai, A.; et al. High-grade traumatic torso visceral injury with hemodynamic instability: effectiveness of transarterial embolization using n-butyl cyanoacrylate. *Acute Med Surg* **2017**, *4*, 145–151. https://doi.org/10.1002/ams2.264
120. Pourshahrestani, S.; Zeimaran, E.; Kadri, N.A.; Mutlu, N.; Boccaccini, A.R. Polymeric Hydrogel Systems as Emerging Biomaterial Platforms to Enable Hemostasis and Wound Healing. *Adv Healthc Mater* **2020**, *9*. https://doi.org/10.1002/adhm.202000905
121. Yang, Z.; Ye, T.; Ma, F.; et al. Preparation of Chitosan/Clay Composites for Safe and Effective Hemorrhage Control. *Molecules* **2022**, *27*, 2571. https://doi.org/10.3390/molecules27082571
122. Miao, D.; Zhao, Y.; Ren, X.; et al. A Multi-Task Based Deep Learning Framework With Landmark Detection for MRI Couinaud Segmentation. *IEEE J Transl Eng Health Med* **2024**, *12*, 697–710. https://doi.org/10.1109/jtehm.2024.3491612
123. Oh, N.; Kim, J.H.; Rhu, J.; et al. Comprehensive deep learning-based assessment of living liver donor CT angiography: from vascular segmentation to volumetric analysis. *Int J Surg* **2024**, *110*, 6551–6557. https://doi.org/10.1097/js9.0000000000001829
124. Boedecker, C.; Huettl, F.; Saalfeld, P.; et al. Using virtual 3D-models in surgical planning: workflow of an immersive virtual reality application in liver surgery. *Langenbecks Arch Surg* **2021**, *406*, 911–915. https://doi.org/10.1007/s00423-021-02127-7
125. Mitsouras, D.; Liacouras, P.; Imanzadeh, A.; et al. Medical 3D Printing for the Radiologist. *Radiographics* **2015**, *35*, 1965–1988. https://doi.org/10.1148/rg.2015140320
126. Meara, J.G.; Leather, A.J.M.; Hagander, L.; et al. Global Surgery 2030: evidence and solutions for achieving health, welfare, and economic development. *Lancet* **2015**, *386*, 569–624. https://doi.org/10.1016/s0140-6736(15)60160-x
127. World Health Organization. *Global Guidelines for the Prevention of Surgical Site Infection*; World Health Organization: Geneva, Switzerland, 2017.

© 2026 by the author(s). Distributed under a Creative Commons CC BY license.

Preprints.org | NOT PEER-REVIEWED | Posted: 10 November 2026 https://doi.org/10.20944/preprints202611.0948.v1

128. Lwin, T.M.; Hoffman, R.M.; Bouvet, M. The future of tumour-specific fluorescence-guided surgery for pancreatic cancer. *Lancet Gastroenterol Hepatol* **2020**, *5*, 715–717. https://doi.org/10.1016/s2468-1253(20)30123-0
129. De Simone, B.; Chouillard, E.; Ramos, A.C.; et al. Operative management of acute abdomen after bariatric surgery in the emergency setting: the OBA guidelines. *World J Emerg Surg* **2022**, *17*. https://doi.org/10.1186/s13017-022-00452-w

Disclaimer/Publisher's Note: The statements, opinions and data contained in all publications are solely those of the individual author(s) and contributor(s) and not of MDPI and/or the editor(s). MDPI and/or the editor(s) disclaim responsibility for any injury to people or property resulting from any ideas, methods, instructions or products referred to in the content.

© 2026 by the author(s). Distributed under a Creative Commons CC BY license.