

Review

Not peer-reviewed version

Effect of High Sucrose Diet on the Occurrence and Progression of Diabetic Retinopathy and Dietary Modification Strategies

[Chen Yang](#), [Yifei Yu](#), [Jianhong An](#)*

Posted Date: 1 April 2024

doi: 10.20944/preprints202404.0085.v1

Keywords: high-sucrose diet; diabetic retinopathy; hyperglycaemia; dietary modification strategies



Preprints.org is a free multidiscipline platform providing preprint service that is dedicated to making early versions of research outputs permanently available and citable. Preprints posted at Preprints.org appear in Web of Science, Crossref, Google Scholar, Scilit, Europe PMC.

Copyright: This is an open access article distributed under the Creative Commons Attribution License which permits unrestricted use, distribution, and reproduction in any medium, provided the original work is properly cited.

Review

Effect of High Sucrose Diet on the Occurrence and Progression of Diabetic Retinopathy and Dietary Modification Strategies

Chen Yang ^{1,†}, Yifei Yu ^{2,†} and Jianhong An ^{1,*}

¹ State Key Laboratory of Ophthalmology, Optometry and Vision Science, Wenzhou Medical University, Wenzhou 325027, Zhejiang, China; Oujiang Laboratory, Zhejiang Lab for Regenerative Medicine, Vision and Brain Health, Wenzhou 325101, Zhejiang, China

² Key Laboratory of Precision Nutrition and Food Quality, Department of Nutrition and Health, China Agricultural University, Beijing, China

* Correspondence: 13780198842@eye.ac.cn

† These authors contributed equally to this work.

Abstract: As the most serious of the many worse new pathological changes caused by diabetes, there are many risk factors for the occurrence and development of DR. It mainly includes hyperglycemia, hypertension, hyperlipidemia and so on. Among them, hyperglycemia is the most critical cause, which plays a key role in the pathological changes of DR. High-sucrose diets (HSDs) lead to elevated blood glucose levels in vivo, which, through oxidative stress, inflammation, the production of AGEs and VEGF, causes plenty of pathological damages to the retina and ultimately bring about loss of vision. The existing therapies for DR primarily target the terminal stage of the disease, when irreversible visual impairment has appeared. Therefore, early prevention is particularly critical. Early prevention of DR-related vision loss requires adjustments to dietary habits, mainly by reducing sugar intake. This article primarily discusses the risk factors, pathophysiological processes, and molecular mechanisms associated with the development of DR caused by HSDs. It aims to raise awareness of the crucial role of diet in the occurrence and progression of DR, promote timely changes in dietary habits, prevent vision loss, and improve the quality of life. The aim is to make people aware of the importance of diet in the occurrence and progression of DR. According to the dietary modification strategies we give, patients can change their poor eating habits timely, avoid the retinopathy that can be avoided theoretically, and obtain an excellent outcome.

Keywords: high-sucrose diet; diabetic retinopathy; hyperglycaemia; dietary modification strategies

1. Introduction

Carbohydrates are one of the three major macronutrients essential for human energy production and are an important source of energy for maintaining normal physiological activities and functions[1]. However, long-term excessive intake of carbohydrates, which is a high-sucrose diet (HSD), especially foods containing high amounts of glucose and fructose, can lead to increased sugar intake and cause metabolic disorder, cardiovascular abnormalities[2], neurological disturbances[1,3] and inflammation[4–6]. This can manifest as hyperglycaemia[7], obesity[8–10], insulin resistance[8], hypertension[11], impaired cardiac metabolic function[12], mood and behavioral disorders, impaired working memory[13], food addiction[1,14], intestinal infections, and microbial dysbiosis [15,16]. In addition, HSDs can also contribute to psychopathology[17]. A HSD in women of childbearing age and during pregnancy can impact the memory processes of offspring[18], and may contribute to a predisposition to developing mental disorders in early life or adulthood.

As the most severe of the many worse new pathological microvascular changes caused by diabetes, diabetic retinopathy (DR) is the most leading pathogeny of preventable vision loss in the

young especially working-age people worldwide[19].The International Diabetes Federation (IDF) estimates that by 2045, the global population aged 20-79 with diabetes will rise to 780 million[20]. It is estimated that 160 million adults will become DR sufferers[21].Clinically, the confirmation of DR is primarily on the basis of the abnormal appearance of retinal vessels[22,23](see Figure 1). There are two main disease stages. The first is NPDR(non-proliferative diabetic retinopathy), which is characterized by progressive retinal microvascular lesions, and then progresses to the PDR(proliferative diabetic retinopathy) stage, which is characterized by neovascularization[24,25]. NPDR involves retinal changes such as hemorrhages, microaneurysms and hard exudates, with the patients usually being asymptomatic. As NPDR progresses and retinal ischemia occurs, leading to neovascularization of the retina, it advances to PDR, and patients may experience severe visual impairment[24,25]. Additionally, diabetic macular edema (DMO) refers to the thickening of the posterior pole of the retina and can occur at any stage[25]. Due to the late onset of clinical symptoms, early histological changes are challenging to detect during clinical examinations, and once detected, irreversible vision loss often occurs. Beyond vision impairment, the degree of retinal damage in diabetic suffers is significantly related with future risks of cerebrovascular accidents, myocardial infarction, and mortality[26]. Therefore, for patients with DR, earlier intervention, timely diagnosis and treatment are necessary to reduce the potential risk of vision loss[27]. Controlling hyperglycemia is the most crucial preventive measure [28].

The risk factors that primarily contribute to the occurrence and progression of DR include hyperglycaemia, hypertension, hyperlipidemia, diabetes duration and so on. Among these factors, hyperglycaemia is the key factor that can trigger all the related abnormalities. Although there are currently many medical treatment options targeted to DR, they are only applicable to the terminal stage of the disease and often come with severe adverse reactions[29], posing a significant economic burden on patients and the global public healthcare system. Improper control and management of DR can lead to late-stage DR[30], which may result in blindness and increase the burden of DR disease[31]. Studies have shown that maintaining normal blood glucose levels can effectively delay the occurrence and progression of DR[32]. A high-sucrose diet and the resultant hyperglycemia exacerbate the occurrence and progression of DR, leading to vision impairment in patients.

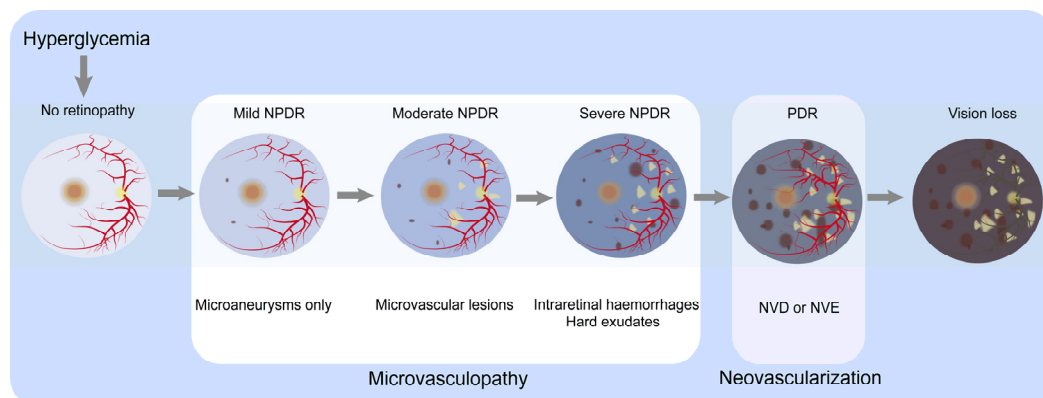


Figure 1. Classification of DR by severity and the major clinicopathological features associated with different stages. In no retinopathy, the retina shows no microvascular abnormalities. Hyperglycemia damages the normal retina, resulting in mild NPDR, characterized by microaneurysms. In moderate NPDR, microaneurysms and other microvascular abnormalities are observed. Severe NPDR is basically characterized by one or a combination of the following: (1) more than 20 retinal hemorrhages; (2) venous beading; (3) retinal microvascular abnormalities but not meeting the criteria for PDR. The progression to the PDR stage is marked by the appearance of NVD or NVE, along with preretinal or vitreous hemorrhage. Microvasculopathy is the main characteristic of the NPDR stage, while neovascularization is the main characteristic of the PDR stage. As the condition worsens, patients experience visual loss. Abbreviations: neovascularization of optic disc, NVD; neovascularization of elsewhere, NVE; non-proliferative diabetic retinopathy, NPDR; proliferative diabetic retinopathy, PDR.

2. Risk Factors for the Occurrence and Development of DR

The primary connected factor is blood glucose levels[33].

2.1. Hyperglycemia

Hyperglycemia significantly affects DR[34]and is the dominating pathogeny of DR progression[35,36]. Glycated hemoglobin (HbA1c) is a marker applied to measure blood glucose control[37], and its blood level represents the average blood glucose concentration over the past 120 days[38]. The strict control of HbA1c levels below 7% can lower the risk of DR occurrence and development[22]. Every 1% reduction in HbA1c reduces the risk of retinopathy and blindness respectively by 40% and 15%[39]. There is a remarkable fact that earlier blood glucose control is better because long-term exposure to high blood glucose conditions can cause irreversible retinal damage even after blood glucose control is regained[40].

2.2. Hypertension

Hypertension is defined as blood pressure \geq 130/80 mmHg[41]. Strictly controlling the pressure of blood can reduce the risk of DR and vision loss[42], especially when maintaining HbA1c levels around 7% simultaneously[43].

2.3. Hyperlipidemia

Intensifying blood glucose control in combination with treating hyperlipidemia can slow down the progression of DR[44].

2.4. Duration of Diabetes Mellitus

The earlier the patients with diabetes the greater risk of DR[45].

2.5. Other Risk Factors

Ethnic origin (such as Hispanic, South Asian), pregnancy, and puberty are additional risk factors for DR.

3. Pathophysiology of DR

DR primarily involves retinal microangiopathy, with histological alterations occurring before the emergence of various obvious clinical symptoms. Persistent hyperglycemia assumes a pivotal role in the pathological advancement of DR by instigating and maintaining various other factors that collectively influence the development of DR.

DR encompasses a classification system comprising two fundamental clinical stages: NPDR and PDR. NPDR signifies the initial phase of DR, whereas PDR confers an escalated propensity towards vision loss relative to individuals with NPDR[46]. The primary pathology of DR involves the microvascular changes in the retinal capillaries, which are comprised of pericytes, basement membranes, and endothelial cells. Pericytes possess contractile properties, maintaining capillary tone, controlling capillary diameter, regulating blood flow in the capillaries and preserving their stability[47]. Endothelial cells form tight junctions creating an internal barrier to prevent substances from leaking out of the blood vessels[48]. During the initial phases of DR progression, elevated blood glucose levels instigate pericyte death, resulting in capillary acellular areas and the development of localized or diffuse microaneurysms due to capillary rarefaction[49]. High blood glucose damages endothelial cells, compromising the integrity of the internal barrier and causing vascular leakage[50]. Increased thickness of the basement membrane induces luminal constriction within the vasculature and vascular stiffness, thereby promoting vascular rigidity and impeding the binding efficacy of growth factors. The loss of these two cell types leads to capillary leakage and occlusion, resulting in non-perfused areas. As the disease progresses, arteriolar involvement occurs, and dilated retinal arterioles accelerate the clinical manifestation of diabetic retinopathy, including edema and

hemorrhage [51]. The non-perfused areas further expand, causing capillary dilation and the formation of venous beading, which is known as intraretinal microvascular abnormalities[39]. NPDR is characterized by the various manifestations including small dilations of blood vessels in the microvascular network, the presence of blood leakage, irregularities in the veins of the retinal vasculature, the reduction of function capillaries, and intraretinal microvascular abnormalities[52]. Notably, retinal arteriolar dilatation potentially serves as an early subclinical marker of microvascular dysfunction[22].

Extensive death of retinal microvascular cells leads to retinal hypoxia, triggering the upregulation of growth factors[53]. Various growth factors act synergistically, resulting in the formation of neovascularization[54], marking the transition to the proliferative stage of DR. Neovascularization continues to grow and forms fibrous tissue membranes. Subsequently, the vitreous is adhered by these fibrous tissues. Contraction of the vitreous can cause hemorrhage, and the contracted fibrous tissue leads to retinal traction and detachment, ultimately resulting in vision loss[55].

Additionally, during the initial phases of the ailment, there is an associated impairment of both retinal ganglion cells and glial cells[56]. Neurologic and glial dysfunction occur concurrently with vascular abnormalities and generally precede obvious microvascular damage[57].

4. Molecular Mechanisms of HSD-Induced Development of DR

Sugar (sucrose) includes fructose and glucose[58]. A HSD can result in elevated levels of glucose in the bloodstream. Elevated blood glucose levels are pivotal in the pathogenesis of vascular complications associated with diabetes. DR represents the predominant complication of the microvasculature. Extensive research has demonstrated that hyperglycemia, especially long-term sustained high blood glucose levels, serves as a central factor in the occurrence and progression of DR, inducing a variety of biochemical abnormalities[59,60](Figure 2).

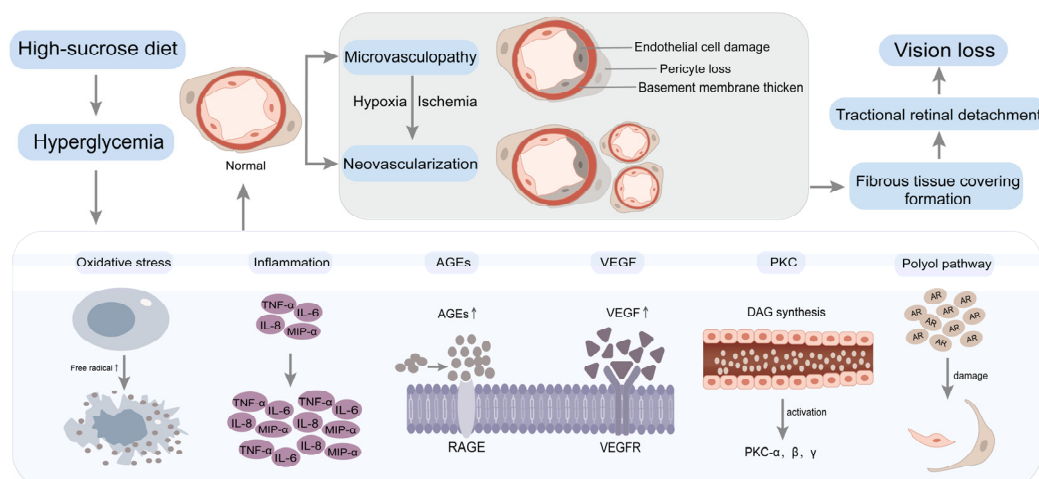


Figure 2. Hyperglycemia induces biochemical changes in DR. A high-sucrose diet leads to increased blood glucose levels, resulting in hyperglycemia. Prolonged and sustained high blood glucose levels contribute to retinal microvasculopathy through multiple pathways, including oxidative stress, inflammation, AGEs, VEGF, PKC and the polyol pathway. Significant apoptotic events within the retinal capillary cells instigate retinal hypoxia and subsequent neovascularization. The proliferation of abundant neovascularization engenders the development of fibrous tissue covering, leading to tractional retinal detachment. Ultimately, this culminates in vision loss. Abbreviations: advanced glycation end products, AGEs; receptor for advanced glycation end products, RAGE; vascular endothelial growth factor, VEGF; vascular endothelial growth factor receptor, VEGFR; protein kinase C, PKC; diacylglycerol, DAG; aldose reductase, AR; tumour necrosis factor- α , TNF- α ; macrophage inflammatory protein-1 α , MIP- α ; interleukin-6, IL-6; interleukin-8, IL-8.

4.1. Oxidative Stress

Under optimal physiological circumstances, the body maintains a meticulous oxidative-reductive equilibrium. However, disruption ensues when there is a disproportionate interplay between the generation and elimination of free radicals, thereby perturbing this dynamic equilibrium and instigating an upsurge in free radical production[61]. Consequently, oxidative stress manifests itself[62]. Given the retina's unique characteristics, characterized by protracted light exposure, heightened oxygen consumption, and reliance on glucose oxidation, it becomes highly susceptible to oxidative stress[63]. The confluence of hyperglycemia precipitates the accrual of reactive oxygen species (ROS) within the retina, thereby subjecting retinal and capillary cells to oxidative stress[50,64,65]. Subsequently, diverse molecular mechanisms are initiated to cause oxidative stress on retinal well-being, including the activation of the PKC pathway, formation of AGEs, initiation of the polyol pathway, facilitation of the hexosamine pathway[66], as well as the induction of inflammatory cascades[62,67,68].

4.2. Inflammation

Hyperglycaemia disrupts the balance between pro-inflammatory and anti-inflammatory responses maintained by microglia, leading to a state of inflammation[69]. This inflammatory state increases vascular permeability and can activate leukocytes, leading to capillary blockages and local retinal ischemia[70]. Elevated concentrations of pro-inflammatory cytokines and chemokines, encompassing various inflammatory mediators, have been detected in ocular samples from DR patients[71], and upregulated pro-inflammatory cytokines may directly or indirectly induce angiogenesis[72,73]. Research has shown that alleviating high glucose-induced inflammation in DR can be achieved by either activating[74–76] or inhibiting[77] specific signaling pathways.

4.3. Advanced Glycation End Products (AGEs)

Persistent hyperglycemia triggers the initiation of non-enzymatic glycation in macromolecules, encompassing proteins, consequently leading to an increase in AGEs[62]. AGEs can increase the levels of cell adhesion molecules within retinal endothelial cells, resulting in capillary occlusion[78]. They may also induce apoptosis of retinal pericytes through oxidative stress mechanisms[79]. The deposition of AGE adducts within the retinal microvascular basement membrane can cause functional impairments, such as perturbation of endothelial junctions and heightened vascular permeability[80], leading to endothelial damage and extravasation of intravascular substances. Additionally, AGEs can cause neuronal abnormalities[78].

4.4. Vascular Endothelial Growth Factor (VEGF)

In DR, progressive loss of capillaries leads to retinal hypoxia, inducing the expression of vascular endothelial growth factor (VEGF)[81]. In the context of DR, the progressive decline of capillary density culminates in retinal hypoxia, prompting the upregulation of VEGF. Subsequently, a robust neovascular response is triggered, particularly during the advanced stages of DR [82], characterized by the excessive neovascularization[83]. VEGF activates PKC, orchestrating the dismantling of tight junctions, perturbation of the blood-retinal barrier (BRB), and increased permeability of capillaries[84,85].

4.5. Protein Kinase C (PKC)

Hyperglycaemia cause the buildup of diacylglycerol (DAG), activating various PKC isoforms in the retina[86,87]. PKC promotes the generation of reactive oxygen species (ROS), leading to amplified vascular permeability, upregulation of VEGF expression[88], modifications in blood flow, and alterations in enzyme activity[89]. These intricate processes contribute to retinal cell apoptosis, the emergence of capillaries devoid of cellular components, and the disturbance of the functionality of the BRB[90].

4.6. Polyol Pathway

Hyperglycaemia triggers the activation of the polyol pathway across diverse cellular populations, leading to excessive aldose reductase activity[66]. Consequently, retinal endothelial cells, pericyte cells, and other retinal cell types endure detrimental effects mediated by oxidative stress[91], increased cellular osmotic pressure, and advanced glycation end product (AGE) formation[92]. It can also lead to abnormalities in neuroglia and neurons[93].

It is important to note that hyperglycaemia does not singularly cause retinal damage in DR through only one of the aforementioned pathways. Rather, these pathways interact and influence each other, collectively contributing to vision loss in DR.

5. Dietary Modification Strategies

Currently, the main therapeutic approaches for DR include laser photocoagulation, intravitreal administration of pharmacological agents targeting VEGF, intravitreal injection of corticosteroids, and vitrectomy[19,24]. However, these approaches primarily target the advanced phases of DR and can only partially alleviate the extent of visual decline; they cannot reverse vision damage. Additionally, these treatments are associated with high costs, multiple side effects, and poor patient compliance. Therefore, early prevention is the most effective, cost-effective, and beneficial primary choice for delaying vision loss in DR. Among the early prevention methods, dietary modification is one of the simplest and easiest to adhere to.

Since the significant implication of hyperglycemia in the pathogenesis and advancement of DR, dietary modification should focus on reducing sugar consumption. According to guidelines established by The World Health Organization (WHO), limiting the consumption of free sugars to less than 10% of the overall energy intake is recommended. Ideally, it can be controlled below 5% when feasible. Although slight variations exist among different countries and age groups, it is advised to minimize sugar consumption as much as possible. It is imperative to acknowledge that free sugars do not encompass naturally occurring sugars found in fresh fruits, vegetables, and milk. Authentic free sugars exclusively include monosaccharides and disaccharides introduced through diverse food manufacturing procedures, commonly recognized as added sugars. Naturally existing sugars in honey and fruit juice also fall under the classification of free sugars.[94].The medical research institute advocates for a maximum threshold of 25% of daily caloric consumption as the recommended limit for added sugar intake[95].

5.1. Fruits and Vegetables

Fruits and vegetables hold significant importance as sources of a diverse array of nutrients and dietary fibers[96]. Research indicates that increasing the consumption of fruits and vegetables can effectively diminish the likelihood of developing DR[97,98]and provide protective effects against DR[99]. Fruits and leafy green vegetables contribute to delaying DR progression and mitigating visual impairment[23]. To promote better blood glucose control and mitigate inflammation in sufferers, it is recommended to consume fruits and vegetables that abound in flavonoids, such as leafy greens, fruits and berries[100,101]. These can protect against the demise of retinal ganglion cells (RGCs) triggered by oxidative stress[102].

5.2. Fish

Polyunsaturated fatty acids (PUFAs) can protect the vision of patients with DR[103], and reduce the severity of DR condition[104]. The retina contains a significant concentration of LC ω 3PUFAs that showcase notable anti-inflammatory and antiangiogenic properties. Daily intake of at least 500mg of dietary LC ω 3PUFAs can decrease the likelihood of visual impairment in patients of DR[105–109]. Fish, being an excellent source of omega-3 polyunsaturated fatty acids, can reduce the formation of pathological blood vessels[110,111]. Increasing fish consumption can slow down the progression of DR[112,113], thereby reducing the probability of developing severe manifestations of the condition[114].

5.3. Vitamins

5.3.1. Vitamin A

The administration of vitamin A has been observed to exhibit protective properties against retinal damage induced by hyperglycaemia and contribute to the delay in retinal neovascularization formation[115]. Serum levels of vitamin A are correlated with DR[116], emphasizing its potential relevance in assessing the condition.

5.3.2. Vitamin B

Vitamin B3 is characterized by its existence in two distinct forms, namely niacin and niacinamide, each exhibiting unique molecular structures and biological functions. Niacinamide can reduce oxidative DNA damage, promote DNA repair, and then alleviate retinal neurodegeneration in diabetic patients[117]. However, high-dose niacin may increase the risk of insulin resistance[118]. Substantial dietary consumption of vitamin B6 has been demonstrated to effectively reduce the likelihood of developing DR[119]. Diminished levels of vitamin B12 in the serum have been correlated with an augmented susceptibility to DR[120], with some indications suggesting its potential role as a distinct risk factor contributing to suffering condition.[121].

Additionally, vitamins B1, B7, and B9 also have exhibited significant therapeutic potential in addressing retinal lesions associated with diabetes, underscoring their significant role in managing these pathological conditions[122,123].

5.3.3. Vitamin D

Vitamin D has properties such as lowering blood glucose, antioxidation, anti-inflammation, antiangiogenesis, and neuroprotection[124–127]. A compelling correlation between serum vitamin D levels and the occurrence or seriousness of DR[128–136]. A prospective study found that maintaining adequate optimal levels of vitamin D in the bloodstream can prevent the deleterious impact of diabetes on the intricately interconnected microvasculature, including DR[137]. The association between serum levels of 25-hydroxyvitamin D and DR was supported by pertinent studies [138–140]. When the concentration of serum 25-hydroxyvitamin D falls below the threshold of 15.57 ng/ml, the risk of visual impairment doubles in DR patients[141]. 1,25-dihydroxyvitamin D₃ may serve as a potential protective role in retina by regulating inflammatory responses[142], which possesses inhibitory prowess against the activity of retinal VEGF and transforming growth factor[143]. Fatty fish and fish oil, notably both salmon and sardines, are designated as prominent dietary reservoirs of vitamin D[124].

5.3.4. Vitamin E

Elevated blood glucose levels have been implicated as a pivotal contributor in the escalation of oxidative stress, and vitamin E can prevent lipid peroxidation, improve oxidative stress[144], and reduce the severity of diabetes-related complications[145]. Additionally, Vitamin E can significantly decrease retinal capillary basement membrane thickness, protecting against retinal damage associated with DR, caused by hyperglycaemia-induced oxidative stress[146,147].

5.4. Non-Vitamin A Carotenoids

Carotenoids, which are indigenous antioxidants, exhibit both anti-inflammatory and antioxidant qualities. They can reduce inflammation and oxidative stress caused by high blood glucose, Their remarkable impact involves mitigating the inflammatory response and oxidative burden arising from hyperglycemia, thereby slowing down the occurrence and development of DR[148,149]. The main carotenoids include lutein, zeaxanthin, astaxanthin, and lycopene.

The macula, a region in the retina, showcases a profound abundance of lutein and zeaxanthin[150]. These two nutrients, well recognized as the macular pigment, possess antioxidant, anti-inflammatory, antiangiogenic, neuroprotective, and blue light-filtering properties in the

eyes[151–157]. They can significantly improve retinal vascular changes caused by high blood glucose[158]and enhance macular function[159], thereby protecting and alleviating DR[160–164]. Carotenoid dietary intake is significantly reduced in DR patients[165]. Since the human body cannot synthesize carotenoids, it is recommended that DR patients obtain them from food sources. Lutein predominantly resides within verdant leafy vegetables such as broccoli, spinach, and lettuce[166]. Zeaxanthin is mainly found in corn and corn products [166], while astaxanthin is primarily found in seafood and algae[167,168].

5.5. Flavonoids

Flavonoids are the preeminent polyphenols ubiquitously interspersed within our nutritional diet and possess anti-inflammatory and antioxidant properties. They can alleviate hyperglycaemia, inhibit oxidative stress and inflammation processes[169], regulate carbohydrate and fat metabolism[170], and slow down visual loss in DR[171,172].

Anthocyanins are a class of flavonoids and important natural bioactive pigments[173]. They are mainly found in berries and cherries[174], such as wild blueberries, cranberries, raspberry seeds, and strawberries[175]. Cyanidin-3-O-glucoside (C3G) is one type of anthocyanin and exhibits strong antioxidant and anti-inflammatory effects. It exhibits a therapeutic intervention for ameliorating inflammation triggered by elevated glucose levels, along with mitigating angiogenesis in DR[176]. Blueberry anthocyanins can enhance the integrity of the BRB compromised by oxidative stress[177], adverse consequences inflicted by oxidative stress and inflammation on retinal tissue homeostasis[178], and inhibit the progression of DR[179]. Blueberry anthocyanin extract protects the capillaries of retina from elevated glucose levels induced damage through antioxidant and anti-inflammatory mechanisms[180].

5.6. Dietary Fiber

Dietary fiber manifests an inhibitory impact on the kinetics of monosaccharides and fatty acid digestion and absorption, impeding their prompt assimilation, thereby reducing calorie absorption[181]. The utilization of this therapeutic approach demonstrated a reduction in the likelihood of DR[182]and has a protective effect against existing cases[99]. Investigations have elucidated that individuals with low dietary fiber intake have a higher risk of vision-threatening DR [183].

5.7. Other Nutrients

Whole grains are rich in soluble and insoluble fiber, which can lower blood glucose levels, ameliorate blood lipid levels, and optimize gut microbiota[184]. The consistent incorporation of cheese and whole wheat bread into the diet has been found to correlate with a reduced likelihood of DR advancement[185]. Goji berries can increase the concentrations of lutein and zeaxanthin, ameliorating high glucose-induced microstructure and physiological damage in the retina[186]. Furthermore, it confers protective effects on the retina[187]. Coconut water can lower blood sugar levels and mitigate DR damage[188].

6. Dietary Recommendations for DR Patients - The Mediterranean Diet(MedDiet)

The Mediterranean diet(MedDiet), renowned for its global recognition, originates from the Mediterranean coast regions. This dietary pattern is distinguished by its emphasis on abundant consumption of plant-derived foods including fruits, vegetables, legumes, grains, and nuts, preferably fresh and minimally processed. It also includes a significant intake of olive oil as the foremost contributor of fat, desired consumption of dairy products like cheese and yogurt, prudent consumption of fish and poultry, and moderate alcohol consumption[189–191](Figure 3).

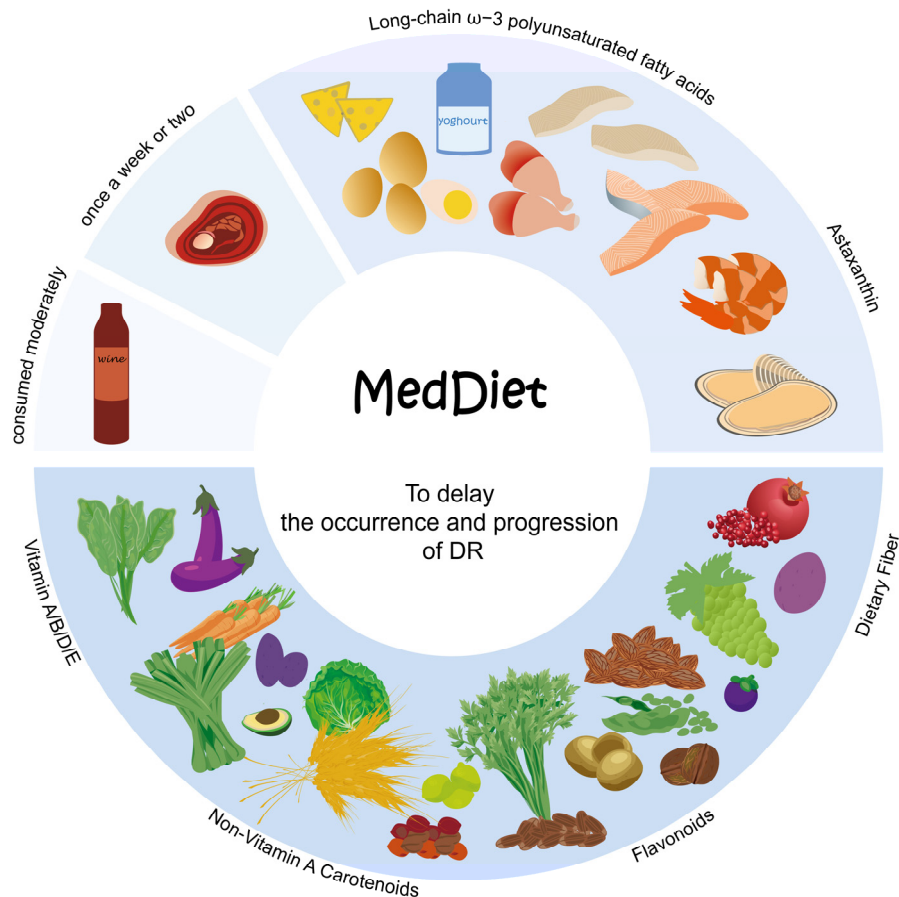


Figure 3. The distinguishing attributes of MedDiet. First, an adequate intake of a huge variety of plant-based foods that are minimally processed, seasonally fresh, and locally grown. This includes fruits, vegetables, minimally refined grains, beans and nuts, as they provide a rich array of nutrients such as vitamins, non-vitamin A carotenoids, flavonoids, and dietary fiber. Incorporate fresh fruits as a regular dessert option. Second, a moderate intake of local products derived from milk, primarily yogurt, alongside fish and seafood, to obtain nutrients like LC ω 3PUFAs and astaxanthin. Third, limit red meat including processed variants consumption to once a week or every two weeks, while allowing moderate wine consumption with meals. The Mediterranean diet offers a variety of nutrients that can help lower blood glucose levels, reduce oxidative stress, and mitigate inflammation, thereby exerting a significant impact on retarding the occurrence and progression of DR.

MedDiet is rich in low glycemic foods, vitamins, minerals, antioxidants, fiber, monounsaturated fatty acids (MUFAs), PUFAs, and probiotics. Research has evidenced the ability of this intervention to result in reduced levels of HbA1c, concentrations of postprandial blood glucose, oxidative stress, inflammation, and improve lipid profiles and gut immune function[190,192]. Numerous studies have demonstrated that adhering to MedDiet helps reduce the morbidity of DR and prevents vision loss[193–197].

7. Other Lifestyle Recommendations

Hypertension is recognized as an additional contributing factor to the incidence of DR, and reducing elevated blood pressure levels confers valuable preventive benefits against DR[198]. Dietary Pattern to Stop Hypertension (DASH) diet has been linked to the management of hypertension and shares similarities with the Mediterranean diet. It also possesses anti-inflammatory and antioxidant properties, which can improve blood glucose control[199]. Calorie restriction and intermittent fasting have demonstrated potency in reducing blood glucose levels in the blood circulation[200]. Maintaining a low-calorie and low-sodium intake is also beneficial for DR[201]. Hyperglycaemia, hypertension, and dyslipidemia represent a triad of modifiable primary risk factors for severe vision

loss in sufferers[202]. Achieving optimal management of glycemic control, blood pressure, and lipid profiles can reduce diabetes-related vision impairment[203,204].

Furthermore, engaging in appropriate physical exercises, such as aerobic activities, strength training, yoga, can mitigate the likelihood of DR occurrence and progression[205,206].

8. Conclusions

Diabetes manifests as the foremost prevailing metabolic disorder, with diabetic retinopathy emerging as its predominant and consequential complication. Additionally, this ocular condition serves as the primary contributor to avoidable vision loss among the working-age cohort. The occurrence and advancement of DR are influenced by a variety of risk elements, including hyperglycemia, hypertension, dyslipidemia, and duration of diabetes. Notably, hyperglycemia assumes a pivotal role as the primary driver behind the occurrence and progression of DR. Therefore, It's crucial that gaining a comprehensive understanding of the underlying disease mechanisms through which HSDs intricately contribute to the occurrence and progression of DR. Given the inconspicuous presentation of clinical indicators amidst the nascent stages of microvascular and neuronal compromise in DR, it is challenging to raise awareness among patients. However, once clinical symptoms manifest, vision loss becomes inevitable. Existing treatment options can only partially alleviate the degree of visual impairments but cannot reverse visual damage. Therefore, early intervention is of utmost importance.

Among various early intervention methods, dietary intervention is the most cost-effective, patient-friendly, least harmful, and highly beneficial approach. We primarily elucidate the complex pathogenesis of DR and the intricate biochemical mechanisms by which a high-sugar diet leads to irreversible vision loss in DR. This aims to raise awareness about the importance of daily dietary habits in the occurrence and advancement of DR. Moreover, we underscore the pronounced impact of specific nutrients in delaying the development of DR, providing dietary modification strategies for DR patients as references. We recommend DR patients minimize their daily sugar intake while controlling the three major high-risk factors of glycemic, blood pressure, and lipid levels to mitigate the potential hazards of vision loss as much as possible.

Author Contributions: Conceptualization, C.Y.; investigation, C.Y.; writing—original draft preparation, C.Y. and Y.Y.; writing—review and editing, C.Y. and J.A.; supervision, J.A. All authors have read and agreed to the published version of the manuscript.

Funding: This work was supported by Wenzhou Basic Scientific Research Project [grant number Y2020356].

Institutional Review Board Statement: Not applicable.

Informed Consent Statement: Not applicable.

Data Availability Statement: No new data were created or analyzed in this study. Data sharing is not applicable to this article.

Acknowledgments: In this section, you can acknowledge any support given which is not covered by the author contribution or funding sections. This may include administrative and technical support, or donations in kind (e.g., materials used for experiments).

Conflicts of Interest: The authors declare no conflicts of interest.

References

1. Witek, K.; Wydra, K.; Filip, M. A High-Sugar Diet Consumption, Metabolism and Health Impacts with a Focus on the Development of Substance Use Disorder: A Narrative Review. *Nutrients* **2022**, *14*, doi:10.3390/nu14142940.
2. Rippe, J.M.; Angelopoulos, T.J. Sugars, obesity, and cardiovascular disease: results from recent randomized control trials. *European Journal of Nutrition* **2016**, *55*, 45-53, doi:10.1007/s00394-016-1257-2.

3. Sung, H.; Vesela, I.; Driks, H.; Ferrario, C.R.; Mistretta, C.M.; Bradley, R.M.; Dus, M. High-sucrose diet exposure is associated with selective and reversible alterations in the rat peripheral taste system. *Curr Biol* **2022**, *32*, 4103-4113 e4104, doi:10.1016/j.cub.2022.07.063.
4. Ma, X.; Nan, F.; Liang, H.; Shu, P.; Fan, X.; Song, X.; Hou, Y.; Zhang, D. Excessive intake of sugar: An accomplice of inflammation. *Front Immunol* **2022**, *13*, 988481, doi:10.3389/fimmu.2022.988481.
5. Yu, S.; Zhang, G.; Jin, L.H. A high-sugar diet affects cellular and humoral immune responses in *Drosophila*. *Exp Cell Res* **2018**, *368*, 215-224, doi:10.1016/j.yexcr.2018.04.032.
6. Tang, L.; Xu, G.T.; Zhang, J.F. Inflammation in diabetic retinopathy: possible roles in pathogenesis and potential implications for therapy. *Neural regeneration research* **2023**, *18*, 976-982, doi:10.4103/1673-5374.355743.
7. Palanker Musselman, L.; Fink, J.L.; Narzinski, K.; Ramachandran, P.V.; Sukumar Hathiramani, S.; Cagan, R.L.; Baranski, T.J. A high-sugar diet produces obesity and insulin resistance in wild-type *Drosophila*. *Disease Models & Mechanisms* **2011**, *4*, 842-849, doi:10.1242/dmm.007948.
8. Zhang, S.; Guo, F.; Yu, M.; Yang, X.; Yao, Z.; Li, Q.; Wei, Z.; Feng, K.; Zeng, P.; Zhao, D., et al. Reduced Nogo expression inhibits diet-induced metabolic disorders by regulating ChREBP and insulin activity. *J Hepatol* **2020**, *73*, 1482-1495, doi:10.1016/j.jhep.2020.07.034.
9. Stanhope, K.L. Sugar consumption, metabolic disease and obesity: The state of the controversy. *Critical reviews in clinical laboratory sciences* **2016**, *53*, 52-67, doi:10.3109/10408363.2015.1084990.
10. Malik, V.S.; Schulze, M.B.; Hu, F.B. Intake of sugar-sweetened beverages and weight gain: a systematic review. *The American journal of clinical nutrition* **2006**, *84*, 274-288, doi:10.1093/ajcn/84.1.274.
11. Lustig, R.H.; Schmidt, L.A.; Brindis, C.D. The toxic truth about sugar. *Nature* **2012**, *482*, 27-29, doi:10.1038/482027a.
12. Apaijai, N.; Arinno, A.; Palee, S.; Pratchayasakul, W.; Kerdphoo, S.; Jaiwongkam, T.; Chunchai, T.; Chattipakorn, S.C.; Chattipakorn, N. High-Saturated Fat High-Sugar Diet Accelerates Left-Ventricular Dysfunction Faster than High-Saturated Fat Diet Alone via Increasing Oxidative Stress and Apoptosis in Obese-Insulin Resistant Rats. *Mol Nutr Food Res* **2019**, *63*, e1800729, doi:10.1002/mnfr.201800729.
13. Hirai, S.; Miwa, H.; Tanaka, T.; Toriumi, K.; Kunii, Y.; Shimbo, H.; Sakamoto, T.; Hino, M.; Izumi, R.; Nagaoka, A., et al. High-sucrose diets contribute to brain angiopathy with impaired glucose uptake and psychosis-related higher brain dysfunctions in mice. *Sci Adv* **2021**, *7*, eabl6077, doi:10.1126/sciadv.abl6077.
14. Avena, N.M.; Rada, P.; Hoebel, B.G. Evidence for sugar addiction: behavioral and neurochemical effects of intermittent, excessive sugar intake. *Neurosci Biobehav Rev* **2008**, *32*, 20-39, doi:10.1016/j.neubiorev.2007.04.019.
15. Sun, S.; Araki, Y.; Hanzawa, F.; Umeki, M.; Kojima, T.; Nishimura, N.; Ikeda, S.; Mochizuki, S.; Oda, H. High sucrose diet-induced dysbiosis of gut microbiota promotes fatty liver and hyperlipidemia in rats. *J Nutr Biochem* **2021**, *93*, 108621, doi:10.1016/j.jnutbio.2021.108621.
16. Liu, J.; Liu, H.; Teng, Y.; Qin, N.; Ren, X.; Xia, X. A high-sucrose diet causes microbiota composition shift and promotes the susceptibility of mice to *Salmonella Typhimurium* infection. *Food & Function* **2023**, *14*, 2836-2846, doi:10.1039/D2FO03467K.
17. Eudave, D.M.; BeLow, M.N.; Flandreau, E.I. Effects of high fat or high sucrose diet on behavioral-response to social defeat stress in mice. *Neurobiol Stress* **2018**, *9*, 1-8, doi:10.1016/j.ynstr.2018.05.005.
18. Mizera, J.; Kazek, G.; Niedzielska-Andres, E.; Pomierny-Chamiolo, L. Maternal high-sugar diet results in NMDA receptors abnormalities and cognitive impairment in rat offspring. *FASEB J* **2021**, *35*, e21547, doi:10.1096/fj.202002691R.
19. Kollias, A.N.; Ulbig, M.W. Diabetic retinopathy: Early diagnosis and effective treatment. *Dtsch Arztebl Int* **2010**, *107*, 75-83; quiz 84, doi:10.3238/arztebl.2010.0075.
20. Sun, H.; Saeedi, P.; Karuranga, S.; Pinkepank, M.; Ogurtsova, K.; Duncan, B.B.; Stein, C.; Basit, A.; Chan, J.C.N.; Mbanya, J.C., et al. IDF Diabetes Atlas: Global, regional and country-level diabetes prevalence estimates for 2021 and projections for 2045. *Diabetes Res Clin Pract* **2022**, *183*, 109119, doi:10.1016/j.diabres.2021.109119.
21. Teo, Z.L.; Tham, Y.C.; Yu, M.; Chee, M.L.; Rim, T.H.; Cheung, N.; Bikbov, M.M.; Wang, Y.X.; Tang, Y.; Lu, Y., et al. Global Prevalence of Diabetic Retinopathy and Projection of Burden through 2045: Systematic Review and Meta-analysis. *Ophthalmology* **2021**, *128*, 1580-1591, doi:10.1016/j.ophtha.2021.04.027.
22. Cheung, N.; Mitchell, P.; Wong, T.Y. Diabetic retinopathy. *Lancet* **2010**, *376*, 124-136, doi:10.1016/S0140-6736(09)62124-3.

23. Broadhead, G.K.; Hong, T.; Bahrami, B.; Flood, V.; Liew, G.; Chang, A.A. Diet and risk of visual impairment: a review of dietary factors and risk of common causes of visual impairment. *Nutr Rev* **2021**, *79*, 636-650, doi:10.1093/nutrit/nuaa100.
24. Wang, W.; Lo, A.C.Y. Diabetic Retinopathy: Pathophysiology and Treatments. *Int J Mol Sci* **2018**, *19*, doi:10.3390/ijms19061816.
25. Mohamed, Q.; Gillies, M.C.; Wong, T.Y. Management of diabetic retinopathy: a systematic review. *JAMA* **2007**, *298*, 902-916, doi:10.1001/jama.298.8.902.
26. Modjtahedi, B.S.; Wu, J.; Luong, T.Q.; Gandhi, N.K.; Fong, D.S.; Chen, W. Severity of Diabetic Retinopathy and the Risk of Future Cerebrovascular Disease, Cardiovascular Disease, and All-Cause Mortality. *Ophthalmology* **2021**, *128*, 1169-1179, doi:10.1016/j.ophtha.2020.12.019.
27. Ting, D.S.; Cheung, G.C.; Wong, T.Y. Diabetic retinopathy: global prevalence, major risk factors, screening practices and public health challenges: a review. *Clin Exp Ophthalmol* **2016**, *44*, 260-277, doi:10.1111/ceo.12696.
28. Fung, T.H.; Patel, B.; Wilmot, E.G.; Amoaku, W.M. Diabetic retinopathy for the non-ophthalmologist. *Clin Med (Lond)* **2022**, *22*, 112-116, doi:10.7861/clinmed.2021-0792.
29. Hernández, C.; Simó-Servat, A.; Bogdanov, P.; Simó, R. Diabetic retinopathy: new therapeutic perspectives based on pathogenic mechanisms. *Journal of Endocrinological Investigation* **2017**, *40*, 925-935, doi:10.1007/s40618-017-0648-4.
30. Mookiah, M.R.; Acharya, U.R.; Chua, C.K.; Lim, C.M.; Ng, E.Y.; Laude, A. Computer-aided diagnosis of diabetic retinopathy: a review. *Comput Biol Med* **2013**, *43*, 2136-2155, doi:10.1016/j.compbiomed.2013.10.007.
31. Tan, T.-E.; Wong, T.Y. Diabetic retinopathy: Looking forward to 2030. *Frontiers in Endocrinology* **2023**, *13*, doi:10.3389/fendo.2022.1077669.
32. The Effect of Intensive Treatment of Diabetes on the Development and Progression of Long-Term Complications in Insulin-Dependent Diabetes Mellitus. *New England Journal of Medicine* **1993**, *329*, 977-986, doi:10.1056/nejm199309303291401.
33. Reiter, C.E.; Gardner, T.W. Functions of insulin and insulin receptor signaling in retina: possible implications for diabetic retinopathy. *Prog Retin Eye Res* **2003**, *22*, 545-562, doi:10.1016/s1350-9462(03)00035-1.
34. Stratton, I.M.; Kohner, E.M.; Aldington, S.J.; Turner, R.C.; Holman, R.R.; Manley, S.E.; Matthews, D.R.; for the, U.G. UKPDS 50: Risk factors for incidence and progression of retinopathy in Type II diabetes over 6 years from diagnosis. *Diabetologia* **2001**, *44*, 156-163, doi:10.1007/s001250051594.
35. Wan, T.T.; Li, X.F.; Sun, Y.M.; Li, Y.B.; Su, Y. Recent advances in understanding the biochemical and molecular mechanism of diabetic retinopathy. *Biomed Pharmacother* **2015**, *74*, 145-147, doi:10.1016/j.biopha.2015.08.002.
36. Ahsan, H. Diabetic retinopathy--biomolecules and multiple pathophysiology. *Diabetes Metab Syndr* **2015**, *9*, 51-54, doi:10.1016/j.dsx.2014.09.011.
37. Jenkins, A.J.; Joglekar, M.V.; Hardikar, A.A.; Keech, A.C.; O'Neal, D.N.; Januszewski, A.S. Biomarkers in Diabetic Retinopathy. *Rev Diabet Stud* **2015**, *12*, 159-195, doi:10.1900/RDS.2015.12.159.
38. Frank, R.N. Diabetic retinopathy and systemic factors. *Middle East Afr J Ophthalmol* **2015**, *22*, 151-156, doi:10.4103/0974-9233.154388.
39. Kohner, E.M. Diabetic retinopathy. *BMJ* **1993**, *307*, 1195-1199, doi:10.1136/bmj.307.6913.1195.
40. Zhang, L.; Chen, B.; Tang, L. Metabolic memory: Mechanisms and implications for diabetic retinopathy. *Diabetes Research and Clinical Practice* **2012**, *96*, 286-293, doi:10.1016/j.diabres.2011.12.006.
41. ElSayed, N.A.; Aleppo, G.; Aroda, V.R.; Bannuru, R.R.; Brown, F.M.; Bruemmer, D.; Collins, B.S.; Hilliard, M.E.; Isaacs, D.; Johnson, E.L., et al. 2. Classification and Diagnosis of Diabetes: Standards of Care in Diabetes-2023. *Diabetes Care* **2023**, *46*, S19-S40, doi:10.2337/dc23-S002.
42. Tight blood pressure control and risk of macrovascular and microvascular complications in type 2 diabetes: UKPDS 38. *BMJ* **1998**, *317*, 703-713, doi:10.1136/bmj.317.7160.703.
43. Preventing blindness due to diabetic retinopathy. Control glycaemia and blood pressure, and monitor the eyes. *Prescrire international* **2010**, *19*, 35-38.
44. Effects of Medical Therapies on Retinopathy Progression in Type 2 Diabetes. *New England Journal of Medicine* **2010**, *363*, 233-244, doi:10.1056/NEJMoa1001288.
45. Scanlon, P.H. Improving the screening of risk factors in diabetic retinopathy. *Expert Rev Endocrinol Metab* **2022**, *17*, 235-243, doi:10.1080/17446651.2022.2078305.

46. Janghorbani, M.; Jones, R.B.; Allison, S.P. Incidence of and risk factors for proliferative retinopathy and its association with blindness among diabetes clinic attenders. *Ophthalmic Epidemiol* **2000**, *7*, 225-241, doi:10.1076/oep.7.4.225.4171.
47. Hammes, H.-P.; Lin, J.; Renner, O.; Shani, M.; Lundqvist, A.; Betsholtz, C.; Brownlee, M.; Deutsch, U. Pericytes and the Pathogenesis of Diabetic Retinopathy. *Diabetes* **2002**, *51*, 3107-3112, doi:10.2337/diabetes.51.10.3107.
48. Yang, J.; Liu, Z. Mechanistic Pathogenesis of Endothelial Dysfunction in Diabetic Nephropathy and Retinopathy. *Front Endocrinol (Lausanne)* **2022**, *13*, 816400, doi:10.3389/fendo.2022.816400.
49. Klaassen, I.; Van Noorden, C.J.; Schlingemann, R.O. Molecular basis of the inner blood-retinal barrier and its breakdown in diabetic macular edema and other pathological conditions. *Prog Retin Eye Res* **2013**, *34*, 19-48, doi:10.1016/j.preteyeres.2013.02.001.
50. Behl, T.; Kaur, I.; Kotwani, A. Implication of oxidative stress in progression of diabetic retinopathy. *Surv Ophthalmol* **2016**, *61*, 187-196, doi:10.1016/j.survophthal.2015.06.001.
51. Quigley, M.G. Prognosis and retinal vessel features. *Ophthalmology* **2007**, *114*, 1796-1797; author reply 1797, doi:10.1016/j.ophtha.2007.04.012.
52. Ockrim, Z.; Yorston, D. Managing diabetic retinopathy. *BMJ* **2010**, *341*, c5400, doi:10.1136/bmj.c5400.
53. Frank, R.N. Diabetic retinopathy. *N Engl J Med* **2004**, *350*, 48-58, doi:10.1056/NEJMra021678.
54. Grant, M.B.; Afzal, A.; Spoerri, P.; Pan, H.; Shaw, L.C.; Mames, R.N. The role of growth factors in the pathogenesis of diabetic retinopathy. *Expert Opin Investig Drugs* **2004**, *13*, 1275-1293, doi:10.1517/13543784.13.10.1275.
55. Solomon, S.D.; Chew, E.; Duh, E.J.; Sobrin, L.; Sun, J.K.; VanderBeek, B.L.; Wyckoff, C.C.; Gardner, T.W. Diabetic Retinopathy: A Position Statement by the American Diabetes Association. *Diabetes Care* **2017**, *40*, 412-418, doi:10.2337/dc16-2641.
56. Ola, M.S.; Nawaz, M.I.; Khan, H.A.; Alhomida, A.S. Neurodegeneration and Neuroprotection in Diabetic Retinopathy. *International Journal of Molecular Sciences* **2013**, *14*, 2559-2572.
57. Catalani, E.; Silvestri, F.; Bongiorno, S.; Taddei, A.R.; Fanelli, G.; Rinalducci, S.; De Palma, C.; Perrotta, C.; Prantera, G.; Cervia, D. Retinal damage in a new model of hyperglycemia induced by high-sucrose diets. *Pharmacol Res* **2021**, *166*, 105488, doi:10.1016/j.phrs.2021.105488.
58. Kearney, F.M.; Fagan, X.J.; Al-Qureshi, S. Review of the role of refined dietary sugars (fructose and glucose) in the genesis of retinal disease. *Clin Exp Ophthalmol* **2014**, *42*, 564-573, doi:10.1111/ceo.12290.
59. Madsen-Bouterse, S.A.; Kowluru, R.A. Oxidative stress and diabetic retinopathy: pathophysiological mechanisms and treatment perspectives. *Rev Endocr Metab Disord* **2008**, *9*, 315-327, doi:10.1007/s11154-008-9090-4.
60. Sahajpal, N.S.; Goel, R.K.; Chaubey, A.; Aurora, R.; Jain, S.K. Pathological Perturbations in Diabetic Retinopathy: Hyperglycemia, AGEs, Oxidative Stress and Inflammatory Pathways. *Curr Protein Pept Sci* **2019**, *20*, 92-110, doi:10.2174/1389203719666180928123449.
61. Gürler, B.; Vural, H.; Yilmaz, N.; Oguz, H.; Satıcı, A.; Aksoy, N. The role of oxidative stress in diabetic retinopathy. *Eye* **2000**, *14*, 730-735, doi:10.1038/eye.2000.193.
62. Kang, Q.; Yang, C. Oxidative stress and diabetic retinopathy: Molecular mechanisms, pathogenetic role and therapeutic implications. *Redox Biol* **2020**, *37*, 101799, doi:10.1016/j.redox.2020.101799.
63. Rossino, M.G.; Casini, G. Nutraceuticals for the Treatment of Diabetic Retinopathy. *Nutrients* **2019**, *11*, doi:10.3390/nu11040771.
64. Kowluru, R.A.; Kowluru, A.; Mishra, M.; Kumar, B. Oxidative stress and epigenetic modifications in the pathogenesis of diabetic retinopathy. *Prog Retin Eye Res* **2015**, *48*, 40-61, doi:10.1016/j.preteyeres.2015.05.001.
65. Ortega, Á.L. Oxidative Stress in Diabetic Retinopathy. *Antioxidants* **2021**, *10*, 50.
66. Wu, M.Y.; Yang, G.T.; Lai, T.T.; Li, C.J. The Oxidative Stress and Mitochondrial Dysfunction during the Pathogenesis of Diabetic Retinopathy. *Oxidative medicine and cellular longevity* **2018**, *2018*, 3420187, doi:10.1155/2018/3420187.
67. Giacco, F.; Brownlee, M.; Schmidt, A.M. Oxidative Stress and Diabetic Complications. *Circulation Research* **2010**, *107*, 1058-1070, doi:10.1161/CIRCRESAHA.110.223545.
68. Al-Kharashi, A.S. Role of oxidative stress, inflammation, hypoxia and angiogenesis in the development of diabetic retinopathy. *Saudi J Ophthalmol* **2018**, *32*, 318-323, doi:10.1016/j.sjopt.2018.05.002.
69. Kinuthia, U.M.; Wolf, A.; Langmann, T. Microglia and Inflammatory Responses in Diabetic Retinopathy. *Front Immunol* **2020**, *11*, 564077, doi:10.3389/fimmu.2020.564077.

70. Forrester, J.V.; Kuffova, L.; Delibegovic, M. The Role of Inflammation in Diabetic Retinopathy. *Front Immunol* **2020**, *11*, 583687, doi:10.3389/fimmu.2020.583687.
71. Spencer, B.G.; Estevez, J.J.; Liu, E.; Craig, J.E.; Finnie, J.W. Pericytes, inflammation, and diabetic retinopathy. *Inflammopharmacology* **2020**, *28*, 697-709, doi:10.1007/s10787-019-00647-9.
72. Rubsam, A.; Parikh, S.; Fort, P.E. Role of Inflammation in Diabetic Retinopathy. *Int J Mol Sci* **2018**, *19*, doi:10.3390/ijms19040942.
73. Captao, M.; Soares, R. Angiogenesis and Inflammation Crosstalk in Diabetic Retinopathy. *J Cell Biochem* **2016**, *117*, 2443-2453, doi:10.1002/jcb.25575.
74. Tu, Y.; Song, E.; Wang, Z.; Ji, N.; Zhu, L.; Wang, K.; Sun, H.; Zhang, Y.; Zhu, Q.; Liu, X., et al. Melatonin attenuates oxidative stress and inflammation of Muller cells in diabetic retinopathy via activating the Sirt1 pathway. *Biomed Pharmacother* **2021**, *137*, 111274, doi:10.1016/j.biopha.2021.111274.
75. Tu, Y.; Li, L.; Zhu, L.; Guo, Y.; Du, S.; Zhang, Y.; Wang, Z.; Zhang, Y.; Zhu, M. Geniposide Attenuates Hyperglycemia-Induced Oxidative Stress and Inflammation by Activating the Nrf2 Signaling Pathway in Experimental Diabetic Retinopathy. *Oxidative medicine and cellular longevity* **2021**, *2021*, 9247947, doi:10.1155/2021/9247947.
76. Nebbioso, M.; Lambiase, A.; Armentano, M.; Tucciarone, G.; Sacchetti, M.; Greco, A.; Alisi, L. Diabetic retinopathy, oxidative stress, and sirtuins: an in depth look in enzymatic patterns and new therapeutic horizons. *Surv Ophthalmol* **2022**, *67*, 168-183, doi:10.1016/j.survophthal.2021.04.003.
77. Zhang, T.; Ouyang, H.; Mei, X.; Lu, B.; Yu, Z.; Chen, K.; Wang, Z.; Ji, L. Erianin alleviates diabetic retinopathy by reducing retinal inflammation initiated by microglial cells via inhibiting hyperglycemia-mediated ERK1/2-NF-kappaB signaling pathway. *FASEB J* **2019**, *33*, 11776-11790, doi:10.1096/fj.201802614RRR.
78. Oshitari, T. Advanced Glycation End-Products and Diabetic Neuropathy of the Retina. *Int J Mol Sci* **2023**, *24*, doi:10.3390/ijms24032927.
79. Chen, B.H.; Jiang, D.Y.; Tang, L.S. Advanced glycation end-products induce apoptosis involving the signaling pathways of oxidative stress in bovine retinal pericytes. *Life Sci* **2006**, *79*, 1040-1048, doi:10.1016/j.lfs.2006.03.020.
80. Kandarakis, S.A.; Piperi, C.; Topouzis, F.; Papavassiliou, A.G. Emerging role of advanced glycation-end products (AGEs) in the pathobiology of eye diseases. *Prog Retin Eye Res* **2014**, *42*, 85-102, doi:10.1016/j.preteyeres.2014.05.002.
81. Behl, T.; Kotwani, A. Exploring the various aspects of the pathological role of vascular endothelial growth factor (VEGF) in diabetic retinopathy. *Pharmacol Res* **2015**, *99*, 137-148, doi:10.1016/j.phrs.2015.05.013.
82. Wong, T.Y.; Cheung, C.M.; Larsen, M.; Sharma, S.; Simo, R. Diabetic retinopathy. *Nat Rev Dis Primers* **2016**, *2*, 16012, doi:10.1038/nrdp.2016.12.
83. Stitt, A.W.; Curtis, T.M.; Chen, M.; Medina, R.J.; McKay, G.J.; Jenkins, A.; Gardiner, T.A.; Lyons, T.J.; Hammes, H.P.; Simo, R., et al. The progress in understanding and treatment of diabetic retinopathy. *Prog Retin Eye Res* **2016**, *51*, 156-186, doi:10.1016/j.preteyeres.2015.08.001.
84. Murakami, T.; Frey, T.; Lin, C.; Antonetti, D.A. Protein Kinase C β Phosphorylates Occludin Regulating Tight Junction Trafficking in Vascular Endothelial Growth Factor-Induced Permeability In Vivo. *Diabetes* **2012**, *61*, 1573-1583, doi:10.2337/db11-1367.
85. Harhaj, N.S.; Felinski, E.A.; Wolpert, E.B.; Sundstrom, J.M.; Gardner, T.W.; Antonetti, D.A. VEGF Activation of Protein Kinase C Stimulates Occludin Phosphorylation and Contributes to Endothelial Permeability. *Investigative Ophthalmology & Visual Science* **2006**, *47*, 5106-5115, doi:10.1167/iovs.06-0322.
86. Geraldès, P.; King, G.L. Activation of protein kinase C isoforms and its impact on diabetic complications. *Circ Res* **2010**, *106*, 1319-1331, doi:10.1161/CIRCRESAHA.110.217117.
87. Geraldès, P.; Hiraoka-Yamamoto, J.; Matsumoto, M.; Clermont, A.; Leitges, M.; Marette, A.; Aiello, L.P.; Kern, T.S.; King, G.L. Activation of PKC- δ and SHP-1 by hyperglycemia causes vascular cell apoptosis and diabetic retinopathy. *Nature Medicine* **2009**, *15*, 1298-1306, doi:10.1038/nm.2052.
88. Volpe, C.M.O.; Villar-Delfino, P.H.; Dos Anjos, P.M.F.; Nogueira-Machado, J.A. Cellular death, reactive oxygen species (ROS) and diabetic complications. *Cell Death Dis* **2018**, *9*, 119, doi:10.1038/s41419-017-0135-z.
89. Das Evcimen, N.; King, G.L. The role of protein kinase C activation and the vascular complications of diabetes. *Pharmacol Res* **2007**, *55*, 498-510, doi:10.1016/j.phrs.2007.04.016.

90. Kim, J.H.; Kim, J.H.; Jun, H.O.; Yu, Y.S.; Kim, K.W. Inhibition of protein kinase C delta attenuates blood-retinal barrier breakdown in diabetic retinopathy. *Am J Pathol* **2010**, *176*, 1517-1524, doi:10.2353/ajpath.2010.090398.
91. Dagher, Z.; Park, Y.S.; Asnaghi, V.; Hoehn, T.; Gerhardinger, C.; Lorenzi, M. Studies of Rat and Human Retinas Predict a Role for the Polyol Pathway in Human Diabetic Retinopathy. *Diabetes* **2004**, *53*, 2404-2411, doi:10.2337/diabetes.53.9.2404.
92. Yumnamcha, T.; Guerra, M.; Singh, L.P.; Ibrahim, A.S. Metabolic Dysregulation and Neurovascular Dysfunction in Diabetic Retinopathy. *Antioxidants (Basel)* **2020**, *9*, doi:10.3390/antiox9121244.
93. Lorenzi, M. The Polyol Pathway as a Mechanism for Diabetic Retinopathy: Attractive, Elusive, and Resilient. *Experimental Diabetes Research* **2007**, *2007*, 061038, doi:10.1155/2007/61038.
94. WHO. Guideline: Sugars intake for adults and children [Internet]. Available online: <https://www.who.int/publications/i/item/9789241549028> (accessed on 4 March, 2015).
95. Schmidt, L.A. New unsweetened truths about sugar. *JAMA Intern Med* **2014**, *174*, 525-526, doi:10.1001/jamainternmed.2013.12991.
96. Boeing, H.; Bechthold, A.; Bub, A.; Ellinger, S.; Haller, D.; Kroke, A.; Leschik-Bonnet, E.; Müller, M.J.; Oberritter, H.; Schulze, M., et al. Critical review: vegetables and fruit in the prevention of chronic diseases. *Eur J Nutr* **2012**, *51*, 637-663, doi:10.1007/s00394-012-0380-y.
97. Tanaka, S.; Yoshimura, Y.; Kawasaki, R.; Kamada, C.; Tanaka, S.; Horikawa, C.; Ohashi, Y.; Araki, A.; Ito, H.; Akanuma, Y., et al. Fruit Intake and Incident Diabetic Retinopathy with Type 2 Diabetes. *Epidemiology* **2013**, *24*.
98. Rahimi-Madiseh, M.; Malekpour-Tehrani, A.; Bahmani, M.; Rafieian-Kopaei, M. The research and development on the antioxidants in prevention of diabetic complications. *Asian Pac J Trop Med* **2016**, *9*, 825-831, doi:10.1016/j.apjtm.2016.07.001.
99. Shah, J.; Cheong, Z.Y.; Tan, B.; Wong, D.; Liu, X.; Chua, J. Dietary Intake and Diabetic Retinopathy: A Systematic Review of the Literature. *Nutrients* **2022**, *14*, doi:10.3390/nu14235021.
100. Valero-Vello, M.; Peris-Martínez, C.; García-Medina, J.J.; Sanz-González, S.M.; Ramírez, A.I.; Fernández-Albarral, J.A.; Galarreta-Mira, D.; Zanón-Moreno, V.; Casaroli-Marano, R.P.; Pinazo-Duran, M.D. Searching for the Antioxidant, Anti-Inflammatory, and Neuroprotective Potential of Natural Food and Nutritional Supplements for Ocular Health in the Mediterranean Population. *Foods* **2021**, *10*, 1231.
101. Mahoney, S.E.; Loprinzi, P.D. Influence of flavonoid-rich fruit and vegetable intake on diabetic retinopathy and diabetes-related biomarkers. *J Diabetes Complications* **2014**, *28*, 767-771, doi:10.1016/j.jdiacomp.2014.06.011.
102. Maher, P.; Hanneken, A. Flavonoids Protect Retinal Ganglion Cells from Oxidative Stress-Induced Death. *Investigative Ophthalmology & Visual Science* **2005**, *46*, 4796-4803, doi:10.1167/iovs.05-0397.
103. Alsbirk, K.E.; Seland, J.H.; Assmus, J. Diabetic retinopathy and visual impairment in a Norwegian diabetic coast population with a high dietary intake of fish oils. An observational study. *Acta Ophthalmol* **2022**, *100*, e532-e538, doi:10.1111/aos.14977.
104. Sasaki, M.; Kawasaki, R.; Rogers, S.; Man, R.E.K.; Itakura, K.; Xie, J.; Flood, V.; Tsubota, K.; Lamoureux, E.; Wang, J.J. The Associations of Dietary Intake of Polyunsaturated Fatty Acids With Diabetic Retinopathy in Well-Controlled Diabetes. *Investigative Ophthalmology & Visual Science* **2015**, *56*, 7473-7479, doi:10.1167/iovs.15-17485.
105. Chew, E.Y. Dietary Intake of Omega-3 Fatty Acids From Fish and Risk of Diabetic Retinopathy. *JAMA* **2017**, *317*, 2226-2227, doi:10.1001/jama.2017.1926.
106. Sala-Vila, A.; Díaz-López, A.; Valls-Pedret, C.; Cofán, M.; García-Layana, A.; Lamuela-Raventós, R.-M.; Castañer, O.; Zanon-Moreno, V.; Martinez-Gonzalez, M.A.; Toledo, E., et al. Dietary Marine ω -3 Fatty Acids and Incident Sight-Threatening Retinopathy in Middle-Aged and Older Individuals With Type 2 Diabetes: Prospective Investigation From the PREDIMED Trial. *JAMA Ophthalmology* **2016**, *134*, 1142-1149, doi:10.1001/jamaophthalmol.2016.2906.
107. Rosenberg, K. Omega-3 Fatty Acid Intake Lowers Risk of Diabetic Retinopathy. *Am J Nurs* **2017**, *117*, 60-61, doi:10.1097/01.NAJ.0000511570.42940.9e.
108. Gorusupudi, A.; Chang, F.Y.; Nelson, K.; Hageman, G.S.; Bernstein, P.S. n-3 PUFA Supplementation Alters Retinal Very-Long-Chain-PUFA Levels and Ratios in Diabetic Animal Models. *Mol Nutr Food Res* **2019**, *63*, e1801058, doi:10.1002/mnfr.201801058.

109. Mayor, S. Oily fish intake reduces risk of diabetic retinopathy, study shows. *BMJ* **2016**, *354*, i4586, doi:10.1136/bmj.i4586.
110. Connor, K.M.; SanGiovanni, J.P.; Lofqvist, C.; Aderman, C.M.; Chen, J.; Higuchi, A.; Hong, S.; Pravda, E.A.; Majchrzak, S.; Carper, D., et al. Increased dietary intake of ω -3-polyunsaturated fatty acids reduces pathological retinal angiogenesis. *Nature Medicine* **2007**, *13*, 868-873, doi:10.1038/nm1591.
111. Sapieha, P.; Stahl, A.; Chen, J.; Seaward, M.R.; Willett, K.L.; Krah, N.M.; Dennison, R.J.; Connor, K.M.; Aderman, C.M.; Licican, E., et al. 5-Lipoxygenase metabolite 4-HDHA is a mediator of the antiangiogenic effect of omega-3 polyunsaturated fatty acids. *Sci Transl Med* **2011**, *3*, 69ra12, doi:10.1126/scitranslmed.3001571.
112. Slomski, A. Eating Oily Fish May Protect Against Diabetic Retinopathy. *JAMA* **2016**, *316*, 1637, doi:10.1001/jama.2016.15436.
113. Kadri, R.; Vishwanath, P.; Parameshwar, D.; Hegde, S.; Kudva, A.A. Dietary associations with diabetic retinopathy-A cohort study. *Indian J Ophthalmol* **2021**, *69*, 661-665, doi:10.4103/ijo.IJO_253_20.
114. Chua, J.; Chia, A.-R.; Chee, M.L.; Man, R.E.K.; Tan, G.S.W.; Lamoureux, E.L.; Wong, T.Y.; Chong, M.F.-F.; Schmetterer, L. The relationship of dietary fish intake to diabetic retinopathy and retinal vascular caliber in patients with type 2 diabetes. *Scientific Reports* **2018**, *8*, 730, doi:10.1038/s41598-017-18930-6.
115. Sharma, Y.; Saxena, S.; Mishra, A.; Saxena, A.; Natu, S.M. Nutrition for diabetic retinopathy: plummeting the inevitable threat of diabetic vision loss. *Eur J Nutr* **2017**, *56*, 2013-2027, doi:10.1007/s00394-017-1406-2.
116. rostamkhani, H.; Mellati, A.A.; Tabaei, B.S.; Alavi, M.; Mousavi, S.N. Association of Serum Zinc and Vitamin A Levels with Severity of Retinopathy in Type 2 Diabetic Patients: a Cross-Sectional Study. *Biological Trace Element Research* **2019**, *192*, 123-128, doi:10.1007/s12011-019-01664-z.
117. Jung, K.I.; Han, J.-S.; Park, C.K. Neuroprotective Effects of Nicotinamide (Vitamin B3) on Neurodegeneration in Diabetic Rat Retinas. *Nutrients* **2022**, *14*, 1162.
118. Kuvin, J.T.; Ramet, M.E.; Patel, A.R.; Pandian, N.G.; Mendelsohn, M.E.; Karas, R.H. A novel mechanism for the beneficial vascular effects of high-density lipoprotein cholesterol: enhanced vasorelaxation and increased endothelial nitric oxide synthase expression. *Am Heart J* **2002**, *144*, 165-172, doi:10.1067/mhj.2002.123145.
119. Horikawa, C.; Aida, R.; Kamada, C.; Fujihara, K.; Tanaka, S.; Tanaka, S.; Araki, A.; Yoshimura, Y.; Moriya, T.; Akanuma, Y., et al. Vitamin B6 intake and incidence of diabetic retinopathy in Japanese patients with type 2 diabetes: analysis of data from the Japan Diabetes Complications Study (JDACS). *European Journal of Nutrition* **2020**, *59*, 1585-1594, doi:10.1007/s00394-019-02014-4.
120. Yang, X.; Hu, R.; Zhu, Y.; Wang, Z.; Hou, Y.; Su, K.; He, X.; Song, G. Meta-analysis of Serum Vitamin B12 Levels and Diabetic Retinopathy in Type 2 Diabetes. *Arch Med Res* **2023**, *54*, 64-73, doi:10.1016/j.arcmed.2022.12.006.
121. Satyanarayana, A.; Balakrishna, N.; Pitla, S.; Reddy, P.Y.; Mudili, S.; Lopamudra, P.; Suryanarayana, P.; Viswanath, K.; Ayyagari, R.; Reddy, G.B. Status of B-Vitamins and Homocysteine in Diabetic Retinopathy: Association with Vitamin-B12 Deficiency and Hyperhomocysteinemia. *PLOS ONE* **2011**, *6*, e26747, doi:10.1371/journal.pone.0026747.
122. Deshmukh, S.V.; Prabhakar, B.; Kulkarni, Y.A. Water Soluble Vitamins and their Role in Diabetes and its Complications. *Curr Diabetes Rev* **2020**, *16*, 649-656, doi:10.2174/1573399815666190916114040.
123. Shi, C.; Wang, P.; Airen, S.; Brown, C.; Liu, Z.; Townsend, J.H.; Wang, J.; Jiang, H. Nutritional and medical food therapies for diabetic retinopathy. *Eye Vis (Lond)* **2020**, *7*, 33, doi:10.1186/s40662-020-00199-y.
124. Caban, M.; Lewandowska, U. Vitamin D, the Vitamin D Receptor, Calcitriol Analogues and Their Link with Ocular Diseases. *Nutrients* **2022**, *14*, doi:10.3390/nu14112353.
125. Totolici, G.; Tiutiuca, C.; Jurja, S.; Tutunaru, D.; Pătrașcu, A.M. The role of vitamin D in the onset and progression of diabetic retinopathy. *Romanian journal of ophthalmology* **2022**, *66*, 214-218, doi:10.22336/rjo.2022.42.
126. Valle, M.S.; Russo, C.; Malaguarnera, L. Protective role of vitamin D against oxidative stress in diabetic retinopathy. *Diabetes/metabolism research and reviews* **2021**, *37*, e3447, doi:10.1002/dmrr.3447.
127. Fernandez-Robredo, P.; González-Zamora, J.; Recalde, S.; Bilbao-Malavé, V.; Bezunartea, J.; Hernandez, M.; Garcia-Layana, A. Vitamin D Protects against Oxidative Stress and Inflammation in Human Retinal Cells. *Antioxidants* **2020**, *9*, 838.
128. Ruamviboonsuk, V.; Grzybowski, A. The Roles of Vitamins in Diabetic Retinopathy: A Narrative Review. *J Clin Med* **2022**, *11*, doi:10.3390/jcm11216490.

129. Tecilazich, F.; Formenti, A.M.; Giustina, A. Role of vitamin D in diabetic retinopathy: Pathophysiological and clinical aspects. *Rev Endocr Metab Disord* **2021**, *22*, 715-727, doi:10.1007/s11154-020-09575-4.
130. Kaur, H.; Donaghue, K.C.; Chan, A.K.; Benitez-Aguirre, P.; Hing, S.; Lloyd, M.; Cusumano, J.; Pryke, A.; Craig, M.E. Vitamin D Deficiency Is Associated With Retinopathy in Children and Adolescents With Type 1 Diabetes. *Diabetes Care* **2011**, *34*, 1400-1402, doi:10.2337/dc11-0103.
131. Trott, M.; Driscoll, R.; Iraldo, E.; Pardhan, S. Associations between vitamin D status and sight threatening and non-sight threatening diabetic retinopathy: a systematic review and meta-analysis. *Journal of Diabetes & Metabolic Disorders* **2022**, *21*, 1177-1184, doi:10.1007/s40200-022-01059-3.
132. Afarid, M.; Ghattavi, N.; Johari, M. Serum Levels of Vitamin D in Diabetic Patients With and Without Retinopathy. *Journal of ophthalmic & vision research* **2020**, *15*, 172-177, doi:10.18502/jovr.v15i2.6734.
133. Ahmed, L.H.M.; Butler, A.E.; Dargham, S.R.; Latif, A.; Robay, A.; Chidiac, O.M.; Jayyousi, A.; Al Suwaidi, J.; Crystal, R.G.; Atkin, S.L., et al. Association of vitamin D2 and D3 with type 2 diabetes complications. *BMC Endocrine Disorders* **2020**, *20*, 65, doi:10.1186/s12902-020-00549-w.
134. Luo, B.-A.; Gao, F.; Qin, L.-L. The Association between Vitamin D Deficiency and Diabetic Retinopathy in Type 2 Diabetes: A Meta-Analysis of Observational Studies. *Nutrients* **2017**, *9*, 307.
135. Long, M.; Wang, C.; Liu, D. Glycated hemoglobin A1C and vitamin D and their association with diabetic retinopathy severity. *Nutrition & Diabetes* **2017**, *7*, e281-e281, doi:10.1038/nutd.2017.30.
136. Bener, A.; Elicak, M.; Cincik, H.; Öztürk, M.; DeFronzo, R.A.; Abdul-Ghani, M. The Impact of Vitamin D Deficiency on Retinopathy and Hearing Loss among Type 2 Diabetic Patients. *Biomed Res Int* **2018**, *2018*, 2714590, doi:10.1155/2018/2714590.
137. Chen, X.; Wan, Z.; Geng, T.; Zhu, K.; Li, R.; Lu, Q.; Lin, X.; Liu, S.; Chen, L.; Guo, Y., et al. Vitamin D Status, Vitamin D Receptor Polymorphisms, and Risk of Microvascular Complications Among Individuals With Type 2 Diabetes: A Prospective Study. *Diabetes Care* **2023**, *46*, 270-277, doi:10.2337/dc22-0513.
138. Ashinne, B.; Rajalakshmi, R.; Anjana, R.M.; Narayan, K.M.V.; Jayashri, R.; Mohan, V.; Hendrick, A.M. Association of serum vitamin D levels and diabetic retinopathy in Asian Indians with type 2 diabetes. *Diabetes Res Clin Pract* **2018**, *139*, 308-313, doi:10.1016/j.diabres.2018.02.040.
139. Castillo-Otí, J.M.; Galván-Manso, A.I.; Callejas-Herrero, M.R.; Vara-González, L.A.; Salas-Herrera, F.; Muñoz-Cacho, P. Vitamin D Deficiency Is Significantly Associated with Retinopathy in Type 2 Diabetes Mellitus: A Case-Control Study. *Nutrients* **2022**, *14*, 84.
140. Gungor, A.; Ates, O.; Bilen, H.; Kocer, I. Retinal Nerve Fiber Layer Thickness in Early-Stage Diabetic Retinopathy With Vitamin D Deficiency. *Invest Ophthalmol Vis Sci* **2015**, *56*, 6433-6437, doi:10.1167/jovs.15-16872.
141. He, R.; Shen, J.; Liu, F.; Zeng, H.; Li, L.; Yu, H.; Lu, H.; Lu, F.; Wu, Q.; Jia, W. Vitamin D deficiency increases the risk of retinopathy in Chinese patients with type 2 diabetes. *Diabetic medicine : a journal of the British Diabetic Association* **2014**, *31*, 1657-1664, doi:10.1111/dme.12581.
142. Nebbioso, M.; Buomprisco, G.; Pascarella, A.; Pescosolido, N. Modulatory effects of 1,25-dihydroxyvitamin D3 on eye disorders: A critical review. *Critical reviews in food science and nutrition* **2017**, *57*, 559-565, doi:10.1080/10408398.2014.893504.
143. Ren, Z.; Li, W.; Zhao, Q.; Ma, L.; Zhu, J. The impact of 1,25-dihydroxy vitamin D3 on the expressions of vascular endothelial growth factor and transforming growth factor-beta(1) in the retinas of rats with diabetes. *Diabetes Res Clin Pract* **2012**, *98*, 474-480, doi:10.1016/j.diabres.2012.09.028.
144. Milluzzo, A.; Barchitta, M.; Maugeri, A.; Magnano San Lio, R.; Favara, G.; Mazzone, M.G.; Sciacca, L.; Agodi, A. Do Nutrients and Nutraceuticals Play a Role in Diabetic Retinopathy? A Systematic Review. *Nutrients* **2022**, *14*, doi:10.3390/nu14204430.
145. Pazdro, R.; Burgess, J.R. The role of vitamin E and oxidative stress in diabetes complications. *Mech Ageing Dev* **2010**, *131*, 276-286, doi:10.1016/j.mad.2010.03.005.
146. Granado-Casas, M.; Ramírez-Morros, A.; Martín, M.; Real, J.; Alonso, N.; Valldeperas, X.; Traveset, A.; Rubinat, E.; Alcubierre, N.; Hernández, M., et al. Type 1 Diabetic Subjects with Diabetic Retinopathy Show an Unfavorable Pattern of Fat Intake. *Nutrients* **2018**, *10*, 1184.
147. Yulek, F.; Or, M.; Ozogul, C.; Isik, A.C.; Ari, N.; Stefek, M.; Bauer, V.; Karasu, C. Effects of stobadine and vitamin E in diabetes-induced retinal abnormalities: involvement of oxidative stress. *Arch Med Res* **2007**, *38*, 503-511, doi:10.1016/j.arcmed.2007.02.006.
148. Murillo, A.G.; Fernandez, M.L. Potential of Dietary Non-Provitamin A Carotenoids in the Prevention and Treatment of Diabetic Microvascular Complications. *Adv Nutr* **2016**, *7*, 14-24, doi:10.3945/an.115.009803.

149. She, C.; Shang, F.; Zhou, K.; Liu, N. Serum Carotenoids and Risks of Diabetes and Diabetic Retinopathy in a Chinese Population Sample. *Current molecular medicine* **2017**, *17*, 287-297, doi:10.2174/1566524017666171106112131.
150. Johra, F.T.; Bepari, A.K.; Bristy, A.T.; Reza, H.M. A Mechanistic Review of beta-Carotene, Lutein, and Zeaxanthin in Eye Health and Disease. *Antioxidants (Basel)* **2020**, *9*, doi:10.3390/antiox9111046.
151. Jia, Y.P.; Sun, L.; Yu, H.S.; Liang, L.P.; Li, W.; Ding, H.; Song, X.B.; Zhang, L.J. The Pharmacological Effects of Lutein and Zeaxanthin on Visual Disorders and Cognition Diseases. *Molecules* **2017**, *22*, doi:10.3390/molecules22040610.
152. Fathalipour, M.; Fathalipour, H.; Safa, O.; Nowrouzi-Sohrabi, P.; Mirkhani, H.; Hassanipour, S. The Therapeutic Role of Carotenoids in Diabetic Retinopathy: A Systematic Review. *Diabetes, metabolic syndrome and obesity : targets and therapy* **2020**, *13*, 2347-2358, doi:10.2147/dms0.S255783.
153. Ahn, Y.J.; Kim, H. Lutein as a Modulator of Oxidative Stress-Mediated Inflammatory Diseases. *Antioxidants* **2021**, *10*, 1448.
154. Neelam, K.; Goenadi, C.J.; Lun, K.; Yip, C.C.; Au Eong, K.G. Putative protective role of lutein and zeaxanthin in diabetic retinopathy. *Br J Ophthalmol* **2017**, *101*, 551-558, doi:10.1136/bjophthalmol-2016-309814.
155. Keegan, G.; Pardhan, S.; Chichger, H. Lutein and zeaxanthin attenuates VEGF-induced neovascularisation in human retinal microvascular endothelial cells through a Nox4-dependent pathway. *Exp Eye Res* **2020**, *197*, 108104, doi:10.1016/j.exer.2020.108104.
156. Sasaki, M.; Ozawa, Y.; Kurihara, T.; Kubota, S.; Yuki, K.; Noda, K.; Kobayashi, S.; Ishida, S.; Tsubota, K. Neurodegenerative influence of oxidative stress in the retina of a murine model of diabetes. *Diabetologia* **2010**, *53*, 971-979, doi:10.1007/s00125-009-1655-6.
157. Bungau, S.; Abdel-Daim, M.M.; Tit, D.M.; Ghanem, E.; Sato, S.; Maruyama-Inoue, M.; Yamane, S.; Kadonosono, K. Health Benefits of Polyphenols and Carotenoids in Age-Related Eye Diseases. *Oxidative medicine and cellular longevity* **2019**, *2019*, 9783429, doi:10.1155/2019/9783429.
158. Lem, D.W.; Gierhart, D.L.; Davey, P.G. A Systematic Review of Carotenoids in the Management of Diabetic Retinopathy. *Nutrients* **2021**, *13*, 2441.
159. Moschos, M.M.; Dettoraki, M.; Tsatsos, M.; Kitsos, G.; Kalogeropoulos, C. Effect of carotenoids dietary supplementation on macular function in diabetic patients. *Eye and Vision* **2017**, *4*, 23, doi:10.1186/s40662-017-0088-4.
160. Li, L.H.; Lee, J.C.; Leung, H.H.; Lam, W.C.; Fu, Z.; Lo, A.C.Y. Lutein Supplementation for Eye Diseases. *Nutrients* **2020**, *12*, doi:10.3390/nu12061721.
161. Brazionis, L.; Rowley, K.; Itsiopoulos, C.; O'Dea, K. Plasma carotenoids and diabetic retinopathy. *British Journal of Nutrition* **2008**, *101*, 270-277, doi:10.1017/S0007114508006545.
162. Maghsoudi, S.; Taghavi Shahraki, B.; Rabiee, N.; Fatahi, Y.; Bagherzadeh, M.; Dinarvand, R.; Ahmadi, S.; Rabiee, M.; Tahriri, M.; Hamblin, M.R., et al. The colorful world of carotenoids: a profound insight on therapeutics and recent trends in nano delivery systems. *Critical reviews in food science and nutrition* **2022**, *62*, 3658-3697, doi:10.1080/10408398.2020.1867958.
163. Landon, R.; Gueguen, V.; Petite, H.; Letourneur, D.; Pavon-Djavid, G.; Anagnostou, F. Impact of Astaxanthin on Diabetes Pathogenesis and Chronic Complications. *Marine Drugs* **2020**, *18*, 357.
164. Ozawa, Y.; Sasaki, M.; Takahashi, N.; Kamoshita, M.; Miyake, S.; Tsubota, K. Neuroprotective effects of lutein in the retina. *Curr Pharm Des* **2012**, *18*, 51-56, doi:10.2174/138161212798919101.
165. Shalini, T.; Jose, S.S.; Prasanthi, P.S.; Balakrishna, N.; Viswanath, K.; Reddy, G.B. Carotenoid status in type 2 diabetes patients with and without retinopathy. *Food & Function* **2021**, *12*, 4402-4410, doi:10.1039/D0FO03321A.
166. Perry, A.; Rasmussen, H.; Johnson, E.J. Xanthophyll (lutein, zeaxanthin) content in fruits, vegetables and corn and egg products. *Journal of Food Composition and Analysis* **2009**, *22*, 9-15, doi:10.1016/j.jfca.2008.07.006.
167. Kanwugu, O.N.; Glukhareva, T.V.; Danilova, I.G.; Kovaleva, E.G. Natural antioxidants in diabetes treatment and management: prospects of astaxanthin. *Critical reviews in food science and nutrition* **2022**, *62*, 5005-5028, doi:10.1080/10408398.2021.1881434.
168. Dong, L.-Y.; Jin, J.; Lu, G.; Kang, X.-L. Astaxanthin Attenuates the Apoptosis of Retinal Ganglion Cells in db/db Mice by Inhibition of Oxidative Stress. *Marine Drugs* **2013**, *11*, 960-974.
169. Jin, Y.; Arroo, R. The protective effects of flavonoids and carotenoids against diabetic complications—A review of in vivo evidence. *Frontiers in Nutrition* **2023**, *10*, doi:10.3389/fnut.2023.1020950.

170. Matos, A.L.; Bruno, D.F.; Ambrosio, A.F.; Santos, P.F. The Benefits of Flavonoids in Diabetic Retinopathy. *Nutrients* **2020**, *12*, doi:10.3390/nu12103169.
171. Majumdar, S.; Srirangam, R. Potential of the bioflavonoids in the prevention/treatment of ocular disorders. *Journal of Pharmacy and Pharmacology* **2010**, *62*, 951-965, doi:10.1211/jpp.62.08.0001.
172. Ola, M.S.; Al-Dosari, D.; Alhomida, A.S. Role of Oxidative Stress in Diabetic Retinopathy and the Beneficial Effects of Flavonoids. *Curr Pharm Des* **2018**, *24*, 2180-2187, doi:10.2174/1381612824666180515151043.
173. Nabavi, S.F.; Habtemariam, S.; Daglia, M.; Shafiqhi, N.; Barber, A.J.; Nabavi, S.M. Anthocyanins as a potential therapy for diabetic retinopathy. *Curr Med Chem* **2015**, *22*, 51-58, doi:10.2174/0929867321666140815123852.
174. Putta, S.; Yarla, N.S.; Kumar, K.E.; Lakkappa, D.B.; Kamal, M.A.; Scotti, L.; Scotti, M.T.; Ashraf, G.M.; Rao, B.S.B.; D, S.K., et al. Preventive and Therapeutic Potentials of Anthocyanins in Diabetes and Associated Complications. *Curr Med Chem* **2018**, *25*, 5347-5371, doi:10.2174/0929867325666171206101945.
175. Zafra-Stone, S.; Yasmin, T.; Bagchi, M.; Chatterjee, A.; Vinson, J.A.; Bagchi, D. Berry anthocyanins as novel antioxidants in human health and disease prevention. *Mol Nutr Food Res* **2007**, *51*, 675-683, doi:10.1002/mnfr.200700002.
176. Zhao, F.; Gao, X.; Ge, X.; Cui, J.; Liu, X. Cyanidin-3-o-glucoside (C3G) inhibits vascular leakage regulated by microglial activation in early diabetic retinopathy and neovascularization in advanced diabetic retinopathy. *Bioengineered* **2021**, *12*, 9266-9278, doi:10.1080/21655979.2021.1996512.
177. Li, R.; Ye, Z.; Yang, W.; Xu, Y.-J.; Tan, C.-P.; Liu, Y. Blueberry Anthocyanins from Commercial Products: Structure Identification and Potential for Diabetic Retinopathy Amelioration. *Molecules* **2022**, *27*, 7475.
178. Song, Y.; Huang, L.; Yu, J. Effects of blueberry anthocyanins on retinal oxidative stress and inflammation in diabetes through Nrf2/HO-1 signaling. *J Neuroimmunol* **2016**, *301*, 1-6, doi:10.1016/j.jneuroim.2016.11.001.
179. Wang, C.; Wang, K.; Li, P. Blueberry anthocyanins extract attenuated diabetic retinopathy by inhibiting endoplasmic reticulum stress via the miR-182/OGG1 axis. *J Pharmacol Sci* **2022**, *150*, 31-40, doi:10.1016/j.jphs.2022.06.004.
180. Huang, W.; Yan, Z.; Li, D.; Ma, Y.; Zhou, J.; Sui, Z. Antioxidant and Anti-Inflammatory Effects of Blueberry Anthocyanins on High Glucose-Induced Human Retinal Capillary Endothelial Cells. *Oxidative medicine and cellular longevity* **2018**, *2018*, 1862462, doi:10.1155/2018/1862462.
181. Francisco, S.G.; Smith, K.M.; Aragones, G.; Whitcomb, E.A.; Weinberg, J.; Wang, X.; Bejarano, E.; Taylor, A.; Rowan, S. Dietary Patterns, Carbohydrates, and Age-Related Eye Diseases. *Nutrients* **2020**, *12*, doi:10.3390/nu12092862.
182. Zhang, G.; Sun, X.; Yuan, T.; Guo, C.; Zhou, Z.; Wang, L.; Dou, G. Certain Dietary Nutrients Reduce the Risk of Eye Affliction/Retinopathy in Individuals with Diabetes: National Health and Nutrition Examination Survey, 2003-2018. *Int J Environ Res Public Health* **2022**, *19*, doi:10.3390/ijerph191912173.
183. Ganesan, S.; Raman, R.; Kulothungan, V.; Sharma, T. Influence of dietary-fibre intake on diabetes and diabetic retinopathy: Sankara Nethralaya-Diabetic Retinopathy Epidemiology and Molecular Genetic Study (report 26). *Clin Exp Ophthalmol* **2012**, *40*, 288-294, doi:10.1111/j.1442-9071.2011.02594.x.
184. Mirmiran, P.; Bahadoran, Z.; Azizi, F. Functional foods-based diet as a novel dietary approach for management of type 2 diabetes and its complications: A review. *World J Diabetes* **2014**, *5*, 267-281, doi:10.4239/wjcd.v5.i3.267.
185. Xixi, Y.; Xiaotong, H.; Changfan, W.; Stuart, K.; Xianwen, S.; Lei, Z.; Mingguang, H. Does daily dietary intake affect diabetic retinopathy progression? 10-year results from the 45 and Up Study. *British Journal of Ophthalmology* **2020**, *104*, 1774, doi:10.1136/bjophthalmol-2018-312990.
186. Neelam, K.; Dey, S.; Sim, R.; Lee, J.; Au Eong, K.G. Fructus lycii: A Natural Dietary Supplement for Amelioration of Retinal Diseases. *Nutrients* **2021**, *13*, doi:10.3390/nu13010246.
187. Yu, H.; Wark, L.; Ji, H.; Willard, L.; Jaing, Y.; Han, J.; He, H.; Ortiz, E.; Zhang, Y.; Medeiros, D.M., et al. Dietary wolfberry upregulates carotenoid metabolic genes and enhances mitochondrial biogenesis in the retina of db/db diabetic mice. *Mol Nutr Food Res* **2013**, *57*, 1158-1169, doi:10.1002/mnfr.201200642.
188. Dai, Y.; Peng, L.; Zhang, X.; Wu, Q.; Yao, J.; Xing, Q.; Zheng, Y.; Huang, X.; Chen, S.; Xie, Q. Effects of coconut water on blood sugar and retina of rats with diabetes. *PeerJ* **2021**, *9*, e10667, doi:10.7717/peerj.10667.
189. Guasch-Ferre, M.; Willett, W.C. The Mediterranean diet and health: a comprehensive overview. *J Intern Med* **2021**, *290*, 549-566, doi:10.1111/joim.13333.
190. Tosti, V.; Bertozzi, B.; Fontana, L. Health Benefits of the Mediterranean Diet: Metabolic and Molecular Mechanisms. *J Gerontol A Biol Sci Med Sci* **2018**, *73*, 318-326, doi:10.1093/gerona/glx227.

191. Widmer, R.J.; Flammer, A.J.; Lerman, L.O.; Lerman, A. The Mediterranean diet, its components, and cardiovascular disease. *Am J Med* **2015**, *128*, 229-238, doi:10.1016/j.amjmed.2014.10.014.
192. Milenkovic, T.; Bozhinovska, N.; Macut, D.; Bjekic-Macut, J.; Rahelic, D.; Velija Asimi, Z.; Burekovic, A. Mediterranean Diet and Type 2 Diabetes Mellitus: A Perpetual Inspiration for the Scientific World. A Review. *Nutrients* **2021**, *13*, doi:10.3390/nu13041307.
193. Dow, C.; Mancini, F.; Rajaobelina, K.; Boutron-Ruault, M.C.; Balkau, B.; Bonnet, F.; Fagherazzi, G. Diet and risk of diabetic retinopathy: a systematic review. *Eur J Epidemiol* **2018**, *33*, 141-156, doi:10.1007/s10654-017-0338-8.
194. Mulpuri, L.; Sridhar, J.; Goyal, H.; Tonk, R. The relationship between dietary patterns and ophthalmic disease. *Current opinion in ophthalmology* **2023**, *34*, 189-194, doi:10.1097/icu.0000000000000943.
195. Wong, M.Y.Z.; Man, R.E.K.; Fenwick, E.K.; Gupta, P.; Li, L.-J.; van Dam, R.M.; Chong, M.F.; Lamoureux, E.L. Dietary intake and diabetic retinopathy: A systematic review. *PLOS ONE* **2018**, *13*, e0186582, doi:10.1371/journal.pone.0186582.
196. Ghaemi, F.; Firouzabadi, F.D.; Moosaie, F.; Shadnoush, M.; Poopak, A.; Kermanchi, J.; Abhari, S.M.F.; Forouzanfar, R.; Mansournia, M.A.; Khosravi, A., et al. Effects of a Mediterranean diet on the development of diabetic complications: A longitudinal study from the nationwide diabetes report of the National Program for Prevention and Control of Diabetes (NPPCD 2016-2020). *Maturitas* **2021**, *153*, 61-67, doi:10.1016/j.maturitas.2021.08.003.
197. Díaz-López, A.; Babio, N.; Martínez-González, M.A.; Corella, D.; Amor, A.J.; Fitó, M.; Estruch, R.; Arós, F.; Gómez-Gracia, E.; Fiol, M., et al. Mediterranean Diet, Retinopathy, Nephropathy, and Microvascular Diabetes Complications: A Post Hoc Analysis of a Randomized Trial. *Diabetes Care* **2015**, *38*, 2134-2141, doi:10.2337/dc15-1117.
198. Do, D.V.; Wang, X.; Vedula, S.S.; Marrone, M.; Sleilati, G.; Hawkins, B.S.; Frank, R.N. Blood pressure control for diabetic retinopathy. *Cochrane Database of Systematic Reviews* **2015**, 10.1002/14651858.CD006127.pub2, doi:10.1002/14651858.CD006127.pub2.
199. Robles-Rivera, R.R.; Castellanos-Gonzalez, J.A.; Olvera-Montano, C.; Flores-Martin, R.A.; Lopez-Contreras, A.K.; Arevalo-Simental, D.E.; Cardona-Munoz, E.G.; Roman-Pintos, L.M.; Rodriguez-Carrizalez, A.D. Adjuvant Therapies in Diabetic Retinopathy as an Early Approach to Delay Its Progression: The Importance of Oxidative Stress and Inflammation. *Oxidative medicine and cellular longevity* **2020**, *2020*, 3096470, doi:10.1155/2020/3096470.
200. Oza, M.J.; Laddha, A.P.; Gaikwad, A.B.; Mulay, S.R.; Kulkarni, Y.A. Role of dietary modifications in the management of type 2 diabetic complications. *Pharmacol Res* **2021**, *168*, 105602, doi:10.1016/j.phrs.2021.105602.
201. Roy, M.S.; Janal, M.N. High caloric and sodium intakes as risk factors for progression of retinopathy in type 1 diabetes mellitus. *Arch Ophthalmol* **2010**, *128*, 33-39, doi:10.1001/archophthalmol.2009.358.
202. Yau, J.W.; Rogers, S.L.; Kawasaki, R.; Lamoureux, E.L.; Kowalski, J.W.; Bek, T.; Chen, S.J.; Dekker, J.M.; Fletcher, A.; Grauslund, J., et al. Global prevalence and major risk factors of diabetic retinopathy. *Diabetes Care* **2012**, *35*, 556-564, doi:10.2337/dc11-1909.
203. Leske, M.C.; Wu, S.Y.; Hennis, A.; Hyman, L.; Nemesure, B.; Yang, L.; Schachat, A.P.; Barbados Eye Study, G. Hyperglycemia, blood pressure, and the 9-year incidence of diabetic retinopathy: the Barbados Eye Studies. *Ophthalmology* **2005**, *112*, 799-805, doi:10.1016/j.ophtha.2004.11.054.
204. Wang, Q.; Zeng, N.; Tang, H.; Yang, X.; Yao, Q.; Zhang, L.; Zhang, H.; Zhang, Y.; Nie, X.; Liao, X., et al. Diabetic retinopathy risk prediction in patients with type 2 diabetes mellitus using a nomogram model. *Front Endocrinol (Lausanne)* **2022**, *13*, 993423, doi:10.3389/fendo.2022.993423.
205. Bryl, A.; Mrugacz, M.; Falkowski, M.; Zorena, K. The Effect of Diet and Lifestyle on the Course of Diabetic Retinopathy-A Review of the Literature. *Nutrients* **2022**, *14*, doi:10.3390/nu14061252.
206. Ellis, M.P.; Lent-Schochet, D.; Lo, T.; Yiu, G. Emerging Concepts in the Treatment of Diabetic Retinopathy. *Current Diabetes Reports* **2019**, *19*, doi:10.1007/s11892-019-1276-5.

Disclaimer/Publisher's Note: The statements, opinions and data contained in all publications are solely those of the individual author(s) and contributor(s) and not of MDPI and/or the editor(s). MDPI and/or the editor(s) disclaim responsibility for any injury to people or property resulting from any ideas, methods, instructions or products referred to in the content.