

Case Report

Not peer-reviewed version

---

# Anderson – Fabry Disease Homozygosity: Rare Case of Late-Onset Variant

---

[Gabriela Dostálová](#)\*, Jaroslav Januška, Michaela Veselá, [Petra Reková](#), Anna Táborská, Martin Pleva, David Zemánek, Aleš Linhart

Posted Date: 19 December 2023

doi: 10.20944/preprints202312.1405.v1

Keywords: Anderson - Fabry disease; homozygosity; exon 5; late onset



Preprints.org is a free multidiscipline platform providing preprint service that is dedicated to making early versions of research outputs permanently available and citable. Preprints posted at Preprints.org appear in Web of Science, Crossref, Google Scholar, Scilit, Europe PMC.

Copyright: This is an open access article distributed under the Creative Commons Attribution License which permits unrestricted use, distribution, and reproduction in any medium, provided the original work is properly cited.

*Case Report*

# Anderson - Fabry Disease Homozygosity: Rare Case of Late-Onset Variant

Gabriela Dostalova <sup>1,\*</sup>, Jaroslav Januska <sup>2</sup>, Michaela Veselá <sup>1</sup>, Petra Reková <sup>3</sup>, Anna Taborska <sup>4</sup>, Martin Pleva <sup>5</sup>, David Zemanek <sup>1</sup> and Aleš Linhart <sup>1</sup>

<sup>1</sup> 2nd Department of Medicine - Department of Cardiovascular Medicine, First Faculty of Medicine, Charles University and General University Hospital in Prague

<sup>2</sup> Department of Cardiology, Hospital Podlesi of the AGEL Group, Trinec, Czech Republic

<sup>3</sup> Department of Neurology, First Faculty of Medicine, Charles University in Prague and General University Hospital in Prague, Czech Republic

<sup>4</sup> Department of Genetics, Hospital Novy Jicin of the AGEL Group, Novy Jicin, Czech Republic

<sup>5</sup> Department of Interventional Radiology, Hospital Podlesi of the AGEL Group, Trinec, Czech Republic

\* Correspondence: gabriela.dostalova@vfn.cz

**Abstract:** Anderson – Fabry disease (AFD) is a rare, X-linked lysosomal storage disorder caused by a mutation in the  $\alpha$ -Galactosidase A gene resulting in  $\alpha$ -Galactosidase A enzyme ( $\alpha$ -Gal A) deficiency. The metabolic defect leads to progressive accumulation of glycosphingolipids and structural and functional impairment of affected organs. Due to the inheritance pattern, male patients are hemizygous with more severe manifestations of the disease as compared to females who in most cases are heterozygous with delayed and variable clinical presentation caused by uneven X – chromosome inactivation. Fabry disease cases are often identified by targeted screening programs in high-risk groups, such as in patients with end-stage renal disease, premature stroke or unexplained cardiomyopathy. Here we describe a unique case of homozygous female patient identified by a nationwide screening program in hypertrophic cardiomyopathy patients. Before the systematic screening, the patient had a diagnosis of hypertrophic obstructive cardiomyopathy and was treated accordingly including alcohol septal ablation to reduce the obstructive gradient. The confirmation of Fabry disease has led to discovery of the same variant in several members of her family. The identified variant was c.644A>G, p.Asn215Ser (N2015S) known to cause predominant cardiac involvement with late onset of the disease. The variant is amenable for an oral therapy by the small molecular chaperone migalastat which was started, then interrupted for recurrence of patient's migraine and then re-initiated again after two years. During this period the patient received enzyme replacement therapy by agalsidase beta but developed a progressively worsening venous access. Our case illustrates the importance of systematic screening of patients with clinical evidence of hypertrophic cardiomyopathy in whom routine diagnostic process fails to discover Fabry disease, in particular variants with late onset cardiac manifestations. Many of the late onset variants are amenable for orally active therapy by migalastat which significantly improves the comfort of the treatment. Its long term results are analysed by a large international "Follow-me" registry which was designed to verify the validity of pivotal trials with migalastat in Fabry disease.

**Keywords:** case report; Anderson - Fabry disease; homozygosity; exon 5; late onset

## Introduction

Anderson – Fabry disease (AFD) is a rare, X-linked lysosomal storage disorder. The mutation in the GLA gene results in  $\alpha$ -Galactosidase A enzyme ( $\alpha$ -Gal A) deficiency, followed by accumulation of its substrate, glycosphingolipids, namely globotriaosylceramide (Gb3). The overloaded lysosomes in different cells cause tissue malfunction and progressive organ failure. The clinical picture varies from the classical variant (with first signs during childhood and multiorgan involvement during young adulthood) to later-onset types, mainly characterized by single-organ manifestations, most

frequently by cardiac involvement mimicking hypertrophic cardiomyopathy [1]. For two decades the disease could be treated by enzyme replacement therapy. More recently, small molecular chaperone treatment was introduced for patients carrying amenable mutations [1–3]. Since early diagnosis is of utmost importance for the achievement of optimal therapeutic response, many efforts were made to improve timely diagnosis in affected individuals. One of the most rewarding strategies is based on high-risk population screening programs. Among those, screening in patients with unexplained cardiac hypertrophy or hypertrophic cardiomyopathy has led to the highest yields of Fabry disease detection [4,5]. This approach is relevant even in the case of diagnosing advanced stages of the disease since on average, one newly diagnosed patient allows to find another 3–4 family members affected by the disease who may benefit from prompt specific therapy initiation. [6]. In males, the diagnosis is easily done by detection of low  $\alpha$ -Gal A activity. Female patients are in general heterozygous. Depending on X-chromosome inactivation skewness, the residual activity may overlap with normal ranges and diagnostic efforts should be combined with measurements of the specific biomarker (globotriaosylsphingosine – lyso-Gb<sub>3</sub>) or directly with GLA gene sequencing [7–9]. Cases of homozygosity in females are extremely rare.

### Case description

We would like to report a case of a patient who was identified through a nationwide screening program that enrolled consecutive unrelated patients suffering from hypertrophic cardiomyopathy (HCM). This screening was conducted in 16 out of 17 cardiac centers in the Czech Republic, covering specialized cardiology care from June 2017 to December 2018. All subjects were tested for  $\alpha$ -Gal A activity and lyso-Gb<sub>3</sub> levels using the dry blood spot method. In male patients with  $\alpha$ -Gal A activity less than 1.2  $\mu$ mol/h/L, and in females with either low  $\alpha$ -Gal A activity or lyso-Gb<sub>3</sub> levels greater than 3.5 ng/mL, Fabry disease (FD) was suspected. Positive screening results were confirmed through genetic testing.

A 55-year-old woman tested positive for low enzyme activity and elevated lyso-Gb<sub>3</sub> (Table 1), indicating a potential severe GLA variant. The subsequent genetic test revealed a presence of single allele carrying a missense variant, potentially suggesting a hemizygous state, raising concerns about chromosomal changes such as Turner syndrome. However, the patient's DNA analysis showed a rare case of homozygous status. There are only a few documented cases of female AFD patients who have two  $\alpha$ -Gal A gene mutation alleles, and even fewer who are homozygous for one mutation. One such case was previously reported in Spain [11]. The pathogenic mutation identified was c.644A>G, p.Asn215Ser (N215S) in exon 5. This variant is a well-known and widespread mutation that usually results in predominant cardiac involvement [10].

A diagram showing the family's lineage was created (refer to Figure 1). Four members of the family agreed to undergo screening, and all were found to have the pathogenic variant through DNA analysis.

In our index patient, the cardiovascular system was severely affected. The patient was followed up by her cardiologist from her 50. Echocardiography described progressive left ventricular hypertrophy subsequently confirmed by the cardiac MRI scan at age of 56. The patient had also a history of dynamic midventricular obstruction caused by dominant midventricular hypertrophy, treated by two sessions of successful alcohol septal ablation with subsequent substantial amelioration of her shortness of breath and chest pain (first alcohol septal ablation done at the age of 56, repeated three years later).

Upon AFD diagnosis, the patient expressed symptoms of shortness of breath (NYHA II-III), occasional palpitations, and minimal ankle swelling that occurred mostly after prolonged standing. She did not experience any syncope and her chest pain resolved after alcohol septal ablation. The physical examination showed no angiokeratomas, a slight apical heave outside the medioclavicular line, regular heart rhythm, no audible murmurs, and no other signs of heart failure. Her blood pressure and heart rate consistently remained within normal limits.

The 12-lead ECG showed signs of incomplete right bundle branch block, prolonged QT interval, voltage criteria for left ventricular hypertrophy, and widespread repolarization changes. (Figure 2).

Her echocardiograms were of limited quality due to poor acoustic windows, as shown in Figure 3. The examination confirmed severe left ventricular hypertrophy, with the interventricular septum being thinner than the posterior wall. No obstructive gradient was detectable at rest or upon provocation manoeuvres. The ejection fraction was normal, but Doppler indices suggested elevated filling pressures, and the left atrium was moderately dilated. The right ventricle was moderately hypertrophic, nondilated, with normal systolic function and filling pressures.

Before the alcohol septal ablation, the cardiac magnetic resonance confirmed a good ejection fraction of the left ventricle. There was predominantly midventricular hypertrophy, including papillary muscles, with wall thinning in the apex due to the dynamic midventricular obstruction, as seen in Figure 4A,B. Late gadolinium enhancement revealed focal myocardial fibrosis in the inferoseptum and basal inferolateral wall, diffuse mid-wall fibrosis in the anterolateral wall, and scar in the apical part of the inferior wall, as seen in Figure 4C,D.

The patient was considered at high risk of sudden cardiac death due to the degree of hypertrophy and myocardial scarring, which resulted in cardioverter-defibrillator implantation.

The variant documented as N215S is primarily responsible for causing cardiac damage. However, even later-onset variants can exhibit a range of symptoms, including cerebrovascular issues like white matter lesions, tinnitus, vertigo, and premature stroke, as well as renal problems such as microalbuminuria and a lower GFR. Gastrointestinal problems like diarrhea, abdominal pain, and bloating, skin issues like angiokeratomas and hypohidrosis, and eye involvement like vessel tortuosity and cornea verticillata may also be encountered. In our patient, the estimated glomerular filtration rate was borderline normal with microalbuminuria between 12-24 mg/24hrs, conjunctival vessel tortuosity was observed (Figure 5). Moreover she had a history of typical peripheral neuropathic pain (often described as acropareshesias) and hypohidrosis.

The N215S variant is characterized by a relatively high residual enzyme activity responding well to treatment by small molecular chaperone migalastat. In general, the treatment is well tolerated and proven to induce significant reductions in left ventricular mass [6]. After a year of undergoing migalastat treatment, the patient experienced a recurrence of severe migraine. As a result, she switched to intravenous infusion enzyme replacement therapy (agalsidase beta 1 mg/kg/ every other week) which was well-tolerated.

Due to limited venous access a port was implanted, but required removal after four months due to infection. The patient resumed therapy with migalastat, with no significant headaches or migraines.

After 4 years of therapy, there were no noticeable changes in her clinical condition. Nonetheless, the patient reported an improved quality of life, particularly amelioration of exercise tolerance.

At age of 62, the course of the disease was further complicated by sudden abdominal pain caused by intestinal ischemia causing paralytic ileus. An angioCT examination confirmed a occlusion of the celiac trunk, resulting in necrosis of the small intestine and most of the colon. Unfortunately, the outcome of the attempted surgery was fatal.

Three affected members of her family were thoroughly investigated, some presenting typical signs and symptoms of the FD. The most severe involvement was encountered in her 57 years old brother who has a significant cardiac hypertrophy with heart failure, peripheral neuropathy, vessel tortuosities, microalbuminuria and suffers from depression. Her 39 years old niece has microalbuminuria and borderline left ventricular wall thickness, while her 30 years old daughter remains asymptomatic. Therapy was started for the proband's brother and niece as well.

## Discussion

AFD is a disorder that affects lysosomes and is linked to the X chromosome. Female carriers of the disorder may exhibit a broad range of symptoms. Some heterozygous females may remain oligosymptomatic due to the skewed X inactivation and mosaicism within tissues. However in this case of rare homozygosity the mitigation of the clinical manifestation by remaining unaffected allele is impossible. In our patient this was reflected by high lyso Gb3 and low residual enzyme activity , showing values usually seen in male patients with late-onset variants. The course of the disease was

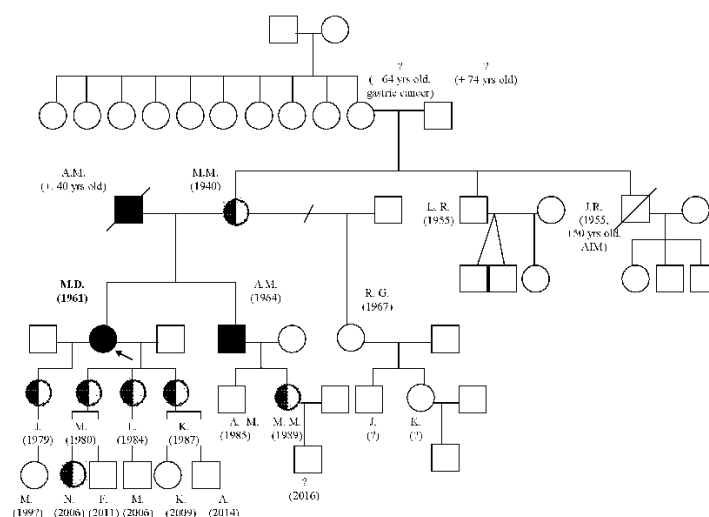
also comparable to male patients with severe cardiac involvement leading to multiple complications. Unfortunately, in our patients AFD was diagnosed late already having irreversible cardiac changes which prevented achieving a more favourable outcome despite chaperone and enzyme replacement therapy.

## Conclusion

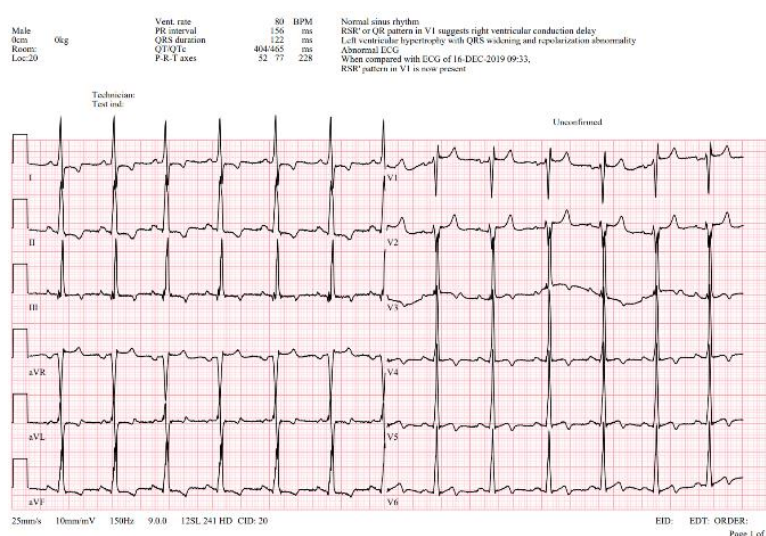
Although AFD is a rare inherited disease, screening programs in patients with HCM or unexplained left ventricular hypertrophy have shown that between 1% and 4% are caused by AFD. With enzyme replacement or chaperone treatment available, it is crucial to diagnose the disease as early as possible to ensure better patient outcomes.

**Table 1.** Dried Blood Spot screening results.

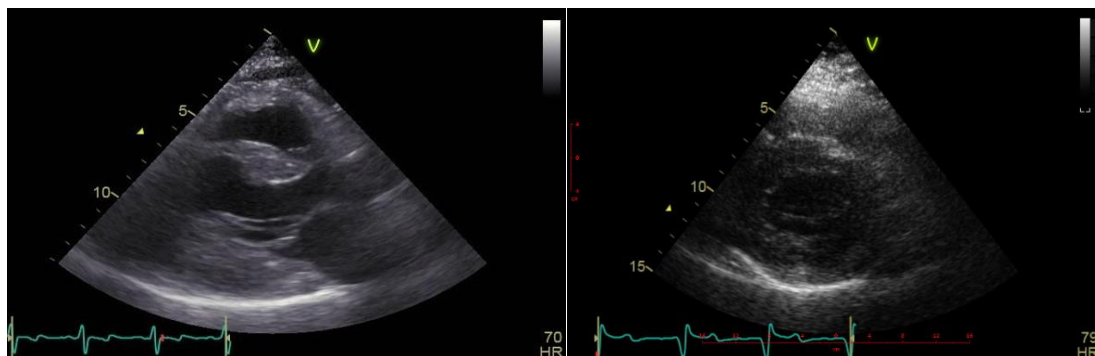
	Results	Unit	Cut-off value
$\alpha$ -Galactosidase A enzyme activity	0.3	$\mu\text{mol/l}$	> 1.2
lyso-Gb <sub>3</sub>	10.0	ng/mL	0.0 - 3.5



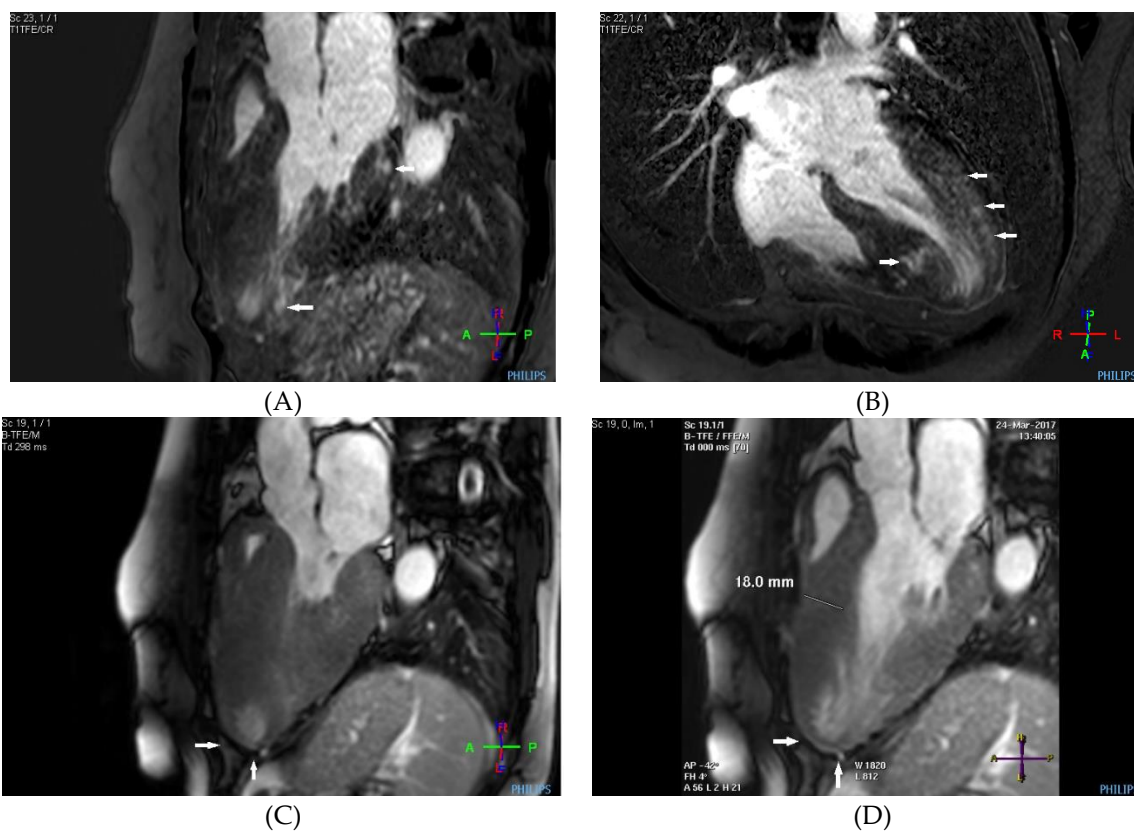
**Figure 1.** Pedigree of the index patient (proband).




**Figure 2.** ECG\* – abnormal ECG curve showing normal sinus rhythm, normal PQ interval (150ms), left ventricular hypertrophy with QRS widening (122ms) with right bundle branch pattern and repolarization abnormalities, prolonged QTc interval (QtC 465ms).



**Figure 3.** Echocardiography – parasternal long and short axis view showing massive hypertrophy particularly within the posterior wall superseding the thickening of the interventricular septum.



**Figure 4. A-D** MRI scan **A, B** : Steady-state free precession cardiovascular magnetic resonance end-diastolic and end-systolic images in long-axis presented dominant midventricular hypertrophy of left ventricle (including papillary muscles) and wall thinning in the apex (arrows) due to dynamic midventricular obstruction. **C, D**: Late gadolinium enhancement in long-axis views demonstrating focal myocardial fibrosis in the inferoseptum and basal inferolateral wall, diffuse mid-wall fibrosis in the anterolateral wall and scar in the apical part of inferior wall (arrows).



**Figure 5. Eye involvement\*** – conjunctival vessel tortuosity.

**Funding:** This work was supported in part by grant from Sanofi/Genzyme GZ-2017-11701.

**Acknowledgments:** The authors obtained written informed consent from the patient's family for publication. The authors would like to thank I. Švandová for preparing the pedigree diagram and the patient's family for their cooperation and agreement to publish their results.

**Conflicts of Interest:** Dostálová G.: honoraria and consulting fees from Amicus Therapeutics, Sanofi, Chiesi and Takeda . SI the Bridge study PB-102-F30 NCT03018730. Januska J.: nothing to declare. Veselá M.: nothing to declare. Zemanek D.: Speaking honoraria from Sanofi and Takeda. Reková, P.: Speaking honoraria from Sanofi and Takeda. Taborska A., nothing to declare. Pleva M.: nothing to declare. Linhart A: Fabry Registry Board member; honoraria and consulting fees from Amicus Therapeutics, Sanofi , Chiesi and Takeda . PI the Bridge study PB-102-F30 NCT03018730.

## References

1. A. Ortiz, D.P. Germain, R.J. Desnick, J. Politei, M. Mauer, A. Burlina, C. Eng, R.J. Hopkin, D. Laney, A. Linhart, S. Waldek, E. Wallace, F. Weidemann, and W.R. Wilcox, Fabry disease revisited: Management and treatment recommendations for adult patients. *Molecular genetics and metabolism* 123 (2018) 416-427.
2. D.P. Germain, A. Fouilhoux, S. Decramer, M. Tardieu, P. Pillet, M. Fila, S. Rivera, G. Deschênes, and D. Lacombe, Consensus recommendations for diagnosis, management and treatment of Fabry disease in paediatric patients. *Clinical genetics* 96 (2019) 107-117.
3. T.P. Bernardes, R.D. Foresto, and G.M. Kirsztajn, Fabry disease: genetics, pathology, and treatment. *Revista da Associacao Medica Brasileira* (1992) 66Suppl 1 (2020) s10-s16.
4. A. Linhart, and F. Cecchi, Common presentation of rare diseases: Left ventricular hypertrophy and diastolic dysfunction. *International journal of cardiology* 257 (2018) 344-350.
5. T. Palecek, J. Honzikova, H. Poupetova, H. Vlaskova, P. Kuchynka, L. Golan, S. Magage, and A. Linhart, Prevalence of Fabry disease in male patients with unexplained left ventricular hypertrophy in primary cardiology practice: prospective Fabry cardiomyopathy screening study (FACSS). *Journal of inherited metabolic disease* 37 (2014) 455-60.
6. D.P. Germain, P.M. Elliott, B. Falissard, V.V. Fomin, M.J. Hilz, A. Jovanovic, I. Kantola, A. Linhart, R. Mignani, M. Namdar, A. Nowak, J.P. Oliveira, M. Pieroni, M. Viana-Baptista, C. Wanner, and M. Spada, The effect of enzyme replacement therapy on clinical outcomes in male patients with Fabry disease: A

- systematic literature review by a European panel of experts. *Molecular genetics and metabolism reports* 19 (2019) 100454.
7. A. Nowak, T. Mechtler, D.C. Kasper, and R.J. Desnick, Correlation of Lyso-Gb3 levels in dried blood spots and sera from patients with classic and Later-Onset Fabry disease. *Molecular genetics and metabolism* 121 (2017) 320-324.
  8. L. Echevarria, K. Benistan, A. Toussaint, O. Dubourg, A.A. Hagege, D. Eladari, F. Jabbour, C. Beldjord, P. De Mazancourt, and D.P. Germain, X-chromosome inactivation in female patients with Fabry disease. *Clinical genetics* 89 (2016) 44-54.
  9. S. Balendran, P. Oliva, S. Sansen, T.P. Mechtler, B. Streubel, P.N. Cobos, Z. Lukacs, and D.C. Kasper, Diagnostic strategy for females suspected of Fabry disease. *Clinical genetics* 97 (2020) 655-660.
  10. D.P. Germain, E. Brand, A. Burlina, F. Cecchi, S.C. Garman, J. Kempf, D.A. Laney, A. Linhart, L. Maródi, K. Nicholls, A. Ortiz, F. Pieruzzi, S.P. Shankar, S. Waldek, C. Wanner, and A. Jovanovic, Phenotypic characteristics of the p.Asn215Ser (p.N215S) GLA mutation in male and female patients with Fabry disease: A multicenter Fabry Registry study. *Molecular genetics & genomic medicine* 6 (2018) 492-503.
  11. A. Rodríguez-Marí, M.J. Coll, and A. Chabás, Molecular analysis in Fabry disease in Spain: fifteen novel GLA mutations and identification of a homozygous female. *Human mutation* 22 (2003) 258.

**Disclaimer/Publisher's Note:** The statements, opinions and data contained in all publications are solely those of the individual author(s) and contributor(s) and not of MDPI and/or the editor(s). MDPI and/or the editor(s) disclaim responsibility for any injury to people or property resulting from any ideas, methods, instructions or products referred to in the content.