

Review

Not peer-reviewed version

Morphological Aspects of the Liver

[Antonella A Chesca](#) *

Posted Date: 13 December 2023

doi: 10.20944/preprints202312.0919.v1

Keywords: liver; diseases; cirrhosis; diagnosis; management



Preprints.org is a free multidiscipline platform providing preprint service that is dedicated to making early versions of research outputs permanently available and citable. Preprints posted at Preprints.org appear in Web of Science, Crossref, Google Scholar, Scilit, Europe PMC.

Copyright: This is an open access article distributed under the Creative Commons Attribution License which permits unrestricted use, distribution, and reproduction in any medium, provided the original work is properly cited.

Review

Morphological Aspects of the Liver

Antonella Chesca

Transylvania University of Brasov, Romania; anto.chesca@gmail.com

Abstract: Chronic liver diseases stimulate a degree of hepatocyte injury. This previously mentioned modifications, alters the known liver architecture and finally ends in cirrhosis. The management of this liver pathology, is centred on the treatment of the causes and complications. Liver transplantation can be required in some cases. The aim of this article is to identify the best available evidences analyzing liver samples, normal and pathological. Were made permanent preparations and used two colors. Hematoxylin–Eosin and also Goldner Szekely trichrome stains stain for observation at optical microscope with x10 and x40 lens magnification. Samples liver collected during necropsy, from healthy patients and from patients diagnosed with cirrhosis. Normal liver with hepatocytes, Kiernann space, connective septa, observations using lens x10 and samples colored with Goldner Szekely trichrome stains. Beside, for comparisons, ill liver images, classic stain H&E. Our contribution in the written text, is related to the impact of physical, psychological and physiological factors.

Keywords: liver; diseases; cirrhosis; diagnosis; management

1. Introduction

Cirrhosis, as a nowadays disease, is characterized by fibrosis and nodule formation of the liver. In the secondary plan, it is known as a chronic injury, which leads to alteration of the normal lobular organization of the liver. A complex of factors, such as life style, or environmentals, can injure the liver, and beside also including viral infections, toxins, hereditary. With each injury, the liver suffer alterations as fibrosis. Finally but after a long-standing injury, liver functional alteration, develop in time cirrhosis as a complex diseases.

Ethiology of the chronic liver diseases usually progress unfortunately in cirrhosis, following pathological mechanisms. In the research, the most common causes of cirrhosis are hepatitis C virus (HCV), alcoholic liver disease, and nonalcoholic steatohepatitis (NASH). Hepatitis B virus (HBV) and HCV are the most common causes.[1] Other ethiological points of cirrhosis include autoimmune hepatitis, primary biliary cholangitis, primary sclerosing cholangitis, hemochromatosis, Budd-Chiari syndrome, Wilson disease, alpha-1 antitrypsin deficiency, drug-induced liver cirrhosis, and chronic right-sided heart failure. [1]

The cause of morbidity and mortality in cirrhosis is the development of portal hypertension and hyperdynamic circulation. Portal hypertension develops secondary to fibrosis and vasoregulatory alterations. [2]

Liver fibrosis it is known by excessive synthesis and deposition of connective tissue proteins. Interstitial collagens in the extracellular matrix of the liver has been discovered in this liver pathology. Hepatocytes alterations, results of an abnormal wound healing in response to chronic liver injury, previously mentioned in this written pages. The long term stimuli involved in the initiation of fibrosis leads to oxidative stress. Next point that concure to disease include mediators of molecular events involved in the pathogenesis of hepatic fibrosis. These processes lead to cellular injury and initiate inflammatory responses. As a response, cytokines and growth factors play a role as trigger activation and transformation of resting hepatic stellate cells into myofibroblast like cells. At the end of process, start an excessive synthesis of connective tissue proteins, including collagens. Uncontrolled and hepatocyte fibrosis results in distortion of lobular architecture of the liver. Pathologists show the nodular formations in the liver as a diagnosis of cirrhosis. The liver strucure injury and regeneration

process could also results in genomic aberrations and mutations. Finally, develop hepatocellular carcinoma. This review try to cover various aspects of the molecular mechanisms involved in the pathogenesis of hepatic fibrosis. A great point of our this scientific orientation, is hepatic fibrosis diagnosis, with special emphasize on N-Nitrosodimethylamine (NDMA; Dimethylnitrosamine, DMN) as the inducing agent. [3]

Prevention and treatment of liver cirrhosis are best done by an interdisciplinary medical team. This scientifically team, include a pathologist, a gastroenterologist, liver surgeon. Beside, a medical team include nurse practitioner, primary care provider and an internist. Liver cirrhosis is associated with systemic complications that can cause death of patients. A liver transplant is not an option from different causes.

Weight loss of at least 7% is good for renewal pathological alterations of the liver structure.

Therapy methods and drugs, are more important, including antiviral medications in viral hepatitis, steroids, and immunosuppressant agents in autoimmune hepatitis, ursodeoxycholic acid and obeticholic acid in primary biliary cholangitis, copper chelation in Wilson disease, and iron chelation and phlebotomy in hemochromatosis. [4]

2. Material and Methods

In order to analyze morphological structural particularities, samples liver collected during necropsy, from healthy patients and from patients diagnosed with cirrhosis.

Following this purpose, were made permanent preparations that were stained with hematoxylin and eosin for observation at optical microscope. The process of the permanent microscopic preparations was based on prior knowledge of the steps from the classical method, using a standard H&E staining technique. Also normally liver samples, were observed by optical microscope using Goldner Szekely trichrome stains. Optical microscope examination were used lens with magnification x10 and x40.

3. Results

The functional unit of the liver is the lobule with hexagonal form. Kienann space is specific for liver strucutre, including a portal triad (portal vein, hepatic artery, bile duct) sits at each corner of the hexagon. Mitochondri as points observing with lens x40. Portal vein with enlarge lumen. (Figure 1)

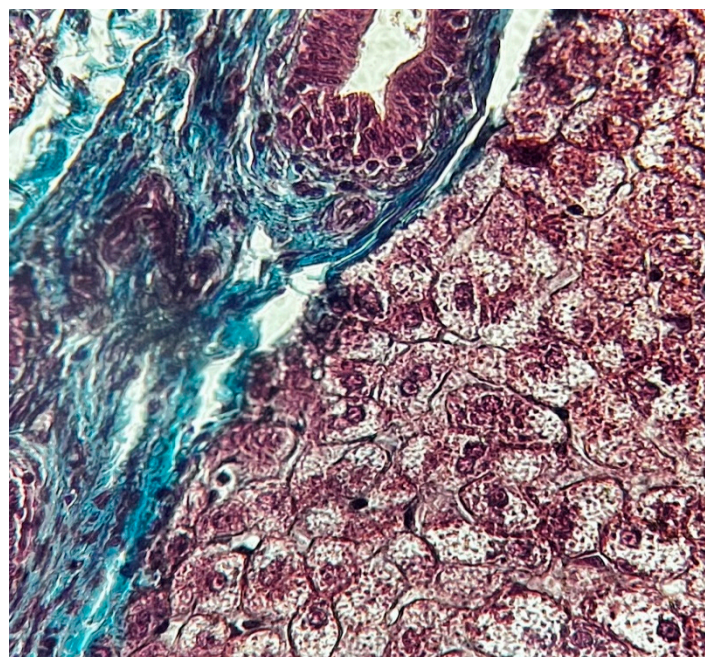


Figure 1. Normal liver x 40 Goldner Szekely stain.

Based on function and perfusion, hepatocytes are divided into three zones.

1. Zone I is considered to be the periportal region of hepatocytes and are the best perfused and first to regenerate due to their proximity to oxygenated blood and nutrients. Implication in oxidative metabolisms.
2. Zone II is defined as the pericentral region of the hepatocytes.
3. Zone III has the lowest perfusion due to its distance from the portal triad. Implication role in detoxification.

Also Kiernann space, hepatocytes, connective septa, in normal liver. (Figure 2)

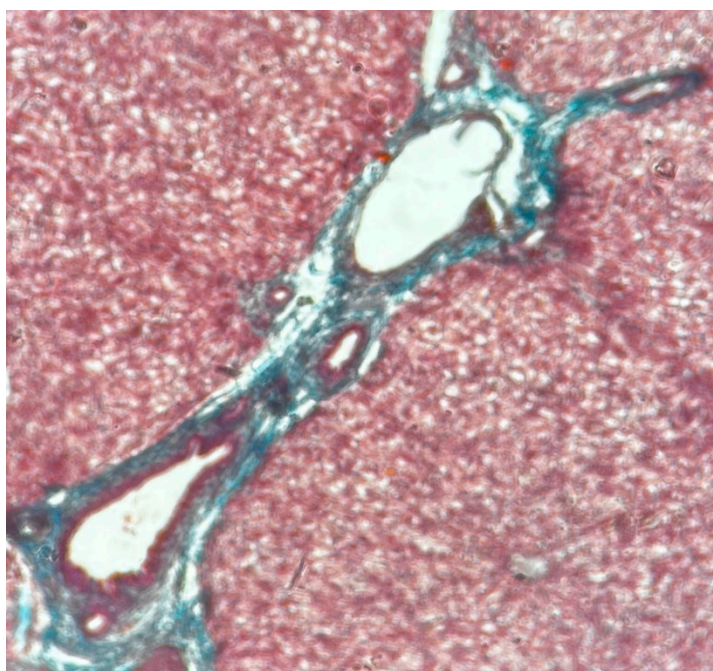


Figure 2. Normal liver x10 Goldner Szekely stain.

Cirrhosis is a result of continuous liver injury, inflammation, fibrosis, and necrosis. Commonly cause cirrhosis are chronic hepatitis B and C and also life style including alcoholism. The fibrosis present in cirrhosis occurs from the secretion of TGF-beta from the Ito cells in the space of Disse. (Figure 3)

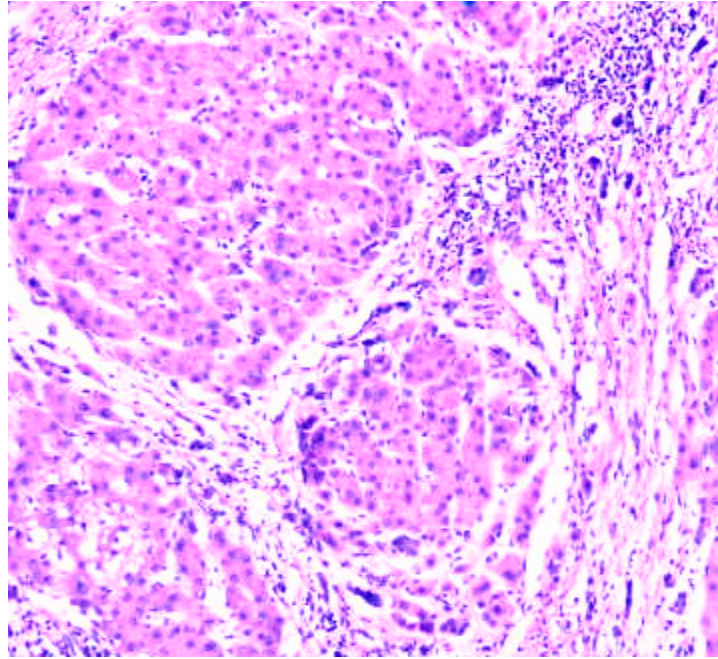


Figure 3. Cirrhosis liver x10 H&E stain.

Cirrhosis usually represents with end-stage liver disease. Hepatitis C is the most damaging. Cirrhosis develops after a period of inflammation. The ill liver has parenchyma with fibrotic tissue and regenerative nodules. (Figure 4)

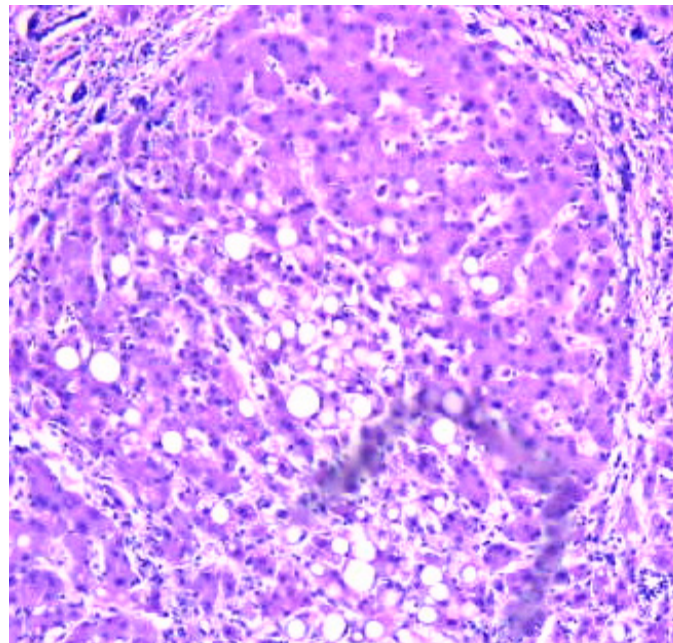


Figure 4. Cirrhosis liver x10 H&E stain.

Liver fibrosis impairs hepatic function and causes structural change with different types of damages. (Figure 5)

Clinically, liver cirrhosis is the severe period of chronic liver diseases. Early prevention and treatment of the causes of development and progression and pathogenic mechanism may slow down or reverse liver cirrhosis and its severe complications.

Decompensated liver cirrhosis and its complications, take attention to the clinicians. Various clinically signs as ascites, esophagogastric variceal bleeding, hepatic encephalopathy, acute kidney

injury, and hepatocellular carcinoma, could be observing at the medical examination. Clearly that patients' quality of life is affected in liver cirrhosis.

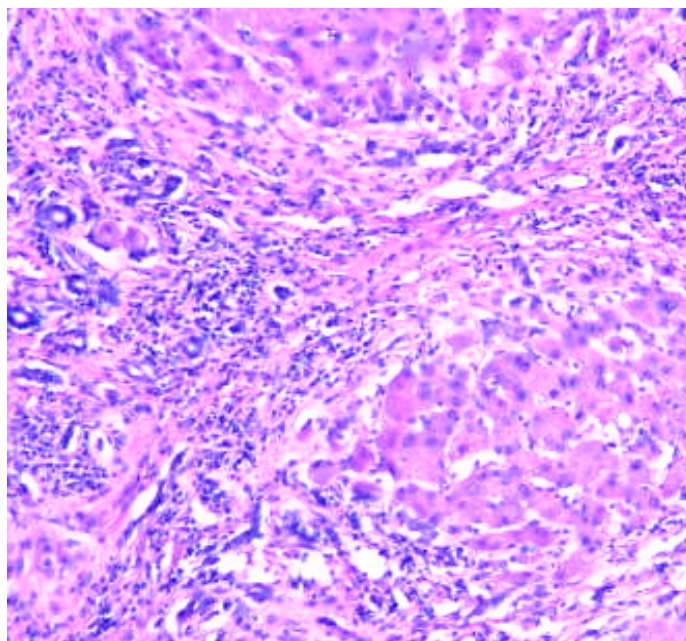


Figure 5. Cirrhosis liver x10 H&E stain.

Liver fibrosis score, standard ultrasonography, and transient elastography are important for practicum. Also useful in identifying ill patients with no to minimal fibrosis or advanced fibrosis., medical tests. (6) In this medical direction, chronic liver disease management includes directed counseling, laboratory testing, and ultrasound monitoring.

The management of liver cirrhosis is centred on the clinical part. The proper treatment of the causes and complications and liver transplantation could be prioritaire.

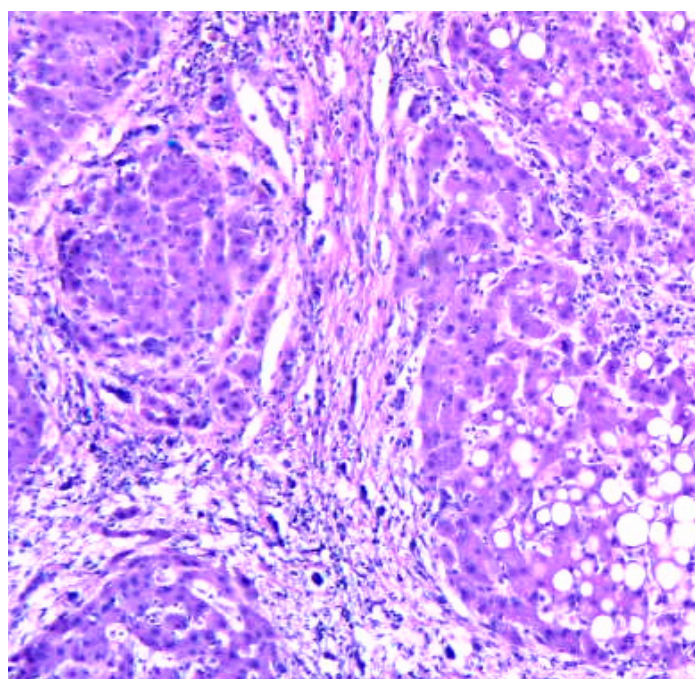


Figure 6. Cirrhosis liver x10 H&E stain.

The Child-Pugh score and model for end-stage liver disease (MELD) score are both used to assess and determine prognosis in cirrhotic patients. The MELD score uses creatinine, bilirubin, and INR. While both are used to create a predictive model for cirrhotic patients, the MELD score is the scale of choice for the evaluation of liver transplant patients.

4. Discussions

Patient lifestyle changes, unfortunately cannot cure cirrhosis. Complications accompanying hepatic cirrhosis include portal hypertension, edema in the abdomen and lower extremities, splenomegaly, infections, hepatic encephalopathy.

Behavioral modifications can prevent or at least delay disease progression and provide symptomatic relief.

Lifestyle changes, include factors, as eliminating ethanol consumption and dietary interventions as possible low-sodium diet, in order to reduce water retention. Regulate protein intake according to their doctor's directions and some medical recommendations, will be proper in the treatment of cirrhosis.

Differential diagnosis of cirrhosis include research directions referring to neonatal iron storage diseases, HELLP(hemolysis, elevated liver enzymes, low platelets) syndrome of pregnancy, idiopathic drug reaction. More than, other diseases are included in the differential diagnosis of cirrhosis. This are Tyrosinemia, Galactosemia, Fructose intolerance

5. Conclusions

Cirrhosis secondary to HBV and HCV is one of the common risk factor for liver degeneration in cirrhosis.. Practically monitoring of cirrhotic patients is recommended, with at least six monthly screenings. Liver biopsy is the gold standard technique highly promising non-invasive methodology under development, that are used in diagnosis. Liver transplantation (LT) is also an effective therapeutic option for the management of cirrhosis end-stage. Relatively recently research investigations try to elucidate the signal transduction pathways that link hepatocytes alterations including cellular dysfunctionality.

Author Contributions: fully version of the manuscript.

Funding: This manuscript received no external funding.

Institutional Review Board Statement: Not applicable.

Informed Consent Statement: Not applicable.

Data Availability Statement: Not applicable.

Acknowledgments: We are grateful to Mr. Tim Sandle PhD, for their helpful comments.

Conflicts of Interest: The author declare no conflict of interest.

References

1. Naveau S, Perlemuter G, Balian A. [Epidemiology and natural history of cirrhosis]. *Rev Prat.* 2005 Sep 30;55(14):1527-32.
2. Kim MY, Baik SK, Lee SS. Hemodynamic alterations in cirrhosis and portal hypertension. *Korean J Hepatol.* 2010 Dec;16(4):347-52.
3. George Joseph, Mutsumi, Tsutsumi Mikihiro, Molecular mechanisms in the pathogenesis of N-nitrosodimethylamine induced hepatic fibrosis, *Cell Death Dis.*, . 2019 Jan 8;10(1):18.
4. Promrat K, Kleiner DE, Niemeier HM, Jackvony E, Kearns M, Wands JR, Fava JL, Wing RR. Randomized controlled trial testing the effects of weight loss on nonalcoholic steatohepatitis. *Hepatology.* 2010 Jan;51(1):121-9
5. Hayward KL, Weersink RA. Improving Medication-Related Outcomes in Chronic Liver Disease. *Hepatol Commun.* 2020 Nov;4(11):1562-1577.

6. Mittal S, El-Serag HB. Epidemiology of hepatocellular carcinoma: consider the population. *J Clin Gastroenterol*. 2013 Jul;47 Suppl:S2-6
7. Schuppan D, Afdhal NH. Liver cirrhosis. *Lancet*. 2008 Mar 08;371(9615):838-51.
8. Scaglione S, Kliethermes S, Cao G, Shoham D, Durazo R, Luke A, Volk ML. The Epidemiology of Cirrhosis in the United States: A Population-based Study. *J Clin Gastroenterol*. 2015 Sep;49(8):690-6.
9. Kim MY, Baik SK, Lee SS. Hemodynamic alterations in cirrhosis and portal hypertension. *Korean J Hepatol*. 2010 Dec;16(4):347-52
10. John S, Thuluvath PJ. Hyponatremia in cirrhosis: pathophysiology and management. *World J Gastroenterol*. 2015 Mar 21;21(11):3197-205.
11. Lata J. Hepatorenal syndrome. *World J Gastroenterol*. 2012 Sep 28;18(36):4978-84.
12. Promrat K, Kleiner DE, Niemeier HM, Jackvony E, Kearns M, Wands JR, Fava JL, Wing RR. Randomized controlled trial testing the effects of weight loss on nonalcoholic steatohepatitis. *Hepatology*. 2010 Jan;51(1):121-9.
13. Vinaixa C, Rubín A, Aguilera V, Berenguer M. Recurrence of hepatitis C after liver transplantation. *Ann Gastroenterol*. 2013;26(4):304-313.
14. Tangkijvanich P, Yee Hal F. Jr., Cirrhosis--can we reverse hepatic fibrosis? *Eur J Surg Suppl.*, 2002;(587):100-12.

Disclaimer/Publisher's Note: The statements, opinions and data contained in all publications are solely those of the individual author(s) and contributor(s) and not of MDPI and/or the editor(s). MDPI and/or the editor(s) disclaim responsibility for any injury to people or property resulting from any ideas, methods, instructions or products referred to in the content.